

Cervical Cytological and Colposcopic Findings in Cases Associated with Prolonged Use of Intrauterine Devices versus Long Acting Injectable Contraceptive Agents

Tamer M. Assar, Ali Q. Algazzar, Omar S. Ward, Mohamed A. Algazzar

Obstetrics and Gynecology
Department, Faculty of
Medicine Benha University,
Egypt.

Corresponding to: Omar S.
Ward. Obstetrics and
Gynecology Department,
Faculty of Medicine Benha
University, Egypt.

Email:
Maro.ward121990@gmail.com

Received: 24 July 2024

Accepted: 7 October 2024

Abstract:

Background: Early detection and treatment of cervical neoplasia depends on the accurate interpretation of the cytologic sample. This study aimed to assess cervical cytological and colposcopic findings in cases associated with prolonged use of Copper T 380 intrauterine devices (IUD) versus long acting depot medroxy-progesterone acetate injectable contraceptive agents. **Methods:** This case control study was conducted on 120 women who were using Copper T 380A intrauterine contraceptive device or long acting depot medroxy-progesterone acetate injections at least 3 years, asymptomatic seeking regular cervical screening program, or symptomatic with contact bleeding. Patients were divided into two equal groups: Group A: women using Copper T 380A intrauterine contraceptive device (Pregna®, DKT, Egypt), and Group B: women using depot medroxy-progesterone acetate contraceptive injections (Oxyprogest®, 150mg, vial, Acdima, Egypt). ALL patients were subjected to colposcopy and pap smear. **Results:** Colposcope was an accurate method for assessment of women with suspected cervical lesion using long term contraceptive method either IUD or hormonal injections with sensitivity 98%, specificity 92.9%, PPV 90.7% and NPV 98.5% respectively. Long term IUD users were proved to have higher frequency of bleeding 40 (66.7%) vs. 29 (48.3%), discharge 46 (76.7%) vs. 31 (51.7%), pain 28 (46.7%) vs. 16 (26.7%) and abnormal colposcopic findings 33 (55.0%) vs. 21 (35.0%) and cervical biopsies 31 (51.7%) vs. 19 (31.7%) compared with long term hormonal injections users. **Conclusion:** Colposcopy is an accurate method for assessment of women with suspected cervical lesion using long term contraceptive method either IUD or hormonal injections.

Keywords: Cervical Cytology; Colposcopy; Intrauterine Devices Injectable Contraceptive

Introduction

When a woman with cervical dysplasia or cervical neoplasia has abnormal cervical cells, PaPscreening is still the recommended course of action ⁽¹⁾.

For many, good cytologic interpretation is essential to the early detection and treatment of cervical neoplasia. It has been demonstrated that the Pap test's sensitivity ranges from 50 to 75 percent ⁽²⁾.

Cytologic screening depends on a pathology expert's subjective evaluation of the material ⁽³⁾.

Any element that influences the cells in the sample may theoretically potentially have an impact on how the sample is interpreted later. External hormones impact the cellular properties of the cervical region ⁽⁴⁾.

Birth control pills known as long-acting reversible contraceptives (LARC) offer long-lasting, effective contraception without the need for user intervention. They consist of intrauterine devices (IUDs) and injections ⁽⁵⁾.

Because their effectiveness is independent of patient compliance, they are the most effective reversible means of contraception. LARCs are underutilized despite being safe and effective; globally, just 15.5% of women use IUDs and 3.4% use injections ⁽⁶⁾.

Nonetheless, there have been contradictory reports on the relationship between cervical cytology changes and IUD use. An evaluation of the study program on HPV and cervical cancer conducted by the Institut Català d'Oncologia and the International Agency for study on Cancer revealed a considerable negative correlation between cervical cytology alterations and IUD use history ⁽⁷⁾.

However, a woman undergoing hormone replacement treatment or contraception may come into contact with exogenous hormones. Exposure to exogenous hormones can cause cellular consequences such as navicular cells (thick, bordered, glycogen-filled squamous cells), crowding, and curling of cells ⁽⁸⁾.

These cellular changes could make cytologic interpretation challenging, albeit the matter has not received much attention ⁽⁹⁾.

One type of long-acting reversible birth control (LARC) with a 0.8% failure rate is the copper IUD. Additionally, up to 19% of women utilize methods of contraception that simply include progesterone ⁽¹⁰⁾.

This implies that any phenomena relating to copper and progesterone exposure as well as variations in cytologic interpretation could potentially harm women ⁽¹¹⁾.

There have been conflicting results thus far regarding the precise impact of progesterone and copper on cytologic interpretation. A higher number of false positive and false negative cervical alterations have been shown in various investigations ⁽¹²⁾.

The aim of this work was to assess cervical cytological and colposcopic findings in cases associated with prolonged use of Copper T 380 intrauterine devices versus long acting depot medroxy-progesterone acetate injectable contraceptive agents.

Patients and Methods:

This cross-sectional observational study was carried out on 120 women aged from 20 – 50 years old, who were using Copper T 380A intrauterine contraceptive device or long acting depot medroxy-progesterone acetate injections at least 3

years, asymptomatic seeking regular cervical screening program, or symptomatic with contact bleeding.

An informed written consent was obtained from the patients. The study was done after approval from the Ethical Committee of Benha University Hospitals (approval code: MS 46-7-2022).

The study took place at Benha University Hospitals between January 2022 and December 2023.

Exclusion criteria were undiagnosed vaginal bleeding, pregnancy, taking alcohol and or tobacco, active vaginal infection, active human papilloma virus infection (genital warts), history of sexual transmitted diseases, previous diagnosed cervical intraepithelial neoplasia (CIN) or cervical cancer, previous cervical operations as large loop excision of the transformation zone (LLETZ), loop electrosurgical excision procedure (LEEP), conization or cauterization, and refusing to participate in the study.

Patients were divided into two equal groups: Group A: women using Copper T 380A intrauterine contraceptive device (Pregna®, DKT, Egypt), and Group B: women using depot medroxy-progesterone acetate contraceptive injections (Oxyprogest®, 150mg, vial, Acdima, Egypt).

The demographic, maternal characteristics were extracted from a questionnaire during their first health care visit. All patients were subjected to complete history taking of clinical importance including personal history, present history (onset, course, duration, exaggerating factors), Menstrual history (last menstrual period, regularity, amount, pain and length), sexual history: pain, bleeding or abnormal discharge, Obstetric history (gravidity, parity, previous miscarriages or obstetric

complications), contraceptive history (previous methods, duration and associated symptoms), medical history (comorbidities as hepatic, renal, endocrinal, psychosocial condition, cardiovascular, diabetes, chronic hypertension to exclude immune-compromised patients), surgical history (Previous operations especially cervical operations and its outcomes), and family history of maternal of gynecological neoplasia. Clinical examination included general examination (Vital signs, pallor and BMI), Abdominal examination to exclude any abdominal masses, and Local examination (Bimanual and Cusco speculum examinations). Complete blood picture, Coagulation profile, Vaginal swab and culture, Viral markers (HBV, HCV, HIV, Chlamydia, gonorrhoea), and Pap smear cytology were also conducted.

At this time, there are no established guidelines from the American College of Obstetricians and Gynaecologists or the Royal College of Obstetricians and Gynaecologists or evidence from randomized clinical trials to base recommendations on diagnosis and treatment of contact bleeding.

Every woman required a thorough examination of the genital tract. A bivalve speculum exam was performed to evaluate the vaginal rugae and cervix. Attention was focused to determine if there are any lacerations or trauma to the vaginal walls. Upon examining the cervix, any obvious gross lesions on the cervix or lesions protruding through the cervical canal were evaluated. Colposcopy was considered when there were any suspicious lesions on the cervix to further evaluate the lesion under high power. In obtaining cultures or clearing mucus from the cervix, we also determined whether gentle palpation alone of the cervix with a swab was able to

recreate bleeding. Considerations were made to break down the bivalve speculum and perform an inspection of the vagina with one blade of the speculum. This allowed for a better visualization of the vaginal rugae as there is less risk of obstruction by the blades of the speculum. This technique was used to evaluate signs of pelvic organ prolapse. A blade was placed along the anterior vaginal wall, while having the patient Valsalva, to evaluate prolapse of the posterior structures.

A bimanual exam was performed to evaluate the size and contour of the uterus as well as the presence of any adnexal masses. During this exam, we delineated whether there is presence of cervical motion tenderness which help with diagnosing an underlying infection. When the patient complained of dyspareunia or pelvic pain, then it was also important to delineate the location of the pain. Finally, when there was concern for underlying malignancy, we evaluated the inguinal lymph nodes to determine if there is any lymphadenopathy.

A rectovaginal exam was performed to determine if there were any masses or nodularities located on the anterior surface of the rectum or extension of disease into the parametrium.

PaP smear Technique:

A metal or plastic speculum was placed in the vagina to examine the cervix. When necessary, lukewarm water was used to lubricate and warm the speculum for patient comfort. In situations in which a lubricant was used, only a small amount was applied to the outer portion of the speculum, with caution to avoid the tip. According to Hologic Inc, maker of ThinPrep pap test, the following lubricants did not contain substances that interfere

with the liquid-based Pap tests: Surgilube, Astroglide, and Crystelle. To ensure an adequate sample was collected, the surface anatomy of the cervix was fully visualized, including the squamous epithelium of the ectocervix, squamocolumnar junction, and the external os. The transformation zone of the cervix was the region where squamous epithelium replaced glandular epithelium in a process called squamous metaplasia.

Because HPV had a predilection for this region, screening was focused on sampling the cells at the transformation zone to adequately detect the presence of dysplasia. Discharge covering the cervix was removed carefully using a large swab, ensuring that the cervix was minimally traumatized. To obtain the specimen, a cervical broom or cervical spatula was applied to the surface of the cervix and turned in a single direction to achieve an adequate sample for cytology, making sure to rotate it at least 360 ° for the spatula and 5 rotations for the broom. When the spatula was used, a cytobrush was additionally needed and inserted into the cervix so that the outermost bristles were still visible at the external os. The brush was then rotated one half turn in a single direction to achieve an adequate cytology sample. The specific protocol for specimen transfer varied depending on the test used. For SurePath, after the cervical broom or cervical spatula and cytobrush were removed from the cervix, they were placed specimen side down into the liquid cytology vial, each removable head was snapped off, and the vial was labeled and sent to pathology. For ThinPrep, the spatula and brush were swirled vigorously in the vial 10 times to release the specimen and then discarded. Similarly, if the broom was used, it was pushed into the bottom of

the vial 10 times and then swirled vigorously and discarded.

When conventional cytology was performed, the specimens were smeared on a glass slide and subsequently sprayed with fixative or placed in 90% alcohol solution.

Although the FDA-approved protocol for the cervical broom does not require use of the cytobrush, some practitioners used the cytobrush following the broom in an attempt to improve the likelihood of obtaining an endocervical component in the sample.

The participants with abnormal cervical smear cytology results and inflammatory lesions were further subjected to colposcopy. Biopsy specimen for histology was collected from the participants with suspicious lesions under colposcopy.

The participants in the 2 groups were matched for age, parity and marital status. The age matching was used in a 5 year age grouping 20-24, 25-29, 30-34, 35-39, 40-44 and 45-49 years. The matching for parity was also grouped into nulliparity, primiparity, multiparity and grand-multiparity

Study outcomes:

Primary outcome was cervical cytological and colposcopic findings in study groups. Secondary outcomes were correlation between cytological and colposcopic findings and women's age and correlation between cytological and colposcopic findings and women's parity.

Sample Size Calculation:

Sample size calculation was done using the comparison of the prevalence of abnormal cervical cytology of women using Copper T 380 intrauterine devices versus long acting depot medroxy-progesterone acetate injectable contraceptive agents. According to

previous publication⁽¹³⁾, we calculated that the minimum proper sample size was 54 women in each group to be able to detect a difference with 80% power at $\alpha = 0.05$ level using Student's t test for independent samples. Sample size will be increased 10% for possible dropout rate, so 120 patients will be enrolled in the study (60 patients in each group). Sample size calculation was done using PS Power and Sample Size Calculations software, version 3.0.11 for MS Windows (William D. Dupont and Walton D., Vanderbilt University, Nashville, Tennessee, USA).

Approval code : MS 46-7-2022

Statistical analysis

Statistical analysis was done by statistical package for social sciences v23 (IBM Inc., Chicago, IL, USA). Data were explored for normality using Kolmogorov-Smirnov and Shapiro-Wilk Test. Quantitative variables were presented as mean, standard deviation (SD) and range and were compared by Independent-samples t-test. Qualitative variables were presented as frequency and percentage (%) and compared using Chi-square test or Fisher's exact test when the expected count in any cell less than 5. Receiver operating characteristic (ROC curve) analysis was used to find out the overall predictivity of parameter in and to find out the best cut-off value with detection of sensitivity and specificity at this cut-off value. A two tailed P value < 0.05 was considered significant.

Results:

There is no statistically significant difference between groups according to Age, Medical Disorders, Occupation, and Parity. Table 1

This table shows statistically significant higher frequency of bleeding, discharge,

and pain in IUD group comparing to 0.004, and 0.003 respectively). injectable group, with p-value ($p < 0.001$,

Table 1: Comparison between IUD group and Injectable group according to Age, Medical Disorders, Occupation, and Parity.

		IUD Group (n=60)	Injectable Group (n=60)	Test value	P-value
Age "years"	22-30 years	10 (16.7%)	18 (30.0%)	4.758	0.190
	>30-40 years	18 (30.0%)	18 (30.0%)		
	>40-50 years	24 (40.0%)	21 (35.0%)		
	>50 years	8 (13.3%)	3 (5.0%)		
	Mean±SD	41.23±9.78	39.73±9.08		
	Range	25-65	22-60		
Medical Disorders	Anemia	6 (10.0%)	1 (1.7%)	2.120	0.223
	DM	6 (10.0%)	12 (20.0%)	2.333	0.127
	HTN	9 (15.0%)	15 (25.0%)	1.859	0.173
	Hypothyroidism	0 (0.0%)	3 (5.0%)	3.000	0.281
	Mastectomy	2 (3.3%)	0 (0.0%)	1.996	0.158
	Prolapse	2 (3.3%)	0 (0.0%)	1.996	0.158
Occupation	House wife	53 (88.3%)	55 (91.7%)	0.380	0.827
	Nurse	4 (6.7%)	3 (5.0%)		
	Teacher	3 (5.0%)	2 (3.3%)		
	Multi para	52 (86.7%)	52 (86.7%)		
Parity	P1	4 (6.7%)	3 (5.0%)	0.254	0.881
	NP	4 (6.7%)	5 (8.3%)		

Data are presented as mean ± SD or frequency (%). DM: Diabetes mellitus, HTN: Hypertension, IUD: intrauterine devices

Table 2: Comparison between IUD group and Injectable group according to Bleeding, Discharge and Pain

	IUD Group (n=60)	Injectable Group (n=60)	Test value	P-value
Bleeding	40 (66.7%)	2 (3.3%)	8.25	<0.001*
Discharge	46 (76.7%)	31 (51.7%)	8.155	0.004*
Pain	28 (46.7%)	6 (10.0%)	6.67	0.003*

Data are presented as frequency (%). * statistically significant as P-value ≤ 0.05 . IUD: intrauterine devices

This table shows statistically significant higher frequency of abnormal of Colposcope in IUD Group comparing to Injectable Group, with p-value ($p = 0.028$). Table 3

In IUD Group; there was 10 women (16.7%) were High grade for colposcope, including 4 women (12.1%) were CIN II, 3 women (9.1%) were SIL high grade, 2 women (6.1%) were CIN III and one woman (3.0%) were Cervical cancer. Also, there was 23 women (38.3%) were Low grade for colposcope, including 5 women (15.2%) were focal atypia and CINI, 2 women (6.1%) were inflammatory, 7

women (21.2%) were SIL- low grade and 9 women (27.3%) were squamous metaplasia. In injectable Group; there was 7 women (11.7%) were High grade for colposcope, including 2 women (9.5%) were CIN II, 3 women (14.3%) were CIN III and 2 women (9.5%) were SIL high grade. Also, there was 14 women (23.3%) were Low grade for colposcope, including 2 women (9.5%) were focal atypia and CINI, one woman (4.8%) were inflammatory, 5 women (23.8%) were SIL- low grade and 6 women (28.6%) were squamous metaplasia.

This table shows statistically significant higher frequency of abnormal of Cytology in IUD Group was 31 women (51.7%) comparing to Injectable Group was 19 women (31.7%), with p-value ($p=0.026$). Table 4

In IUD Group; there was 8 women (13.3%) were High grade for cytology, including 3 women (9.7%) were CIN II, 2 women (6.5%) were CIN III, 2 women (6.5%) were SIL high grade and one women (3.2%) were Cervical Cancer. There was 23 women (38.3%) were low grade for cytology, including 8 women (25.8%) were CINI, 8 women (25.8%) were squamous metaplasia, 5 women (16.1%) were SIL- low grade and 2 women (6.5%) were focal atypia.

In injectable Group; there was 7 women (11.7%) were High grade for cytology, including 3 women (15.8%) were CIN III, 2 women (10.5%) were CIN II and 2

women (10.5%) were SIL high grade. There was 12 women (20%) were low grade for cytology, including 5 women (26.3%) were squamous metaplasia, 4 women (21.1%) were SIL- low grade, 2 women (10.5%) were focal atypia and CINI and one women (5.3%) were inflammatory. Table 4

Table 4 showed that from a total 120 cases, Colposcope performed there were 49 cases were abnormal from 50 cases abnormal biopsy, while there were 65 cases normal colposcope from 70 cases normal cytology, with p-value ($p<0.001$).

Discrimination between Colposcope vs. Biopsy: Receiver operating characteristics (ROC) curve was performed for colposcope and demonstrated an area under the curve of 0.954 with P value <0.001 , with sensitivity 98%, specificity 92.9%, PPV 90.7% and NPV 98.5%. Figure 1.

Table 3: Comparison between IUD group and Injectable group according to Colposcope

Colposcope	IUD Group (n=60)	Injectable Group (n=60)	Test value	P-value
Abnormal	33 (55.0%)	21 (35.0%)	4.848	0.028*
Normal	27 (45.0%)	39 (65.0%)		

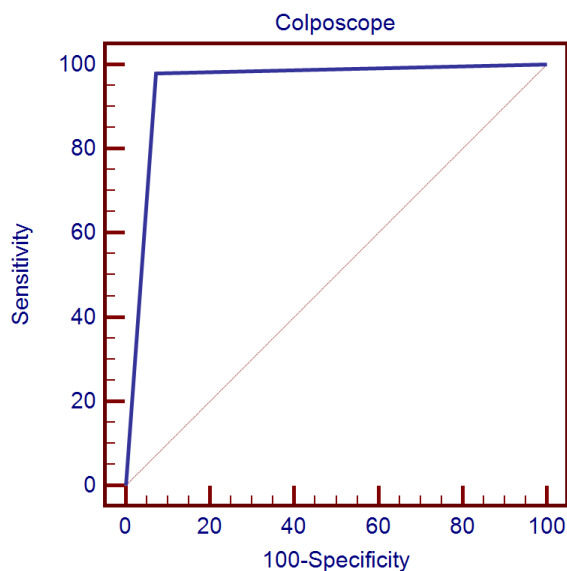
Data are presented as frequency (%). * statistically significant as P-value ≤ 0.05 . IUD: intrauterine devices

Table 4: Comparison between IUD group and Injectable group according to Cytology and Colposcope

Cytology	IUD Group (n=60)		Injectable Group (n=60)		Test value	P-value
Abnormal	31 (51.7%)		19 (31.7%)		4.937	0.026*
Normal	29 (48.3%)		41 (68.3%)			
<u>Types of abnormalities</u>						
High grade cytology	8 (13.3%)		7 (11.7%)		2.33	0.123
CIN II	3 (9.7%)		3 (15.8%)			
CIN III	2 (6.5%)		2 (10.5%)			
SLN	2 (6.5%)		2 (10.5%)			
Cervical cancer	1 (3.2%)		0 (0.0%)			
Low grade cytology	23 (38.3%)		12 (20%)		4.54	0.087
CIN I	8 (25.8%)		1 (5.3%)			
Squamous metaplasia	8 (25.8%)		5 (26.3%)			
SIL low grade	5 (16.1%)		4 (21.1%)			
Focal atypia	2 (6.5%)		1 (5.3%)			
Inflammatory	0		1 (5.3%)			

Colposcope	Cytology				Total		Chi-square test	
	Abnormal		Normal					
	No.	%	No.	%	No.	%	x ²	p-value
Abnormal	49	40.8%	5	4.2%	54	45.0%	104.762	<0.001**
Normal	1	0.8%	65	54.2%	66	55.0%		
Total	50	41.7%	70	58.3%	120	100.0%		

Data are presented as frequency (%). * statistically significant as P-value ≤ 0.05 . IUD: intrauterine devices, CIN: cervical intra-epithelial neoplasia, SLN: Sentinel lymph node Data are presented as frequency (%). * statistically significant as P-value ≤ 0.05 .

**Figure 1:** Receiver-operating characteristic (ROC) curve for screening tests in detecting Cervical Neoplasia

Discussion

Papanicolaou screening is the standard of care for the detection of abnormal cervical cells ⁽¹⁴⁾.

Early detection and treatment of cervical neoplasia depends on the accurate interpretation of the cytologic sample ⁽¹⁵⁾.

Diagnosis of dysplasia is made by histology interpretation to confirm the results of cytology screening ⁽¹⁶⁾.

Cervical cells are susceptible to change as a result of hormonal exposure, and this has the potential to affect cytologic interpretation ⁽¹⁷⁾.

Consequently, this study was conducted and aimed to assess cervical cytological and colposcopic findings in cases associated with prolonged use of Copper T 380 intrauterine devices versus long acting depot medroxy-progesterone acetate injectable contraceptive agents.

This case control study was conducted at Obstetrical and Gynecological Department Benha University Hospitals "Family Planning Clinic and Cervical Cancer Screening Unit" from July 2022 until January 2024.

During this study, 120 women were enrolled, after consenting each of them and divided into two equal groups; IUD and hormonal injectable groups.

To the best of our knowledge, there are no studies in literature assessing our study objectives.

Most of studies that disagreed with our results were due to several causes as different study methodology, outcomes, sample size and different medical conditions of studied cases at time of enrollment.

Our study revealed that Colposcope was an accurate method for assessment of women with suspected cervical lesion using long term contraceptive method either intrauterine device or hormonal injections with sensitivity 98%, specificity 92.9%, PPV 90.7% and NPV 98.5% respectively.

Long term intrauterine device users were proved to have higher frequency of bleeding 40 (66.7%) vs. 29 (48.3%), discharge 46 (76.7%) vs. 31 (51.7%), pain 28 (46.7%) vs. 16 (26.7%) and abnormal colposcopic findings 33 (55.0%) vs. 21 (35.0%) and cervical biopsies 31 (51.7%) vs. 19 (31.7%) compared with long term hormonal injections users.

On the other hand, no differences were noted between study groups regarding maternal age, associated medical disorders, occupation and parity.

Prevalence of abnormal cervical cytology data analysis:

The prevalence of abnormal cervical cytology of 10.3% (16/156) reported among the IUD users was similar to 7.3% (25/343) reported among IUD users in Turkey ⁽¹⁸⁾.

More so, the prevalence of cervical neoplasia of 5.8 % (9/156) reported among the IUD users was similar to 4% prevalence which was initially reported in Malaysia ⁽¹⁹⁾.

The overall prevalence of cervical neoplasia of 4.8% (15/312) was slightly higher than 3.06% previously reported in Egypt as reported by Abd El All et al. ⁽²⁰⁾.

However, it was similar to 4.8% reported in Zaria but less than 9.1% reported in Ibadan as reported by Adekunle OO and Samaila MO (21) and Omigbodun et al. ⁽²²⁾.

As was previously reported in India by Dimkpa et al.⁽²³⁾, none of the cases among IUD users in this study had malignant transformation. The absence of statistically significant difference between the participants using IUD and non-users of modern contraception is supported by the previous reports in USA by Lassise et al.⁽²⁴⁾. However, this was contrary to the reports in India by Dimkpa et al.⁽²³⁾.

The non-existence of statistical significant difference on cervical inflammatory changes between the women using IUD and non-users of modern contraception was contrary to the report in Egypt by Abd El All et al.⁽²⁰⁾ which showed that cervical inflammatory changes were more associated with women who were using IUD than others.

Long term intrauterine device users data analysis:

In the same line with current study, Farg et al.⁽²⁵⁾ reported that it is crucial to make sure that cervical cancer screening and contraception function closely together in order to give women the best treatment possible. This cross-sectional study was conducted on 200 monogamous individuals with IUCD who have been free of STIs for three to five years made up the study group (group 1). On the other hand, and control group (Group 2) included 200 patients without a previous anamnesis of any contraception method. Between the subjects in groups (1) and (2), the quantity of aberrant cervical cytology differed in a statistically significant way. When compared to group 1, group 2 was shown to have a higher incidence of inflammatory and infectious disorders, but group 1 had a higher incidence of abnormal ectopic changes.

Against our study, in the study by Ajah et al.⁽¹³⁾ 156 women were split into each of

the 2 groups. The average participant age, which was 37.56 7.87 years, indicated that they ranged in age from 20 to 49 years. The socio-demographic characteristics of participants using IUDs and those not using contemporary contraception are compared, and the participants' mean duration of IUD use was 42.32 11.32 months. On these variables, there was no statistically significant difference between the 2 participant groups.

Our findings were uncorroborated by a research by Loopik et al.⁽⁷⁾, which found that 91.4% of women did not acquire any cervical abnormalities during follow-up while 6.6% and 1.9%, respectively, did so. 95.6% of high-grade lesions were histologically confirmed, and among all included women, 5547 (0.79%), 6705 (0.96%), and 559 (0.08%) developed histologically confirmed CIN (cervical intraepithelial neoplasia) 2, CIN3, and cervical cancer, respectively.

Against our study, according to Kaplan⁽²⁶⁾, women using Cu-IUDs experienced a decrease in the frequency of CIN II+ lesions while COC (Combination Oral Contraceptive) users experienced an increase ($p=0.038$).

In contrast, the study by Aba et al.⁽²⁷⁾ indicated that mild ectopy detection rates in Groups 1 and 2 were 25.8% and 19.18%, moderate ectopy detection rates were 25.8% and 28.6%, and severe ectopy detection rates were 11.38% and 23.8 percent, respectively. The rates of ectopy before colposcopy did not differ statistically significantly between the two groups. F. Patients who used an IUD had a significantly decreased mosaic rate ($2 = 3.74, p0.05$).

There was no correlation between copper IUDs and cervical dysplasia or cancer,

according to Hardeman and Weiss' analysis¹⁰ of the data.

With the levonorgestrel IUD, there was a marginally elevated risk for CIN 2, but not CIN 3. The 52 mg levonorgestrel IUD was the only one included in this study due to the timing of the research. The Lekovich et al. ⁽²⁸⁾ hypothesized that residual confounding may be to blame for this shaky connection. As a result, they conducted second research comparing IUD users to those who used hormonal contraceptives (while excluding those who were not taking contraception), however, they were unable to find a connection between IUD use and CIN 2. This lends credence to the idea that sexual activity that results in HPV infection could be a complicating factor. Additionally, a very weak connection that is unlikely to have clinical significance is indicated by a relative risk of 1.18. It is unknown how levonorgestrel might affect the cervix's capacity to rid itself of HPV infection. Some believe that the anti-inflammatory effects of levonorgestrel may prevent HPV removal.

In the Cu IUD cohort there were 77 cervical neoplasms (0.9%), whereas in the LNG-IUS cohort there were 37 (1.5%), according to Spotnitz et al. ⁽²⁹⁾.

Ions of copper, which are released by copper IUDs, are thought to raise prostaglandin levels in uterine and tubal fluids. LNG-IUSs, on the other hand, inhibit cervical and uterine immunity by reducing prostaglandin synthesis. According to a retrospective investigation by Cortessis et al. (30), users of LNG-IUS may clear HPV infections more slowly and be more prone to infection than users of Cu IUDs because of these variations in immunomodulation.

According to Skorstengaard et al. ⁽³¹⁾, HIUD and CIUD users had a lower risk of CIN2 and CIN3+ than OC users over the course of the subsequent 5 years among women with normal cytology at the time of initiating contraceptive usage. HIUD users were more likely than CIUD or OC users to have a normal histology or a low grade CIN1 diagnosis. This might be explained by diagnostic monitoring of irregular bleeding after HIUD insertion. This was only observed in women who had used HIUDs for a brief period of time—between 1-2 years.

Dimkpa et al. ⁽²³⁾ reported that none of the cases among IUD users in our study developed malignant transformation, contrary to what was previously described in India.

The results of earlier studies, Pillay et al. ⁽³²⁾ conducted in the USA, Israel, New Zealand, and other centers corroborate the lack of a statistically significant difference between participants using IUDs and those who did not use contemporary contraception in this study.

Long term hormonal injections users data analysis:

McFarlane-Anderson et al. ⁽³³⁾ conducted a study to determine whether use of hormonal contraceptives is associated with cervical dysplasia and cancer in a population where there is widespread use of hormonal contraception. Against us, they reported that hormonal contraception did confer some risk of dysplasia and women using HC should therefore be encouraged to do regular Pap smear screening. Depo-provera use (with age and number of sexual partners as covariates) was associated with disease and severity of disease. With parity and alcohol added to this model, depo-provera use retained significance. Exposure to HC > 4 years

conferred more risk for disease and severity of disease.

Several studies have contributed to the present understanding of the relationship between the use of HC and disease. The International Agency for Research on Cancer (IARC) Moreno et al. ⁽³⁴⁾, pooled data from eight studies of invasive cancer and two of carcinoma in situ in HPV positive cases and found that risk increased significantly with parity. Women who used HC for less than 5 years were not at increased risk but risk became apparent after 10 years.

Results from the WHO collaborative Study of Neoplasia and Steroid Contraceptives showed that there was a slight risk for ever-users that increased with duration of > 4 years as reported by Thomas et al. ⁽³⁵⁾.

Similar findings were reported by the Oxford Family Planning Association contraceptive study. Based on the most recent evaluation of several studies, the IARC has concluded that HC can be classified as carcinogenic to the cervix as well as to the breast ⁽³⁶⁾.

Finally, Collins ⁽³⁷⁾ assessed the effect of progesterone only contraception on the accuracy of cervical cytologic interpretation. They reported that subjects in this study who used either the progesterone IUD or injection had no difference in association of their cytology to histology findings compared to women who had no progesterone exposure. What can be derived from the study are a basis for comparing varied progesterone delivery systems, as well as format for repetition of a similar study in a multi-center, multi-site study. There are several other forms of progesterone (implant and oral progesterone formulations) which were not included in this study which may

affect the association between cytology and histology results. Further investigation is warranted.

The strength points of this study are that it was case control study design and having no patients who were lost during the study period.

It was the first study in Benha University Hospitals to assess cervical cytological and colposcopic findings in cases associated with prolonged use of Copper T 380 intrauterine devices versus long acting depot medroxy-progesterone acetate injectable contraceptive agents.

Every effort was made to ascertain that all follow-up data were documented, and only complete information was included in data analysis.

All clinical assessment and evaluation of study outcomes were done by the same team.

The limitations of the study are worthy of mention, this study was a hospital-based study, hence there was a limited number of cases with relatively smaller sample size relative to study outcomes, not being a multicentric study and this represents a significant risk of publication bias and did not represent a particular community.

Conclusion:

Colposcope was an accurate method for assessment of women with suspected cervical lesion using long term contraceptive method either intrauterine device or hormonal injections. Long term intrauterine device users were proved to have higher frequency of bleeding, discharge, pain and abnormal colposcopic findings and cervical biopsies compared with long term hormonal injections users.

References:

- Perkins RB, Wentzensen N, Guido RS, Schiffman M. Cervical Cancer Screening: A Review. *Jama*. 2023;330:547-58.
- Rezende MT, Bianchi AGC, Carneiro CM. Cervical cancer: Automation of Pap test screening. *Diagn Cytopathol*. 2021;49:559-74.
- Lew M, Wilbur DC, Pantanowitz L. Computational Cytology: Lessons Learned from Pap Test Computer-Assisted Screening. *Acta Cytol*. 2021;65:286-300.
- Chen Y, Huang Y, Deng X. External cervical resorption-a review of pathogenesis and potential predisposing factors. *Int J Oral Sci*. 2021;13:19.
- Kaitz M, Mankuta D, Mankuta L. Long-acting reversible contraception: A route to reproductive justice or injustice. *Infant Ment Health J*. 2019;40:673-89.
- Durante JC, Sims J, Jarin J, Gold MA, Messiah SE, Francis JKR. Long-Acting Reversible Contraception for Adolescents: A Review of Practices to Support Better Communication, Counseling, and Adherence. *Adolesc Health Med Ther*. 2023;14:97-114.
- Loopik DL, Int'Hout J, Melchers WJG, Massuger L, Bekkers RLM, Siebers AG. Oral contraceptive and intrauterine device use and the risk of cervical intraepithelial neoplasia grade III or worse: a population-based study. *Eur J Cancer*. 2020;124:102-9.
- Sammaritano LR. Which Hormones and Contraception for Women with APS? Exogenous Hormone Use in Women with APS. *Curr Rheumatol Rep*. 2021;23:44.
- Kumar N, Gupta R, Gupta S. Glandular cell abnormalities in cervical cytology: What has changed in this decade and what has not? *Eur J Obstet Gynecol Reprod Biol*. 2019;240:68-73.
- Nagy B, Szekeres-Barthó J, Kovács GL, Sulyok E, Farkas B, Várnagy Á, et al. Key to Life: Physiological Role and Clinical Implications of Progesterone. *Int J Mol Sci*. 2021;22.
- Cardoso PG, Resende-de-Oliveira R, Rocha E. Combined effects of increased temperature and levonorgestrel exposure on zebrafish female liver, using stereology and immunohistochemistry against catalase, CYP1A, HSP90 and vitellogenin. *Environ Pollut*. 2019;252:1059-67.
- Katz AP, Civantos FJ, Sargi Z, Leibowitz JM, Nicolli EA, Weed D, et al. False-positive reverse transcriptase polymerase chain reaction screening for SARS-CoV-2 in the setting of urgent head and neck surgery and otolaryngologic emergencies during the pandemic: Clinical implications. *Head Neck*. 2020;42:1621-8.
- Ajah LO, Chigbu CO, Ozumba BC, Oguanuo TC, Ezeonu PO. Association of Intrauterine Device (IUD) and Cervical Neoplasia - A Study in a Poor Nigerian Population. *J Clin Diagn Res*. 2016;10:Qc05-8.
- Thrall MJ. Automated screening of Papanicolaou tests: A review of the literature. *Diagn Cytopathol*. 2019;47:20-7.
- Schulmeyer CE, Stübs F, Gass P, Renner SK, Hartmann A, Strehl J, et al. Correlation between referral cytology and in-house colposcopy-guided cytology for detecting early cervical neoplasia. *Arch Gynecol Obstet*. 2020;301:263-71.
- Odell E, Kujan O, Warnakulasuriya S, Sloan P. Oral epithelial dysplasia: Recognition, grading and clinical significance. *Oral Dis*. 2021;27:1947-76.
- Draganova-Tacheva R, HooKim K. Normal and Benign Cervical Cytology. In: Xu H, Qian X, Wang H, editors. *Practical Cytopathology : Frequently Asked Questions*. Cham: Springer International Publishing; 2020. p. 43-57.
- Ajah LO, Chigbu CO, Ozumba BC, Oguanuo TC, Ezeonu PO. Is there any association between hormonal contraceptives and cervical neoplasia in a poor Nigerian setting? *Oncotargets Ther*. 2015;8:1887-92.
- Ganacharya S, Bhattoa HP, Batár I. Pre-malignant and malignant cervical pathologies among inert and copper-bearing intrauterine contraceptive device users: a 10-year follow-up study. *Eur J Contracept Reprod Health Care*. 2006;11:89-97.
- el-All HS, Refaat A, Dandash K. Prevalence of cervical neoplastic lesions and Human Papilloma Virus infection in Egypt: National Cervical Cancer Screening Project. *Infect Agent Cancer*. 2007;2:12.
- Adekunle OO, Samaila MO. Prevalence of cervical intraepithelial neoplasia in Zaria. *Ann Afr Med*. 2010;9:194.
- Omigbodun AO. Management of cervical intraepithelial neoplasia where colposcopy is not available. *Cent Afr J Med*. 1991;37:7-11.
- Dimkpa OJ, Okwudili OE, Wamadi NE. Intrauterine contraceptive device use in Port Harcourt, Southern Nigeria: a retrospective analysis. *J Adv Med Med Res*. 2014;4:3132-9.
- Lassise DL, Savitz DA, Hamman RF, Barón AE, Brinton LA, Levines RS. Invasive cervical cancer and intrauterine device use. *Int J Epidemiol*. 1991;20:865-70.
- Farg EM, Ali SA-A, Mostafa A-EA-E. Cervical Cytologic and Colposcopic Changes in Cases Using Intrauterine Devices for Along Time. *Al-Azhar Intern Med J*. 2022;3:123-9.
- KAPLAN S. Is there a Relationship between Combined Oral Contraceptive Use and Intrauterine Device Use with Abnormal Smear

- Results and Cervical Atypia? J Clin Diagn Res. 2020;14.
27. Aba YA, Şık BA, Şentürk M, Kumbasar S, Sümer E, Dülger Ö. Cervical cytologic and colposcopic changes in cases using IUDs for a long time. *IJHSRP*. 2017;2:1-9.
 28. Lekovich JP, Amrane S, Pangasa M, Pereira N, Frey MK, Varrey A, et al. Comparison of human papillomavirus infection and cervical cytology in women using copper-containing and levonorgestrel-containing intrauterine devices. *Obstet Gynecol*. 2015;125:1101-5.
 29. Spotnitz ME, Natarajan K, Ryan PB, Westhoff CL. Relative Risk of Cervical Neoplasms Among Copper and Levonorgestrel-Releasing Intrauterine System Users. *Obstet Gynecol*. 2020;135:319-27.
 30. Cortessis VK, Barrett M, Brown Wade N, Enebish T, Perrigo JL, Tobin J, et al. Intrauterine Device Use and Cervical Cancer Risk: A Systematic Review and Meta-analysis. *Obstet Gynecol*. 2017;130:1226-36.
 31. Skorstengaard M, Lynge E, Napolitano G, Blaakær J, Bor P. Risk of precancerous cervical lesions in women using a hormone-containing intrauterine device and other contraceptives: a register-based cohort study from Denmark. *Hum Reprod*. 2021;36:1796-807.
 32. Pillay B, Gregory AR, Subbiah M. Cytopathologic changes associated with intrauterine contraceptive devices. A review of cervico-vaginal smears in 350 women. *Med J Malaysia*. 1994;49:74-7.
 33. McFarlane-Anderson N, Bazuaye PE, Jackson MD, Smikle M, Fletcher HM. Cervical dysplasia and cancer and the use of hormonal contraceptives in Jamaican women. *BMC Womens Health*. 2008;8:9.
 34. Moreno V, Bosch FX, Muñoz N, Meijer CJ, Shah KV, Walboomers JM, et al. Effect of oral contraceptives on risk of cervical cancer in women with human papillomavirus infection: the IARC multicentric case-control study. *Lancet*. 2002;359:1085-92.
 35. Thomas DB, Ray RM. Oral contraceptives and invasive adenocarcinomas and adenosquamous carcinomas of the uterine cervix. The World Health Organization Collaborative Study of Neoplasia and Steroid Contraceptives. *Am J Epidemiol*. 1996;144:281-9.
 36. Wang R, Pan W, Jin L, Huang W, Li Y, Wu D, et al. Human papillomavirus vaccine against cervical cancer: Opportunity and challenge. *Cancer Lett*. 2020;471:88-102.
 37. Collins MR. The effect of progesterone only contraception on the accuracy of cervical cytologic interpretation: The University of Tennessee Health Science Center; 2012.

To cite this article: Tamer M. Assar, Ali Q. Algazzar, Omar S. Ward, Mohamed A. Algazzar. Cervical Cytological and Colposcopic Findings in Cases Associated with Prolonged Use of Intrauterine Devices versus Long Acting Injectable Contraceptive Agents. *BMFJ* 2025; 42(5):67-80.