

Dorsal Bridge Plating versus Volar Locking Plate Fixation for Management of Unstable Distal Radius Fractures**El Sayed Said^a, Emad Hamdy^a, Baher Mohamed Safy^{a*}, Hamdy Tammam^a**^aDepartment of Orthopedic Surgery, Faculty of Medicine, South Valley University, Qena, Egypt.**Abstract**

Background: The use of volar locked plates (VLP) has become standard treatment of the majority of distal radius fractures. Nevertheless, adequate fixation for high energy comminuted fractures still a major challenge. Severely comminuted articular fractures are technically challenging where dorsal bridge plating (DBP) can be used as an improved fixation technique.

Objectives: The main objective of this prospective study is to compare the radiological and functional outcomes of DBP and VLP in comminuted distal radial fractures.

Patients and methods: Between 2022 and 2023, 19 patients with displaced, unstable fractures of the distal radius were randomized to receive either DBP or VLP.

Results: The mean age of DBP and VLP group was 38.2 and 39.1 years, respectively. The mean time to union was 2.6 ± 0.3 and 2.3 ± 0.2 months in the DBP and VLP, respectively ($P > .05$). Both fixation techniques demonstrated similar radial inclination, and radial height at last follow-up ($P > .05$). However, the volar tilt was significantly better in the VLP group compared to the DBP group ($P = .001$). No statistically significant difference was observed between groups in grip strength and wrist ranges of motion at final follow-up ($P > .05$).

Conclusion: This study showed better radiographic results of VLP compared to DBP. However, no technique demonstrated functional superiority at last follow-up.

Keywords: Distal radius; Dorsal bridge plate; Dorsal distraction plating; Volar locked plate.

DOI: 10.21608/SVUIJM.2023.233432.1678

***Correspondence:** bahermohamed2019@gmail.com

Received: 6 August, 2023.

Revised: 9 September, 2023.

Accepted: 10 September, 2023.

Published: 23 April, 2025

Cite this article as El Sayed Said, Emad Hamdy, Baher Mohamed Safy, Hamdy Tammam. (2025). Dorsal Bridge Plating versus Volar Locking Plate Fixation for Management of Unstable Distal Radius Fractures. *SVU-International Journal of Medical Sciences*. Vol.8, Issue 1, pp: 866-873.

Introduction

Distal radius fracture is still one of most frequent type of injuries presenting to emergency departments. Distal radius fractures came in third position following fractures of the vertebrae and hips as regarding the most common injuries in osteoporotic bones (Rozenental et al., 2002) with age prevalence in young age peoples at 2nd - 3rd decades also may occur in the 5th - 6th decades following trivial trauma mainly in postmenopausal women (Margaliot et al., 2005).

Fall on the ground still the most common cause of this injury in elderly (Nguyen et al., 2001) while high energy trauma like fall from height and motor car accident is the main cause in younger males.

There is a clear evidence suggesting increasing morbidity and mortality rate following distal radius fracture, particularly in old age males akin to osteoporotic fractures of hip (Rozenental et al., 2002). Because there are various methods for fixing distal radius fractures, surgical management differs. Anatomic stabilization and reduction are the objectives of fixation since they have been found to increase the likelihood of functional recovery. (Chen and Jupiter, 2007). The usage of volar locked plate has been become the standard for the management of most of distal radial fractures. Severely comminuted articular fractures are technically challenging situation and in these circumstances, the dorsal distraction plating, also known as the bridging plating technique, can be used as a better fixation method because it enables comminuted articular fragments to reduce under effect of ligamentotaxis and acts as a buttress for the distal radius's dorsal cortex (Mignemi et al., 2013).

The present study aims to compare the results of our functional & radiological outcomes of distal radius fractures fixation by dorsal bridging plate versus volar locked plate.

Patients and methods

Over a period of one year, from July 2022 till July 2023, Nineteen patients with fractures of unstable distal radius requiring operative management were managed either by Dorsal Bridge Plate (DBP group) or Volar Locked Plate (VLP group). Exclusion criteria included stable noncomminuted distal radius fractures, cases with ipsilateral injuries, and skeletally immature patients. The institution review board approved (Approval code:SVU-MED-ORT017-1-22-10-474) this study and all patients signed informed consent.

A complete history and full physical examination were performed including the mechanism of trauma, neurovascular examination, compartment syndrome exclusion and skin condition evaluation. Standard radiographs were obtained at the time of presentation including antero-posterior (AP), lateral view of injured wrist to classify the fracture according to AO distal radius fracture classification. In addition, Comparative views of normal side were obtained to assess reduction, then Ct scan of injured wrist was done for all of our cases for to delineate fracture pattern in addition to accurate preoperative planning

A random-number generator was used to randomly assign cases to one of the two techniques at the time of the patient's presentation..

Surgical Technique

In both groups, after general anesthesia, the patient is placed supine with the injured limb placed on a radiolucent table with use of a tourniquet.

In the DBP group we used 3.5-mm DCP (Orthomed) or 3.5-mm reconstruction plate (Orthomed) with plate length ranging from 12-14 holes

In the DBP group a distal incision was done in the web space between 2nd and 3rd metacarpal for distal fixation of the plate to 2nd or 3rd metacarpal according to surgeon preference then a proximal incision was placed in bare area of dorsal

aspect of radial diaphysis for proximal plate fixation. A freer elevator is used to elevate the tendons and muscle bellies of the second or third compartment for subsequent plate placement along the index or long finger, and then the bridge plate was placed in a retrograde fashion beneath the selected compartment, with attention paid to confirm that plate placement is volar to the extensor tendons. Fixation began with a cortical screw in the

distal aspect of the selected metacarpal (**Fig.1**) followed by fracture reduction via ligamentotaxis using longitudinal traction, pronation and palmar translation under fluoroscopic confirmation followed by fixation completion distally and proximally (**Richard et al., 2012**). In VLB group, Open reduction, and fracture fixation by locked anatomical plate under fluoroscopic guide through the standard volar Henry approach (**Fig. 2**).

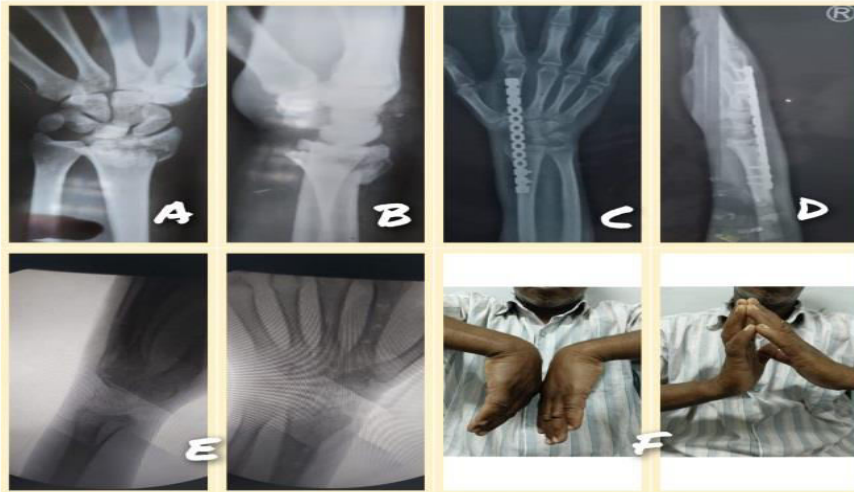

Fig.1. 40 years old male presented with unstable comminuted fracture distal left radius after motor car accident (A,B) was managed by Dorsal Bridge Plate (C,D) with good radiological (E after implant removal) and Functional (F) outcomes at 6 months follow up.

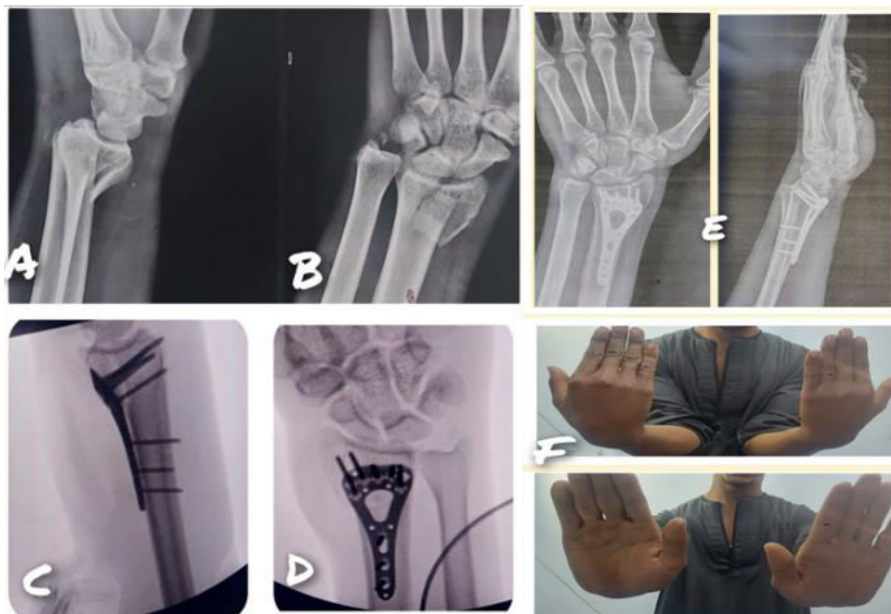


Fig.2. A 22-year-old male presented with unstable comminuted fracture distal left radius after fall on outstretched hand (A,B) was managed by Volar Locked Plate (C,D) with good radiological (E) and Functional (F) outcomes at 6 months follow up.

In all cases no external support was used unless in cases of osteoporotic bone with weak fixation purchase and patients were discharged 2-3 days postoperative and encouraged to start passive and active movement of their fingers and wrist (only in Patients treated by VLP). The patients were followed up at two weeks for suture removal, six weeks then at three months then at six months and 1 year. In DBP cases, plate was removed after fracture union followed by wrist physiotherapy (Ruch and Papadonikolakis, 2006).

Radiological Evaluation

Standard posteroanterior and lateral views of our patients wrist were obtained with wrist was kept in zero position, i.e., shoulder abducted at 90°, elbow flexed at

90°, and the forearm and wrist were held in neutral position. Inclination angle (described as the angle between the long axis of the shaft of the radius and a line connecting the tip of the radial styloid with the ulnar corner) and radial height (axial length between two parallel lines , 1st one is perpendicular to axis of the shaft of the radius passing along ulnar corner of articular surface & 2nd one passing along the tip of radial styloid) were calculated on the PA view, but the volar tilt of the distal radius from the neutral plane was calculated on the lateral vie (described as angle between line perpendicular to longitudinal axis of radius and tangent line passing through volar and dorsal rim of articular surface) (Fig.3).

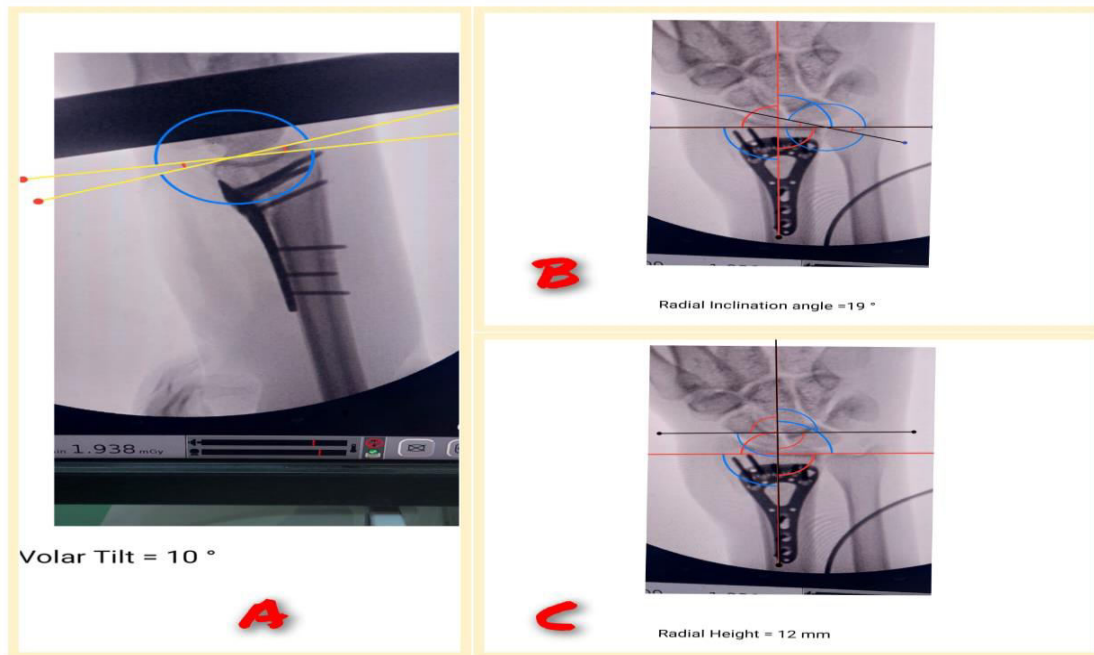


Fig.3. Illustration of radiological parameters (A) Volar tilt angle (B) Radial inclination angle (C) Radial Height

Clinical Evaluation

The wrist's active & passive ranges of motion, including extension, flexion, supination, pronation, were all clinically assessed on each patient. This was done using a hand-held goniometer. Using a Jamar dynamometer , the grip's strength was also measured and expressed as a % when compared to the side that wasn't compromised. Throughout the subsequent

follow-up period, patients were monitored for surgical complications..

Statistical analysis

Using the Shapiro-Wilk Test, it was discovered that the data had a normal distribution. Means and standard deviation have been used to present quantitative factors, whereas frequencies and percentages were utilized to describe qualitative variables. The independent t-

test was used to compare numerical variables to categorical data, and the Chi-square test was used to compare them to categorical variables. Statistical significance was defined as P value < 0.05 .

Results

Our mean follow-up of this study has been 8 ± 1.2 months. (**Table.1**) summarizes the basic demographic data of enrolled patients. No statistical difference has been found between the two groups regarding age, gender, affected side, and AO fracture type.

Table 1. Demographic Data (N = 19)

	DBP	VLP	<i>P</i> value
Age, years *	38 ± 5 Range (35-50)	39 ± 4 Range (33-49)	.502 ^a
Male **	5 (50)	4 (44)	.809 ^b
Dominant Side **	4 (40)	3 (33)	.764 ^b
AO Type **			.622 ^b
C1	6 (60)	6 (67)	
C2	3 (30)	3 (33)	
C3	1 (10)	0 (0)	

* Data presented as mean standard deviation, ** Data presented as frequency and percentage, ^a Independent sample t test; ^b Chi-square test.

Radiological results

The mean time to union was 2.6 ± 0.3 months and 2.3 ± 0.2 months in the DBP and VLP, respectively. No statistically significant difference was detected between two groups in terms of union time ($P = .214$).

As shown in (**Table.2**), both groups showed no statistically significant

difference in radial inclination and radial height between the affected and contralateral sides ($P > .05$). On other hand, a statistically significant difference in volar tilt was found between affected and contralateral sides in the DPB group ($P = .001$).

Table 2. Radiographic Outcomes

Variables	DBP	VLP
RI, deg		
• Affected	19 ± 3	18 ± 2
• Contralateral	21 ± 2	20 ± 4
• <i>P</i> value	.271	.365
RH, mm		
• Affected	7.5 ± 4	7.3 ± 2
• Contralateral	8.2 ± 2	8.1 ± 3
• <i>P</i> value	.129	.183
VT, deg		
Affected	2.7 ± 3	6.3 ± 3
Contralateral	7.4 ± 4	7.8 ± 2
<i>P</i> value	.001	.066

RI: radial inclination, RH: radial height, VT: volar tilt. * Independent sample t test

(Fig.3) compares the radiographic measurements in the DPB and VLP groups. Both fixation techniques demonstrated similar radial inclination,

and radial height at last follow-up ($P > .05$). However, the volar tilt has been significantly better in the VLP group compared to the DBP group ($P = .001$).

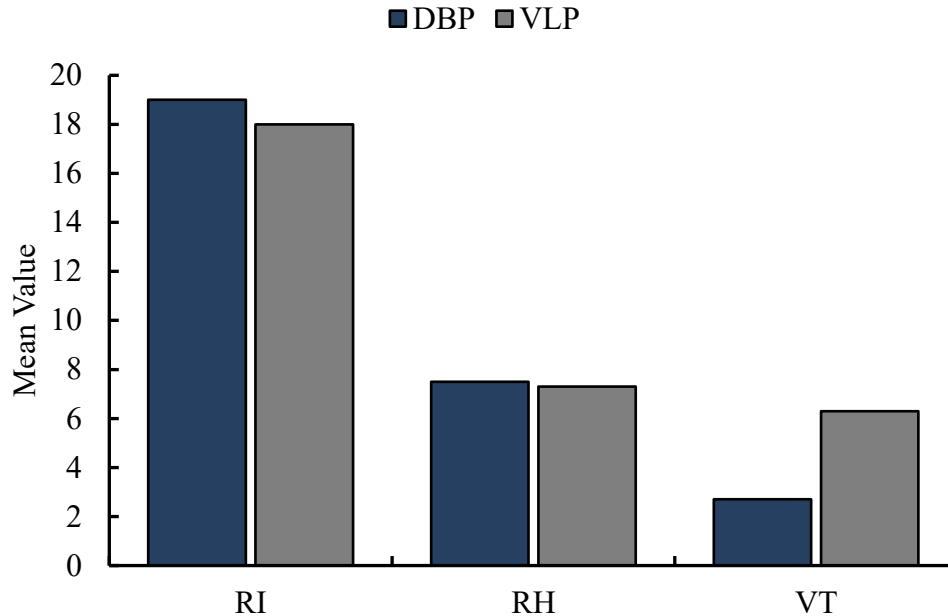


Fig.3. Radiologic measurements

Functional Results

(Table.3) compares the grip strength, flexion, extension, pronation, and supination of the DBP and VLP groups at the last follow-up. At the final follow-up, there was no statistically significant difference in strength of grip or wrist active & passive range of motion between the two groups ($P > .05$).

Complications

Two patients (10%) in the VLP group had superficial surgical site infections that were treated with antibiotics and daily dressings. In the DBP group, one (10%) patient had complex regional pain syndrome, and one (10%) demonstrated radial collapse at final follow-up with no significant impact on wrist function (Table.3).

Table 3. Functional Outcomes

	DBP	VLP	<i>P</i> value
Grip strength	80 ± 10	82 ± 9	.329
Flexion	48 ± 5	50 ± 6	.145
Extension	54 ± 7	55 ± 8	.159
Pronation	68 ± 4	72 ± 5	.495
Supination	64 ± 8	66 ± 7	.491

Data presented as mean standard deviation * Independent sample t test

Discussion

In addition to their prevalence rising globally, distal radius fractures are now regarded as the most frequent long bone fractures. There are many modes of trauma, although fall on outstretched hand remains the most frequent mode of trauma. Intra-articular fractures treatment remains challenging with the main goal of fixation is to achieve anatomical reduction and good stability in addition to restore radial height inclination and Volar tilt since evidence suggests that doing so will increase the likelihood of functional recovery (Chen and Jupiter, 2007).

In this study, there was no significant statistical difference between dorsal bridge plate and volar locked plate in both radiological and functional outcome at the final follow up of patients with comminuted unstable distal radius fractures which is similar to what was reported by different studies that differences between fixation types may be short-lived and that long-term outcomes (Egol et al., 2008; Wei et al., 2009).

In a systematic review of the literature (Beeres et al., 2022), A total of 353 patients with 357 distal radius fractures had been enrolled in two prospective and eight retrospective cohort studies. They reached their conclusion that DBP is a safe procedure with a low complication rate and satisfactory functional and radiological results for the treatment of challenging distal radius fractures. The benefits of this method include temporary wrist immobilization as well as avoiding the drawbacks of external fixators. (Dodds et al., 2013; Beeres et al., 2022). Another study was conducted on 25 patients having comminuted distal radius fracture. They found that they have an average ROM after 6 months follow up to be 45.8 degrees of flexion, 42.4 degrees of extension, 68.6 degrees of supination & 76.4 degrees of pronation.

On the other hand, we found that (Marcheix et al., 2010) performed a randomized control study on patients with

distal radius fracture fixed by volar plating or percutaneous kirschner wires, he found that the average ROM in cases treated by volar plate after 26 weeks to be of 53 degree flexion, 50 degree extension, 81 degree supination & 77 degree pronation which is comparable to the results of DBP (Margaliot et al., 2005; Dzaja et al., 2013) performed another retrospective study on fracture distal radius AO type A & C1 and compared the functional outcomes of treatment of volar plate versus k wires fixation & found that Range of motion after 1 year follow up about 60-degree flexion, 58 degrees of extension, 66-degree supination & 74 degrees for pronation for cases treated by volar locking plate (Margaliot et al., 2005; Williksen et al., 2013) performed a randomized controlled trial on about 104 patients with unstable distal radius fractures who are treated with a volar locked plating or External fixators & k wires, They found that the mean ROM at 24 weeks follow-up to be the 52 degrees of flexion, 55 degrees of extension, 86 degrees of supination & 87 degrees of pronation as regarding cases treated by Volar locked plate

Conclusion

This study showed better radiographic results of VLP compared to DBP. However, no technique demonstrated functional superiority at last follow-up.

Ethical approval: The study was approved by the Research Ethics Committee of our institution.

Conflict of interest: The authors of the study have no conflict of interest related to this publication.

References

- Beeres FJP, van de Wall BJM, Hug U, Schep NWL, Babst R, Link BC, et al. (2022). Temporary spanning plate wrist fixation of complex distal radius fractures: a systematic review of 353 patients. *Eur J Trauma Emerg Surg*, 48(3): 1649-1662.
- Chen NC and Jupiter JB (2007). Management of distal radial fractures.

- J Bone Joint Surg Am, 89(9): 2051-2062.
- **Dodds SD, Save AV and Yacob A (2013).** Dorsal spanning plate fixation for distal radius fractures. *Tech Hand Up Extrem Surg*, 17(4): 192-198.
 - **Dzaja I, MacDermid JC, Roth J and Grewal R (2013).** Functional outcomes and cost estimation for extra-articular and simple intra-articular distal radius fractures treated with open reduction and internal fixation versus closed reduction and percutaneous Kirschner wire fixation. *Can J Surg*, 56(6): 378-384.
 - **Egol K, Walsh M, Tejwani N, McLaurin T, Wynn C and Paksima N (2008).** Bridging external fixation and supplementary Kirschner-wire fixation versus volar locked plating for unstable fractures of the distal radius: a randomised, prospective trial. *J Bone Joint Surg Br*, 90(9): 1214-1221.
 - **Marcheix PS, Dotzis A, Benkö PE, Siegler J, Arnaud JP and Charissoux JL (2010).** Extension fractures of the distal radius in patients older than 50: a prospective randomized study comparing fixation using mixed pins or a palmar fixed-angle plate. *J Hand Surg Eur Vol*, 35(8): 646-651.
 - **Margaliot Z, Haase SC, Kotsis SV, Kim HM and Chung KC (2005).** A meta-analysis of outcomes of external fixation versus plate osteosynthesis for unstable distal radius fractures. *J Hand Surg Am*, 30(6): 1185-1199.
 - **Mignemi ME, Byram IR, Wolfe CC, Fan KH, Koehler EA, Block JJ, et al. (2013).** Radiographic outcomes of volar locked plating for distal radius fractures. *J Hand Surg Am*, 38(1): 40-48.
 - **Nguyen TV, Center JR, Sambrook PN and Eisman JA (2001).** Risk factors for proximal humerus, forearm, and wrist fractures in elderly men and women: the Dubbo Osteoporosis Epidemiology Study. *Am J Epidemiol*, 153(6): 587-595.
 - **Richard MJ, Katolik LI, Hanel DP, Wartinbee DA and Ruch DS (2012).** Distraction plating for the treatment of highly comminuted distal radius fractures in elderly patients. *J Hand Surg Am*, 37(5): 948-956.
 - **Rozental TD, Branas CC, Bozentka DJ and Beredjiklian PK (2002).** Survival among elderly patients after fractures of the distal radius. *J Hand Surg Am*, 27(6): 948-952.
 - **Ruch DS and Papadonikolakis A (2006).** Volar versus dorsal plating in the management of intra-articular distal radius fractures. *J Hand Surg Am*, 31(1): 9-16.
 - **Wei DH, Raizman NM, Bottino CJ, Jobin CM, Strauch RJ and Rosenwasser MP (2009).** Unstable distal radial fractures treated with external fixation, a radial column plate, or a volar plate. A prospective randomized trial. *J Bone Joint Surg Am*, 91(7): 1568-1577.
 - **Williksen JH, Frihagen F, Hellund JC, Kvernmo HD and Husby T (2013).** Volar locking plates versus external fixation and adjuvant pin fixation in unstable distal radius fractures: a randomized, controlled study. *J Hand Surg Am*, 38(8): 1469-1476.