

# EFFECTIVENESS OF USING THE MAGNETIC MALLET FOR RIDGE SPLITTING OF THE NARROW POSTERIOR MANDIBULAR RIDGE WITH SIMULTANEOUS IMPLANT PLACEMENT (A CLINICAL TRIAL)

Mohamed H. Salama<sup>1\*</sup> BDS, Nevein S. Mohamed<sup>2</sup>, Marwa G. Noureldin<sup>3</sup>

## ABSTRACT

**INTRODUCTION:** Implant placement in the posterior mandible is sometimes problematic due to loss of horizontal bone width after extraction of posterior teeth. With simultaneous implant placement, the Magnetic Mallet can be used in horizontal bone compaction and expansion.

**OBJECTIVES:** To clinically and radiographically evaluate bone width change using the magnetic mallet for ridge splitting of the narrow posterior mandibular ridge. The secondary aim was to radiographically evaluate bone density change using the magnetic mallet for ridge splitting of the narrow posterior mandibular ridge and the implant stability.

**MATERIALS AND METHODS:** Ten patients with narrow posterior mandibular edentulous ridges underwent ridge splitting using the magnetic mallet and osseodensification with simultaneous implant placement. The assessment comprised a cone beam computed tomography analysis of bone width and bone density change at two weeks, 4, and 6 months postoperatively. Furthermore, implant stability was measured using Osstell.

**RESULTS:** The mean bone density preoperatively ( $480.73 \pm 119.38$  HU) increased significantly six months after ridge splitting and osseodensification ( $697.89 \pm 86.90$  HU). Implant stability also significantly increased at four months postoperatively ( $62.50 \pm 2.64$ ) than immediate postoperative ( $52.40 \pm 3.63$ ) ( $p < .001$ ). Bone width showed a significant increase at six months postoperatively ( $10.34 \pm 0.78$  mm) when compared with preoperative ( $8.45 \pm 0.84$  mm) ( $p < .001$ ).

**CONCLUSION:** The magnetic mallet is an effective and minimally invasive method for ridge splitting of the narrow posterior mandibular ridge with simultaneous implant placement for horizontal bone augmentation. A significant increase in bone width, bone density, good implant stability, and minimal postoperative pain evidence this. Furthermore, the technique is believed to be safe and less time-consuming, eliminating the costs and need for bone grafting and saving time, since no need for a second surgery.

**KEYWORDS:** Magnetic mallet, Narrow posterior mandibular ridge, Ridge splitting, Horizontal ridge augmentation, Dental implant

**RUNNING TITLE:** Magnetic Mallet for Ridge Splitting of Narrow Posterior Mandibular Ridge

1-BDS Faculty of Dentistry, Pharos University in Alexandria

2- Professor of Oral and Maxillofacial Surgery, Faculty of Dentistry, Alexandria University

3-Associate Professor of Oral and Maxillofacial Surgery, Faculty of Dentistry, Alexandria University

*\*Corresponding author:*

[mohamedsalama.mac@gmail.com](mailto:mohamedsalama.mac@gmail.com)

## INTRODUCTION

The approach to comprehensive treatment for individuals with partial or complete edentulism, involving dental implant-based oral restoration, has advanced significantly, offering a reliable and durable solution for replacing missing teeth. However, achieving an optimal prosthetic outcome through ideal implant placement is frequently hindered or not feasible due to the gradual loss of the alveolar ridge due to various factors such as extraction-related complications, periodontal problems, dento-alveolar trauma, or prolonged periods of edentulism (1).

In a prior systematic review, it was emphasized that after tooth extraction, there was a documented reduction in the width of the alveolar ridge, typically falling within the range of 29% to 63%. Maintaining

sufficient height and width of the alveolar ridge is imperative to achieve the essential functional and aesthetic results for restorations supported by dental implants (2).

In implant dentistry, a minimum thickness of 1-1.5mm of intact bone should be on both the buccal and lingual aspect of the implant(s) to ensure a successful outcome (3). Several methods can be performed for bone augmentation in horizontally deficient ridges, such as block bone grafting, guided bone regeneration, and horizontal osteo-distraction (4). However, these methods have many disadvantages: long treatment period, very high cost, patient refusing surgery in another site, morbidity of the donor site, limited availability of bone in the donor site, an

unpredictable resorption of the grafting material, and unexpected reaction against allograft (if used) (5, 6). Hence, alternative treatment strategies and techniques have been proposed for horizontal reconstruction of alveolar deficiencies involving the split-crest technique, ridge expansion and guided bone regeneration with particulated autogenous bone graft in combination with bone substitutes to diminish post-surgical morbidity and shorten patient treatment time (7).

The alveolar ridge splitting method is a surgical technique for horizontal ridge augmentation of narrow ridges to insert implants for prosthetic treatment. The ridge-splitting technique is one of the best methods for managing horizontally deficient ridges. It was developed by Scipioni et al. (4) and Simion et al. (8)

The split-crest technique in conjunction with immediate implant placement involves splitting the alveolar ridge horizontally in two parts using chisels, piezoelectric surgery, or oscillating saws. The buccal cortical bone plate is gently separated from the bone marrow and displaced in a labial direction to increase the alveolar ridge width to enable insertion of implants with an appropriate diameter (9).

Ridge expansion can be performed using various kinds of devices. The traditional devices include chisel and mallet; surgical burs; microsaw blades; osteotomes etc. While the modern devices include the motorized bone expanders; expansion crest devices; ultrasonic/piezoelectric devices and bone expanders. With new technologies availability and advancement in the diagnostic field, a shift from the traditional to the modern devices has been seen (9).

The modern devices have an edge over the traditional ones as they act within a short interval of time, cause minimum trauma and prevent bone heating. These factors in turn result in faster bone healing. All this helps to save the clinician's time and alleviates fear from the patient's mind as well. The earliest instruments used for alveolar ridge expansion were chisels and blades. However, using these instruments was difficult as there was no control and precision. This leads to the advent of newer devices for the bone cutting (9).

The Magnetic Mallet (MM) represents a groundbreaking tool in dental and implant surgery, offering versatility in procedures involving both vertical and horizontal bone compaction and expansion. Essentially, it can replace the conventional surgical hammer across a wide array of cases (10). The device harnesses electromagnetic impact, enabling it to deliver a high-intensity impact force with a precise and brief duration. The purpose of this design is to induce controlled deformation of the bone without widespread

propagation through the bone structure, a common outcome seen when using a surgical hammer (11).

The control unit provides the power for the handpiece of the Magnetic Mallet (MM) utilizing an electromagnetic field. The resulting shock waves create axial and radial movements that are conveyed to the osteotome tip, highlighting significant advantages over conventional mallets. The MM device had a better bone condensing efficiency, especially in softer bone because of the magnetic wave and the subsequent shock wave; induce axial and radial movements applied on the tip of osteotome with a fast energy avoiding patient distress (12).

By electronically controlling the collision between two masses, the Magnetic Mallet achieves a high-intensity impact, generating a shock wave of 130 DaN with a brief pulse lasting 80  $\mu$ s. This process produces an elastic wave followed by controlled motion, ultimately creating a non-elastic shockwave effect on the bone. This phenomenon allows for osseodensification of the bone concurrent with implant site preparation, minimizing or eliminating any jumping gap and negating the necessity for bone grafts (13).

In the process of preparing the osteotomy site for implant placement using the magnetic mallet, there is no need for traditional drilling. As a result, the risks of heat-induced damage and unnecessary bone removal are mitigated. The bone surrounding the implant site undergoes condensation rather than removal, facilitating accelerated osseointegration. The use of magnetic mallets guarantees the delivery of forces in a specific, steady, and anticipated fashion, thereby amplifying the clinician's control throughout the procedure.

Given the innovative nature of this technique, the primary objective of this study was to perform an evaluation that combines clinical observations and radiographic analysis of changes in bone width when utilizing the magnetic mallet for ridge splitting of the narrow posterior mandibular ridge. The secondary objective was to conduct a radiographic assessment of changes in bone density and to assess the stability of implants while utilizing the magnetic mallet for ridge splitting in the narrow posterior mandibular ridge.

## PATIENTS AND METHODS

Ten patients with narrow posterior mandibular ridges were chosen from the outpatient clinics of the Oral and Maxillofacial Surgery Department at the Faculty of Dentistry of Alexandria University. Before the procedure, all patients signed an informed consent form. The Research Ethics Committee of Alexandria University Faculty of Dentistry ethically approved this study on the 19<sup>th</sup> of June 2022 (0446-06/2022).

### Selection Criteria for Patients

#### *Inclusion criteria*

Adult patients within the age range of 40-60 years, displaying satisfactory oral hygiene with no specific sex predilection.

The target population comprised individuals having an inadequate alveolar ridge in the posterior mandibular region (specifically, the premolar to molar area) due to missing mandibular posterior teeth necessitating dental implantation.

Adequate inter-occlusal distance.

D2 or D3 or D4 bone quality.

A minimum bone width of 3 mm is a prerequisite.

A minimum bone height of at least 10 mm above the mandibular canal is required.

#### *Exclusion criteria*

Uncontrolled diabetes (14).

Ongoing chemotherapy or radiotherapy (15).

Heavy smokers.

Individuals with a history of drugs or alcohol abuse

Pregnant women.

Acute infection.

Para-functional habits.

#### *Materials*

The dental implant system used in this study comprised a two-piece screw-type design made of titanium (Vitronex, Italy).

Magnetic mallet: Using its specialized bone splitting tips (Magnetic Mallet, Meta-Ergonomica, Turbigo, Milano, Italy).

Osstell ISQ device (Osstell ISQ, W&H, Sweden).

#### *Methods*

Pre-surgical phase: It included taking the past medical history, past dental history, and chief complaint of the patient, in addition to both extra-oral and intra-oral clinical examination. Cone Beam Computer Tomography (CBCT) was performed to verify bone width, implant position and length, and the intended position of ridge splitting. The bucco-lingual thickness in the crestal area and the density of the cancellous bone were measured.

Surgical Phase (16, 17): Before surgery, every patient in this group underwent scaling and root planning to obtain proper periodontal health. Patients were instructed to rinse their mouths with mouthwash containing 0.12 percent chlorhexidine. All patients were operated under local anesthesia with 4% articaine (1:100,000 epinephrine). No.15 Bard-Parker scalpel blade was used for the crestal incision (slightly buccal to the mid-crest); a full muco-periosteal envelope flap was elevated by a sharp muco-periosteal elevator to reveal the bone crestally, slightly buccally, and lingually. Crestal osteotomy of the crestal bone with bone densification and implant site preparation were all performed simultaneously using the magnetic mallet's ridge-splitting tips, continued in the sequence

recommended by the manufacturer. Then, the implant was inserted manually and fitted sub-crestally by the ratchet of the implant system. The implant stability was recorded using the Osstell, and the cover screw secured the implant. Finally, flap closure was done using 4/0 Silk sutures in a simple interrupted fashion. The sutures were then removed on the 10<sup>th</sup> day postoperatively.

#### *Post-surgical Phase*

##### *Postoperative instructions*

Cold fomentations were applied extra-orally at regular intervals during the first day of surgery, followed by hot fomentation for the next 24 hours to avoid ecchymosis and tissue discoloration (18).

Chlorohexidine mouthwash twice a day for one week starting the day after surgery.

##### *Oral hygiene instructions.*

##### *Postoperative medications*

Patients were prescribed Amoxicillin/Clavulanic acid (Augmentin: Amoxicillin 875 mg + Clavulanic acid 125 mg: GlaxoSmithKline, UK) at a dosage of 1 gm twice daily for a duration of seven days.

Trypsin and Chymotrypsin (Ambezim-G: Trypsin 5mg + Chematrypsin 5mg: Global NAPI Pharmaceuticals, Alexandria, Egypt) 1 tab every eight hours before meals by an hour for five days.

Diclofenac potassium (Cataflam: Diclofenac Potassium 50 mg: Novartis-Switzerland) was prescribed as 50mg twice daily (every 12-hours) for five days.

Following the surgical procedure, patients were directed to apply the antiseptic mouthwash containing Chlorhexidine (Hexitol: Chlorhexidine 125mg/100ml, concentration 0.125%, manufactured by ADCO, Alexandria, Egypt) twice each day for a week.

#### *Clinical evaluation*

Following the surgical procedure, early monitoring was conducted at two days and one week to detect any signs of infection, edema, and assess wound healing progress. Pain levels in the postoperative phase were evaluated using a 10-point Visual Analogue Scale [VAS] where 0 indicates absence of pain, (1-3) denotes mild discomfort, (4-6) signifies moderate pain, and (7-10) represents severe pain (19), both at the two-day and one-week marks after surgery. Immediately after implant placement, the implant initial stability was evaluated using the Osstell ISQ device (Osstell ISQ, W&H, Sweden) by analyzing insertion torque and resonance frequency and then at the four-month postoperative evaluation. A comprehensive clinical and radiographic follow-up was conducted for all patients over a six-month postoperative period.

#### *Radiographic Evaluation*

Before the surgical procedure and at specific intervals of two weeks, four months, and six months

following the surgery, scans were performed to assess alterations in bone width and bone density surrounding the placed dental implants. To ensure data accuracy and minimize potential biases, all CBCT scans were uniformly performed at a singular radiology facility using the same imaging device.

#### Prosthetic treatment

Following a four-month period, healing abutments were installed to achieve an appropriate emergence profile. Subsequently, impressions were obtained, and the prostheses were provided two weeks thereafter.

#### Bone width measurements (Figure 3)

Concerning the bone width measurements, the OnDemand 3D software was employed for these measurements. A 4mm subcrestal virtual point was landmarked preoperatively from the alveolar crest as the reference point. Subsequently, same measurements were used for post-operative CBCT at the same cuts after 2 weeks, 4 and 6 months. The bone width results showed an increase of  $22.78 \pm 8.70$  between the two studied periods at six months postoperatively and preoperative width which was significantly different ( $p < .001$ ).

#### Bone density measurements

Bone density assessments were conducted before the surgery, as well as at two weeks, four months, and six months following the implant placement. The OnDemand 3D software was utilized for these measurements. First, a virtual implant was meticulously adjusted to align precisely with the size and placement of the planned implant for the designated site before the surgery. Afterward, the software autonomously determined the mean bone density around the implant site before the procedure, with measurements taken 2 mm away from the implant's edge. Following a period of four months, the OnDemand 3D software was utilized to choose a virtual implant that closely resembled the implant actually placed. Then, the virtual implant was overlaid onto the actual placed implant. The software automatically measured the mean bone density around the implant, avoiding potential distortions caused by the metal stray beam from the actual implant (Figure 1) (20).

#### Statistical analysis

The gathered data underwent statistical analysis using version 25 of the Statistical Package for the Social Sciences (SPSS) program (21). The data were described using descriptors such as minimum, maximum, mean, standard deviation, standard error of the mean, and a 95% confidence interval (CI) for the mean (22). When establishing the sample size, a 20% margin of error (beta error) was considered acceptable to maintain a study power of 80%. The significance level (alpha) was set at 5%, representing a 95%

confidence level. Statistical significance was determined with a  $p$ -value less than .05 (23).

#### RESULTS (data are presented as mean $\pm$ SD)

##### Biodata

The study encompassed a total of ten patients seven females and three males. Their ages ranged from 42 to 59 years, with a mean age of  $49.40 \pm 5.50$  years. Each patient received a single implant, resulting in a total of ten implants.

##### Clinical evaluation

##### Soft tissue healing

The majority of patients exhibited satisfactory healing. However, two patients encountered soft tissue abscesses, necessitating treatment through incision and drainage alongside the administration of broad-spectrum antibiotics.

##### Pain

Two days postoperatively, 8/10 (80.00%) had moderate VAS, and 2/10 (20.00%) had severe VAS. One week postoperatively, 9/10 (90.00%) had mild VAS, and 1/10 (10.00%) had moderate VAS. VAS Intensity was significantly decreased after one week postoperatively compared to two days postoperatively ( $p = .002$ ) (Table 1).

##### Implant stability (ISQ)

Implant Stability (ISQ) after four months postoperatively ( $62.50 \pm 2.64$ ) was significantly increased compared with immediate postoperatively ( $52.40 \pm 3.63$ ) ( $p < .001$ ) (Table 1).

##### Radiographic evaluation

##### Bone width (bone expansion)

Preoperatively, the mean bone width was  $8.45 \pm 0.84$  mm; two weeks postoperatively, it was  $9.06 \pm 0.69$  mm; four months postoperatively, it was  $9.65 \pm 0.65$  mm; six months postoperatively, it was  $10.34 \pm 0.78$  mm. Repeated measures analysis revealed that bone width statistically significantly increased during the different time points of measurements ( $p < .001$ ).

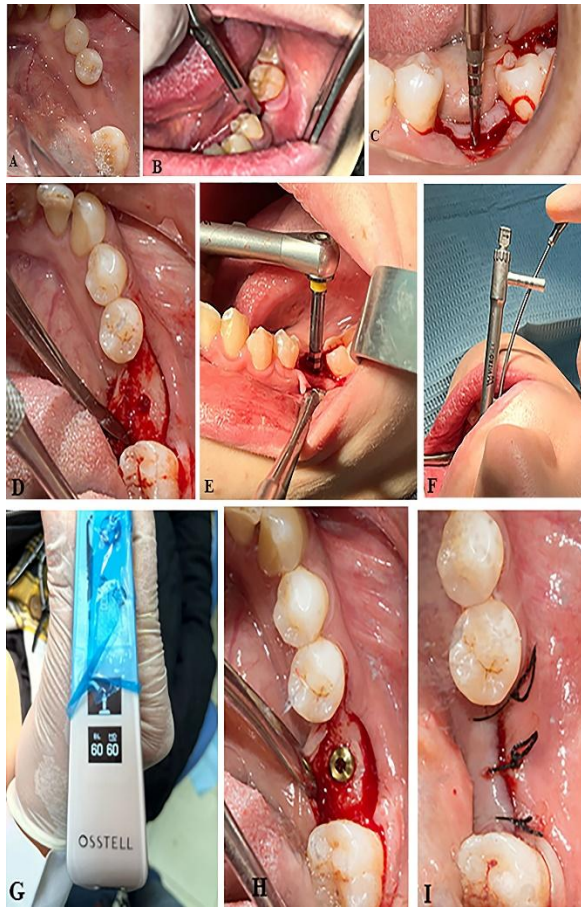
The pairwise analysis indicated a statistically significant augmentation in bone width at two weeks, four months, and six months postoperatively in comparison to the preoperative levels ( $p < .001$  for all). Furthermore, a substantial significant increase in bone width was evident at both four and six months postoperative, signifying a significant difference compared to the bone width measured at the two-week postoperative point ( $p < .001$  for both comparisons). Additionally, it is important to note a statistically significant rise in bone width at the six-month postoperative stage when compared to the bone width observed at four months postoperative ( $p < .025$ ) (Table 3).

##### Bone density (bone compaction)

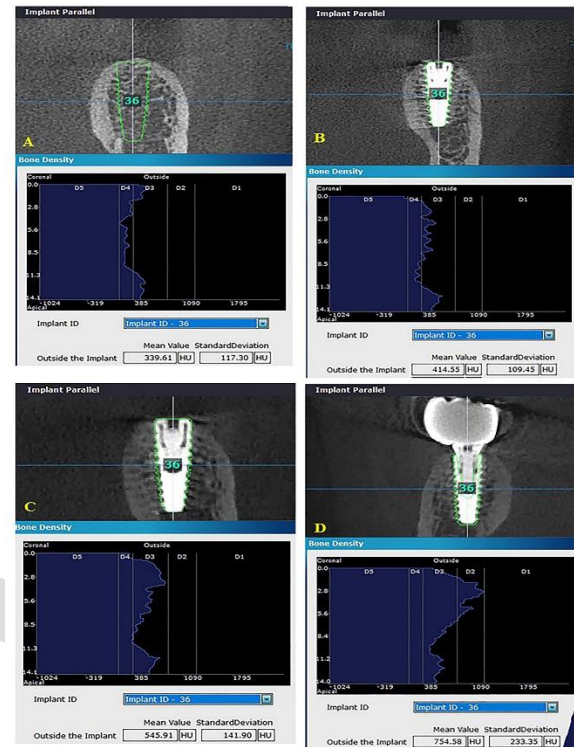
Preoperatively, the mean bone density was  $480.73 \pm 119.38$  HU; two weeks postoperatively, it was  $547.53 \pm 108.35$  HU; SEM of 34.26 HU, four months



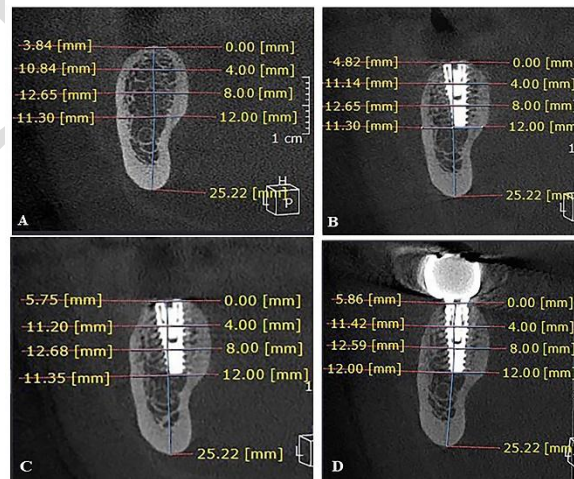
postoperatively, it was  $629.71 \pm 86.34$  HU, six months postoperatively, it was  $697.89 \pm 86.90$  HU. Repeated measures analysis revealed that bone density statistically significantly increased during the different time points of measurements ( $p < .001$ ). The comparative analysis showed a significant increase in bone density at two weeks, four months, and six months postoperatively when compared to the preoperative levels ( $p < .001$  for all). Furthermore, a significant rise in bone density was observed at four and six months postoperative compared to two weeks postoperative ( $p = .001$ ,  $p < .001$ , respectively). Additionally, at six months postoperatively, a notable significant increase in bone density was observed in comparison to the bone density noted at the four-month postoperative stage ( $p < .001$ ) (Table 2).



**Figure (1):** Steps for ridge-splitting using the magnetic mallet with simultaneous implant placement. A) Preoperative occlusal view of the narrow posterior mandibular ridge, B) Crestal incision, C) Ridge splitting using magnetic mallet splitting tip, D) Osteotomy site, E) Implant placement, F) Assessment of the primary stability using implant System's Ratchet, G) Measurement of the primary stability using Osstell, H) Cover screw, I) Flap closure.



**Figure (2):** A) Bone density measurement preoperatively. B) Bone density measurement 2 weeks postoperatively. C) Bone density measurement 4 months postoperatively. D) Bone density measurement 6 months postoperatively.



**Figure (3):** A) Bone width measurement preoperatively. B) Bone width measurement 2 weeks postoperatively. C) Bone width measurement 4 months postoperatively. D) Bone width measurement 6 months postoperatively.

**Table (1):** Visual Analogue Scale (VAS) Two days postoperative and one week postoperative in the studied group and Implant Stability (ISQ) immediate postoperative and four months postoperative in the studied group.

| VAS                           | Two days postoperative            | One week Postoperative    | VAS Percentage change (%)               |
|-------------------------------|-----------------------------------|---------------------------|---|
| n                             | 10                                | 10                        | 10                                      |
| Min. – Max.                   | 4.00-7.00                         | 2.00                      | 80.00 - -                               |
| Mean ± SD                     | 5.00                              | 2.00-4.00                 | 42.86                                   |
| SE of the mean                | 5.00-7.00                         | 1.00-2.00                 | -69.05                                  |
| 95% CI of the mean            | 5.00-6.00                         | 1.00                      | -80.00 - -                              |
| Test of significance          | $Z_{(WSR)}=2.844$<br>$p=.004^*$   |                           |   |
| p value                       |                                   |                           |   |
| VAS grade                     |                                   |                           |   |
| Mild                          | 0 (0.00%)                         | 9 (90.00%)                |   |
| Moderate                      | 8 (80.00%)                        | 1 (10.00%)                |   |
| Severe                        | 2 (20.00%)                        | 0 (0.00%)                 |   |
| Test of significance          | Kendall's W=1.000<br>$p=.002^*$   |                           |   |
| p value                       |                                   |                           |   |
| Implant Stability (ISQ)       | Immediate postoperative           | Four months Postoperative | Implant stability percentage change (%) |
| n                             | 10                                | 10                        | 10                                      |
| Min. – Max.                   | 45.00-58.00                       | 59.00-68.00               | 13.46-35.56                             |
| Mean ± SD                     | 52.40±3.63                        | 62.50±2.64                | 19.59±6.45                              |
| SE of the mean                | 1.15                              | 0.83                      | 2.04                                    |
| 95% CI of the mean            | 49.81-54.99                       | 60.61-64.39               | 14.98-24.20                             |
| Paired t-test of significance | $t_{(df=9)}=12.485$<br>$p<.001^*$ |                           |   |
| p                             |                                   |                           |   |

n: Number of patients

Min-Max: Minimum – Maximum

SD: Standard Deviation

SE: Standard error

CI: Confidence interval

WSR: wilcoxon signed ranks test

df: degree of freedom

\*: Statistically significant ( $p<.05$ )**Table (2):** Bone density (HU) postoperative, two weeks, four and six months postoperative in the studied group

| Bone density (HU)    | Preoperative   | Two weeks Postoperative  | Four months Postoperative   | Six months Postoperative |
|----------------------|--|--|---|--------------------------|
| n                    | 10   | 10   | 10  | 10                       |
| Min. – Max.          | 311.00-624.76  | 404.42-673.48  | 497.76-724.94   | 525.10-788.94            |
| Mean ± SD            | 480.73 <sup>a±</sup>   | 547.53 <sup>b±</sup>   | 629.71 <sup>c±</sup>  | 697.89 <sup>d±</sup>     |
| SE of the mean       | 119.38   | ±108.35  | ±86.34  | ±86.90                   |
| 95% CI of the mean   | 37.75  | 34.26  | 27.30   | 27.48                    |
| Test of significance | $F_{(GG)(d1.642)}=88.514$<br>$p<.001^*$<br>$\eta^2=0.908$ (90.8%)            |  |   |                          |
| p                    | 1 (100.00)   |  |   |                          |
| Partial Eta Squared  |  |  |   |                          |
| Observed Power       |  |  |   |                          |
|                      | Percentage change <sup>1</sup> (%) (Two weeks postoperative vs preoperative) | Percentage change <sup>2</sup> (%) (Four months postoperative vs preoperative) | Percentage change <sup>3</sup> (%) (Six months postoperative vs preoperative) |                          |
| N Min. – Max.        | 10   | 10   | 10  |                          |
| Mean ± SD            | 3.56-36.38   | 15.25-60.05  | 23.91-90.19   |                          |
| SE of the mean       | 15.54±9.65   | 34.89±18.39  | 50.10±23.62   |                          |
| 95% CI of the mean   | 3.05   | 5.82   | 7.47  |                          |
|                      | 8.63-22.44   | 21.73-48.04  | 33.20-66.99   |                          |

n: Number of patients

Min-Max: Minimum – Maximum

SD: Standard Deviation

SE: Standard error

CI: Confidence interval

F: F ratio of ANalysis Of VAriance (ANOVA) test.

df: degree of freedom

a,b,c,d: different superscript letters indicate pairwise significance based on estimated marginal means

(p value adjustment for multiple comparisons using Bonferroni method)

\*: Statistically significant ( $p<.05$ )

**Table (3):** Bone width (mm) postoperative, two weeks, four and six months postoperative in the studied group.

| Bone Width (mm)   | Preoperative  | Two weeks Postoperative   | Four months Postoperative  | Six months Postoperative |
|---|---|---|--|--------------------------|
| n   | 10  | 10  | 10   | 10                       |
| Min. – Max.   | 7.21-9.84   | 8.15-10.17  | 8.77-10.64   | 9.11-11.24               |
| Mean ± SD   | 8.45 <sup>a±</sup> 0.84   | 9.06 <sup>b±</sup> 0.6 9  | 9.65 <sup>c±</sup> 0.6 5   | 10.34 <sup>d±</sup> 0.78 |
| SE of the mean  | 0.26  | 0.22  | 0.20   | 0.25                     |
| 95% CI of the mean  | 7.85-9.05   | 8.56-9.55   | 9.19-10.11   | 9.78-10.89               |
| Test of significance<br><i>p</i><br>Partial Eta Squared<br>Observed Power | F <sub>(GG)(d1,383)</sub> =67.70<br><i>p</i> <.001*<br>$\eta^2=0.883$ (88.3%)<br>1 (100.00) |   |  |                          |
|   | Percentage change <sup>1</sup> (%)<br>(Two weeks postoperative vs preoperative)             | Percentage change <sup>2</sup> (%)<br>(Four months postoperative vs preoperative) | Percentage change <sup>3</sup> (%)<br>(Six months postoperative vs preoperative) |                          |
| n   | 10  | 10  | 10   |                          |
| Min. – Max.   | 3.35-13.22  | 8.13-24.55  | 6.42-33.64   |                          |
| Mean ± SD   | 7.36±3.30   | 14.50±4.65  | 22.78±8.70   |                          |
| SE of the mean  | 1.04  | 1.47  | 2.75   |                          |
| 95% CI of the mean  | 5.00-9.72   | 11.18-17.83   | 16.55-29.00  |                          |

n: Number of patients

Min-Max: Minimum – Maximum

SD: Standard Deviation

SE: Standard error

CI: Confidence interval

F: F ratio of ANalysis Of VAriance (ANOVA) test.

df: degree of freedom

<sup>a,b,c,d</sup>: different superscript letters indicate pairwise significance based on estimated marginal means

(p value adjustment for multiple comparisons using Bonferroni method)

\*: Statistically significant (*p*<.05)

## DISCUSSION

The ridge-splitting procedure offers numerous benefits, including the avoidance of bone grafting, whether allo-grafts, xeno-grafts or even autografting and harvesting bone from an additional intra-oral surgical site (such as ramus, maxillary tuberosity, mandibular symphysis) or extra-oral sites (as iliac crest, or tibia) (24). Implant placement simultaneously with the ridge split procedure results in cost-effectiveness for patients and a reduction in the overall duration of treatment (25). The primary surgical risk pertains to the possible fracture of the buccal cortical plate, which may happen during ridge splitting, expanding the ridge with bone expanders, or during the insertion of implants (26). Prior studies indicated that the likelihood of cortical plate fracture during implant placement is quite low (27).

Research indicates that the alveolar ridge splitting technique meets the essential criteria for optimal bone healing and regeneration in cases of bony defects. These criteria encompass minimizing bone loss, preserving the integrity of bony structures, maintaining a controlled healing environment, providing ample space, and ensuring mechanical stability of the wound (28-30).

As of now, the Magnetic Mallet (MM) stands as the established gold standard for the insertion of blade and wedge implants (31). During the years 2014 to 2015, Crespi and co-researchers reported a successful experience with the placement of 152 dental implants using the Magnetic Mallet in a group of 59 patients who had undergone ridge expansion. Their study showed a remarkable survival rate of over 98% during a two-year follow-up period. The authors highlighted the safety, reliability, and patient tolerance of using the Magnetic Mallet for segmental ridge splitting, noting that it did not cause bone damage or overheating (32).

In this study, the repeated measure analysis showed that the Bone Width at 4 mm sub-crestally was statistically significantly higher after four months compared to the pre-operative measurement in the patients under study. The pairwise comparison revealed that there was a significant increase in bone width (at 4 mm) -landmark point- sub-crestally two weeks post-operatively, four- and six-months post-operative compared with pre-operative. In addition, there was a significant increase in bone width (mm) four months post-operatively compared with two weeks post-operative.

A notable augmentation in bone width was achieved through alveolar bone splitting and expansion using the Magnetic Mallet as a new modality for ridge splitting of narrow posterior mandibular ridge. This was served as a positive indicator of successful treatment. Pre-operatively, the



mean bone width was  $8.45 \pm 0.84$  mm; two weeks post-operatively, it was  $9.06 \pm 0.69$  mm; four months post-operatively, it was  $9.65 \pm 0.65$  mm; six months post-operatively, it was  $10.34 \pm 0.78$  mm. Repeated measures analysis revealed that bone width statistically significantly increased during the different time points of measurements ( $p < .001$ ). The pairwise analysis indicated a statistically significant augmentation in bone width at two weeks, four months, and six months post-operatively in comparison to the pre-operative levels ( $p < .001$  for all). Bone density exhibited a significant and consistent increase at two weeks, four months, and six months postoperatively compared to the preoperative levels ( $p < .001$  for all). Furthermore, a statistically significant rise in bone density was observed at four and six months postoperatively in comparison to two weeks postoperative ( $p = .001$ ,  $p < .001$ , respectively). Additionally, a significant statistical rise in bone density was evident at the six-month postoperative assessment in comparison to the bone density observed at four months postoperatively ( $p < .001$ ). In this study, there was a noteworthy percentage increase in bone density, ranging from more than 15% to as much as 50%, at the six-month postoperative point. These findings align with those of El-Said et al (33), who observed a 39% increase in mean bone density six months after implant placement compared to the preoperative values.

Previous studies have identified a rise in bone density following osseodensification. It is widely believed that this heightened bone density, combined with greater bone-to-implant contact, leads to improved stability of the implant (26). In this current study, a substantial increase in mean bone density was noted following the utilization of the MM for osseodensification in conjunction with crestal ridge splitting for ridge expansion. Moreover, histological data substantiate the superior performance of osseodensification compared to traditional drilling concerning bone-to-implant contact and the proportion of area occupied (27).

In the present study, the OnDemand system's automated measurement of bone density surrounding the implants exhibited a statistically significant variance between preoperative and postoperative outcomes. These findings align with the research conducted by Fanuscu et al. (34)

Abdulhalim et al. (35) demonstrated a significant increase in implant stability after 6 months, which is consistent with the findings of Kreissel et al. (36) Kreissel's study also assessed implant stability in expanded ridges and reported a noteworthy improvement in ISQ values over the study duration due to the application of bone spreaders. Digholkar et al. (37) emphasized the significance of ISQ values,

stating that the acceptable stability range, as determined by several studies using Resonance Frequency Analysis (RFA), falls between 55 and 85 ISQ, with an average ISQ level of 70. In the Abdulhalim et al. (35), the mean ISQ value after a healing period of 6 months was 72.12.

In this study, a statistically notable improvement in implant stability was observed after four months, as compared to the stability values immediately following the surgery ( $p < .001$ ).

In the present study, the Magnetic Mallet (MM) was utilized to achieve the expansion effect after ridge splitting, capitalizing on its densifying effect to improve both implant stability and peri-implant bone density. By utilizing the MM, implant placement could be performed simultaneously, ensuring adequate primary stability and obviating the need for bone grafts or additional instruments for implant site preparation. This approach led to a reduction in both treatment cost and duration. Furthermore, the study found that secondary implant stability at four months was notably improved through osseodensification (38); This aligns with the findings of the current research.

Abou Hamdan et al. (39) as well as Agarwal et al. (10) illustrated that ridge splitting in conjunction with implant placement represents a minimally invasive strategy to enhance the width of the alveolar ridge horizontally. Moreover, patients exhibited successful healing by adhering to postoperative instructions, resulting in minimal scores on the Visual Analogue Scale (VAS), affirming the safety and conservative nature of the technique. Additionally, this method eliminated the requirement for a subsequent surgical procedure by integrating implant site preparation and enabling immediate implant placement within the same surgical session.

## CONCLUSIONS

The magnetic mallet is an effective and minimally invasive method for ridge splitting of the narrow posterior mandibular ridge with simultaneous implant placement for horizontal bone augmentation. A significant increase in bone width, bone density, good implant stability, and minimal postoperative pain evidence this. Furthermore, the technique is believed to be safe and less time-consuming, eliminating the costs and need for bone grafting and saving time, since no need for a second surgery.

## RECOMMENDATIONS

It is advisable to conduct additional long-term studies involving larger sample sizes and extended follow-up durations to substantiate the observed outcomes. Moreover, it is advisable to integrate a control group



to compare the effects of osseodensification with alternative methods of ridge splitting and expansion.

#### LIMITATIONS

Availability of patients with narrow posterior mandibular ridge seeking dental implantation as a treatment plan. Availability and high cost of the magnetic mallet device and its splitting tips.

#### CONFLICT OF INTEREST:

The authors declare no conflicts of interest.

#### FUNDING STATEMENT:

The authors received no specific funding for the conduction of this study.

#### REFERENCES

1. Buser D, Sennerby L, De Bruyn H. Modern implant dentistry based on osseointegration: 50 years of progress, current trends and open questions. *Periodontol* 2000. 2017;73:7-21.
2. Bassetti MA, Bassetti RG, Bosshardt DD. The alveolar ridge splitting/expansion technique: a systematic review. *Clin Oral Implants Res*. 2016;27:310-24.
3. Albrektsson T, Zarb G, Worthington P, Eriksson A. The long-term efficacy of currently used dental implants: a review and proposed criteria of success. *Int J Oral Maxillofac Implants*. 1986;1:11-25.
4. Scipioni A, Bruschi GB, Calesini G. The edentulous ridge expansion technique: a five-year study. *Int J Periodontics Restorative Dent*. 1994;14:451-9.
5. Machtei EE. The effect of membrane exposure on the outcome of regenerative procedures in humans: a meta-analysis. *J Periodontol*. 2001;72:512-6.
6. Chiapasco M, Ferrini F, Casentini P, Accardi S, Zaniboni M. Dental implants placed in expanded narrow edentulous ridges with the Extension Crest device. A 1-3-year multicenter follow-up study. *Clin Oral Implants Res*. 2006;17:265-72.
7. Yoo RH, Chuang SK, Erakat MS, Weed M, Dodson TB. Changes in crestal bone levels for immediately loaded implants. *Int J Oral Maxillofac Implants*. 2006;21:253-61.
8. Simion M, Baldoni M, Zaffe D. Jawbone enlargement using immediate implant placement associated with a split-crest technique and guided tissue regeneration. *Int J Periodontics Restorative Dent*. 1992;12.
9. Eriksson RA, Albrektsson T. The effect of heat on bone regeneration: an experimental study in the rabbit using the bone growth chamber. *J Oral Maxillofac Surg*. 1984;42:705-11.
10. Agarwal N, Pai U, Rodrigues S, Baral S. Ridge splitting for horizontal bone augmentation with Guided Bone Regeneration (GBR) and simultaneous implant placement. *Journal of Nepalese Prosthodontic Society*. 2020;3:37-43.
11. Desai A, Patil S, Mitra D, Shah R. Magnetic Mallet-Feel the Future. *JIDA: Journal of Indian Dental Association*. 2020;14.
12. Crespi R, Bruschi GB, Capparé P, Gherlone E. The utility of the electric mallet. *J Craniofac Surg*. 2014;25:793-5.
13. Vercellotti T, Troiano G, Oreglia F, Lombardi T, Gregorig G, Morella E, et al. Wedge-Shaped Implants for Minimally Invasive Treatment of Narrow Ridges: A Multicenter Prospective Cohort Study. *J Clin Med*. 2020;9.
14. Marchand F, Raskin A, Dionnes-Hornes A, Barry T, Dubois N, Valéro R, Viallettes B. Dental implants and diabetes: conditions for success. *Diabetes Metab*. 2012;38:14-9.
15. Shugaa-Addin B, Al-Shamiri H-M, Al-Maweri S, Tarakji B. The effect of radiotherapy on survival of dental implants in head and neck cancer patients. *J Clin Exp Dent*. 2016;8:e194.
16. Gottsegen R. Should the Teeth be Scaled Prior to Surgery? *J Periodontol*. 1961; 32:301-7. .
17. Poppolo Deus F, Ouanounou A. Chlorhexidine in Dentistry: Pharmacology, Uses, and Adverse Effects. *Int Dent J*. 2022;72:269-77.
18. Mani A, Mani S, Sachdeva S, Sodhi JK, Vora HR, Gholap S. Post-surgical care in surgical periodontics. *P Int J Periodontol Implantol* 2021;6:74-8.
19. Ghai A, Kumar H, Karwasra R, Kad N, Rohilla S, Parsad S. Ultrasound Guided Celiac Plexus Neurolysis by Anterior Approach for Pain Management in Upper Abdominal Malignancy: Our Experience. *Anaesthesia, Pain & Intensive Care*. 2019:274-81.
20. Faek AMS, Elsheikh S, Noureldin MG. Evaluation of one-Stage inverted U-Shaped ridge splitting and concurrent implant placement in anterior maxillary undercut defect (a Clinical Trial). *Alex Dent J*. 2023;48:28-34.
21. IBM Corp. IBM SPSS Statistics for Windows, Version 25.0. Armonk, NY: IBM Corp.; Released 2017.
22. Greenland S, Senn SJ, Rothman KJ, Carlin JB, Poole C, Goodman SN, Altman DG. Statistical tests, P values, confidence intervals, and power: a guide to misinterpretations. *Eur J Epidemiol*. 2016;31:337-50.
23. Curran-Everett D. Evolution in statistics: P values, statistical significance, kayaks, and walking trees. *American Physiological Society Bethesda, MD*; 2020. p. 221-4.
24. Basa S, Varol A, Turker N. Alternative bone expansion technique for immediate placement of implants in the edentulous posterior mandibular

- ridge: a clinical report. *Int J Oral Maxillofac Implants*. 2004;19.
25. Lindquist LW, Rockler B, Carlsson GE. Bone resorption around fixtures in edentulous patients treated with mandibular fixed tissue-integrated prostheses. *J Prosthet Dent* 1988;59:59-63.
  26. Torrella F, Pitarch J, Cabanes G, Anitua E. Ultrasonic osteotomy for the surgical approach of the maxillary sinus: a technical note. *Int J Oral Maxillofac Implants*. 1998;13.
  27. Blus C, Szmukler-Moncler S. The split-crest procedure with ultra-sonic bone surgery. Results of a 3-year experience with 172 treated sites. *Clin Oral Implants Res*. 2004;14:xxxvi-xxxvii.
  28. Proussaefs P, Lozada J. The use of intraorally harvested autogenous block grafts for vertical alveolar ridge augmentation: a human study. *Int J Periodontics Restorative Dent*. 2005;25.
  29. Botticelli D, Berglundh T, Buser D, Lindhe J. The jumping distance revisited: An experimental study in the dog. *Clin Oral Implants Res*. 2003;14:35-42.
  30. Sjöström M, Sennerby L, Nilson H, Lundgren S. Reconstruction of the atrophic edentulous maxilla with free iliac crest grafts and implants: a 3-year report of a prospective clinical study. *Clin Implant Dent Relat Res*. 2007;9:46-59.
  31. Obiechina N. Osteotome technique: A Minimally Invasive Way to Increase Bone for Dental Implant Placement in The Posterior Maxilla and Prevent Sinus Membrane Perforation for Single and Multiple Teeth Replacements. *J Med Clin Res Rev*. 2019;3:1-6.
  32. Crespi R. *Magnetic Mallet in Bone Remodeling*: Quintessenza; 2016.
  33. El-Said MM, Sharara AA, Melek LF, Khalil NM. Evaluation of Autogenous Fresh Demineralized Tooth Graft Prepared at Chairside for Dental Implant (Clinical and Histological Study). *Alex Dent J*. 2017;42:47-55.
  34. Fanuscu MI, Chang T-L, Akça K. Effect of surgical techniques on primary implant stability and peri-implant bone. *J Oral Maxillofac Surg*. 2007;65:2487-91.
  35. Abdulhalim AO, Tawfik BEAR, Hosni A. Effect of Ridge Splitting Simultaneous with Implant Placement for Treatment of Narrow Ridge. *Al-Azhar Journal of Dental Science*. 2020;23:285-90.
  36. Kreissel P, Kölpin F, Graef F, Wichmann M, Karl M. Effect of rotating osteotomes on primary implant stability-an in vitro investigation. *J Oral Implantol*. 2013;39:52-7.
  37. Digholkar S, Madhav VNV, Palaskar J. Methods to measure stability of dental implants. *Journal of Dental and Allied Sciences*. 2014;3:17.
  38. González-García R, Monje F, Moreno C. Alveolar split osteotomy for the treatment of the severe narrow ridge maxillary atrophy: a modified technique. *Int J Oral Maxillofac Surg*. 2011;40:57-64.
  39. Abou Hamdan H, Nassar J, Aoun G. Alveolar ridge split technique with immediate implant placement: A case report. *Int J Biomed Healthc*. 2019;7:30-3.