

EFFICACY OF ORAL ZINC SUPPLEMENT AS AN ADJUNCTIVE THERAPY FOR EROSIVE ORAL LICHEN PLANUS (A RANDOMIZED, CONTROLLED CLINICAL TRIAL)

Esraa M. Farahat^{1*} BDS, Shahira A. El Domiaty² PhD,
Sabah A. Mahmoud³ PhD, Souzy K. Anwar⁴ PhD

ABSTRACT

BACK GROUND: Oral Lichen planus (OLP) is an autoimmune disorder with a chronic nature where CD8+ cytotoxic T-cells release inflammatory cytokines. Inflammations in OLP persist due to matrix metalloproteinases (MMPs) that have a role in collagen cleavage. Zinc prevents basement membrane disruption through inhibition of MMP-9 activation.

AIM OF THE STUDY: Evaluating and comparing clinically the effectiveness of adding systemic oral zinc supplementation to topical corticosteroids and topical corticosteroids alone for erosive OLP (EOLP) treatment, and to measure biochemically salivary MMP-9 levels before and after both treatment modalities.

METHODOLOGY: This study was performed on 22 patients have EOLP and divided equally into: Test group; 11 patients received oral zinc picolinate 50 mg as a single morning dose with 0.1% triamcinolone acetonide (TA) oral paste twice daily for 6 weeks. Control group; 11 patients received 0.1% TA orabase twice daily for 6 weeks. Patients were recruited and assessed clinically at baseline, after six and twelve weeks using numerical rating scale (NRS) for pain assessment and Thongprasom et al score for objective assessment of oral lesions. Salivary MMP-9 was evaluated at baseline and after 12 weeks.

RESULTS: Test group showed a significant lowering in Thongprasom et al score after 6 weeks, a significant reduction in NRS after 6 and 12 weeks, and a significant reduction in MMP-9 levels from baseline to weeks 12 as compared to control group.

CONCLUSIONS: Oral zinc supplementation with topical corticosteroids has promising effects for EOLP.

KEYWORDS: Oral lichen planus, Matrix metalloprotenase, Zinc.

RUNNING TITLE: Oral Zinc Effects on Erosive Oral Lichen Planus.

1 BDS, 2014, Faculty of Dentistry, Alexandria University, Alexandria, Egypt

2 Professor of Oral Medicine, Periodontology, Oral Diagnosis and Oral Radiology Department, Faculty of Dentistry, Alexandria University, Alexandria, Egypt

3 Professor of Medical Biochemistry, Medical Biochemistry Department, Faculty of Medicine, Alexandria University, Alexandria, Egypt

4 Assistant Professor of Oral Medicine, Periodontology, Oral Diagnosis and Oral Radiology Department, Faculty of Dentistry, Alexandria University, Alexandria, Egypt

* Corresponding Author:

E-mail: dresraamagdy5@gmail.com

INTRODUCTION

Oral lichen planus inflammatory disease is characterized by dysregulation of T-lymphocytes mediated immunity. Oral lichen planus has no racial predilection with an estimated prevalence 0.55%-2% worldwide, and presents with six diverse forms including reticular, papular, plaque, atrophic, bullous, and erosive forms. Two main hypotheses are widely accepted about pathogenesis mechanisms of OLP; antigen-distinctive cell-mediated immune response and non-distinctive pathways. In antigen-distinctive pathway, activated apoptosis process of keratinocytes is by T lymphocytes (cytotoxic cells). In non-distinctive pathway, the inflammations persist due to releasing of pro-inflammatory mediators, presence of

oxidative stress related molecules which cause oxidative damage to DNA proteins (1), and activating of matrix metalloproteinase-9 enzymes (MMPs-9) that have a role in cells matrix composition and repairing, because it is precisely regulated under normal conditions, as well as being involved in pathological inflammatory processes and tumor progression (2).

They are several studies conducted on the recent therapeutic modalities for OLP which concluded that corticosteroids are the first choice for treatment. Immune suppressive agents (calcineurin inhibitors), retinoids, and dapsone have also a significant participation. Photodynamic and laser therapy have promising therapeutic effects on OLP (3).

Oral zinc supplements may attribute to reduce signs and symptoms of OLP disease (4). The relation of OLP and zinc depends on zinc benefits in enhancement of proteins structure, inhibition of deregulated MMPs-9 and prevention of keratinocytes apoptosis (4).

Numerous authors have proposed that systemic zinc supplements may have potential benefits in several immune-mediated inflammatory conditions, including psoriasis, rheumatoid arthritis, and various cardiovascular diseases, by enhancing allergic reactions, improving the body's response to pathogens, and reducing the inflammatory response (5). Additionally, another meta-analysis found that zinc supplementations significantly decrease glucose levels in those with chronic metabolic disorders, such as obesity and types 1 and 2 diabetes mellitus (6). Rare adverse effects of zinc supplementation have been found such as Zn interaction with some antibiotics, immune system suppression, which increases susceptibility to infections; copper insufficiency and related neurological problems. Zinc supplementation is not recommended for alcoholism and individuals with some inflammatory bowel illnesses because of its limited absorption (7).

Researchers have also reported that zinc deficiency could cause over expression of cyclooxygenase-2 (COX-2). Up regulation of COX-2 enhances cells to proliferate and inhibits apoptosis process, contributing to cancer. So that, zinc re supplementation strategies prevent cancer, and aid in the limitation of its malignancy through repairing and protecting DNA proteins from free radicals (8).

Our clinical trial assessed the systemic oral zinc supplementation effects as an additional medication that may be considered an adjunctive for the topical corticosteroid therapy and compared that with topical corticosteroids alone for EOLP treatment. The null hypothesis of the research was that there would be non statistical significant difference between the two studied groups relating to the subjective and objective outcomes after treatment with both therapeutic modalities.

MATERIALS AND METHODS

A two arm Parallel randomized controlled clinical trial following the CONSORT 2010 guidelines (9) was performed on 22 patients with erosive OLP attending the outpatient clinic of the Oral Medicine, periodontology, Diagnosis, and Radiology Department, Faculty of Dentistry, Alexandria University, Egypt. They were diagnosed according to the modified WHO criteria of oral lichen planus in terms of history, clinical and histopathological examination (10).

All patients signed a written informed consent according to the guidelines of Ethics Committee of

Alexandria University Faculty of Dentistry (IRB No.001056-IORG0008839-0290-09/2021). Patients were treated according to the principles of the modified Helsinki's code for human clinical studies 2013 (11). The research has been registered at Clinical Trial. gov (NCT06042010).

Size of the sample was calculated based on clinical trials that evaluated the effects of zinc together with corticosteroids on the treatment of symptomatic OLP. According to Suvarna et al (4), patients treated with oral zinc 50 mg and 0.1% triamcinolone, the mean of the size of lesions was calculated to be 1.95 (0.22) at baseline and 0.3 (0.65) after 6 months. Therefore the lesion size after 12 weeks was estimated to be 1.12 (0.435). In the control group, the mean (SD) lesion size was 2.20 (0.79). Based on difference between two independent means using the highest SD, the least sample size was 10 patients per group, elevated to 11 patients to recompense for lost to follow up cases. Total sample = number per group x groups number = 11 x 2 = 22 patients. Software sample size was established on Rosner's method (12) and was measured by G*Power 3.1.9.7 (13).

Participants were randomly allocated into one of two groups proposed namely zinc with corticosteroids (test) and corticosteroids only (control) groups using the permuted block randomization technique (14). Allocation numbers were be in sealed envelopes and arranged sequentially by an independent examiner. Blinding was carried out by masking the type of intervention from the statistician, and biochemist, but blinding of the operators and patients was difficult due to the different doses and forms of the treatment in the two groups (15).

Inclusions criteria

Selected male and female participants were considered eligible if they had erosive OLP and above 25 years old (16). Diagnosis of OLP confirmed by an incisional biopsy that was taken under local anesthesia from the lesion.

Prior to recruitment for our clinical research, all the twenty-two allocated patients received topical corticosteroids as treatment and the outcomes weren't favorable in all of them.

Exclusion criteria

Patients were excluded being smokers, pregnant and lactating females (17).

Any patient presented with extra oral lichen planus lesions or with drug or lichenoid contact reactions was excluded (17).

Patients had history of cancer, kidney, liver or other autoimmune disease and those patients showed dysplastic changes in the confirmatory biopsy or had vitamin administration within the last 3 months were excluded (17).

Oral hygiene instructions explained for all participants and received phase I therapy (scaling,

root planning and removal of any sharp cusps or traumatized area) (18).

Intervention

The twenty two participants were randomly allocated into one of 2 groups

(A) Test group: received oral systemic zinc picolinate capsule 50mg (obtained from a pharmacy, (Now foods factory), (USA) (as a single dose, one to two hours before meals with a glass of water for optimal absorption for 6 consecutive weeks, in addition to application of topical corticosteroids 0.1% triamcinolone acetonide (TA) gel (obtained from a pharmacy, (Bristol-Myers Squibb company), (USA) twice daily for 6 consecutive weeks (4).

(B) Control group: was instructed to use corticosteroids 0.1% TA gel for topical application twice daily for 6 consecutive weeks (16).

Saliva was collected before and after 12 weeks of the treatment. All participants expectorated around 5 ml of saliva sample in a clean glass for approximately 5 minutes that shouldn't be tinged with blood (19).

Saliva samples were collected into eppendorfs and given sequential number of each corresponding patients, then were sent to the laboratory of the Medical Biochemistry Department at Faculty of Medicine, Alexandria University, Egypt, on the same day of its collection, and were stored at -80°C till biochemical analysis then transferred into clean tubes then centrifuged at 3,000 for 5 minutes to remove any cellular debris (17).

Assessment of clinical outcomes

A) Assessment of primary outcomes

1. Subjective assessment

Numerical rating scale was performed for pain and discomfort assessment at the three periods in each group (baseline, 6 and 12 weeks). Patients were instructed to register a number indicating the severity of their burning sensation on a standard level from zero to ten, with score zero being pain free and ten being the worst pain sensation (20).

2. Objective assessment

Objective assessment of the oral lesion was conducted at baseline, after 6 and 12 weeks of treatment, according to Thongprasom et al scoring system (21). Measurement of the outcomes were assigned by scores:

Score 5: patients having white striae with erosive areas $>1\text{ cm}^2$. (Fig.1).

Score 4: patients with white striae and erosive areas $<1\text{ cm}^2$.

Score 3: patients have white striae and atrophic areas $>1\text{ cm}^2$.

Score 2: patients have white striae and atrophic areas $<1\text{ cm}^2$.

Score 1: patients have only white striae.

Score 0: patients have normal mucosa.

B) Assessment of secondary outcomes

Biochemical assessment was performed by measuring salivary matrix metalloproteinase -9 enzyme levels at the baseline and after 12 weeks from baseline, using Enzyme-Linked Immunosorbent Assay (ELISA) kit, purchased from Shanghai Korain Biotech (Office, Shanghai, China) (22).

All forms, samples and standard solutions prepared and brought to room temperature before use. Matrix metalloproteinase-9(MMP-9) presents in the sample was added and bound to antibodies coated on the wells. And then biotinylated Human MMP-9 Antibody was added and bound to MMP-9 in the sample. Then Streptavidin-HRP was added and bound to the Biotinylated MMP-9 antibody. After incubation unbound Streptavidin-HRP was washed away during a washing step. Substrate solution was then added and color developed in proportion to the amount of Human MMP-9. The reaction was terminated by addition of acidic stop solution and absorbance was measured at 450 nm (22).

Statistical analysis

Data were fed to the computer and analyzed using IBM SPSS software package version 20.0. (Armonk, NY: IBM Corp) (23). Qualitative data were described using number and percent. The Kolmogorov-Smirnov test was used to verify the normality of distribution. Quantitative data were described using range (minimum and maximum), mean, standard deviation, median and interquartile range (IQR). Significance of the obtained results was judged at the 5% level. Comparison between the variables between the two groups at each point of time was done using T-test when the variable was normally distributed and Mann-Whitney U test when the variable was not normally distributed. Comparing between different time points in each group separately was done using repeated measures ANOVA for normally distributed variables and Friedman test for non-normally distributed variables, and both were followed with multiple pairwise comparisons (24).

RESULTS

All patients completed the study. The most involved site was buccal mucosa. Neither patients taking topical corticosteroids alone nor ones taking zinc along with topical corticosteroids showed adverse effects.

Table 1 represents pain assessment using NRS. There was no significant difference between the two studied groups at baseline, after 6 and 12 weeks of treatment ($P>0.05$). However, the test group showed a significant reduction in the mean score values of NRS after 6 and 12 weeks of treatment (p value= 0.014 and 0.003 respectively). (Fig.2) While, the control group revealed no statistical significant reduction in the mean score values of NRS after 6 and 12 weeks ($p=0.214$).

Table 2 shows Thongprasom et al score evaluation of the oral lesions. There was no statistical significant difference between both groups at

baseline, and at both the six and 12 weeks. However, the test group showed a significant reduction in the mean score values of Thongprasom et al score after 6 weeks ($P=0.025$). (Fig.3, Fig.4).Whereas, the control group revealed no statistical significant reduction in the lesion score after 6 and 12 weeks ($P=.529$).

Table 3 shows results of biochemical assessment of MMP-9. There was no statistical significant difference between both groups at baseline and after 12 weeks. However, the test group revealed a statistical significant reduction in MMP9 levels from the baseline to weeks 12(P value 0.026) as compared to the control group ($P=0.083$).

Fig. 5 shows comparison between the three studied periods according to lesion size (surface area). There was no significant difference between both groups.

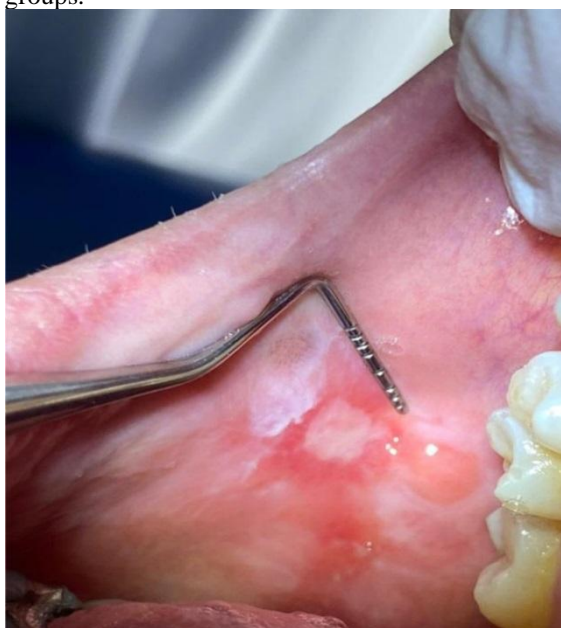

Figure (1): Measurement of clinical lesion size at base line and after 6 and 12weeks of treatment using Calibrated pro dental probe. (length* width) size of lesion >1 cm² and given score 5 according to Thongprasom et al scoring system.

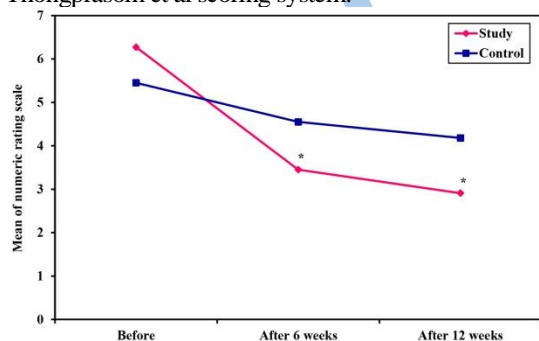


Figure (2): Comparison between the three studied periods according to numeric rating scale. Significant reduction in mean score values of NRS *: from baseline to weeks 6 and from base line to weeks 12 in the test (study) group.

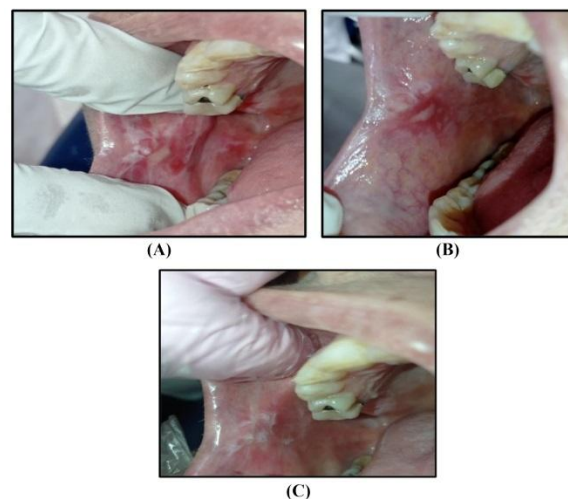


Figure (3): Case 1: OLP lesions changes along all assessment times in a case of the zinc group (A-C). A. Baseline assessment revealing ulcerative lesion surrounded by white striations of the right buccal mucosa. B. 6weeks follow up showing improvement of the degree of redness and reduction of striations. C. 12 weeks follow up showing almost complete resolution of the ulcer.

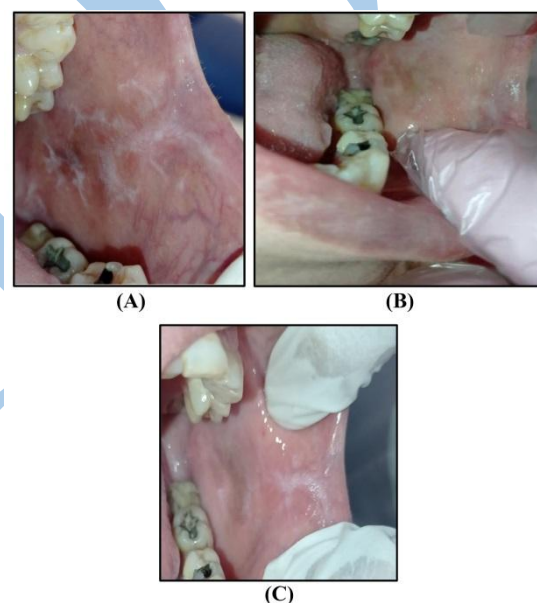


Figure (4): Case 2: in a case of the zinc group (A-C). A. Baseline assessment revealing atrophic lesion surrounded by white striations of the left buccal mucosa. B. 6 weeks follow up showing improvement of the degree of redness and reduction of striations. C. 12 weeks follow up showing almost complete resolution of the lesion.

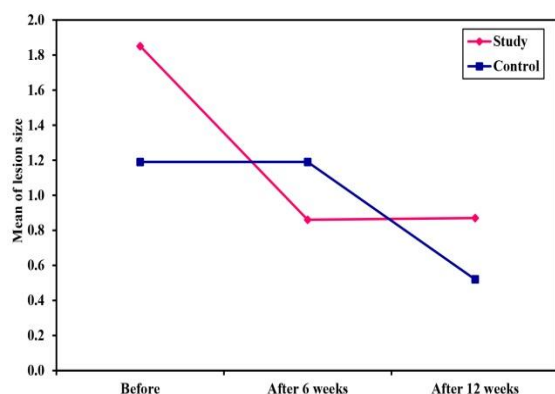


Figure (5): Comparison between the three studied periods according to lesion size (surface area) showed no significant difference between the 2 groups.

No statistical significant reduction in the mean value of lesion size (surface area) after 6 weeks and 12 weeks in the test (study) group and the control group.

Table (1): Comparison between the two groups according to numeric rating scale

Numeric rating scale	test (n = 11)	Control (n = 11)	U	p
Before				
Min. – Max.	3.0 – 9.0	3.0 – 9.0		
Mean ± SD.	6.27 ± 2.24	5.45 ± 2.21	48.00	0.438
Median (IQR)	8.0 (4.0 – 8.0)	5.0 (3.5 – 7.5)		
After 6 weeks				
Min. – Max.	1.0 – 6.0	2.0 – 8.0	44.0	0.300
Mean ± SD.	3.45 ± 1.57	4.55 ± 2.3.		
Median (IQR)	3.0 (2.5 – 4.0)	4.0 (2.5 – 7.0)		
After 12 weeks				
Min. – Max.	1.0 – 7.0	2.0 – 7.0	35.50	0.101
Mean ± SD.	2.91 ± 1.92	4.18 ± 1.83		
Median (IQR)	2.0 (2.0 – 3.0)	4.0 (2.5 – 5.0)		
Fr	11.436*	3.081		
p₀	0.003*	0.214		
p₁	0.014*			
p₂	0.003*			
p₃	0.594			

IQR: Inter quartile range SD: Standard deviation U: Mann Whitney test

Fr: Friedman test, Sig. bet. periods was done using Post Hoc Test (Dunn's)

p: p value for comparing between the two studied groups

p₀: p value for comparing between the three periods in each group

p₁: p value for comparing between **Before** and **After 6 weeks**

p₂: p value for comparing between **Before** and **After 12 weeks**

p₃: p value for comparing between **After 6 weeks** and **After 12 weeks**

*: Statistically significant at $p \leq 0.05$

Table (2): Comparison between the two groups according to Thongprasom et al score

Thongprasom et al	Test (n = 11)	Control (n = 11)	U	p
Before				
Min. – Max.	3.0 – 5.0	2.0 – 5.0		
Mean ± SD.	4.09 ± 1.04	3.18 ± 1.25	34.0	0.060
Median (IQR)	5.0 (3.0 – 5.0)	3.0 (2.0 – 4.0)		
After 6 weeks				
Min. – Max.	2.0 – 5.0	2.0 – 5.0	54.5	0.673
Mean ± SD.	2.82 ± 1.08	2.91 ± 0.94	0	
Median (IQR)	2.0 (2.0 – 3.50)	3.0 (2.0 – 3.0)		
After 12 weeks				
Min. – Max.	2.0 – 5.0	2.0 – 5.0	58.0	0.860
Mean ± SD.	2.82 ± 0.98	2.91 ± 1.04		
Median (IQR)	3.0 (2.0 – 3.0)	3.0 (2.0 – 3.5)		
Change (from baseline to 12th weeks)				
Min. – Max.	-1.0 – 3.0	-1.0 – 1.0	31.5	0.056
Mean ± SD.	1.27 ± 1.27	0.27 ± 0.79	0	
Median (IQR)	1.0 (0.50 – 2.0)	0.0 (0.0 – 1.0)		
Fr	8.400*	1.273		
p₀	0.015*	0.529		
p₁	0.025*			
p₂	0.253			
p₃	1.000			

IQR: Inter quartile range SD: Standard deviation U: Mann Whitney test

Fr: Friedman test, Sig. bet. periods was done using Post Hoc Test (Dunn's)

p: p value for comparing between the two studied groups

p₀: p value for comparing between the three periods in each group

p₁: p value for comparing between **Before** and **After 6 weeks**

p₂: p value for comparing between **Before** and **After 12 weeks**

p₃: p value for comparing between **After 6 weeks** and **After 12 weeks**

*: Statistically significant at $p \leq 0.05$

Table (3): Comparison between the two studied groups according to Matrix metalloprotease 9

Matrix metalloprotease 9	Test (n = 11)	Control (n = 11)	Test of sig.	p
Before				
Min. – Max.	1.66–2.42	1.45 – 2.38		
Mean ± SD.	2.03 ± 0.21	1.85 ± 0.30	t=1.658	0.113
Median (IQR)	2.09 (1.93 – 2.12)	1.912 (1.58 – 2.05)		
After 3 months				
Min. – Max.	1.33 – 2.42	0.65 – 2.22	t=1.113	0.282
Mean ± SD.	1.77 ± 0.11	1.54 ± 0.60		
Median (IQR)	1.83 (1.37 – 2.12)	1.74 (0.82 – 2.07)		
t_p	2.607*	1.924		
p₀	0.026*	0.083		

IQR: Inter quartile range SD: Standard deviation t: Student t test

t_p: t- paired test

p: p value for comparing between the two studied groups

po: p value for comparing between baseline and after 12 weeks

*: Statistically significant at $p \leq 0.05$

DISCUSSION

Oral Lichen planus is an autoimmune disorder that has long been discussed because of its variant pathogenesis and treatments. Conventional therapeutic modalities of OLP disease include corticosteroids (topical or systemic) are considered the first line of defense working to modulate inflammation and immune response. In nowadays clinical practice, other treatment options have been of vital consideration for OLP patients rather than the corticosteroids which are associated with secondary candidiasis as an adverse effect (25). The efficacy of the oral zinc supplement combined with topical corticosteroids, as one of these treatment options, has been documented in many studies aimed to treat oral LP disease (26,27). In our research, comprehensive results were obtained contributing to the wealth of knowledge on this topic, not only from the clinical assessment of disease activity and pain intensity following topical corticosteroid and zinc use. In addition, our results concluded significant decrease in level of salivary biomarker matrix metallo proteinase-9 enzyme indicating that oral zinc therapy was adjunctive in reducing inflammation in OLP disease.

Zinc is an essential micro nutrient, and has important and critical functions in collagen synthesis and gene expression (28). And zinc deficiency is related to multiple physiological abnormalities, and involves in oral mucosal diseases (OMD) pathogenesis, for example; atrophic glossitis, xerostomia, burning mouth syndrome (BMS) and OLP. These results have been obtained in China by Bao et al (29) in a study that aimed to measure average serum zinc levels in 368 individuals have OMD, and to compare these to healthy individuals. The author reported that the mean value of zinc levels in all patients had any of OMD was significant less than that of the healthy controls (29).

In Oral lichen planus disease, the immune system is intensely affected by zinc (Zn) deficiency such as disturbances of function, development and polarization of T-lymphocytes. Gholizadeh et al (30) noted that there was a statistical significant difference between erosive oral lichen planus (EOLP) and non EOLP in the mean value of serum Zn level, and concluded that serum zinc deficiency may be attributed to dysregulation of lymphocytic reactions (30). So zinc resupplementation is considerable, but when zinc supplements are consumed in large quantities and long term, they may have negative effects such as flu-like symptoms, vomiting, diarrhea and nausea and can cause copper deficiency (7).

Oral zinc supplement used in the present study (zinc picolinate capsule 50mg) was selected in accordance to a clinical trial that compared between different oral supplementation of zinc (equivalent to 50 mg zinc per day), and suggested that complexing zinc with picolinic acid within human body can improve Zn absorption (7). The length of treatment and the study design followed were inconsistent with the above mentioned trial, and were based on an other clinical trial that aimed to evaluate the efficacy of adding systemic oral zinc acetate 30mg supplementation to topical corticosteroids for 6 weeks as an adjuvant to topical corticosteroids therapy in OLP patients (27).

After 6 and 12 weeks in our study, the test group revealed a significant reduction in numerical rating scale (NRS) as compared to the control group that manifested as reduction of pain severity, lesions redness regression, and conversion of erosions into white striations or almost disappearance. The improvement in NRS in our study was in line with Suvarna et al (4) who evaluated the effectiveness of adding oral zinc acetate 50 mg to 0.1% triamcinolone orabase, and compared that with 0.1% triamcinolone orabase alone for the treatment of symptomatic OLP and found out that there was gradual decrease in the pain and burning sensation assessed by visual analogue scale (VAS). NRS reduction may be attributed to the fact that Zn has a potent anti-inflammatory effect and it is an integral necessary signal component for regulation of cell adhesion, tissue proliferation and remodeling, cellular-stress responses, and other physiological functions of cells. Moreover, Zn monitor metallothionein (MT), which is a powerful antioxidant protein (28). Besides, topical corticosteroids which are immune suppressive agents that inhibit phagocytic cells, and down regulate the cell-mediated immunity (25).

After 6 weeks and 12 weeks of treatment, there was no significant difference between the two groups in reduction of the lesion surface area. In contrast to Mehdipour et al (26) who compared the efficacy of combination of 0.2% zinc mouthwash together with fluocinolone and fluocinolone monotherapy in treatment of EOLP, and reported that combination was more significant in lesion size reduction along the trial. The reduction in the lesion size in above mentioned study may be attributed to that zinc mouthwash has more penetrance properties than the oral zinc supplement. Moreover, fluocinolone is more potent than triamcinolone in accelerating the healing, preserving stratum corneum integrity (26).

After 6 weeks, the test group in our study, showed a significant reduction in Thongprasom et al (21) score as compared to the control group. Moreover, there was no recurrence of lesions or burning sensation in both groups at follow up visits after stopping treatment. On contrary, a clinical study by Thomas et

al (31) who compared between the efficacy of clobetasol propionate in the topical formulation alone and clobetasol propionate together with zinc sulphate cream in the treatment of sub-acute and chronic eczema, lichen planus and limited psoriasis. The author reported that the rebound of diseases symptoms (erythema, pain and lichenification) was higher in the group received 0.05% Clobetasol propionate the topical cream formulation alone (31). Positive results of zinc administration in the present study provide an evidence that Zn has a role in host immunomodulation through variable anti-inflammatory mechanisms. More over, zinc can recognize major histocompatibility complex (MHC) and can regulate production of pro inflammatory cytokines (32).

Animal studies demonstrated that 0.3 mg/cm² zinc oxide (ZnO) cream promotes epithelialization by enhancing endogenous growth factors (EGF) and enzymes important for epithelial proliferation and migration. Similarly, Baroni et al (33), in a previous clinical study, evaluated several pharmacological therapeutic modalities for modulation of the profibrotic activity of dermal fibroblasts. The author reported that ZnO in the topical formulation had a significant role in induction of profibrotic mediators production (33).

Dysregulated matrix metalloproteinase enzymes under pathological conditions cooperate to achieve effective extracellular matrix (ECM) degradation and many compounds of the basal membrane leading to increase inflammations, cleavage of collagen especially type IV, keratinocytes apoptosis, and intra-epithelial cells migration leading to OLP disease (34,35).

Several studies have reported over expression of MMP-9 levels within the inflammation found in OLP tissue (36). Fathi et al (37) aimed at evaluating the function of salivary MMP-9 as a biomarker in 20 patients have various forms of OLP, the author concluded that salivary MMP-9 could be a reliable biomarker that may predict and diagnose OLP (37). In accordance with Chen et al (38) who reported that immunoscore of MMPs in atrophic oral lichen planus was significantly more than non atrophic oral lichen planus (38).

Regarding biochemical measurement of salivary MMP-9 levels, the test group revealed significant more reduction of salivary MMP-9 levels after 12 weeks of treatment as compared to the control group. Clear reduction in MMP-9 levels after Zn administration is a reflection of decreased inflammation and oxidative stress (34). Proteolysis and inhibition of MMP-9 are mainly regulated by endogenous inhibitors action called tissue inhibitors of metalloproteinases (TIMPs) (35). Accordingly, our results support that Zn is a co-factor for MMPs-9 through protection of the sensitive cleavage sites of basement membrane and arranging MMP-9

activation inhibition imbalance in the treatment EOLP (34). Similarly, it has been evidenced by Shahzad (39) who aimed to realize a relation between zinc level adjustment and MMP-9 transcription and expression and noted that Zn deficiency increases the activity of MMPs (39).

In the present clinical trial, in the test group, there was strong correlation between NRS and lesion surface area at the base line, however after 12 weeks of treatment, this correlation became weak and not significant, that may be due to treatment modalities of OLP disease result in symptoms resolution and relieve rather than lesions remission (40).

In the present study, the results provided an evidence that Zn combined with topical corticosteroids has optimistic therapeutic effects in the treatment of EOLP with no adverse effects. The strength of this study is that, it didn't depend on clinical examination of disease activity and pain severity, but it depended on measurement of the lesion surface area, and biochemical assessment of salivary biomarker MMP-9 levels providing comprehensive outcomes.

The study had some limitations; further clinical trials with longer follow up and larger sample size are needed. Furthermore, clinical trials contrasting the effectiveness of other forms and doses of Zn are also required. Therapeutic effects of Zn must be conducted by on other forms of lichen planus disease especially that show dysplastic changes. In addition, there is a need for conducting a blinded approach of the operators and patients to avoid any possible chance of bias.

CONCLUSIONS

Oral systemic zinc supplement combined with topical corticosteroids has promising therapeutic effects in the treatment of patients with EOLP with no adverse effects or lesion recurrence throughout the clinical trial. Salivary MMP-9 levels are biomarkers of inflammation and oxidation that can be significantly reduced by the potent anti-inflammatory effects of zinc.

CONFLICT OF INTEREST

The authors declare that they have no conflicts of interest.

FUNDING STATEMENT

The authors received no specific funding for this work.

REFERENCES

1. Eisen D. The clinical features, malignant potential, and systemic associations of oral lichen planus: a study of 723 patients. *J Am Acad Dermatol.* 2002;46:207-14.
2. Sugerman PB, Savage NW, Walsh LJ, Zhao ZZ, Zhou XJ, Khan A, et al. The pathogenesis of oral lichen planus. *Crit Rev Oral Biol Med.* 2002;13:350-65.
3. Qataya PO, Elsayed NM, Elguindy NM, Ahmed Hafiz M, Samy WM. Selenium: A sole

- treatment for erosive oral lichen planus (Randomized controlled clinical trial). *Oral Dis.* 2020;26:789-804.
4. Suvama C, Chaitanya NC, Ameer S, Mannava H, Bontala P, Alyami JS, et al. A Comparative Evaluation on the Effect of Oral Zinc 50 mg with or without 0.1% Triamcinolone Orabase on Oral Lichen Planus. *Int J Appl Basic Med Res.* 2020;10:54-8.
 5. Sanna A, Firinu D, Zavattari P, Valera P. Zinc Status and Autoimmunity: A Systematic Review and Meta-Analysis. *Nutrients.* 2018;10:68.
 6. Capdor J, Foster M, Petocz P, Samman S. Zinc and glycemic control: a meta-analysis of randomised placebo controlled supplementation trials in humans. *J Trace Elem Med Biol.* 2013;27:137-42.
 7. Healthline. Zinc Supplements: Benefits, Dosage, and Side Effects: Healthline. Available at: <https://www.healthline.com/nutrition/zinc-supplements>.
 8. Fong LY, Zhang L, Jiang Y, Farber JL. Dietary zinc modulation of COX-2 expression and lingual and esophageal carcinogenesis in rats. *J Natl Cancer Inst.* 2005;97:40-50.
 9. Moher D, Hopewell S, Schulz KF, Montori V, Gøtzsche PC, Devereaux PJ, et al. CONSORT 2010 explanation and elaboration: updated guidelines for reporting parallel group randomised trials. *Int J Surg.* 2012;10:28-55.
 10. Rotaru DI, Sofineti D, Bolboacă SD, Bulboacă AE. Diagnostic Criteria of Oral Lichen Planus: A Narrative Review. *Acta Clin Croat.* 2020;59:513-22.
 11. World Medical Association. World Medical Association Declaration of Helsinki: ethical principles for medical research involving human subjects. *JAMA.* 2013;310:2191-4.
 12. Rosner B. *Fundamentals of Biostatistics.* 8th ed. Boston, MA: Cengage Learning; 2015.
 13. Faul F, Erdfelder E, Lang AG, Buchner A. G*power for windows (version 3.1.9.7) (computer software) Germany: Heinrich-Heine-Universität Düsseldorf (HHU); 2020. Available at: <https://www.psychologie.hhu.de/arbeitsgruppen/allgemeine-psychologie-und-arbeitspsychologie/gpower>.
 14. Schulz KF, Grimes DA. Generation of allocation sequences in randomised trials: chance, not choice. *Lancet.* 2002;359:515-9.
 15. Karanicolas PJ, Farrokhyar F, Bhandari M. Blinding: who, what, when, why, how? *Can J Surg.* 2010;53:345-8.
 16. Malik U, Gupta S, Malik SD, Vashishth S, Zaheeruddin, Raju MS. Treatment of symptomatic oral lichen planus (OLP) with 0.1% tacrolimus powder in Oraguard-B - A pilot prospective study. *Saudi Dent J.* 2012;24:143-8.
 17. Eita AAB, Zaki AM, Mahmoud SA. Serum 8-isoprostane levels in patients with resistant oral lichen planus before and after treatment with lycopene: a randomized clinical trial. *BMC Oral Health.* 2021;21:343.
 18. Salgado DS, Jeremias F, Capela MV, Onofre MA, Massucato EM, Orrico SR. Plaque control improves the painful symptoms of oral lichen planus gingival lesions. A short-term study. *J Oral Pathol Med.* 2013;42:728-32.
 19. Kamodyová N, Baňasová L, Janšáková K, Koborová I, Tóthová L, Stanko P, et al. Blood Contamination in Saliva: Impact on the Measurement of Salivary Oxidative Stress Markers. *Dis Markers.* 2015;2015:479251.
 20. Kaliakatsou F, Hodgson TA, Lewsey JD, Hegarty AM, Murphy AG, Porter SR. Management of recalcitrant ulcerative oral lichen planus with topical tacrolimus. *J Am Acad Dermatol.* 2002;46:35-41.
 21. Thongprasom K, Luengvisut P, Wongwatanakij A, Boonjatturus C. Clinical evaluation in treatment of oral lichen planus with topical fluocinolone acetonide: a 2-year follow-up. *J Oral Pathol Med.* 2003;32:315-22.
 22. Cheng XC, Fang H, Xu WF. Advances in assays of matrix metalloproteinases (MMPs) and their inhibitors. *J Enzyme Inhib Med Chem.* 2008;23:154-67.
 23. IBM SPSS Statistics 20.0 Release Notes: IBM Support. Available at: <https://www.ibm.com/support/pages/ibm-spss-statistics-200-release-notes>.
 24. Field A. *Discovering Statistics Using IBM SPSS Statistics.* 4th ed. London: SAGE Publications; 2013.
 25. Eisen D, Carrozzo M, Bagan Sebastian JV, Thongprasom K. Number 5 Oral lichen planus: clinical features and management. *Oral Dis.* 2005;11:338-49.
 26. Mehdi-pour M, Taghavi Zenouz A, Bahramian A, Yazdani J, Pouralibab F, Sadr K. Comparison of the Effect of Mouthwashes with and without Zinc and Fluocinolone on the Healing Process of Erosive Oral Lichen Planus. *J Dent Res Dent Clin Dent Prospects.* 2010;4:25-8.
 27. National Library of Medicine. Effect of Oral Zinc Supplementation as an Adjuvant to Topical Corticosteroid in Oral Lichen Planus Patients: National Library of Medicine. 2020. Available at: <https://clinicaltrials.gov/study/NCT04278599?tab=results>.
 28. Chasapis CT, Loutsidou AC, Spiliopoulou CA, Stefanidou ME. Zinc and human health: an update. *Arch Toxicol.* 2012;86:521-34.
 29. Bao ZX, Yang XW, Shi J, Liu LX. Serum zinc levels in 368 patients with oral mucosal diseases: A preliminary study. *Med Oral Patol Oral Cir Bucal.* 2016;21:e335-40.

30. Gholizadeh N, Mehdipour M, Najafi S, Bahramian A, Garjani S, Khoeini Poorfar H. Evaluation of the serum zinc level in erosive and non-erosive oral lichen planus. *J Dent (Shiraz)*. 2014;15:52-6.
31. Thomas J, Kandhari S, Oberoi C, Jayaseelan E, Raj KY. A double - blind randomised multicentre controlled study of topical 0.05% clobetasol propionate with 2.5% zinc sulphate preparation. *Indian J Dermatol Venereol Leprol*. 2001;67:135-7.
32. Jarosz M, Olbert M, Wyszogrodzka G, Młyniec K, Librowski T. Antioxidant and anti-inflammatory effects of zinc. Zinc-dependent NF- κ B signaling. *Inflammopharmacology*. 2017;25:11-24.
33. Baroni A, Perfetto B, Buttini G, Catalanotti P, Gorga F, Tufano MA. Topical amikacin formulation induces fibroblast growth factor and cytokine release from human dermal fibroblasts. *Arch Dermatol Res*. 1999;291:296-9.
34. Nosrati R, Kheirouri S, Ghodsi R, Ojaghi H. The effects of zinc treatment on matrix metalloproteinases: A systematic review. *J Trace Elem Med Biol*. 2019;56:107-15.
35. Zhou XJ, Sugerman PB, Savage NW, Walsh LJ. Matrix metalloproteinases and their inhibitors in oral lichen planus. *J Cutan Pathol*. 2001;28:72-82.
36. Paulusová V, Laco J, Drízhál I, Slezák R. Expression of matrix metalloproteinase 9 in patients with oral lichen planus. *Acta Medica (Hradec Kralove)*. 2012;55:23-6.
37. Fathi MS, El Dessouky HF, Breni HA. CD4+CD25+ T regulatory cells and MMP-9 as diagnostic salivary biomarkers in oral lichen planus. *Egypt J Immunol*. 2013;20:39-53.
38. Chen Y, Zhang W, Geng N, Tian K, Jack Windsor L. MMPs, TIMP-2, and TGF-beta1 in the cancerization of oral lichen planus. *Head Neck*. 2008;30:1237-45.
39. Shahzad A, Rink L, Wessels I. Regulation of matrix metalloproteinase-9 during monopoiesis and zinc deficiency by chromatin remodeling. *J Trace Elem Med Biol*. 2023;78:127162.
40. Kaplan I, Ventura-Sharabi Y, Gal G, Calderon S, Anavi Y. The dynamics of oral lichen planus: a retrospective clinicopathological study. *Head Neck Pathol*. 2012;6:178-83.