

EVALUATION OF USING 3D INTERLOCKING MINIPLATES FOR FIXATION OF MANDIBULAR FRACTURES IN THE MENTAL FORAMEN REGION

(A CLINICAL AND RADIOGRAPHIC STUDY)

Ibrahim M. Abdelhamed^{1*} BDS, Abdelaziz F. Khalil² PhD, Yehia A. El-Mahallawy³ PhD

ABSTRACT

INTRODUCTION: Mandibular fractures are considered one of the most common types of trauma encountered by oral and maxillofacial surgeons. Fractures involving the mental nerve region represent about 9 % - 57 % of mandibular fractures. Conventional 3D plates cannot be used in this area due to the presence of the mental nerve. 3D interlocking miniplates were designed for fixation of fractures in the aforementioned region without interfering with the neurovascular bundle.

AIM OF THIS STUDY: To evaluate the efficiency of 3D interlocking miniplates for fixation of mandibular fracture in mental foramen region.

MATERIALS AND METHODS: Eight patients with recent mandibular fracture at the mental foramen region are to be treated using 3D interlocking miniplates. Clinical follow up was done after 24-hours, one, four, six and twelve weeks. Clinical assessment parameters included postoperative occlusion, interfragmentary mobility and sensory nerve function. In addition, a radiographic investigation was performed after twelve weeks to measure the mean bone density and healing across the fracture line.

RESULTS: Upon the completion of the follow-up phase, all patients showed satisfactory occlusion and no interfragmentary mobility. Upon radiographic assessment, all fractures showed proper healing and the difference in mean bone density between baseline and final values was statistically significant.

CONCLUSION: 3D interlocking mini plates can provide satisfactory clinical and radiographic outcomes in the treatment of mandibular fractures at mental foramen region without injuring the neurovascular bundle.

KEYWORDS: 3D interlocking miniplates, Mandibular fracture, Mental nerve

RUNNING TITLE: 3D interlocking plates in parasymphseal-body fractures.

1 -Instructor of Oral and Maxillofacial Surgery, Faculty of Dentistry, Alexandria University.

2 -Professor of Oral and Maxillofacial Surgery, Faculty of Pharmacy, Alexandria University.

3 -Lecturer of Oral and Maxillofacial Surgery, Faculty of Dentistry, Alexandria University.

**Corresponding author:*

ibrahim.mohamed.dent@alexu.edu.eg

INTRODUCTION

Mandibular fractures are some of the most prevalent injuries to the facial bones due to their location, mobility, and prominence⁽¹⁾. The leading causes of mandibular fractures are vehicular incidents and physical assaults. Additional contributing factors include occupational accidents, falls, and sports-related injuries⁽²⁾.

There are two transition zones in the mandible: the anterior one is where the parasymphysis meets the body. This area corresponds to the lower canine roots' outlines⁽³⁾. Since the mental nerve is located in this transition zone, mental nerve paresthesia is one of the most frequent postoperative consequences following reduction of the broken segment at this zone⁽⁴⁾.

When treating mandibular fractures, it is critical to restore occlusion, temporomandibular function, and facial appearance⁽⁵⁾. Mandibular fracture treatment techniques have advanced

substantially during the past few decades. The techniques used include closed reduction with maxillomandibular fixation (MMF), open reduction with wire osteosynthesis, and open reduction with rigid internal fixation or adaptive miniplate fixation⁽⁶⁾.

Michelet et al. introduced the use of readily flexible, non-compression mini plates inserted trans-orally and attached with monocortical screws in 1973⁽⁷⁾. Champy and his colleagues later improved on this approach, introducing the optimal line of osteosynthesis⁽⁸⁾.

The current procedure is to fix fractures in the transition zone with two mini-plates, one subapical and the other at the lower border. Although it shows sufficient stability of the fractured segments in many cases, it can lead to paresthesia of the mental nerve⁽⁹⁾. Mini plates support fractures in two dimensions, which may result in insufficient stabilization in the load-

bearing area, prompting the creation of 3D plates. The compact shape and quadrangular geometry of 3D plates provide three-dimensional stability which counteracts torsional stresses, especially in the mental foramen region.⁽¹⁰⁾

3D plates were shown to be superior to miniplates in the parasymphysis region; but still, in cases of fracture around the mental foramen region, these plates cannot be placed without damaging the neurovascular bundle⁽¹¹⁾. In order to solve the limitation associated with 3D plates in the mental foramen region, a system of interlocking 3D miniplates (VAS 3D bone plate) was developed. These improvised miniplates operated on the principle of 3D geometry and could be utilized in the mental foramen region without injuring the mental nerve⁽¹²⁾.

AIM OF THE STUDY

To evaluate the use of 3D interlocking miniplates for fixation of mandibular fractures in the mental foramen region.

1. Primary objective: Evaluation of bone density across the fracture line by using CBCT.

1. Secondary objective: Clinical evaluation including pain, interfragmentary stability, wound healing and sensory nerve function

MATERIALS AND METHODS

This study was a prospective clinical study, that was performed after gaining ethical clearance from the Research Ethics Committee, Faculty of Dentistry, Alexandria University.

Patients

Eight patients were selected from the Emergency Ward of Alexandria University Teaching Hospital in the period between January 2023 and January 2024 and were operated upon in the Oral and Maxillofacial Surgery Department, Faculty of Dentistry, Alexandria University. Only adult patients 18 years old or above with no gender predilections, suffering from recent, uninfected, non-comminuted mandibular parasymphyseal-body fractures that demand open reduction and internal fixation were included in the study. The exclusion criteria were medically compromised patients contradicting operation (ASA III, IV & V), patients receiving radiotherapy or chemotherapy, the existence of infection at the fracture line, pathological fractures, and old fractures. An informed consent was signed by all the patients after explaining all the procedures including all benefits and side effects in a simple and easy way.

Sample size estimation

Sample size was estimated assuming 5% alpha error and 80% study power. According to Al-Tairi et al.⁽¹³⁾ The mean (SD) bone density was 683.37 (86.63) HU preoperatively and 1003.25 (151.12) HU after 3 months. Based on difference between dependent means using the highest

SD=151.12 to ensure enough study power, the sample size was calculated to be 6 patients. This was increased to 8 patients to make up for lost to follow up cases.

Sample size was based on Rosner's method calculated by G*Power 3.1.9.7.⁽¹⁴⁾

Materials

3D interlocking miniplates (designed by *Arab engineer's co.*) consisted of two separate plates: a 1.5-mm thick U-shaped plate and a linear plate which can attach to U plate (figure 1). The superior ends of the tissue surface of the U-shaped plate had circular recess, in which the round elevations present on the ends of the bone surface of the linear plate would snugly fit (Fig. 2a). The length of the vertical bar of U-shaped plate is 6–9 mm. Both the plates achieve geometry similar to standard 3D plates after fixation of screws and give three-dimensional stability to the segment without injury to mental nerve (Fig. 2b).

Methods

Preoperative assessment

Complete personal data was obtained, along with the circumstances of the traumatic event, like cause, time, place, and type of assault. Past medical and dental history were recorded for patients, along with a full appraisal of the general state of health. Patients were examined extra orally for detection of any swelling, facial deformity, bleeding, ecchymosis, jaw deviation during function, and soft tissue laceration, and intraorally for detection of the presence of bleeding, lingual hematoma, buccal ecchymosis, malocclusion, midline shift, and teeth integrity was also examined. Palpation was done extra orally for the assessment of any step deformity, tenderness, bony crepitus, condylar movements during opening and closing, and altered lip sensation, and intraorally for the presence of tenderness or alteration in contour. Bimanual manipulation of the mandible on either side of the suspected fracture was done to detect any abnormal segment mobility and tenderness. Mental nerve innervation was compared with the opposite side to conclude the presence of anesthesia or paresthesia. A vitality test was done for teeth in the fracture line.

Surgical phase

Prophylactic antibiotic therapy was administered preoperatively in the form of Cefotaxime 1 gm/12 hours (Cefotax, E.I.P.I.C.O, Egypt) intravenously to prevent postoperative infection. All of the patients underwent open reduction and internal fixation of mandibular fractures under general anesthesia administered through naso-endotracheal intubation. The surgical field was scrubbed with povidone-iodine surgical scrub solution (Betadine 7.5%; Purdue Products L.P), followed by draping of the patient with sterile towels exposing only the area of surgery a vestibular, curvilinear incision was placed through the mucosa 8–10 mm from the

mucogingival junction extending from lateral incisor/canine to first molar region. After incising the mentalis muscle, subperiosteal dissection and skeletonization of nerve were carried out. This was followed by mobilization of the fracture, removal of any soft tissue entrapped within the fracture line, and management of teeth in the fracture line either by extraction or preservation. Intermaxillary fixation (IMF) was temporarily secured to provide proper occlusion that served as a guide for fracture reduction. The bone was then reduced into proper anatomical occlusion and the reduction was confirmed visually by verifying the alignment of the buccal cortex and inferior border. For the fixation of 3D interlocking miniplates, initially the U-shaped plate was placed around fracture site and adjusted such a way that vertical bars were parallel to the fracture line. Screws of 9 mm at the inferior border of the U-shaped plate were placed first on both sides of fracture line to secure the plate and then, upper horizontal plate was placed over U-shaped plate in subapical region and secured with 7 mm screws (figure 3). After assessment of occlusion, meticulous closure was performed.

Post-operative phase:

All patients received intravenous Cefotax 1 g/12 h for one day postoperatively followed by oral antibiotics in the form of Amoxicillin + Clavulanic acid (Augmentin 1gm; GlaxoSmithKline, UK) twice daily for 5–7 days after discharge. Analgesic and anti-inflammatory medication in the form of diclofenac potassium 50 mg tablets (Cataflam 50 mg, Novartis, Switzerland) was given every 8 hours for five days, and the patients were instructed to follow a soft diet for one month along with careful oral hygiene.

Follow-up phase

Clinical evaluation:

A postoperative clinical assessment was executed after 24 hours, one week, two weeks, four weeks, six weeks, and twelve weeks. A postoperative clinical evaluation for the interfragmentary mobility, the state of occlusion and mental nerve paresthesia was performed.

Sensory nerve function was evaluated in this study using two methods: subjective test, which depends on the patient's sensation of paresthesia. Objective test (pinprick test) using a sharp probe that touches the patient's mucosa at the site of the mental foramen, and the patient should feel pain if the nerve is not affected.

Radiographic evaluation:

A postoperative radiographic evaluation was performed using an immediate postoperative CBCT scan to assess the adequacy of fracture line reduction (figure 4a), then another scan was taken after 12 weeks to show the healing progression and estimate the mean bone density at the fracture line in comparison to the immediate postoperative scan (figure 4b).

Statistical analysis.

Data were fed to the computer and analyzed using IBM SPSS software package version 20.0. (Armonk, NY: IBM Corp) Qualitative data were described using number and percent. The Shapiro-Wilk test was used to verify the normality of distribution. Quantitative data were described using range (minimum and maximum), mean, standard deviation, median. Significance of the obtained results was judged at the 5% level.

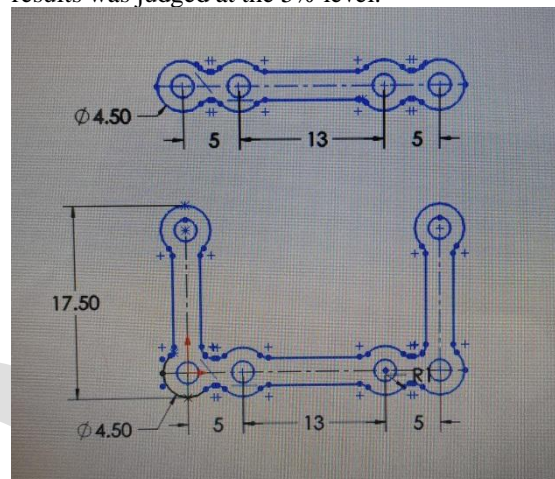


Figure 1. 3D interlocking miniplate design.




Figure 2. A. 3D interlocking miniplate before assembly, B. Plate after assembly.

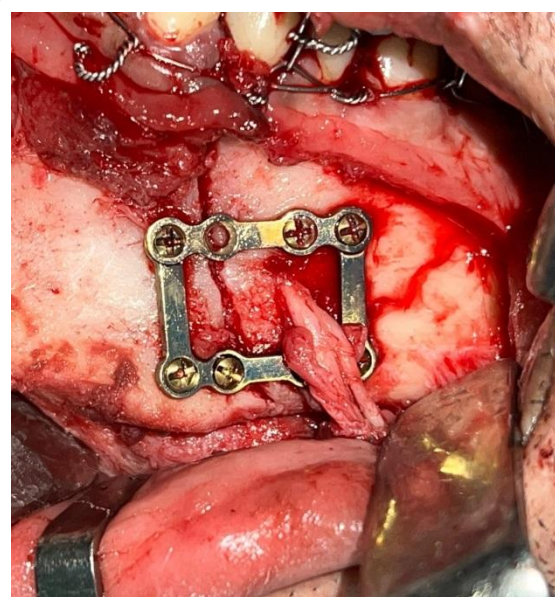


Figure 3. 3D interlocking miniplate in place.

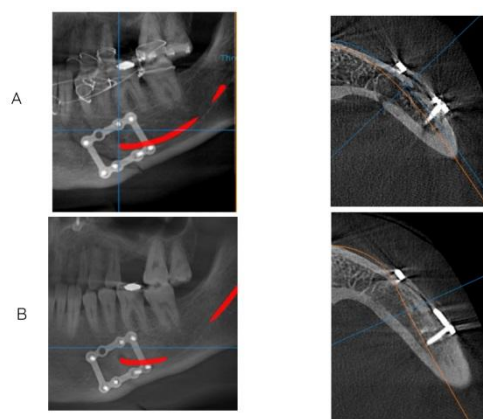


Figure 4. A. Immediate postoperative CBCT scan, B. CBCT after 3 months

RESULTS

The study was conducted on 8 patients with 9 parasymphyseal fractures as one patient had a bilateral fracture, while five patients had had left mandibular fractures and two patients had right mandibular fracture. The study population age ranged from 18 - 45 years with a mean value of 29.13 ± 9.08 years old. The male to female ratio was 7:1. Road traffic accident was the most prevailing fracture etiological factor ($n=6$), which is followed by claimed falls and Inter-personal violence with one patient each.

Regarding the clinical date, patients were monitored clinically for 6 weeks postoperatively. Postoperative reported pain value showed a statistically significant decrease across the follow-up period ($P<0.001$). All of the cases were assessed bimannually for mobility across the fracture line, and none of the fracture lines reported any noticeable interfragmentary mobility. The occlusal examination showed a normal occlusal and intercusp relation in all of the cases and none of the cases required any sort of selective grinding or occlusal modification.

In the first postoperative week, one fracture line suffered from wound dehiscence. The sutured wound was open and purulent exudate was seen oozing from the wound. This patient was managed with microbial swab and culture for specific antibiotic administration. Also wound irrigation and debridement was performed each other day. The bacterial culture swab showed no specific bacterial or fungal isolation and empirical antibiotic was continued for further 5 days. By the end of the second postoperative week, the sutured wound showed improved healing with no any oozing discharge. Complete healing of the affected wound was achieved by the end of the third postoperative week. The remaining 8 fracture lines showed uneventful healing

Concerning the sensory nerve paresthesia results, 7 cases felt numbness immediate postoperatively. In the fourth postoperative week, only two cases were still complaining of

numbness. Only one case suffered from numbness until the 12th week. The change of the subjective test across time was statistically significant p -value <0.0001 .

Radiographic assessment was performed in this study by an immediate postoperative CBCT to assess the accuracy of the reduction of the fracture. This was followed by another scan at the 12th postoperative week for bone healing across the fracture line assessment. The mean immediate postoperative bone density was 805.7 ± 73.48 HU, while the mean bone density after twelve weeks was 1108.4 ± 101.0 HU. The difference between these values was found to be statistically significant ($p<0.001$) (Table 1) (Figure 5).

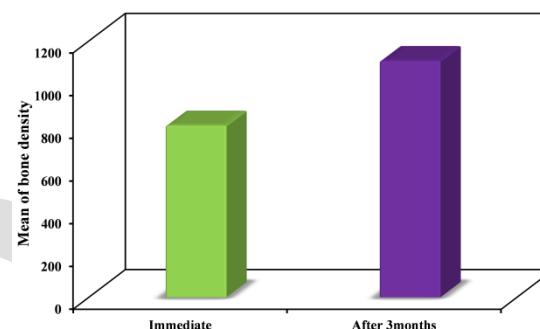


Figure 5. Graph showing the radiographic evaluation of the mean bone density across the fracture line.

Table 1. Descriptive analysis of the mean bone density values in Hounsfield Unit (HU) throughout the follow-up period.

Radiographic evaluation of bone density (HU)	Immediate postoperative	After 3 months	p
Min. – Max.	680.9 – 904.2	995.5 – 1286.4	<0.001*
Mean \pm SD.	805.7 ± 73.48	1108.4 ± 101.0	
Median	801.7	1089.4	

SD: Standard deviation

p: p value for comparing between the studied periods

*: Statistically significant at $p \leq 0.05$

DISCUSSION

When compared to other parts of the jaw, mandibular fractures at the mental foramen region remain among the most difficult to treat, even with the great advancements in procedures for fixating maxillofacial fractures. This is due to the excessive stresses at this area mainly torsional forces and the possibility of mental nerve injury. This demonstrates the importance of maintaining postoperative stability in this location by rigid fixation⁽¹⁵⁾

Fractures in the transition zone are currently fixed utilizing two mini-plates, one positioned subapically and the other at the lower border. While it frequently shows adequate stability of the fractured segments, it has a tendency to cause paresthesia of the mental nerve⁽¹⁶⁾. The use of 3D plates in the parasymphysis region has been demonstrated to be superior to miniplates. Nevertheless, when confronted with oblique or body fractures in and around the mental foramen, Using these plates is hazardous to the neurovascular bundle⁽¹¹⁾

A system of interlocking 3D miniplates was devised to address the limitation that was previously observed with 3D plates in the mental foramen region. Utilizing the principle of three-dimensional geometry, these improvised miniplates could be positioned in the mental foramen region without causing injury to the mental nerve.⁽¹²⁾

Through a twelve-week postoperative follow-up period, patients were assessed for interfragmentary mobility, postoperative occlusion, mental nerve paresthesia, and estimated bone density at the line of fracture

There was a gender predilection in this study, with a male to female ratio of 7:1, which agrees with other studies⁽¹⁷⁾. The explanation for this higher male ratio may be that men are more exposed to RTA as the percentage of males who ride vehicles and motorcycles is higher than females.

The Etiology of the trauma for 75.5% of the cases included in this study was R.T.A. This finding agrees with other studies from developing countries⁽¹⁸⁾. This high incidence of R.T.A. may result from the spread of motorcycles. The elevated rate can be attributed to the rise in their usage, particularly among the adolescent demographic, which is accompanied by reckless driving and a lack of obedience to traffic regulations and safety protocols. . Kamel et al.⁽¹⁹⁾ too found that 76.5% of the 196 mandibular fracture cases involved in his study were caused by RTAs while 13% were caused by inter personal violence.

During the follow-up period, the Visual Analogue Scale (VAS) score for the degree of pain intensity decreased for all patients. At 24 hours postoperative follow-up, the mean score was 5.11 ± 2.30 , which corresponds to the initial level of subjective pain perception as moderate to severe. While the average score during the initial week following the procedure was 3.11 ± 2.30 , The reduction in pain exhibited a statistically significant decline beginning in the fourth week when compared to the 24-hour postoperative follow-up. This could be attributed to the functional stabilization that the 3d interlocking miniplate offered, which enabled unrestricted movement of the mandible. Consistent with previous researches,

these findings indicate that pain intensity diminishes over time when proper bone fixation is achieved.⁽²⁰⁾

The Etiology of the trauma for six the cases included in this study was RTA while one was due to fall or violence . This finding agrees with other studies from developing countries⁽²¹⁾ This high incidence of RTA may result from the sudden spread of motorcycles and the lack of following the traffic rules.

After the operation, none of the patients had interfragmentary mobility. This was consistent with the findings of Xue et al. ⁽²²⁾, who demonstrated that, in comparison to miniplates, three-dimensional plates indicated superior initial interfragmentary stability. In comparison to previous plating procedures used in mandibular fractures, the 3D strut plate design has a more favorable biomechanical behavior, according to a biomechanical research by Alkan et al. ⁽²³⁾. This is because, instead of placing screws in a linear configuration on either side of the fracture line, a box-shaped arrangement creates wide platform that may improve the plate's ability to withstand torsional forces, leading to improved interfragmentary stability⁽²⁴⁾. Initial mobility was observed in 40% and 10% of cases involving conventional and 3D plates, respectively, following mandibular fracture management, as reported by Vineeth et al., However, all cases in this study exhibited stable fractures after one month. In contrast to linear plates, this comes to the conclusion that three-dimensional plates provide early primary stability.

In terms of the postoperative occlusion, every patient had an acceptable one. This is consistent with the literature, which revealed occlusal derangement between 0 to 20% in investigations using 3D plates⁽¹¹⁾. The superior stability of the fractured segments, which is a result of the plate's three-dimensional design, contributes to this stable occlusion. according to Barde et al.⁽²⁵⁾ post operative occlusion is better in cases treated by 3d plates then cases treated by conventional miniplates.

Sensory nerve function was evaluated in this study using two methods: subjective test, which depends on the patient's sensation of paresthesia. Objective test (pinprick test) using a sharp probe that touches the patient's mucosa at the site of the mental foramen, and the patient should feel pain if the nerve is not affected. Concerning the subjective test results, 7 cases felt numbness immediate postoperatively. In the fourth postoperative week, only two cases were still complaining of numbness. Only one case suffered from numbness until the 12th week. The change of the subjective test across time was statistically significant p-value <0.0001.

The outcomes of the objective test mirrored those of the subjective test. The paresthesia observed may be attributable to soft tissue edema or the stretching of tissues that occurred during the operation. It comes in Accordance to Thapliyal et al.⁽¹²⁾, only one case had numbness after the 12 weeks.

Nerve damage can occur as a result of two main causes: initial trauma during flap retraction and exposure during surgery, or manipulation of fracture segments. It is crucial to provide a detailed description of the neurological condition prior to surgery to prevent unjustified claims; it is not possible to rule out the possibility that nerve manipulation during surgery caused or exacerbated the neurological injury.

Reducing the incidence of iatrogenic injury of the mental nerve is possible through skeletonization of the nerve to its three separate terminal branches to allow for a better retraction and visibility, also implantation of plates above or below the canal and screw placement away from the mandibular canal.

Concerning wound dehiscence, By the 12th Week of the postoperative period, one case still had wound dehiscence as this patient was a smoker and had very bad oral hygiene. The change of wound dehiscence across time was a statistically significant p-value (0.001). This comes in accordance to Sarepally et al.⁽²⁶⁾ 12.5 % of cases showed wound dehiscence when using 2.0mm Two-Dimensional Mini-plates in mandibular fractures.

As reported by Liu et al.⁽²⁷⁾, the occurrence of wound dehiscence, malocclusion, and hardware failure, was considerably decreased in three-dimensional plates in comparison to miniplates. Postoperative complications such as screw loosening and plate breakage were not found in this study. However, intra-oral screw exposure was observed in one patient following a three-month follow-up period. One potential explanation is an increase in thickness at the superior end, which may be the result of the straight and U-shaped segments overlapping just below the line of incision. The case which had screw exposure was advised to remove the plates after the osseous union of the fractured segments.

An elevated occurrence of infection was documented by Cheng et al.⁽²⁸⁾ when the duration of surgery exceeded 4–6 hours. In the current study, the 3D interlocking plates necessitated a longer duration for fixation in comparison to the miniplates. One potential explanation for the relatively extended duration of the procedure is that the surgeon displayed more caution in positioning and adjusting the U-shaped plate around the mental nerve in order to preserve the neurovascular bundle. With respect to the radiographic evaluation, the immediate postoperative radiographs yielded a

mean value of 805.7 ± 73.48 HU. After 12 weeks the mean was 1108.4 ± 101.0 HU. The change in bone density is statistically significant, p-value <0.001 . The results obtained in this investigation align with those reported by ELNakeeb et al.⁽²⁹⁾ The researchers documented that the average bone density following three months of treatment with 3D plates for an anterior mandibular fracture was 1001.57 ± 243.78 HU after 12 weeks. This suggests that 3D interlocking miniplates can produce the same or better bone density across the fractured segments as the conventional 3D plates while preserving the neurovascular bundle in the mental foramen region.

We observed that the process of plate fixation was more challenging when 3D interlocking mini plates were utilized as opposed to conventional mini plates. Singh et al.⁽³⁰⁾ found that using 3D plates in fixation of fractures in the body and angle of the mandible was more difficult due to visibility, accessibility, drilling tool direction, and prevention of iatrogenic mental nerve injury. The present study shares similar results with the previously mentioned study regarding the ease of fixation.

Surgeons should be cautious when assessing the bone height and position of the mental foramen before the placement of 3D interlocking miniplates. Sufficient cortical bone height is necessary for the plate to be used. Inadequate bone is considered a limitation of the plate. Therefore, multiple plates with a variable of lengths of the U-shaped vertical bar (6–9mm) must be already fabricated before the operation. We choose the suitable plate according to bone height by studying the preoperative CT carefully, we should also put in our consideration the length and position of the roots in when choosing the length of the plate and drilling direction of screw holes.

CONCLUSION

Three-dimensional interlocking miniplates provide a satisfying clinical and radiographical outcome when used in fixation of mandibular fracture in the mental foramen region. This is due to the excellent resistance of torsional forces provided by the plate's three-dimensional design and the 1.5 mm thickness of the plate. The unique design of the plate allows its usage in this area where it was impossible to use a 3D plate without causing injury to the neurovascular bundle.

CONFLICT OF INTEREST

The authors declare that they have no conflict of interest.

REFERENCES

1. Kanala S, Gudipalli S, Perumalla P, Jagalanki K, Polamarasetty P, Guntaka S, et al. Aetiology, prevalence, fracture site and management of maxillofacial trauma. *The Annals of The Royal*

- College of Surgeons of England. 2021;103(1):18-22.
2. Abosadeh MM, Rahman SA. Epidemiology and incidence of traumatic head injury associated with maxillofacial fractures: A global perspective. *Journal of international oral health*. 2018;10(2):63-70.
3. Cornelius C-P, Audigé L, Kunz C, Prein J. The comprehensive AOCMF classification system: glossary of common terminology. *Craniomaxillofacial Trauma & Reconstruction*. 2014;7(1_suppl):136-40.
4. Shah NS, Panchal KV, Agrawal P. Prevalence of mental nerve injury in facial fractures: a 3 year retrospective study. *International Journal of Research in Medical Sciences*. 2019;7(12):4578.
5. Bohner L, Beiglboeck F, Schwitter S, Lustosa RM, Pieirna Marino Segura C, Kleinheinz J, et al. Treatment of mandible fractures using a miniplate system: A retrospective analysis. *Journal of Clinical Medicine*. 2020;9(09):2922.
6. Subramaniyan D, Sathyanarayanan R, Suresh V, Subramaniyan M, Guna TP. A comparative study evaluating the efficacy of 2.0-mm mini locking plate and 2.0-mm three-dimensional locking miniplates in mandibular angle fractures. *Formosan Journal of Surgery*. 2021;54(2):61-5.
7. Michelet FX, Deymes J, Dessus B. Osteosynthesis with miniaturized screwed plates in maxillo-facial surgery. *J Maxillofac Surg* 1973;1:79-84.
8. Champy M, Lodde J, Schmitt R, Jaeger J, Muster D. Mandibular osteosynthesis by miniature screwed plates via a buccal approach. *J Maxillofac Surg* 1978;6:14-21.
9. Mohd YQ, Reddy S, Sinha R, Agarwal A, Fatima U, Abidullah M. Three-dimensional miniplate: For the management of mandibular parasymphysis fractures. *Annals of maxillofacial surgery*. 2019;9(2):333.
10. Budhraj NJ, Shenoi RS, Badjate SJ, Bang KO, Ingole PD, Kolte VS. Three-dimensional locking plate and conventional miniplates in the treatment of mandibular anterior fractures. *Annals of maxillofacial surgery*. 2018;8(1):73.
11. Mittal Y, Varghese KG, Mohan S, Jayakumar N, Chhag S. A comparative study of 3-dimensional titanium versus 2-dimensional titanium miniplates for open reduction and fixation of mandibular parasymphysis fracture. *Journal of maxillofacial and oral surgery*. 2016;15:93-8.
12. Thapliyal S, Mowar A, Bansal V. Comparison between conventional titanium miniplates and indigenous detachable custom made 3D titanium plates (VAS 3D bone plate) for fixation of mandibular fracture in mental foramen region: a randomized clinical trial and finite element analysis. *Journal of Maxillofacial and Oral Surgery*. 2020:1-8.
13. Al-Tairi N, Shoushan M, Khedr MS, Abd-Alal S. Comparison of three-dimensional plate versus double miniplate osteosynthesis for treatment of unfavorable mandibular angle fractures. *Tanta Dent J*. 2015;12(2):89-98.
14. Rosner B. *Fundamentals of biostatistics*: Nelson Education. Nelson Education. 2015.
15. Kurakar M, Joshi U. Comparative study of miniplate vs reconstruction plate in the management of bilateral parasymphysis mandible fracture: FEM analysis. *Journal of Maxillofacial and Oral Surgery*. 2021:1-9.
16. Salavadi RK, Sinha R, Vadepally AK, Uppada UK. Comparative Evaluation of Conventional Miniplates, Three-Dimensional Miniplates and Lag Screws for Internal Fixation of Parasymphysis Fracture of Mandible—A Double-Blind Randomized Clinical Study. *Journal of Maxillofacial and Oral Surgery*. 2022:1-7.
17. Kabak SL, Zhuravleva NV, Melnichenko YM. Human mandible prenatal morphogenesis. *Journal of Morphological Sciences*. 2019;36(02):057-62.
18. Singaram M, G SV, Udhayakumar RK. Prevalence, pattern, etiology, and management of maxillofacial trauma in a developing country: a retrospective study. *Journal of the Korean Association of Oral and Maxillofacial Surgeons*. 2016;42(4):174-81.
19. Kamel M, Abd El Moniem N, Abdel AalHassanein F, Hassan S. Conventional 2.0 mm miniplates versus 3D miniplate in mandibular fracture fixation. *Al-Azhar Dental Journal for Girls*. 2016;3(4):325-30.
20. Helmy AM, El Prince NH, Fliefel RM. Computer-assisted surgery in management of mandibular fracture using a custom-made titanium mesh tray. *Alexandria Dental Journal*. 2020;45(3):44-8.
21. Singaram M, Udhayakumar RK. Prevalence, pattern, etiology, and management of maxillofacial trauma in a developing country: a retrospective study. *Journal of the Korean Association of Oral and Maxillofacial Surgeons*. 2016;42(4):174.
22. Xue AS, Koshy JC, Wolfswinkel EM, Weathers WM, Marsack KP, Hollier Jr LH. A prospective study of strut versus miniplate for fractures of mandibular angle. *Craniomaxillofacial Trauma & Reconstruction*. 2013;6(3):191-6.
23. Alkan A, Çelebi N, Özden B, Baş B, İnal S. Biomechanical comparison of different plating techniques in repair of mandibular angle fractures. *Oral Surgery, Oral Medicine, Oral Pathology, Oral Radiology, and Endodontology*. 2007;104(6):752-6.

24. Jain MK, Manjunath K, Bhagwan B, Shah DK. Comparison of 3-dimensional and standard miniplate fixation in the management of mandibular fractures. *Journal of oral and maxillofacial surgery*. 2010;68(7):1568-72.
25. Barde DH, Mudhol A, Ali FM, Madan R, Kar S, Ustaad F. Efficacy of 3-dimensional plates over Champys miniplates in mandibular anterior fractures. *Journal of international oral health: JIOH*. 2014;6(1):20.
26. Sarepally G, Seethamsetty S, Karpe T, Nasyam FA, Fatima U, Fatema R. A Comparative Evaluation of 2.0 mm Two-Dimensional Miniplates Versus 2.0 mm Three-Dimensional Miniplates in Mandibular Fractures. *Cureus*. 2022;14(1).
27. Liu Y, Wei B, Li Y, Gu D, Yin G, Wang B, et al. The 3-dimensional miniplate is more effective than the standard miniplate for the management of mandibular fractures: a meta-analysis. *European journal of medical research*. 2017;22:1-10.
28. Cheng H, Chen BP-H, Soleas IM, Ferko NC, Cameron CG, Hinoul P. Prolonged operative duration increases risk of surgical site infections: a systematic review. *Surgical infections*. 2017;18(6):722-35.
29. El Nakeeb NA, El Dibany MM, Shokry MM. A comparative study between 3-D plates and conventional miniplates for internal fixation of anterior mandibular fractures. *Alexandria Dental Journal*. 2016;41(3):253-60.
30. Singh A, Arunkumar K. Standard 3D titanium miniplate versus locking 3D miniplate in fracture of mandible: A prospective comparative study. *Journal of maxillofacial and oral surgery*. 2016;15:164-72.