

ORIGINAL ARTICLE

Intratonsillar Molecular Detection of some Herpesviruses with a Histopathological Study

¹Akeel A. Jassim*, ²Hayder A. Al-Hmudi, ²Maha K. Al-Mallak¹Basrah Directorate of Education, Ministry of Education, Iraq²College of Science, University of Basrah, Basrah, Iraq

ABSTRACT

Key words:**Tonsils, Tonsillectomy, EBV, HHV6, HHV7*****Corresponding Author:**Akeel A. Jassim
Basrah Directorate of
Education, Ministry of
Education, Iraq
mustafafadil837@gmail.com

Background: Recurrent tonsillitis (CT) is a parenchymal infection of the palatine tonsils that is identified based on clinical criteria, some studies show a close relation between viral infections and tonsillitis. **Objectives:** The aim of our study is to determine the prevalence of some human herpesviruses (HHV) including HHV-4, HHV-6 and HHV-7 using the multiplex polymerase chain reaction (mPCR) technique and to characterize the association between viruses and recurrent tonsillitis to evaluate the histopathological changes in tonsillar tissues among patients with tonsillitis. **Methodology:** A total of (100) samples from patients of Basrah general hospital during period (Sep. 2023 to Feb. 2024) from both sexes were collected after surgical interventions from (54) males and (46) females with age ranged (2-50) years with regard to clinical information and molecular detection and histopathological study. **Results:** Our results showed that EBV (HHV-4 DNA) was detected in 20% samples, while positive results of HHV-6 DNA was 16%, tonsillitis in children infected with HHV type 6 is characterized by a longer course of the disease, which leads to a longer hospital treatment and the age group (6-10) years was more infected than other age groups, and the tonsillitis was predominantly in males more than women, while HHV-7 DNA was not amplified. **Conclusion:** The current study concludes that the most common virus in the tonsils was EBV, then HHV6, with HHV7 not being diagnosed.

INTRODUCTION

The lymphatic Waldeyer's ring, which is thought to include the tonsils, acts as a barrier to prevent germs from entering the digestive and respiratory systems¹. Chronic or acute, tonsillitis is the most frequent microbially-induced inflammation of the palatine tonsils and is typically brought on by either bacteria or viruses². It is characterized by a sudden onset of typical clinical symptoms, such as sore throat (with or without difficulty in swallowing), tonsil enlargement (possibly with plaque), hyperemia, enlargement of cervical lymph nodes, fever, and generalized malaise. In 70–95% of cases, acute tonsillitis (AT) is caused by a viral infection, but bacterial pathogens can also cause tonsillar and pharyngeal inflammation in children in 15–30% of cases. The most frequently implicated bacteria in immunocompetent children are group A Streptococcus³. Few studies compared the craniofacial features of children with different locations of enlarged pharyngeal lymphoid tissue, which may be potential confounding factors. However, prior research generally ignored the different locations of adenoids and tonsils when analyzing the relationship between adenotonsillar hypertrophy and craniofacial morphology. Tonsillar hypertrophy (TH) is more frequently accompanied by obstructive sleep apnea and no symptoms of infection^{4,5}.

A tonsillectomy is one of the most common surgeries in ENT practice, especially for children, because of the high levels of lymphatic tissue and intense activity that occur during this time in their lives. Despite advancements in many medical specialties, upper respiratory tract infections like acute otitis media, acute sinusitis, sore throats, and tonsillar hypertrophy are very common conditions, and treating them accounts for a significant amount of healthcare expenses⁶. Approximately 75–95% of children experience acute sore throats due to viral infections, primarily respiratory viruses such as influenza, adenovirus, Coxsackie, and parainfluenza viruses. In 15–30% of instances, bacteria, including Streptococcus and Staphylococcus, are to blame⁷. Several studies indicate a strong correlation between tonsillitis and viral infections, with the Epstein-Barr virus (EBV) being one of the most common causes of both acute and recurring instances⁸. Human herpesviruses 6 (HHV6), 7 (HHV7), and Epstein-Barr virus (EBV) were the most often detected herpesviruses in tonsillar tissue, according to recently published research⁹. In recent years, many studies have been conducted in Basrah Governorate on the most important pathogenic medical viruses, as in the studies conducted by Shihab *et al.*¹⁰, Atbee *et al.*¹¹, Al-Salait *et al.*¹², Nasser and Al-Hmudi¹³, Almarjan *et al.*¹⁴ and Al-Asadi and Al-Mallak¹⁵. The current study was carried out to

detected HHV-4, HHV-6 and HHV-7 genetically, also include the objectives comprised the delineation of the relationship between the infection with HPV subtypes and clinical histopathological manifestations and demographic characteristics of the study groups.

METHODOLOGY

Subjects

The present study was conducted on the following study groups during the period from Sep. 2023 to Feb. 2024. A total of (100) samples from both sexes were collected after surgical interventions from 54 males and 46 females with age ranged (2-50) years.

Samples collection

Tonsillectomy tissues were collected during operations of tonsillectomy patients from Al-Basrah general hospital, the tissues specimens were divided into two parts, one of which was placed in fixation solution (formalin 10%) until used for histopathological study, and the other was placed in the dry tubes until used for

DNA extraction for molecular detection. The samples were transferred immediately to laboratory of the Microbiology \Virology of the Faculty of Science at Al-Basrah University and stored in freezing until using.

Molecular detection

Extraction of DNA

Viral DNA was extracted by using gSYNC™ DNA Extraction Kit according to company instructions with modification.

Conventional PCR

Purified DNA was amplified using specific primers according to Tanaka *et al.*¹⁶ study by using multiplex PCR (Table 1). Primer design was based on the DNA polymerase genes of human herpes viruses. The PCR condition was set as an initial denaturation step at 95 °C for 10 min, followed by 35 cycles of denaturation at 95 °C for 30 sec, annealing at 60 °C for 30 sec, and extension step at 72 °C for 30 sec with a final extension at 72 °C for 5 min. PCR products were visualized under a UV source on a 2% agarose gel.

Table (1) : Primer design of human herpes viruses

Viruses	Primer sequences	Product size (bp)
HHV-4	F:CTTAGAATGGTGGCCGGGCTGTAAAAT	229
	R: ATCCAGTACGTCTTTGTGGAGCCCAAG	
HHV-6	F: ATGCGCCATCATAATGCTCGGATACA	183
	R: CCCTGCATTCTTACGGAAGCAAAACG	
HHV-7	F: GCCCGTTTTTCGGAAATATTGGAGAGAT	347
	R: ACGCACGAGACGCACTTTTCTTAAACA	

Histopathological study

Palatine tonsils tissue biopsies were prepared for histological study according to Bancroft and Steven, 2012.

Statistical analysis

The data were analyzed using SSPS ver.1. The statistical significance of difference of data was assessed by chi square. p -values ≤ 0.05 were considered statistically significant.

RESULTS

Molecular detection

Out of 100 samples, EBV (HHV-4) DNA was detected in 20% samples, while positive results of HHV-6 DNA was 16% and HHV-7 DNA was not

amplified (Fig. 1). Results of EBV positive samples showed that there were no significant differences between males and females. The age groups with ages (6-10) years showed highly significant differences ($p<0.000$) to prone to the tonsillitis than other age groups. Regarding to type of tonsillitis, 16% were hypertrophic with highly significant differences ($p<0.000$), the distribution of patients based on residence, showed that 8% of the patients were from center of Basrah with highly significant differences ($p<0.000$) than other places. As for period of illness, the period of three year (9%) were the most periods of time that patients spent until tonsillectomy was performed with highly significant differences ($p<0.000$) than other periods (Table 2).

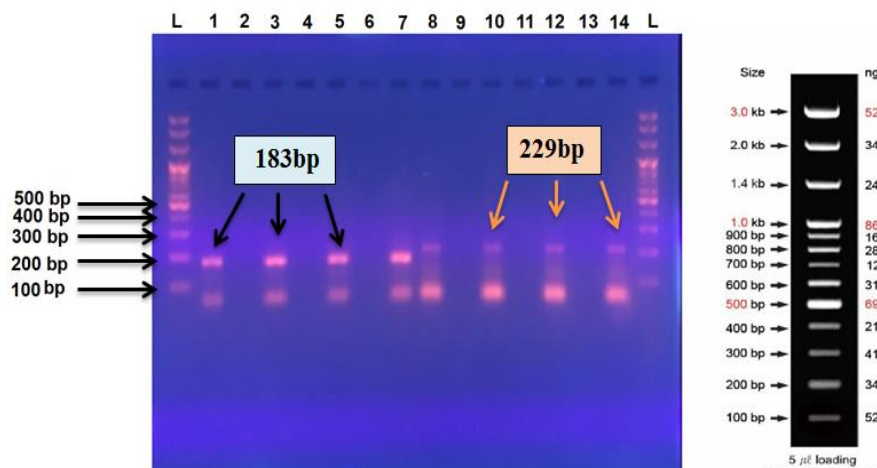


Fig. 1: Agarose gel electrophoresis of PCR products of EBV and HHV-6, Ladder = DNA ladder,, Lane 1,3,5,7 = HHV-6 positive samples (183bp), Lane 8,10,12,14 = EBV positive samples (229bp)

Table 2: Sex and age groups of positive HHV-4

Age groups	EBV+	Male	Female	Chronic	Hypertrophy	Residence					Period of illness			
						Center of Basrah	North of Basrah	South of Basrah	West of Basrah	East of Basrah	Three months	One year	Two years	Three years
≤5	3	2	1	1	2	2	0	0	0	1	1	1	0	1
6-10	8	5	3	3	5	4	2	1	0	1	0	4	2	2
11-20	3	1	2	1	2	0	1	0	1	1	0	1	0	2
21-30	3	0	3	1	2	0	2	1	0	0	0	0	0	3
31-40	1	1	0	0	1	1	0	0	0	0	0	0	1	0
41-50	2	1	1	0	2	1	0	0	0	1	0	0	1	1

p-value ≥ 0.05

In HHV-6 positive (Table 3), females 12% were more with significant ($p < 0.05$) than males 4%. The age groups with ages from (≤ 5 to 11-20) years showed highly significant differences ($p < 0.01$) more prone to tonsillitis than other age groups. Regarding to type of tonsillitis, 11% were hypertrophic with highly significant differences ($p < 0.01$). The distribution of

patients based on residence, showed that (10%) of the patients were from center of Basrah with highly significant differences ($p < 0.01$) than other places. As for period of illness, the period with years were the most periods of time that patients spent until tonsillectomy was performed with highly significant differences ($p < 0.01$) than other periods in months.

Table 3: Sex and age groups of positive HHV-6

Age groups	HHV-6 +	Male	Female	Chronic	Hypertrophy	Residence					Period of illness			
						Center of Basrah	North of Basrah	South of Basrah	West of Basrah	East of Basrah	Three months	One year	Two years	Three years
≤5	4	1	3	1	3	3	0	1	0	0	0	4	0	0
6-10	6	1	5	1	5	4	0	1	1	0	0	1	4	1
11-20	5	1	4	3	2	3	0	1	1	0	0	0	3	2
21-30	1	1	0	0	1	0	0	1	0	0	0	0	0	1
31-40	0	0	0	0	0	0	0	0	0	0	0	0	0	0
41-50	0	0	0	0	0	0	0	0	0	0	0	0	0	0

p-value ≥ 0.05

Histopathologic study

All sections related to palatine tonsils resected from patients with recurrent tonsillitis showed large lymphatic tissue, follicular hyperplasia, most lymph nodules with reactive germinal centers extend

occupying the sub epithelial tissue, variable cells some with dark stained nucleus known centro blast, (Tangible body) macrophages, lymphocytes and macrophages with apoptotic bodies, so the most common features were lymphoid tissue hyperplastic reaction (Fig. 2) .

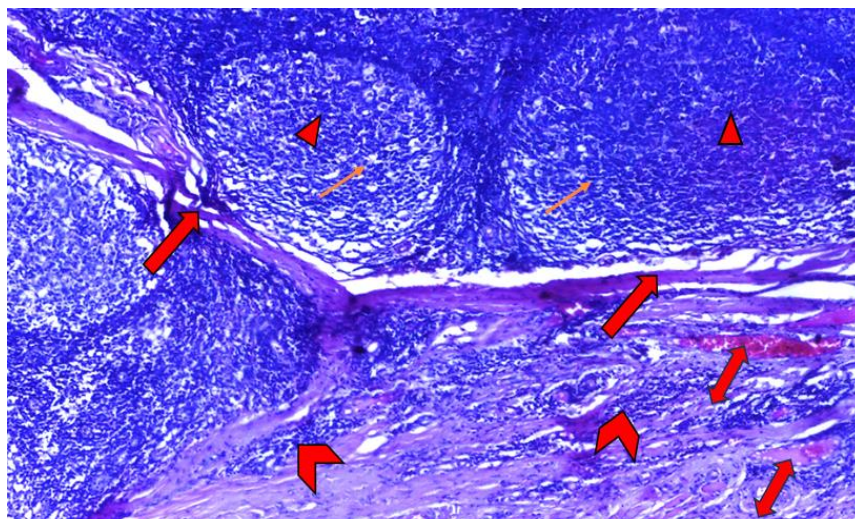


Fig (2) : Section in palatine tonsil showed lymphatic follicular hyperplasia (→), reactive germinal center (▲), the lymph nodules separated by bundles of collagen fibers (→), also congested blood vessels (↔) and accumulation of lymphatic tissue was observed (→). (H & E) stain (10X)

Microscopic findings revealed tonsillar hypertrophy characterized histologically by enlargement follicles, lymph nodes with dense cortex and hyperplastic abnormality in lymphoid cells within lymphoid follicles or non-specific lymphatic hyperplasia, also inter

follicular regions separated the follicles and composed of sub epithelial tissue from collagen fibers, endothelial congested venules, inflammatory cells acute focal suppurative inflammation and lesions formed within inter tonsillar crypts (Fig. 3).

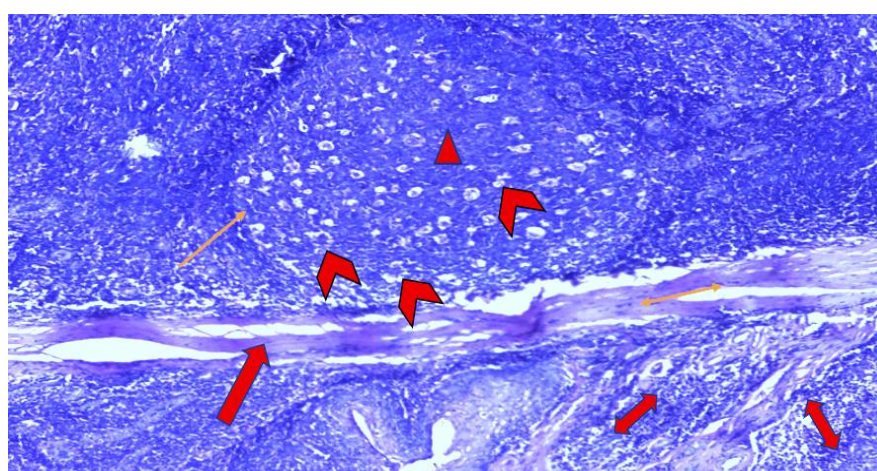


Fig (3) : Section in palatine tonsil showed large, active lymph node (→), reactive germinal centre (▲) with numerous macrophage (→), interfollicular region (→) showed strands of smooth muscle (→) and inflammatory cells (↔). (H&E) stain (40X)

Observations clarified that simple-unbranched tonsillar crypts appeared as blind invaginations covering epithelial surface surrounded by lymphatic tissue, the crypts lumen full with leukocytes and continue with stratified squamous epithelium and invagination hemi

capsule that carried congested blood vessels, fibroblast, plasma cells and lymphocytes, moreover the epithelial cells appeared with vacuolated cytoplasm and flat nucleus at the surface layer (Fig. 4).

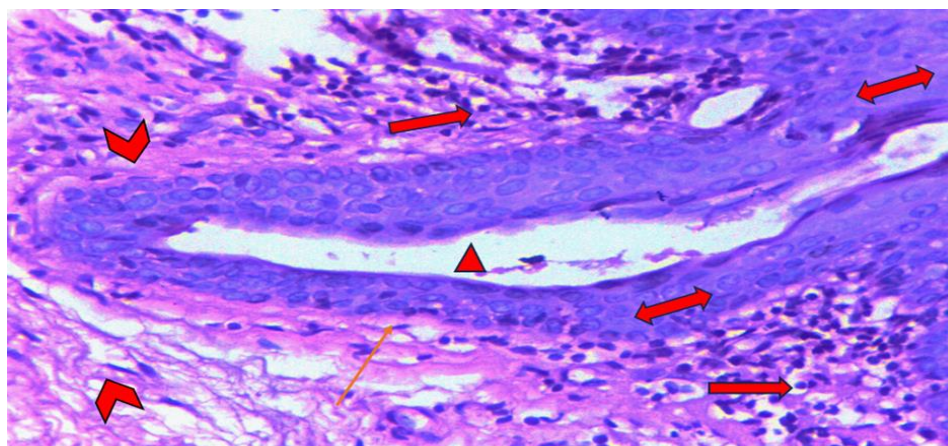







Fig (4) : Section from resected palatine tonsils showed single tonsillar crypt (), surrounded by epithelial tissue (), crypt invaginate the hemcapsule region (), crypt lumen () with debris , also collagen fibers extend beneath the crypt () . (H&E) . (40X)

Histopathological diagnosis on resected palatine tonsils revealed that tonsillar crypts system may be branched and extend deep as highly complicated canals with epithelium and with various structures surrounding

the canals like blood and lymphatic vessels and reactive germinal centers , this is known as complicated branch tonsillar crypts (Fig. 5) .

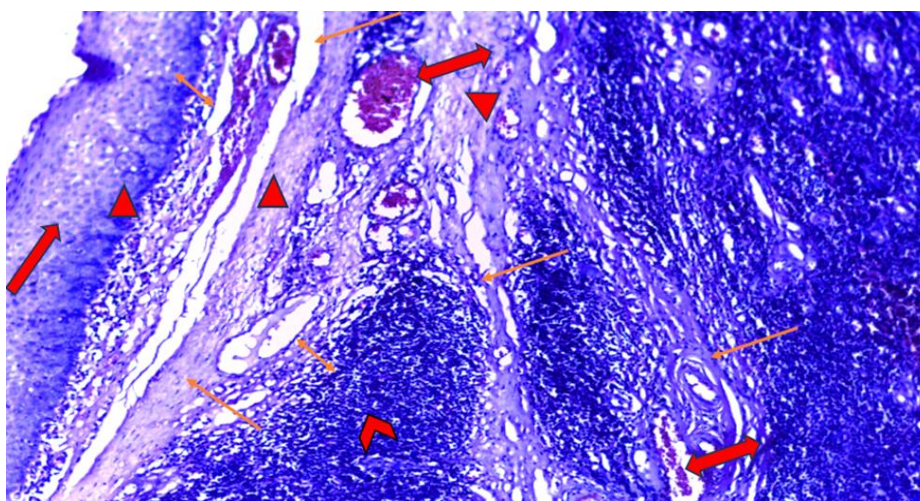








Fig (5) : Section in palatine tonsils showed complicated branched tonsillar crypts (), surrounded by epithelium () and congested blood vessels (), lymphatic vessels () and reactive germinal center (), the crypts continue with stratified nonkeratinized squamous epithelium () . (H&E) stain. (10X)

DISCUSSION

HHVs are known to cause a number of diseases and are one of the main human pathogens¹⁷. Out of 100 patients, the present study showed a successful amplification of 20% and 16% of EBV and HHV-6, respectively, but HHV-7 DNA was not amplified.

The current investigation demonstrated an independent correlation between chronic/recurrent tonsillitis and the presence of both EBV and HHV-6. found many HHVs in the same tonsil, which was only previously documented for young children¹⁸.

Regarding EBV, the tonsils may have become contaminated during the infectious mononucleosis infection, according to this study. Although it can strike at any age, infectious mononucleosis (IM), a viral infection primarily caused by the EBV, is a contagious illness that primarily affects adolescents and young adults. It is characterized by symptoms like fever, sore throat, swollen lymph nodes, and fatigue, which can sometimes last for several weeks. Although often regarded as a benign, self-limiting condition, it might result in severe, protracted side effects like hepatitis, splenic rupture, or neurological issues¹⁹. Numerous reports contend that EBV can colonize a child's tonsils and that it may play a direct or indirect part in recurrent tonsillitis and nasopharyngeal cancer^{20,21}.

Despite the fact that an EBV infection is linked to acute tonsillitis in infectious mononucleosis, no prior description of EBV's involvement in chronic or recurrent tonsillitis has been found. The local reactivation of latent EBV in this situation may result in chronic or recurrent tonsillitis. The possibility that some of the patients had a subclinical illness at the time of surgery is also a possibility, albeit a very remote one. Notably, our interpretation is predicated on a somewhat small patient population, and additional research is necessary to validate this conclusion. EBV DNA levels were higher in the B cell-enriched fraction from the tonsils that tested positive for EBV than in the T cell fraction²².

But according to some reports, tonsil tissue has a greater detection rate of EBV DNA than our study did. Of the 97 DNA samples taken from the tonsils of children, 46 (47.4%), or nearly half of the samples, tested positive for EBV. The incidence of EBV in our group is comparable to earlier findings in pediatric tonsils (40–53%)^{23,24}. A Japanese study found that 43% of children under 16 with tonsillar hypertrophy had the EBV genome in their tonsil tissue²⁵. Additionally, in earlier research was 73,3in Switzerland¹⁸, 58% Pai *et al.*²⁶ in Taiwan, 23% (Ivaska *et al.*)²⁴ in Finland and 64% (Niedobitek *et al.*)²⁷ in Germany; link between tonsillitis and the prevalence of EBV DNA. In by (Khabie *et al.*)²⁸ study, EBV DNA prevalence in tonsils was 11%, which is lower than what this study found.

These findings suggest possible regional differences in tonsillitis-related EBV prevalence.

The present study showed a successful amplification of 16% of HHV-6 DNA, this result appears to reflect a low spread of HHV-6. On palatine tonsils, mucocutaneous swabs, and cell plasma and CSF samples, the novel multiplex assay demonstrated exceptionally good performance. According to reports, the highest HHV geno prevalences for EBV are found in this lymphoid organ (20.4 to 88.8%), followed by HHV-7 (71.4%), HHV-6B (50.7%), HSV-1 (1.8 to 6.3%), and HCMV (0 to 5.4%)⁹. Also, in previous studies was 25%²⁹ in Italy, 16%³⁰ in Finland, and 45%²⁴ in Finland where there was association of HHV-6 DNA prevalence with tonsillitis.

The current investigation discovered that among patients over 30, who were diagnosed with chronic or recurrent tonsillitis, there were no positive results for HHV-6. Early childhood or adolescence is when most HHV-6 infections are contracted, and the initial infection may not cause any symptoms³¹. After the primary infection, HHV-6 may continue to exist in the host, for instance in the salivary glands and tonsillar tissue²⁹. We considered the likelihood of HHV-6 latency in the tonsils in light of the fact that HHV-6 is widely distributed, primarily infects lymphocytes, and that the tonsils are located anatomically and include members of the herpesviridae family. A small number of studies have suggested that tonsil tissues may contain HHV-6 in varying proportions. Despite its low level, one of them demonstrated that HHV6 DNA was found in all tonsil tissues³², the other paper showed a 77% positivity¹⁸.

Interestingly, the tonsil tissue in this study did not exhibit HHV-7 DNA amplification. This could be because of a lack of samples, a low viral titer, a mistake in DNA extraction, or the type of PCR used. The sensitivity would have been higher if real-time PCR had been employed. The virus most frequently found in tonsils was HHV7¹⁸. Similar to other herpesviruses, primary HHV-7 infections that are postponed into adolescence may result in more serious neurological disorders than those that happen in early childhood³³⁻³⁵. This is because, ironically, a better developed immune system's violent inflammatory reaction may result in more tissue damage. However, in immunocompromised persons (e.g., corticosteroids, chemotherapy, transplantation, HIV infection), the immune system's incapacity to locally restrict HHV-7 infection also predisposes patients to more severe neurological disorders³⁶. Tonsil tissues had substantially larger quantities of HHV6 and HHV7 virus DNA than adenoid tissues, with HHV7 being the most often found virus in tonsils. While our study supports previous findings on HHV7, it contradicts those about HHV6. The prevalence of HHV7 in tonsil brushings was quite close between males and females (73.3% vs. 69.6%) and

between adults and children (74.3% vs. 64.7%, respectively). In the sole study that is currently available by Berger *et al.*¹⁸. Molecular findings in some research a 53.6% Silvoniemi *et al.*³⁰ in Finland and 52% (Ivaska *et al.*)²⁴ in Finland but the present without result about HHV -7 used PCR detection. Also, in previous studies was 53.6% Silvoniemi *et al.*³⁰, 52% (Ivaska *et al.*)²⁴ correlation between tonsillitis and the incidence of HHV-7 DNA.

The majority of lymph nodules with reactive germinal centers spread out over the subepithelial tissue, and some of these cells have dark-stained nuclei called centroblasts, (Tangible body) macrophages, palatine tonsils, which were lymphoid tissue and responded to any inflammation by producing reactive lymph nodules linked to the growth of macrophages and lymphocytes, as well as lymphocytes. The most notable feature was the lymphoid tissue hyperplastic reactivity. The germinal center's presence signifies that the lymphoid follicle is very active in generating lymphocytes. Children are known to exhibit higher immunological activity and highly active germinal centers, whether or not they have acute or chronic infections³⁷.

Results showed the tonsillar hemorrhage and congested blood vessels with scarring tissue caused by the inflammation which cause increased blood flow to the tonsils and then necrosis or trauma of the congested blood vessels, also observations clarified that simple-unbranched tonsillar crypts appeared as blind invaginations of covering epithelial surface surrounded by lymphatic tissue, these crypts full with pus, inflammatory cells and debris.

Our studies in agreement with other studies showed that macrophages and other white blood cells are also concentrated by the tonsillar crypts in response to the microorganisms drawn to the crypts, and the extravasation of red blood cells from engorged tonsillar vasculature may cause diffuse parenchymal bleeding. The tonsillar crypts also act as a forward sentry for the immune system by exposing immune system cells to infectious organisms that may enter the body through food or other ingested matter³⁸.

Latent EBV infection cannot occur in normal pharyngeal epithelial cells, and EBV infection in normal epithelial cells typically causes growth arrest. EBV transmitted to epithelial cells is regarded as entering a lytic infection in nature³⁹.

CONCLUSION

Results of molecular techniques concluded with that this method has more specificity in diagnosis of (HHV) subtypes associated with acute and chronic are tonsillitis.

Ethical approval

All procedures performed in studies involving human participants were in accordance with the Ethical

Standards of the institutional and/or National Research Committee and with the 1964 Helsinki Declaration and its later amendments or comparable ethical standards. Informed consent was obtained from all individual participants involved in the study.

Declarations:

Consent for publication: Not applicable

Availability of data and material: Data are available upon request.

Competing interests: The author(s) declare no potential conflicts of interest with respect to the research, authorship and/or publication of this article. This manuscript has not been previously published and is not under consideration in another journal.

Funding: Authors did not receive any grants from funding agencies.

REFERENCES

1. Kostic M, Ivanov M, Babić S, Zvezdana Tepavčević, Radanović O, Soković M, et al. Analysis of Tonsil Tissues from Patients Diagnosed with Chronic Tonsillitis-Microbiological Profile, Biofilm-Forming Capacity and Histology. *Antibio* 2022;11(12):1747–1762.
2. Haidara AW, Sidibé Y, Samaké D, Coulibaly A, Touré MK, Coulibaly BB, et al. Tonsillitis and Their Complications: Epidemiological, Clinical and Therapeutic Profiles. *Inter J of Otolaryngo and H & Ne Sur* 2019;08(03):98–105.
3. Hunt IM, Kapur N, Windfuhr K, Robinson J, Bickley H, Flynn S, et al. Suicide in Schizophrenia: Findings from a National Clinical Survey. *J of Psych Pra* 2006;12(3):139–47.
4. Franco LP, Souki BQ, Cheib PL, Abrão M, Pereira TBJ, Becker HMG, et al. Are distinct etiologies of upper airway obstruction in mouth-breathing children associated with different cephalometric patterns?. *Inter J of Ped Otorhino* 2015;79(2):223–8.
5. Chen S, Wang WW, Wang Y, Li YQ, Zhu LX. Cellular senescence in recurrent tonsillitis and tonsillar hypertrophy in children. *Inter J of Ped Otorhino* 2020;133:110004.
6. Yamanaka N. Moving Towards a New Era in the Research of Tonsils and Mucosal Barriers. *Rec Advan in Ton and Muc Barr of the Upp Air* 2011;72:6–19.
7. Wi D, Choi SH. Positive Rate of Tests for Group A Streptococcus and Viral Features in Children with Acute Pharyngitis. *Child* 2021;8(7):599–607.
8. Endo LH, Ferreira D, Montenegro MCS, Pinto GA, Altemani A, Bortoleto AE, et al. Detection of Epstein-Barr virus in tonsillar tissue of children and

- the relationship with recurrent tonsillitis. *Inter J of Ped Otorhino* 2001;58(1):9–15.
9. Aboud Kourieh, Tarik Gheit, Tommasino M, Véronique Dalstein, Clifford GM, Lacau J, et al. Prevalence of human herpesviruses infections in nonmalignant tonsils: The SPLIT study. *J of Med Viro* 2018;91(4):687–97.
 10. SHIHAB SS, AL-HMUDI HA, AL-SALAIT SA. Serological and molecular detection of Epstein – Barr virus (EBV) in patients with malignant lymphoid solids. *Inter J of Pharma Res* 2020;12(02):2264–70.
 11. Atbee MAA, HMUDI H, Salait SKA. Molecular detection of human Parvovirus B19 in patients with hemoglobinopathies in Basrah province-Iraq. *Inter J of Pharma Res* 2020;12(02):2257–63.
 12. Al-Salait SK, Al-Atbee MA, Al-Hmudi HA. View of Unexpected Effect of Parvovirus B19 Infection on Hematological Parameters in Individuals with Normal Hemoglobin Variant. *Sci J of Med Res* 2021;5(18):59-61.
 13. Nasser K, Al-Hmudi H. The Molecular Prevalence of Torque Teno Virus (TTV) and SEN virus (SENV) in Hepatitis Patients and Blood Donors. *Tur J of Physio and Rehab* 2021;32(3):13416–31.
 14. Almarjan M, Hayder A, Al-Hmudi H, Habib H. WHOLE GENOME SEQUENCES OF LOCAL VARICELLA-ZOSTER VIRUS (VZV) STRAINS OF BASRAH CITY/IRAQ. *Tur J of Physio and Rehab* 2021;32(3):16094–103.
 15. Al-Asadi SYR, Al-Malak M K. Over expression of p16 ink4a associated with high grade lesions of (CIN) and cervical cancer (study applied on women infected with HPV in Basrah. Iraq). *Eur J of Biosci* 2020;14(1): 2079-2087.
 16. Tanaka T, Kogawa K, Sasa H, Nonoyama S, Furuya K, Sato K. Rapid and simultaneous detection of 6 types of human herpes virus (herpes simplex virus, varicella-zoster virus, Epstein-Barr virus, cytomegalovirus, human herpes virus 6A/B, and human herpes virus 7) by multiplex PCR assay. *Biomed Res* 2009;30(5):279–85.
 17. Boppana SB, Fowler KB. Persistence in the population: epidemiology and transmission. Nih.gov. Cambridge University Press; 2010 .
 18. Berger C, Hug M, Gysin C, Molinari L, Frei M, Bossart W, et al. Distribution patterns of β - and γ -herpesviruses within Waldeyer's ring organs. *J of Med Viro* 2007;79(8):1147–52.
 19. Sylvester JE, Buchanan BK, Silva TW. Infectious Mononucleosis: Rapid Evidence Review. *Amer Fam Phy* 2023;107(1):71–8.
 20. Rajesh BP, Chatterji M. “Bacterial or Viral” Is Age an Indicator in Acute Suppurative Tonsillitis. *JK Sci* 2008;10(4):37–44.
 21. Dias EP, da Rocha ML, de Oliveira Carvalho MO, da Fonte de Amorim LM. Detection of Epstein-Barr virus in recurrent tonsillitis. *Braz J of Otorhino* 2009;75(1):30–4.
 22. Hudnall SD, Ge Y, Wei L, Yang NP, Wang HQ, Chen T. Distribution and phenotype of Epstein–Barr virus-infected cells in human pharyngeal tonsils. *Mod Patho* 2005;18(4):519–27.
 23. Luis Renee Gonzalez-Lucano, Gabriela Vazquez Vasquez-Armenta, Ana Laura Pereira-Suárez, Arellano A, Santos, Lopez-Pulido EI. Prevalence of Epstein-Barr virus DNA in tonsillar tissue from patients with chronic tonsillitis in Mexican population. *The J of Infec in Dev Cou* 2019;13(08):764–7.
 24. Ivaska LE, Antti Silvoniemmi, Mikola E, Tuomo Puhakka, Waris M, Tytti Vuorinen, et al. Herpesvirus infections in adenoids in patients with chronic adenotonsillar disease. *J of Med Viro* 2022;94(9):4470–7.
 25. Seishima N, Kondo S, Wakisaka N, Kobayashi E, Imoto T, Moriyama-Kita M, et al. EBV infection is prevalent in the adenoid and palatine tonsils in adults. *J of Med Viro* 2016;89(6):1088–95.
 26. Pai PC, Tsang NM, Tseng CK, Hao SP, Kuo TT, Wei KC, et al. Prevalence of LMP-1 gene in tonsils and non-neoplastic nasopharynxes by nest-polymerase chain reaction in Taiwan. *Head & Neck* 2004;26(7):619–24.
 27. Niedobitek G, Herbst H, Young L, Brooks L, Masucci M, Crocker J, et al. Patterns of Epstein-Barr virus infection in non-neoplastic lymphoid tissue. *Blo* 1992;79(10):2520–6.
 28. Nissim Khabie, Savva A, Kasperbauer JL, McGovern R, Gostout B, Strome SE. Epstein-Barr Virus DNA Is Not Increased in Tonsillar Carcinoma. *The Laryngosco* 2001;111(5):811–4.
 29. Comar M, Domenico Leonardo Grasso, G. Dal Molin, Elisabetta Zocconi, Cesare Campello. HHV-6 infection of tonsils and adenoids in children with hypertrophy and upper airway recurrent infections. *Inter J of Ped Otorhino* 2010;74(1):47–9.
 30. Antti Silvoniemmi, Mikola E, Ivaska L, Marja Jeskanen, Eliisa Löyttyniemi, Tuomo Puhakka, et al. Intratonsillar detection of 27 distinct viruses: A cross-sectional study. *J of Med Viro* 2020;92(12):3830–8.
 31. ZERR DM. Human herpesvirus 6: a clinical update. *Her* 2006;13(1):20-24.
 32. Roush KS, Domiati-Saad RK, Margraf LR, Krisher K, Scheuermann RH, Rogers BB, et al. Prevalence and Cellular Reservoir of Latent Human Herpesvirus 6 in Tonsillar Lymphoid Tissue. *Amer*

- J of Clin Patho 2001;116(5):648–54.
33. Fay AJ, Noetzel MJ, Mar SS. Pediatric Hemorrhagic Brainstem Encephalitis Associated With HHV-7 Infection. *Ped Neuro* 2015;53(6):523–6.
 34. Foiadelli T, Rossi V, Paolucci S, Rovida F, Federica Novazzi, Orsini A, et al. Human Herpes Virus 7-related encephalopathy in children. *PubMed* 2022;92(S4):1–9.
 35. Christou E, Mastrogianni S, Bourousis E, Bachou T, Tsikrikas T, Mouskou S, et al. A case of seronegative autoimmune encephalitis associated with human herpesvirus-7 (HHV-7). *J of Med Viro* 2021;94(2):795–8.
 36. Escobar-Villalba A, Sainz de la Maza S, Pérez Torre P, Galán JC, Rodríguez-Domínguez M, Monreal Laguillo E, et al. Acute myelitis by human herpes virus 7 in an HIV-infected patient. *J of Clini Viro* 2016;77:63–5.
 37. Reis LGV, de Souza Almeida ÉC, da Silva JC, de Araújo Pereira G, de Fátima Barbosa V, Etchebehere RM. Tonsillar hyperplasia and recurrent tonsillitis: clinical-histological correlation. *Braz J of Otorhino* 2015;79(5):603–8.
 38. Fagö-Olsen H, Dines LM, Sørensen CH, Jensen A. The Adenoids but Not the Palatine Tonsils Serve as a Reservoir for Bacteria Associated with Secretory Otitis Media in Small Children. *mSys* 2019;4(1):1–17.
 39. Tsang CM, Deng W, Yip YL, Zeng MS, Lo KW, Tsao SW. EBV infection and persistence in nasopharyngeal epithelial cells. *Chin J of Can* 2014;33(11):549–55.