

# IJMA



## INTERNATIONAL JOURNAL OF MEDICAL ARTS

Volume 7, Issue 4 (April 2025)



<http://ijma.journals.ekb.eg/>


P-ISSN: 2636-4174

E-ISSN: 2682-3780





Available online at Journal Website  
<https://ijma.journals.ekb.eg/>  
 Main Subject [Orthopedic Surgery]



## Original Article

# Percutaneous Fixation of Metatarsal Fractures

Eslam Fawzy Mahfouz<sup>\*</sup>; Adnan Abd El Aleem El-Sebaay; Mohammed Abd-ElKader

Department of Orthopedic Surgery, Faculty of Medicine, Al-Azhar University, Cairo, Egypt.

## ABSTRACT

### Article information

**Received:** 23-01-2025

**Accepted:** 23-02-2025

**DOI:** [10.21608/ijma.2025.355084.2113](https://doi.org/10.21608/ijma.2025.355084.2113)

**\*Corresponding author**

**Email:** [eslammahfouz95@yahoo.com](mailto:eslammahfouz95@yahoo.com)

**Citation:** Mahfouz EF, El-Sebaay AA, Abd-ElKader M. Percutaneous Fixation of Metatarsal Fractures. IJMA 2025 Apr; 7 [4]: 5571-5576. doi: [10.21608/ijma.2025.355084.2113](https://doi.org/10.21608/ijma.2025.355084.2113).

**Background:** Both children and adults frequently suffer metatarsal bone fractures, which, if untreated, can cause persistent foot pain. Most fractures are treated nonoperatively, but displaced fractures, particularly of the first and fifth metatarsals, require special attention due to their impact on foot function. In cases with significant soft tissue damage or severe misalignment, operative intervention may be necessary. Certain injuries, such as Lisfranc and Jones fractures, remain complex and controversial in their treatment.

**The aim of the work:** The study aim was to evaluate and study the functional and radiological short term outcome of percutaneous [k-wire] fixation of metatarsal fractures.

**Patients and Methods:** This prospective study reviewed 15 recent cases of closed metatarsal fractures treated at Al-Azhar University Hospitals and Shibin Elkom Teaching Hospital between October 2023 and July 2024. The patients, aged 18 to 55, were assessed using the AO classification and AOFAS score. Radiographs were analyzed for fracture displacement and type, with follow-up evaluations included

**Results:** In this study of 15 patients with closed metatarsal fractures treated with percutaneous pinning, all achieved full radiographic union within 6-9 weeks. AOFAS scores showed significant improvement, with all patients scoring 40 points for pain, 10 points for function, and 15 points for alignment at the end of follow-up. Complications included one case of malunion [6.67%] and two cases of pin tract infection [13.33%]. The overall results were excellent in 13 patients and good for 2.

**Conclusion:** Closed reduction and percutaneous pinning for metatarsal fractures resulted in a 90% consolidation rate and return to activity without pain, even without radiographic confirmation. Patients had a good range of motion, minimal disability, and no significant radiographic differences between fracture fixation and healing.

**Keywords:** Percutaneous; K-Wire Fixation; Metatarsal fractures; AOFAS score; Radiographic Union.



This is an open-access article registered under the Creative Commons, ShareAlike 4.0 International license [CC BY-SA 4.0] [<https://creativecommons.org/licenses/by-sa/4.0/legalcode>].

## INTRODUCTION

Metatarsal fractures are common injuries among both adults and children, often resulting in chronic foot pain. These fractures exhibit various patterns, categorized by anatomical location, injury mechanism, treatment options, and clinical outcomes [1]. The majority of metatarsal fractures are managed with nonoperative treatments, while only a small percentage requires surgical stabilization. While maintaining the integrity of the longitudinal and transverse arches, the main objective of treatment is to ensure appropriate weight distribution by realigning the metatarsals. First and fifth metatarsal displaced fractures are especially significant because of their significant impact on foot movement [2].

Subcapital malalignment can also cause chronic deformities, Metatarsalgia, and post-traumatic degenerative changes. There is disagreement over how to treat metatarsal fractures because of the significant intraarticular disruption, severe misalignment, and load-bearing dysfunction that frequently call for closed or open reduction and fixation [3].

Soft tissue damage from crush injuries and open metatarsal fractures is regarded as a distinct injury category [4]. The foot's limited soft tissue coverage has a major impact on prognosis and makes managing foot trauma more difficult. Even though most metatarsal fractures heal well, some fractures, such as Lisfranc and Jones fractures, are still challenging to treat. This is clear from the large amount of research on these injuries [5]. Because of their complexity and the foot's delicate structure, treating these fractures frequently calls for specialized care. Effective management is necessary to avoid long-term functional problems. Because of their effects on foot mechanics and general mobility, these fractures are more challenging to treat.

The aim of this study was to evaluate and study the functional and radiological short term outcome of percutaneous [k-wire] fixation of metatarsal fractures.

## PATIENT AND METHODS

This prospective study, conducted between October 2023 and July 2024 at Al-Azhar University Hospitals and Shibin Elkom Teaching Hospital in Menofia, included 15 patients with recent closed metatarsal fractures. The participants, aged 18 to 55 years, comprised 9 males [60%] and 6 females [40%]. Ethical approval was obtained, and informed consent was collected from all participants. The study utilized the AO classification system and the American Orthopedic Foot and Ankle Score [AOFAS] to assess clinical outcomes. **The inclusion criteria** for this study were as follows: patients with metatarsal neck and shaft fractures exhibiting displacement greater than 3–4 mm or angulation exceeding 10° in the sagittal plane, patients aged over 18 years, and those with fractures occurring within the past 4 weeks. Exclusion criteria included patients under 18 years old, those with open fractures, pathological fractures, or neurovascular injuries, individuals with a history of prior surgery on the affected foot or ankle, and patients with medical conditions that made them unfit for surgery.

**The preoperative assessment** included a thorough history taking, which covered patient demographics [age, sex, occupation], the mechanism of injury, symptoms [pain, swelling, deformity], and relevant medical and surgical history. Clinical evaluation involved a general examination of vital signs and a systematic review, along with a local examination to assess pain, tenderness, skin condition, swelling, bruising, gait, and any associated vascular or neurological injuries. Routine preoperative laboratory tests were performed, including a complete blood count, kidney and liver profiles, random blood sugar, and coagulation

profile. Radiographic evaluation involved obtaining plain X-rays in A-P, oblique, and lateral views of the foot, along with an A-P view of the ankle, to classify the fractures and guide surgical planning.

The operative procedure began with spinal anesthesia for all patients. The patients were positioned supine on a radiolucent orthopedic table, and an image intensifier was used to provide clear access to the metatarsal bone. After preparing the fracture for closed reduction, a Kirschner wire [KW], featuring one sharp and one blunt end, was used for intramedullary fixation. The KW was introduced via a free-hand technique under fluoroscopic guidance to ensure accurate placement. Intraoperative fluoroscopy confirmed correct positioning of the wire. For fractures with significant shortening, manual force was applied using a drill and KW to achieve proper alignment. The wire was then inserted and secured within the metatarsal, with careful attention to avoid dorsally subluxing the metatarsophalangeal joint.

Postoperative care involved close monitoring of pain, function, gait abnormalities, and alignment. Prophylactic antibiotics [cephalosporins] were administered for the first 24 hours. Patients were encouraged to begin partial weight-bearing immediately using a back splint and crutches for the first 4 weeks, with full weight-bearing allowed only after radiographic confirmation of no displacement. Follow-up appointments were scheduled at 2-week intervals, and radiographs were taken at 6 weeks to assess fracture healing. The Kirschner wire [KW] and bandage were removed at 4–6 weeks once fracture union was confirmed both clinically and radiographically.

Patients were regularly monitored during clinical follow-up for pain, function, and alignment. Radiological follow-up included postoperative radiographs taken at 3, 6, and 9 months to assess fracture healing and ensure maintenance of anatomical reduction. Fracture union was confirmed when the fracture lines were no longer visible, and bony trabeculae had bridged the fracture site.

**Statistical Analysis:** The study uses descriptive statistics to summarize patient demographics, fracture details, and complications, while analytical statistics [P-values] highlight statistically significant improvements in pain, function, and alignment over time. This combination ensures a comprehensive understanding of the treatment's effectiveness.

## RESULTS

**Table [1]** summarizes patient characteristics, including sex, fracture side, trauma mode, follow-up period, and fracture type. Most patients were male [60%], with the right foot more commonly fractured [53.3%]. Direct trauma was the leading cause [53.33%], followed by motorbike accidents [26.67%]. Most fractures were Type A [53.33%], indicating less complex injuries. In addition, all 15 cases achieved complete radiographic union within 6 to 9 weeks. Specifically, 7 patients [46.67%] achieved full union at 6 weeks, 5 patients [33.33%] at 7 weeks, 2 patients [13.33%] at 8 weeks, and 1 patient [6.67%] at 9 weeks [**Figure 1**].

**Table [2]** summarizes the clinical results based on the AOFAS score, showing significant improvement in pain, function, and alignment over time. By the end of follow-up, all patients achieved complete pain relief and maximum scores in functional categories like activity, footwear, and walking distance. Alignment was also perfect in all cases. At the final assessment, 86.67% of patients had excellent outcomes, and 13.33% had good results, demonstrating the effectiveness of the treatment in promoting recovery.

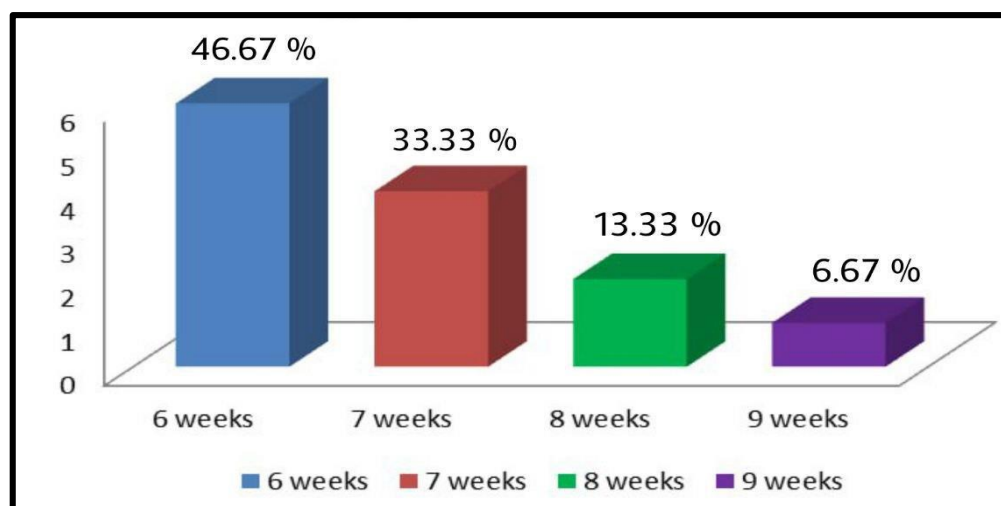
**Table [3]:** The data shows significant improvements in key functional

measures from 3 months to the end of the study, with a P-value of less than 0.05 indicating statistical significance. By the end of the follow-up, all patients achieved full pain relief, compared to 53.33% at 3 months. Functional scores, including activity, support, and footwear requirements, improved, with 100% of patients reaching the highest scores by the end. The percentage of patients able to walk the maximum distance increased from 73.33% to 93.33%, and all patients achieved full recovery in walking ability on various surfaces. Alignment remained perfect for all patients,

and 86.67% achieved excellent final scores, with 13.33% rated good. **Table [4]** presents the distribution of complications observed in the studied patients. Mal-union occurred in 1 patient, accounting for 6.67% of the cases, while pin tract infection was reported in 2 patients, representing 13.33%. These results suggest that while complications were relatively uncommon, pin tract infection was the most frequent issue encountered among the patients.

**Table [1]:** The demographics, trauma mechanisms, and fracture characteristics of the patient population

Parameter	Category	Number of patients	%
Sex Distribution	Male	9	60
	Female	6	40
Side of Fracture	Right	8	53.3
	Left	7	46.7
Model of Trauma	Direct Trauma [fall from height & heavy object]	8	53.33
	Motorbike Accident [MBA]	4	26.67
	Foot Twisting [indirect]	3	20
Type of Fracture [AO Classification]	Type A	8	53.33
	Type B	6	40
	Type C	1	6.67



**Figure [1]:** Bar-chart showing radiographic union in weeks.

**Table [2]:** The clinical results based on the American Orthopaedic Foot and Ankle Society [AOFAS] score

Parameter	Score Range	Follow-up Period	Frequency	Percentage [%]
Pain	30 points	First 3 months	8 patients	53.33
	40 points	First 3 months	7 patients	46.67
	40 points	End of follow-up	15 patients	100
Function [Activity, Limitation, Support]	10 points	After 3 months	7 patients	46.67
	7 points	After 3 months	7 patients	46.67
	4 points	After 3 months	1 patient	6.67
	10 points	End of follow-up	15 patients	100
Function [Footwear Requirements]	5 points	After 3 months	13 patients	86.67
	3 points	After 3 months	2 patients	13.33
	5 points	End of follow-up	15 patients	100
Function [Maximum Walking Distance]	10 points	After 3 months	11 patients	73.33
	7 points	After 3 months	4 patients	26.67
	10 points	End of follow-up	14 patients	93.33
	7 points	End of follow-up	1 patient	6.67
Function [Walking Surfaces]	10 points	After 3 months	10 patients	66.67
	5 points	After 3 months	5 patients	33.33
	10 points	End of follow-up	15 patients	100
Alignment	15 points	After 3 months	15 patients	100
	15 points	End of follow-up	15 patients	100
Final Score	Excellent	End of follow-up	13 patients	86.67
	Good	End of follow-up	2 patients	13.33



**Table [3]:** Comparison of Functional Recovery and Pain Relief at 3-Month and Final Follow-Up in Metatarsal Fracture Patients"

Parameter	Score Range	3 Months Follow-Up	End of Follow-Up	P-Value
Pain	30 points	8 patients [53.33%]	-	<0.05
	40 points	7 patients [46.67%]	15 patients [100%]	<0.05
Function [Activity, Limitation, Support]	10 points	7 patients [46.67%]	15 patients [100%]	<0.05
	7 points	7 patients [46.67%]	-	<0.05
	4 points	1 patient [6.67%]	-	<0.05
Function [Footwear Requirements]	5 points	13 patients [86.67%]	15 patients [100%]	<0.05
	3 points	2 patients [13.33%]	-	<0.05
Function [Maximum Walking Distance]	10 points	11 patients [73.33%]	14 patients [93.33%]	<0.05
	7 points	4 patients [26.67%]	1 patient [6.67%]	<0.05
Function [Walking Surfaces]	10 points	10 patients [66.67%]	15 patients [100%]	<0.05
	5 points	5 patients [33.33%]	-	<0.05
Alignment	15 points	15 patients [100%]	15 patients [100%]	-
Final Score	Excellent	-	13 patients [86.67%]	<0.05
	Good	-	2 patients [13.33%]	<0.05

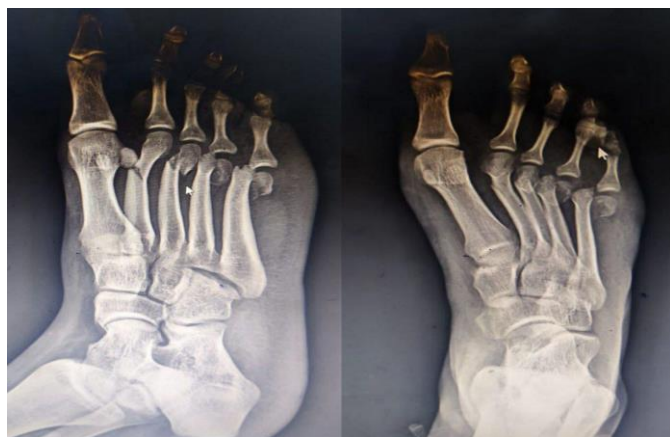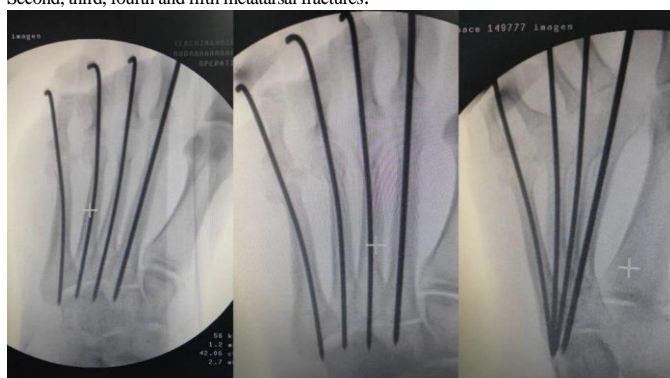
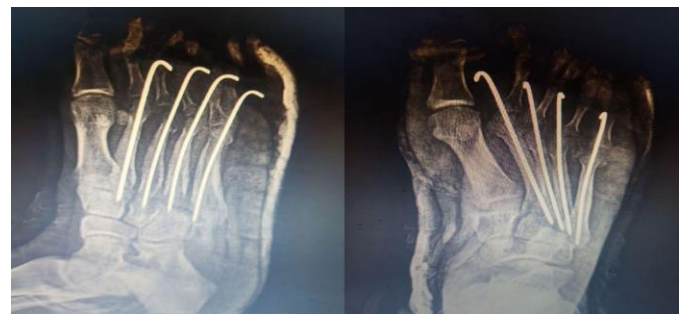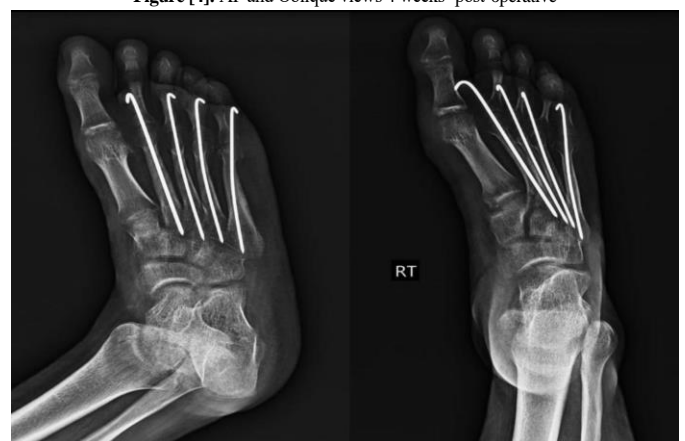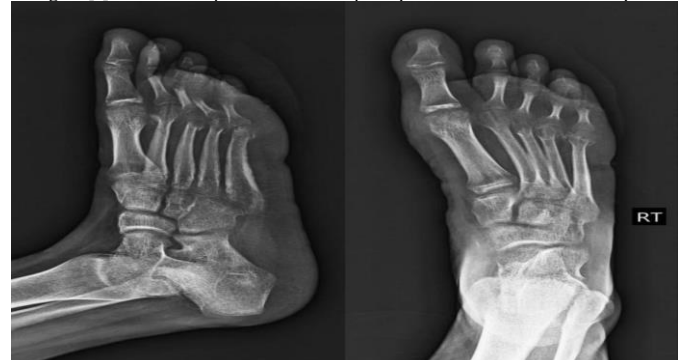**Table [4]:** Distribution of the studied patients regarding complications

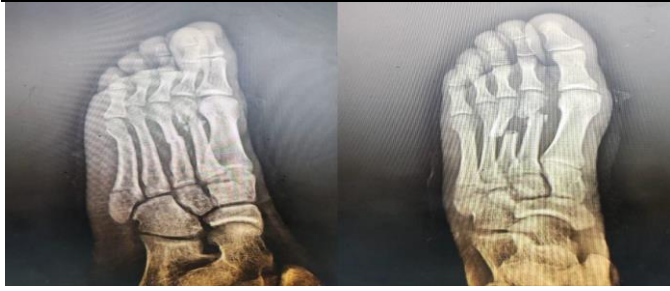Complication	Number of Patients	Percentage [%]
Mal-union	1	6.67
Pin tract infection	2	13.33

### Cases

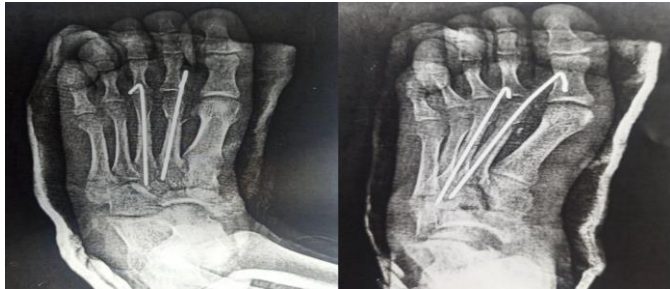**Case [1] [Figures 2-6]:** A 34 years old male with fracture right Second, third, fourth and fifth metatarsals. Mode of trauma was falling from height. He was operated on second day.

**Case [2] [Figures 7-9]:** A 29 years old male with fracture left Second and third metatarsal. Mode of trauma was falling from height. He was operated on first day.

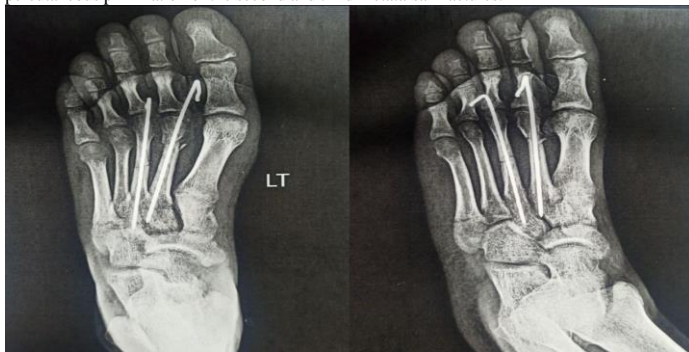
**Figure [2]:** Anteroposterior [AP] and oblique views of the patient preoperatively showing Second, third, fourth and fifth metatarsal fractures.**Figure [3]:** Intra operative closed reduction and percutaneous pin fixation of the Second, third, fourth and fifth metatarsal fractures.**Figure [4]:** AP and Oblique views 4 weeks' post-operative**Figure [5]:** AP and Oblique views 8 weeks' post-operative and before removal of pins.**Figure [6]:** AP and oblique views 12 weeks' post-operative and 4 weeks following healing and removal of the pins, good alignment of Second, third, fourth and fifth metatarsal fractures is demonstrated on the radiographic views.



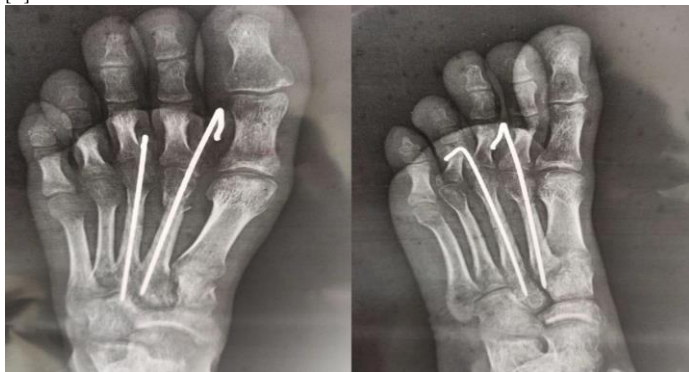**Figure [7]:** AP and oblique views of the patient preoperatively showing second and third metatarsal fractures.



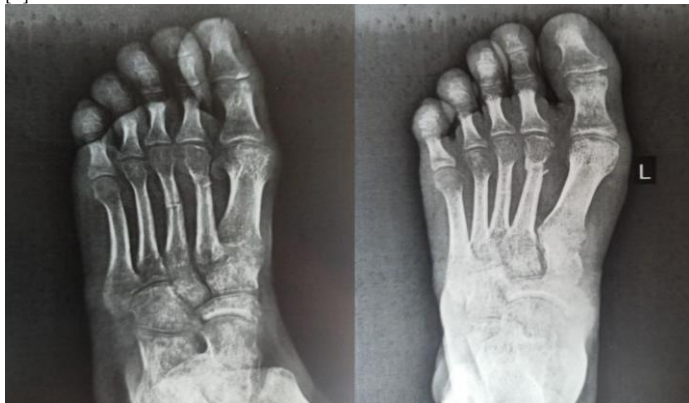**Figure [8]:** AP and Oblique view the immediate post-operative closed reduction and percutaneous pin fixation of the second and third metatarsal fractures.



[A]



[B]



**Figure [9]:** The AP and Oblique views at various post-operative intervals show significant progress in the healing of the metatarsal fractures: [A] at 4 weeks, initial healing is observed; [B] At 8 weeks, prior to pin removal, continued healing with proper alignment is evident; and [C] at 12 weeks, 4 weeks after pin removal, excellent alignment of the second and third metatarsals is demonstrated, confirming successful healing.

## DISCUSSION

Percutaneous fixation of metatarsal fractures is a minimally invasive technique that uses pins, wires, or screws to stabilize fractures with minimal soft tissue disruption [13]. This approach reduces the risk of complications like infection and promotes quicker recovery compared to open surgery. It is especially effective for non-displaced or mildly displaced fractures, allowing for accurate alignment and early weight-bearing. However, it may not be suitable for highly displaced fractures, and careful patient selection is crucial for optimal outcomes. The aim of this study was to assess and analyze the functional and radiological short-term outcomes of percutaneous fixation using K-wires for metatarsal fractures [14].

This study found that metatarsal fractures were more common in male patients [60%] and occurred more frequently in the right foot [53.3%], possibly due to biomechanical factors. Direct trauma was the leading cause of fractures [53.33%], with motorbike accidents contributing to 26.67% of cases, highlighting the need for targeted injury prevention. Most fractures were Type A [53.33%], indicating less complex injuries that likely resulted in favorable outcomes, suggesting the effectiveness of early intervention and percutaneous fixation techniques. These findings are in line with those of **Kaushik et al.** [8], who reported that 90% of the cases were male, with a much smaller percentage of female patients [10%]. Regarding the cause of fractures, Kaushik et al. found that road traffic accidents were the leading cause [56% of cases], followed by falls from heavy objects [30%], twisting injuries [10%], and assaults [4%]. Similarly, they noted that while side of injury was not a major factor, the right foot was more commonly affected [74% of cases], Gotha et al. Further supporting the trend observed in our study that the right foot is most frequently fractured [11].

**Chandran et al.** also had an incidence similar to our study with male more predominant than female while the most common mode of injury was high-velocity road traffic accidents accounts [12].

In our study, all 15 cases achieved complete radiographic union within 6 to 9 weeks, with 46.67% of patients [7 cases] achieving full union at 6 weeks, 33.33% [5 cases] at 7 weeks, 13.33% [2 cases] at 8 weeks, and 6.67% [1 case] at 9 weeks. These results are consistent with the findings of **Kim's et al.** study, where closed intramedullary pinning was used for metatarsal fractures in 30 patients, involving 46 fractures of the metatarsal head, neck, or shaft. In his study, Bone union was achieved at an average of 7.1 weeks, with a range from 6 to 10 weeks [6]. Both studies highlight the effectiveness of percutaneous fixation techniques in promoting early and reliable bone union in metatarsal fractures.

The clinical results of this study, evaluated using the AOFAS score, demonstrate the effectiveness of K-wire fixation for metatarsal fractures, showing significant improvements in pain relief, function, and alignment over time. By the end of the follow-up period, all patients experienced complete pain relief and achieved maximum functional scores in key areas such as activity, footwear, and walking distance, suggesting the treatment effectively addressed both immediate and long-term recovery needs. Furthermore, perfect alignment was achieved in all cases, highlighting the role of K-wire fixation in promoting proper healing and restoring metatarsal integrity. With 86.67% of patients achieving excellent outcomes and 13.33% achieving good results, the high success rate supports the efficacy of K-wire fixation for full recovery and long-term functional restoration. These findings are consistent with Kim's study, which also demonstrated the success of closed intramedullary pinning for metatarsal fractures, with an average AOFAS score of 96.7 at final follow-up [range: 83 to 100]. This further validates the positive outcomes associated with percutaneous fixation techniques for metatarsal fractures.



In a similar vein, **Santoso et al.** [7] found that after using the integrated approach for K-wire fixation, callus formation was observed within 2 months, and patients reported a high AOFAS score of 95 at 6 months' post-surgery.

**Kaushik et al.** [8] reported a good AOFAS score of 84.26 for patients treated with K-wire fixation, further confirming the effectiveness of this technique. Similarly, Cakir et al. Also found satisfactory outcomes in metatarsal fractures treated with K-wire fixation, reinforcing the consistent success of this approach across various studies [10].

In this study, the data demonstrated significant improvements in key functional measures from 3 months to the end of the study. By the end of the follow-up, all patients achieved full pain relief, compared to 53.33% at 3 months. Functional scores, including activity, support, and footwear requirements, showed marked improvement, with 100% of patients reaching the highest scores. Additionally, the percentage of patients able to walk the maximum distance increased from 73.33% to 93.33%, and all patients regained full walking ability on various surfaces. Alignment remained perfect for all patients.

In the current study, complications were relatively rare, with mal-union occurring in just 1 patient [6.67%] and pin tract infection in 2 patients [13.33%]. Pin tract infection emerged as the most common issue, while the low incidence of mal-union suggests that the K-wire fixation method was generally effective in promoting proper bone healing.

These findings are consistent with **Baumfeld et al.**'s conclusion that percutaneous K-wire fixation is an effective treatment for lateral metatarsal fractures, associated with a lower incidence of complications compared to other methods [9]. Similarly, **Kaushik et al.** [8] reported a lower overall complication rate in the K-wire fixation group, with only 2 cases of infection and 1 case of persistent deformity, further supporting the efficacy and safety of this technique in managing metatarsal fractures.

The study has several limitations that impact its conclusions. The small sample size of 15 patients. Additionally, the lack of a control group prevents a direct comparison with other treatment methods, such as ORIF or conservative management. The inclusion of diverse fracture types adds complexity to the analysis. Lastly, while complications were reported, the study did not address how these complications were managed, limiting insights into potential risks and their mitigation.

### Conclusion:

The study demonstrated a 90% consolidation rate and successful return to pre-injury activity levels without symptoms. Closed reduction and percutaneous pinning for metatarsal fractures resulted in excellent motion and minimal disability, with no significant radiographic differences in fracture healing. Pinning is an effective, low-cost treatment with excellent short-term results. However, the small sample size and short follow-up period, limit the findings, suggesting the need for larger studies with longer follow-up. Overall, K-wire pinning is a successful method with minor complications.

**Consent for publication:** All authors have agreed to the manuscript's content. On behalf of the authors, I am excited to communicate with your Journal and sincerely hope our research will be carefully reviewed under your attention.

**Competing interests:** No conflict of interest regarding the publication of this paper. No fund was received.

## REFERENCES

1. Samaila EM, Ditta A, Negri S, Leigheb M, Colò G, Magnan B. Central metatarsal fractures: a review and current concepts. *Acta Biomed.* 2020 May 30;91[4-S]:36-46. doi: 10.23750/abm.v91i4-S.9724.
2. Grushky AD, Im SJ, Steenburg SD, Chong S. Traumatic injuries of the foot and ankle. In: *Seminars in Roentgenology.* WB Saunders; 2021. p. 47-69. doi:10.1053/j.ro.2020.09.003.
3. Bouteffouchet T, Budair B, Backshayesh P, Ali S. Metatarsal fractures: A review and current concepts. *Trauma.* 2014; 18:147-63, doi: 10.1177/1460408614525.
4. Al-Ashhab MG, El-Gazzar AS, El-Hammady AS, Awad-Allah ME. Comparison between conservative and surgical treatment of base of fifth metatarsal fracture. *Benha J Appl Sci.* 2021;6[5]:123-7.
5. Mascio A, Greco T, Maccauro G, Perisano C. Lisfranc complex injuries management and treatment: current knowledge. *Int J Physiol Pathophysiol Pharmacol.* 2022 Jun 15;14[3]:161-170. PMID: 35891929.
6. Kim HN, Park YJ, Kim GL, Park YW. Closed antegrade intramedullary pinning for reduction and fixation of metatarsal fractures. *J Foot Ankle Surg.* 2012 Jul-Aug;51[4]:445-9. doi: 10.1053/j.jfas.2012.04.009.
7. Santoso AR, Gunawan H. AOFAS Functional Scoring After Antegrade K Wires Fixation of Multiple Metatarsal Neck Fracture: A Case Report. *Orthop J Sports Med.* 2019 Nov 27;7[11 suppl6]:2325967119S00467. doi: 10.1177/2325967119S00467.
8. Kaushik S, Verma RK, Gupta SP, Bhair R. Evaluation of efficacy of different modalities in treatment of fracture metatarsal. *Asian J Pharm Clin Res.* 2021;140-3, doi: 10.22159/ajpcr.2021v14i5.41218.
9. Baumfeld D, Macedo BD, Nery C, Esper LE, Filho MA. Anterograde percutaneous treatment of lesser metatarsal fractures: technical description and clinical results. *Rev Bras Ortop.* 2015 Nov 4;47[6]:760-4. doi: 10.1016/S2255-4971[15]30035-5.
10. Cakir H, Van Vliet-Koppert ST, Van Lieshout EM, De Vries MR, Van Der Elst M, Schepers T. Demographics and outcome of metatarsal fractures. *Arch Orthop Trauma Surg.* 2011 Feb;131[2]:241-5. doi: 10.1007/s00402-010-1164-6.
11. Gotha HE, Lareau CR, Fellars TA. Diagnosis and management of lisfranc injuries and metatarsal fractures. *R I Med J [2013].* 2013 May 1;96 [5]:33-6. PMID: 23641461.
12. Chandran P, Puttaswamaiah R, Dhillon MS, Gill SS. Management of complex open fracture injuries of the midfoot with external fixation. *J Foot Ankle Surg.* 2006 Sep-Oct;45[5]:308-15. doi: 10.1053/j.jfas.2006.06.002.
13. Dewar CP, O'Hara GN, Roebke LJ, McKeon J, Martin KD. Percutaneous Screw Fixation of Proximal Fifth Metatarsal Fractures. *JBJS Essent Surg Tech.* 2024 Nov 15;14[4]: e23.00078. doi: 10.2106/JBJS.ST.23.00078.
14. Patel V, Deshpande SV, Goel S, Suneja A, Jadawala VH. Intramedullary Kirschner Wire Fixation for Metatarsal Fractures: A Comprehensive Review of Treatment Outcomes. *Cureus.* 2024 Apr 30;16[4]: e59368. doi: 10.7759/cureus.59368.



# IJMA



## INTERNATIONAL JOURNAL OF MEDICAL ARTS

Volume 7, Issue 4 (April 2025)



<http://ijma.journals.ekb.eg/>

P-ISSN: 2636-4174

E-ISSN: 2682-3780