

Schimplug versus Anterior Segment Optical Coherence Tomography after Epi-on Corneal Cross Linking in Keratoconus

Hoda R. Mohammed, Hamdy A. Al-Gazzar, Taher K. Eleiwa, Ahmed Sh. Mostafa

Department of Ophthalmology
Faculty of Medicine; Benha
University. Egypt.

Correspondence to: Ahmed
Sh. Mostafa, Department of
Ophthalmology Faculty of
Medicine; Benha University.
Egypt.

Email:

ahmedsherin@icloud.com

Received: 16 November 2023

Accepted: 22 December 2023

Abstract

Background: The measurement of corneal thickness is a crucial factor in evaluating keratoconus and its potential treatment methods, such as collagen cross-linking (CXL). The aim of this study was to evaluate the inter-device reliability in the corneal pachymetry following epi-on CXL using anterior segment optical coherence tomography (AS-OCT) and Scheimpflug tomography. **Methods:** This was across-sectional observational study that involved patients diagnosed with keratoconus and had undergone epi-on cross linking. Patients were subjected to follow-up examinations and corneal imaging with Pentacam (Oculus) and AS-OCT (Optovue). The inter-device reliability was assessed using the intraclass correlation coefficient (ICC) and Cronbach's alpha. **Results:** 72 of eyes (36 patients), aged (18-43) years with 27 (75%) males, 9(25%) females were included in the study. Regarding central corneal thickness (CCT) pentacam measured a mean of 519.18µm, versus 507.83 µm using AS-OCT, P value < 0.001. Thinnest corneal thickness (TCT) measured 511.61µm with pentacam versus 491.61 µm using AS-OCT, P value <0.001. On evaluating the agreement between pentacam and AS-OCT in measuring central corneal thickness, ICC ranged from 0.82 to

0.984, which reflected excellent reliability. Cronbach alpha was 0.975 demonstrated excellent agreement. For TCT, ICC ranged from 0.15 to 0.979, which reflected good reliability. Cronbach alpha was 0.972 demonstrated excellent agreement. **Conclusion:** Based on the results of corneal pachymetry, after epi-on CXL, both AS-OCT and pentacam demonstrates comparable measurements with excellent inter-device reliability. However, it is worth noting that the pentacam appears to slightly overestimates the CCT and TCT.

Keywords: Keratoconus, Pentacam, Optical Coherence Tomography.

Introduction

Keratoconus is a bilateral and asymmetrical corneal disorder that is defined as the progressive thinning and steepening of the cornea, resulting in notable vision impairment. This condition is non-inflammatory in nature and is typically observed in a cone-shaped form (1). The estimated prevalence of keratoconus is reported to be 1 in 84 (2) to 1 in 375 (3) in young adults.

Corneal cross-linking (CXL) is an established therapeutic intervention utilized for the purpose of decelerating or interrupting the advancement of keratoconus process (4). CXL induces various effects on the corneal tissue, ultimately resulting in promoting the corneal stiffness. As a result, it effectively halts or decelerates the advancement of keratoconus (5). CXL has been shown to effectively inhibit the progression of keratoconus, and enhance visual acuity by around 1-2 lines (6,7).

The measurement of corneal thickness is a crucial factor in assessing keratoconus and its potential treatment methods, such as CXL. The clinical significance of corneal thickness measurements using different tools is currently substantial. Numerous investigations have been conducted to evaluate the various outcomes of refractive, topographic, tomographic, pachymetric, and aberrometric analyses following CXL (8). However, the optimal method for measuring corneal thickness in patients who have undergone this operation remains undetermined.

The utilization of corneal tomography as a diagnostic method for keratoconus is prevalent, primarily owing to its ability to detect abnormal corneal elevation, even in instances of mild or subclinical disease (9).

The advent of the Scheimpflug camera system has facilitated the assessment of the posterior cornea by the acquisition of cross-sectional pictures using a rotating camera. The utilization of this equipment facilitated the identification of initial alterations occurring in the posterior cornea among individuals who exhibited no clinical abnormalities. This development constituted a significant advancement in the field of disease diagnosis and monitoring (10,11).

AS-OCT is extensively employed for the purpose of analyzing the anterior segment. The AS-OCT is a non-invasive equipment utilized for generating cross-sectional images of the anterior segment. These images can then be reconstructed into a three-dimensional representation, allowing for the assessment of corneal thickness (CT) and epithelium thickness (ET). The use of AS-OCT is becoming more widely acknowledged as a highly sensitive diagnostic technique for identifying keratoconus, demonstrating equivalent efficacy to Scheimpflug imaging (12).

The main aim of the current study was to evaluate inter-device reliability in corneal pachymetry following epi-on corneal collagen cross-linking using two different imaging techniques: AS-OCT versus Scheimpflug-based pentacam.

Patients and methods:

Patients' characteristics

This study was cross-sectional observational research that involved 72 eyes belonging to 36 patients diagnosed with keratoconus. The patients were selected based on their eligibility for epi-on CXL operation and were admitted to the Ophthalmology department at Benha University Hospital. The study was done during a period extending from July 2022 to May 2023. The present study gained an approval from the Research Ethics Committee (REC) of Benha University and conformed to the principles outlined in the Declaration of Helsinki.

Approval code: Ms 50-7-2022

The inclusion criteria for the current study included individuals of both sexes, aged 18 years or older, who had progressive keratoconus and a minimum corneal thickness of 400 μm . The diagnosis of keratoconus was established through utilization of both clinical and tomographic data. The study excluded individuals who were subjected to ocular trauma or previous eye surgery, those with ocular surface problems, allergic eye diseases, aphakia, an endothelial cell count below 2300 cells/ mm^2 , corneal scarring that could potentially affect Scheimpflug imaging, and individuals with glaucoma.

Corneal crosslinking technique

The procedure of epithelium-on cross linking was carried out (custom fast epi-on CXL) using riboflavin solution (RIBOFAST: 1.5 ml - riboflavin 0.1%, Vit E TPGS (penetration enhancer),

Sodium phosphate dibasic dodecahydrate, Sodium phosphate monobasic monohydrate, Sodium chloride, Purified water) and UV illuminator (CF-X Linker). Preoperatively, the corneal surface was prepared with a drop of proparacaine, followed by the placement of lid speculum, then riboflavin was administered onto the intact epithelium at a rate of 1-2 drops every 2 minutes for 10 minutes or longer if required until adequate saturation was achieved. The device focus system was used to align the optical head on the patient's eye under ultraviolet light which emits continuous radiation at a wavelength 365 nm with intensity of $3\text{mW}/\text{cm}^2$. After 30 minutes of UVA treatment ($5.4\text{ J}/\text{cm}^2$), The light source was switched off.

Gatifloxacin was administered 4 times daily for one week and prednisolone acetate 4 times daily in the first week, then the dose was decreased to 3 times then twice per day in a week and once per day in the final week. All patients were fitted with a bandage contact lens which was removed at day 1.

Follow up

The patients were subjected to follow-up assessment visits every two weeks. During every visit, the visual acuity (VA), best corrected visual acuity (BCVA), as determined by the Snellen chart, and slit lamp examination were conducted.

Corneal imaging was conducted once the epithelial healing process was fully completed. The corneal imaging techniques employed in this study included the use of Pentacam and OCT.

Corneal imaging

Pentacam examination was conducted utilizing the Allergo Oculyzer device, manufactured by Wave Light GmbH in Erlangen, Germany. The pentacam is a Schimpflug camera equipped with a rotating mechanism and a slit light emitting diode at a wavelength of 475 nm. This camera rotates around its axis of fixation and collects a minimum of 25 photos. This gadget utilizes the Schimpflug principle in order to build corneal maps.

The pentacam tomographic data included measurements of various parameters related to the cornea. These parameters were Central corneal thickness (CCT) in micrometers (μm), Thinnest corneal thickness (CT) in micrometers (μm), Curvature power of the flat meridian (K1) in diopters (D), Curvature power of the steep meridian (K2) in diopters (D), Maximum curvature power (K Max) in diopters (D), keratoconus index (KI), Central keratoconus index (CKI), Minimum sagittal curvature (R min) in millimeters (mm), Index of surface variance (ISV), Index of vertical asymmetry (IVA), Index of height asymmetry (IHA), Index of height decentration (IHD), and Belin/Ambrosio enhanced ectasia total deviation value (BAD-D).

Secondly, AS-OCT imaging is known to be a non-invasive imaging tool that generates high resolution pictures and provides quantitative assessments of the anterior segment and its anatomical components. The Fourier-domain AS-OCT system Optovue (RTVue RT-100 Optovue inc, Fremont, CA, USA) was

utilized to perform corneal pachymetry and epithelial thickness mapping. This device is equipped with a high-speed camera capable of capturing 26,000 axial scans per second. The device has an axial (depth) resolution of 5 μm and a transverse resolution of 15 μm . Additionally, a corneal adapter module with an add-on lens (CAM-L mode: 6.0 – 2.0 mm) and a wavelength of 840 nm was employed. A pachymetry scan pattern was selected to map the cornea, utilizing a scan diameter of 6 mm, and incorporating eight radials.

The study employed various parameters for analysis, including central corneal thickness (CCT) measured in micrometers (μm), minimal corneal thickness (Min CT) also measured in μm , the range between minimum and maximum corneal thickness, minimum epithelial thickness (Min ET) measured in μm , maximum epithelial thickness (Max ET) measured in μm , standard deviation (SD), central epithelial thickness measured in μm , and the range between minimum and maximum epithelial thickness (Min - Max ET) within a 6 mm zone.

During the Pentacam and AS-OCT measurements, participants assumed an upright sitting position and were instructed to rest their heads on the headrest. They were given specific instructions to maintain straight-ahead gaze and avoid blinking throughout each scan. During the inter-measurement intervals, participants were instructed to recline and perform many blinking movements in order to facilitate the even distribution of the tear coat prior to the realignment of the systems.

Both devices provide automatic measurements of the CCT at the apex and the thinnest pachymetry value (TCT). The sequential acquisition of scans was performed by a skilled technician in a controlled setting with standardized lighting conditions, following the parameters provided by the manufacturer. We included only scans that met the manufacturer's acquisition quality criteria, namely the quality specification of "OK" for the Pentacam and "✓" for AS-OCT. Furthermore, measurements of epithelial thickness were obtained.

Statistical analysis:

The data analysis was conducted utilizing SPSS computer software (Statistical Package for the Social Sciences) program, specifically version 26. The quantitative variables were mentioned by their means and standard deviation, or by their medians and interquartile ranges, depending on the nature of the data. The categorical variables were mentioned by their absolute frequencies and corresponding percentages. The assumptions for the application of parametric tests were assessed using the Kolmogorov-Smirnov test, which examines the distribution type, and the Levene test, which assesses the homogeneity of variances.

To assess the differences in a single variable within a group across two different time points, a paired sample t-test is employed, assuming that the data follows a normal distribution.

The intraclass correlation coefficient (ICC) was employed for evaluation of

the consistency or reproducibility of quantitative measurements conducted by various observers who were measuring the same item. Cronbach's alpha is a widely utilized reliability coefficient that is employed to assess the internal consistency of tests. Bland-Altman plot was employed to measure the concordance between the two measurement approaches. The threshold for statistical significance was established at a significance level of P below or equal to 0.05. A highly statistically significant difference was seen when the p-value was less than or equal to 0.001.

Results

This study included 72 eyes of 36 patients. Females represented 25% (9) with a mean age of 27.49 years \pm 6.39 (range 18-43).

Regarding grade of keratoconus, 76.4% (55) of the studied patients had grade 1, and 19.4% (14) of patients had keratoconus grade 3. BCVA ranged from 0.1 to 1 with a mean of 0.87. Spherical equivalent ranged from -12 D to 6 D with a median of (-0.75). (Table 1)

Regarding pentacam, central corneal thickness (CCT) ranged from 395 μ m to 602 μ m with a mean of 519.18 μ m. Thinnest corneal thickness (TCT) ranged from 394 μ m to 594 μ m with a mean of 511.61 μ m. Mean K1, K2 and K max were 43.46 D , 43.46 D and 46.02 D respectively. KI ranged from 0.98 D to 1.5 D with a mean of 1.06 D. Mean CKI and R min were 1.01mm and 7.3 mm respectively. Median ISV, IVA, IHA,

IHD and BAD-D were 22, 0.16, 5.63, 0.013 and 1.54 respectively. (Table 2)

AS-OCT revealed that mean Min CT and CCT were 491.61 μm and 507.83 μm respectively. The median range of min-max was (-0.75). AS-OCT revealed that mean Min ET, Max ET and C-ET were 46.49 μm , 57.06 μm and 52.47 μm respectively. The median of min-max ET was 22 μm . (Table 2)

On evaluating the agreement between pentacam and AS-OCT in measuring **central corneal thickness**, ICC ranged from 0.82 to 0.984, which reflected excellent reliability. Cronbach alpha was 0.975 demonstrated excellent agreement, with good agreement by Bland-Altman plot. (Figure 1A, table 3)

Also, on evaluating the agreement between pentacam and AS-OCT in measuring **thinnest corneal thickness**, ICC ranged from 0.15 to 0.979, which reflected good reliability. Cronbach

alpha was 0.972 demonstrated excellent agreement, with weak agreement by Bland-Altman plot. (Figure 1B, table3)

As regards grades of keratoconus, on evaluating the agreement between pentacam and AS-OCT in measuring **central corneal thickness**, for **grade I KC**, ICC ranged from 0.236 to 0.975, which reflected excellent reliability. Cronbach alpha was 0.983 demonstrated excellent agreement, while in **grade III KC**, ICC ranged from 0.475 to 0.93, which reflected good reliability. Cronbach alpha was 0.88 demonstrated good reliability. Table (4)

In measuring thinnest corneal thickness, for **grade I KC**, ICC ranged from -0.019 to 0.961, which reflected good reliability. Cronbach alpha was 0.98 demonstrated excellent agreement, while in, **grade III KC**, ICC ranged from 0.136 to 0.932, which reflected moderate reliability. Cronbach alpha was 0.822 demonstrated good agreement. Table (4)

Table 1: Demographic & clinical data among studied patients

Variables	All patients
Age	
Mean \pm SD	27.49 \pm 6.39
Range	(18-43)
Sex n. %	
Male	27 (75%)
Female	9 (25%)
Side n. %	
OD	36 (50%)
OS	36 (50%)
Grades n. %	
Grade 1	55 (76.4%)
Grade 2	3 (4.2%)
Grade 3	14 (19.4%)
Best corrected visual acuity (BCVA)	
Mean \pm SD	0.87 \pm 0.23
Range	(0.1-1)
Spherical equivalent (SE)	
Median (IQR)	-0.75(-2.5, -0.12)
Range	(-12, 6)

Table 2: Pentacam and AS-OST findings among studied patients:

Pentacam findings		All patients (n=72 eyes)
Central corneal thickness (CCT) (μm)	Mean \pm SD	519.18 \pm 47.34
	Range	(395 – 602)
Thinnest corneal thickness (CT) (μm)	Mean \pm SD	511.61 \pm 47.88
	Range	(394 – 594)
Curvature power of flat meridian (K1) (D)	Mean \pm SD	43.46 \pm 2.65
	Range	(39.6 – 52.4)
Curvature power of steep meridian (K2) (D)	Mean \pm SD	43.46 \pm 3.37
	Range	(409 – 57.2)
Maximum curvature power (K Max) (D)	Mean \pm SD	46.02 \pm 4.58
	Range	(41.6 – 68.8)
keratoconus index (KI)	Mean \pm SD	1.06 \pm 0.1
	Range	(0.98 – 1.5)
Central keratoconus index (CKI)	Mean \pm SD	1.01 \pm 0.03
	Range	(0.98 – 1.13)
Minimum sagittal curvature (R min) (mm)	Mean \pm SD	7.3 \pm 0.7
	Range	(4.94 – 8.11)
Index of surface variance (ISV)	Median (IQR)	22 (16 – 36)
	Range	(9 – 146)
Index of vertical asymmetry (IVA)	Median (IQR)	0.16 (0.12 – 0.22)
	Range	(0.05 – 1.67)
Index of height asymmetry (IHA)	Median (IQR)	5.65 (3 – 9.3)
	Range	(0.2 – 61.3)
Index of height decentration (IHD)	Median (IQR)	0.013 (0.009 – 0.02)
	Range	(0.002 – 0.236)
Belin/Ambrosio enhanced ectasia total deviation value (BAD-D)	Median (IQR)	1.54 (0.87 – 2.44)
	Range	(0.03 – 12.65)
AS-OST findings		All patients (n=72 eyes)
Minimal corneal thickness (Min CT) (μm)	Mean \pm SD	491.61 \pm 45.88
	Range	(355 – 578)
Central corneal thickness (CCT) (μm)	Mean \pm SD	507.83 \pm 41.51
	Range	(415 – 587)
Minimum – maximum (μm)	Median (IQR)	-0.75 (-2.5, -0.12)
	Range	(-191 , -39)
Min epithelial thickness (μm)	Mean \pm SD	46.49 \pm 6.22
	Range	(22 – 54)
Max epithelial thickness (μm)	Mean \pm SD	57.06 \pm 6.8
	Range	(48 – 80)
Standard deviation (SD)	Mean \pm SD	2.22 \pm 1.34
	Range	(0.8 – 7.2)
Central epithelial thickness (μm)	mean \pm SD	52.47 \pm 3.95
	Range	(41 – 63)
Min – max ET(μm)	Median (IQR)	22 (16 – 36)
	Range	(-31 , -3)

Table 3: Agreement of CCT and TCT between Pentacam and AS-OCT among studied patients:

	Pentacam	AS-OCT	p [¥]
Central corneal thickness (CCT) (µm) Mean ± SD	519.18±47.34	507.83 ±41.51	<0.001**
Agreement	ICC (95% CI) = 0.959 (0.82 – 0.984) Cronbach alpha = 0.975 P-value <0.001**		
Thinnest corneal thickness (TCT) (µm) Mean ± SD	511.61±47.88	491.61 ±45.88	<0.001**
Agreement	ICC (95% CI) = 0.868 (0.15 – 0.959) Cronbach alpha = 0.972 P-value <0.001**		

ICC test-retest interclass correlation coefficient, CI Confidence interval >0.9 is excellent [¥]p for paired sample t test [∞]p for ICC ICC <0.5 poor reliability 0.5 to 0.75 moderate reliability 0.75 and 0.9 good reliability, and any value above 0.9 indicates excellent reliability, Cronbach alpha 0.5 to <0.6 is poor 0.6 to <0.7 is questionable 0.7 to <0.8 is good p 0.8 to <0.9 is good p≥0.9 is excellent agreement.

Table 4: Agreement between CCT and TCT between Pentacam and AS OCT among studied patients with grades of KC:

	Pentacam	AS-OCT	p [¥]
Grade I Mean ± SD	532.2±41.79	518.36 ± 38.88	<0.001**
Agreement	ICC (95% CI) = 0.914 (0.236 – 0.975) Cronbach alpha = 0.983 P-value <0.001**		
Grade III Mean ± SD	470.57±37.46	468.71 ± 29.16	<0.001**
Agreement	ICC (95% CI) = 0.797 (0.475 – 0.93) Cronbach alpha = 0.88 P-value <0.001**		
	Pentacam	AS-OCT	p [¥]
Grade I Mean ± SD	525.87±41.08	506.33 ± 36.92	<0.001**
Agreement	ICC (95% CI) = 0.855 (-0.019 – 0.961) Cronbach alpha = 0.822 P-value <0.001**		
Grade III Mean ± SD	457.64±35.11	435.86±37.28	<0.001**

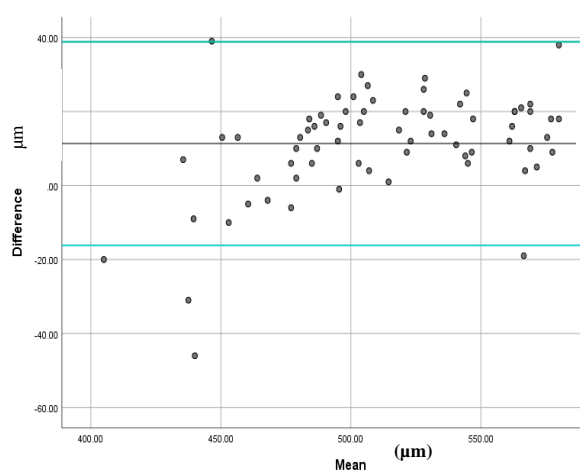
ICC (95% CI) = 0.602 (0.136 – 0.923)

Agreement

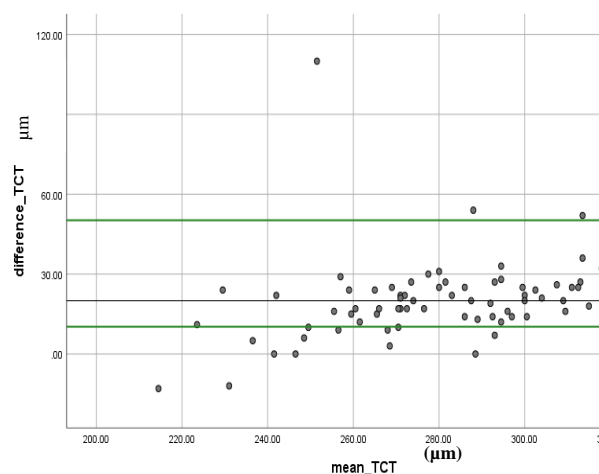
Cronbach alpha = 0.822

P-value= 0.002*

- ICC test-retest interclass correlation coefficient, CI Confidence interval >0.9 is excellent χ^2 p for paired sample t test χ^2 p for ICC ICC <0.5 poor reliability 0.5 to 0.75 moderate reliability 0.75 and 0.9 good reliability, and any value above 0.9 indicates excellent reliability, Cronbach alpha 0.5 to <0.6 is poor 0.6 to <0.7 is questionable 0.7 to <0.8 is good p 0.8 to <0.9 is good p \geq 0.9 is excellent agreement.
- ICC test-retest interclass correlation coefficient, CI Confidence interval >0.9 is excellent χ^2 p for paired sample t test χ^2 p for ICC ICC <0.5 poor reliability 0.5 to 0.75 moderate reliability 0.75 and 0.9 good reliability, and any value above 0.9 indicates excellent reliability, Cronbach alpha 0.5 to <0.6 is poor 0.6 to <0.7 is questionable 0.7 to <0.8 is good p 0.8 to <0.9 is good p \geq 0.9 is excellent agreement.

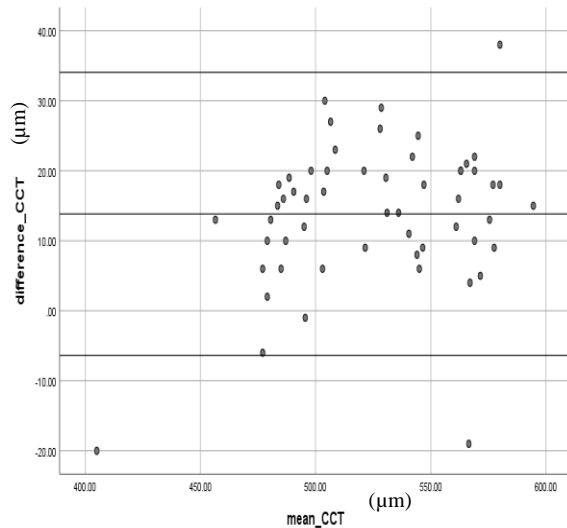


(1A)

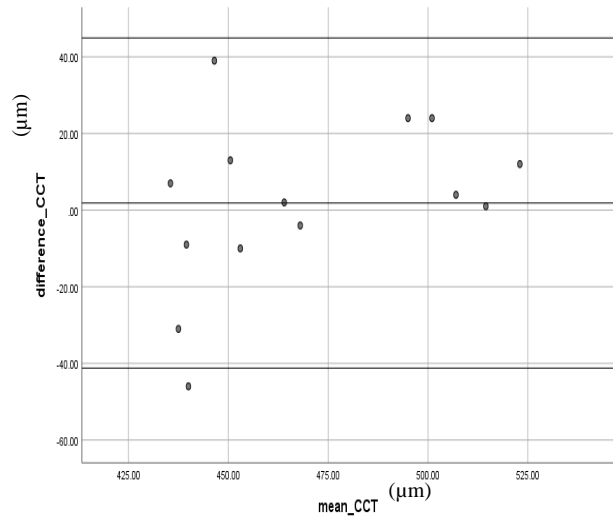


(1B)

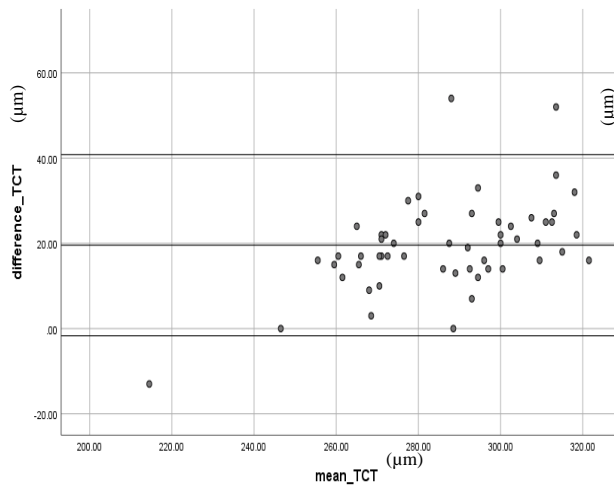
Fig. (1A) Bland-Altman plot: Showing good agreement between the two devices in measuring central corneal thickness where difference between two methods ranged from [-18 to 39] and precision error was estimated as 8.5%. **(1B) Bland-Altman plot:** Showing weak agreement between the two devices in measuring thinnest corneal thickness (15.8% below lower CI and 4.2% above higher CI where difference between two methods ranged from [-10 to 55]) [scattering of points is high, and many points cross line of agreement] and precision error=9%.



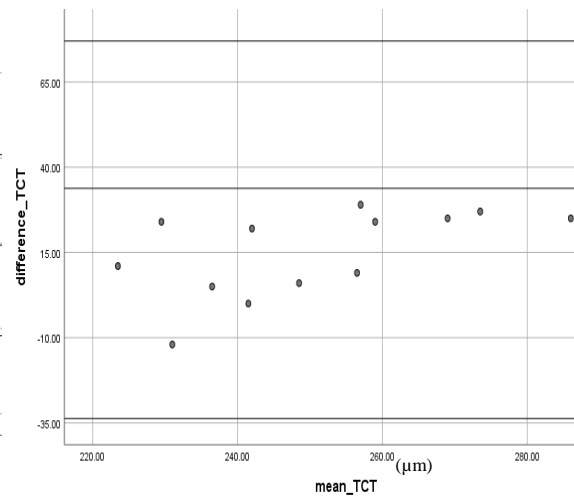
(2A)



(2B)



(2C)



(2D)

Figure 2: (2A) Bland-Altman plot showing agreement between two measures in diagnosis of central corneal thickness (3.6% below lower CI and 1.8% above higher CI where difference between two methods ranged from [-6.37 to 34.05) among grade I KC. **(2B) Bland-Altman plot** showing good agreement between two measures in diagnosis of central corneal thickness where difference between two methods ranged from [-41.223 to 44.937] (7.1% below lower CI and 0% above higher CI among patients with grade III KC

(2C) Bland-Altman plot showing agreement between two measures in diagnosis of thinnest corneal thickness (1.8% below lower CI and 3.6% above higher CI where difference between two methods ranged from [-1.716 to 40.816) among grade IKC. **(2D) Bland-Altman plot** showing agreement between two measures in diagnosis of thinnest corneal thickness (where difference between two methods ranged from [-33.42 to 77]) .

Discussion

The importance of corneal thickness measures continues to rise, particularly in occurrences of keratoconus, as accurate assessment of corneal thickness is crucial for both diagnostic and therapeutic purposes. This study investigated the corneal characteristics in a cohort of eyes with KC following epithelium-on corneal CXL utilizing two distinct techniques: Pentacam and AS-OCT. In the current study, we provide findings indicating that in keratoconus, following epi-on CXL intervention, the evaluation of corneal thickness using both Pentacam and AS-OCT yields equivalent results. Notably, the measurements obtained from Pentacam partially overestimate both CCT and TCT measurements.

Consistent with our findings, Chen et al., documented that non-contact assessments of CCT using HR Scheimpflug (Pentacam HR; Oculus, Wetzlar, Germany) and FD-OCT (RTVue-100; Optovue Inc., Fremont, CA, USA) devices exhibited excellent reliability and consistency. Moreover, they concluded that these measurements can be utilized interchangeably with Pentacam, although with a slight tendency to overestimate CCT (13).

In a comparable manner in their study, Zaho et al., found that the corneal curvature and thickness measurements obtained using CASIA were significantly lower compared to those obtained using Pentacam HR. The study included a sample of 78 eyes from 78 children and aimed to assess the level of agreement between these two systems in evaluating

various regions of the cornea in pediatric patients (14).

In their study, Li X et al. found that Pentacam pachymetry measures (Oculus) exhibited somewhat elevated central corneal thickness (CCT) values relative to CASIA2 measurements in a population of healthy people. Nonetheless, the study did not yield any statistically significant findings about the variations in corneal thickness across different regions and anterior chamber depth (ACD) as measured by the two devices (15).

According to the findings of Szalai et al., it was shown that in eyes affected by keratoconus, the variation between successive measurements was smaller when using AS-OCT with the Casia SS-1000 device, compared to Scheimpflug imaging with the Pentacam high resolution system. This trend was observed across many parameters, including keratometry and astigmatism values, apical thickness, and anterior chamber depth (ACD) (16).

In another study, Viswanathan et al. observed that the Pentacam device manufactured by Oculus Inc. in Wetzlar, Germany, yielded notably higher measures in both normal and keratoconic eyes compared to the AS-OCT (Visante OMNI) apparatus produced by Carl Zeiss Meditec in Jena, Germany (17).

In contrast, Mencucci et al. found that Pentacam (Oculus Optikgeräte GmbH) underestimated corneal thickness measurements when compared to Visante

AS-OCT (Carl Zeiss Meditec) and ultrasound pachymetry (USP) (Optikon Pacline) in their study. The study involved 50 patients (total 54 eyes) had epi-off CXL for correction of keratoconus. Corneal thickness was measured at baseline, then serial measurements at 1, 3, 6, and 12 months post treatment. These discrepancies could be attributed to the different operative techniques, heterogeneous reflectivity of the postoperative cross-linked cornea, as well as potential alterations in refractive index and acoustic impedance, which could influence the observed differences among the measurement techniques (18).

In another retrospective study a cohort of 33 patients with keratoconus were examined before and after undergoing personalized epi-off CXL treatment. The researchers utilized the Pentacam HR and the MS-39 AS-OCT imaging techniques to evaluate the corneal thickness measurements preoperatively and 1, 3, and 12 months. Their findings indicated that the Pentacam HR method exhibited a tendency to underestimate pachymetry measurements in cases when corneal haze was present (19).

Furthermore, Ashour et al. found that the Pentacam HR (Oculizer II) had a tendency to underestimate corneal thickness readings in keratoconus (KC) and scarred corneas when compared to AS-OCT. The study also revealed a high level of agreement in the KC group, while the scar group demonstrated a moderate level of agreement. This study involved the categorization of three distinct groups: Group A consisted of 20 individuals with normal, non-operated

corneas. Group B consisted of 20 individuals with keratoconus. While Group C consisted of a total of 20 eyes exhibiting corneal scars or interface complications, including those resulting from post laser-assisted in situ keratomileusis procedures (20). The divergent outcomes seen may be attributed to variations in the inclusion criteria employed in the two investigations and the heterogeneity of the populations under study.

The limitations of the current study encompass several aspects, including the cross-sectional design, small sample size, the absence of a control group (namely, epi-off), and being limited to one center.

Conclusion

Based on the results of corneal pachymetry after epi-on CXL, it can be concluded that AS-OCT demonstrates similar outcomes to the pentacam. Moreover, pentacam appears to provide slightly higher estimates for CCT and TCT. The AS-OCT technology demonstrates enhanced precision and marginally reduced corneal thickness measurements in comparison to the Scheimpflug system, particularly in cases with lower corneal thickness. The expanding clinical utilization of AS-OCT in corneal imaging and pachymetry has led to the identification of a remarkable finding. This finding holds potential for enhancing the accuracy of corneal thickness measurement.

References

1. Shajari M, Steinwender G, Herrmann K, Kubiak KB, Pavlovic I, Plawetzki E et al. Evaluation of keratoconus progression.

- British Journal of Ophthalmology. 2019; 103:551-7.
2. Chan E, Chong EW, Lingham G, Stevenson LJ, Sanfilippo PG, Hewitt AW et al. Prevalence of keratoconus based on scheimpflug imaging: The raine study. *Ophthalmology* 2021;128:515–21.
3. Godefrooij DA, de Wit GA, Uiterwaal CS, Imhof SM, Wisse RP. Age-specific Incidence and prevalence of keratoconus: A nationwide registration study. *Am J Ophthalmol*. 2017;175:169–72.
4. Chow VW, Chan TC, YuM, Wong VW, Jhanji V. One-year outcomes of conventional and accelerated collagen crosslinking in progressive keratoconus. *SC Rep*. 2015; 5:120-25.
5. Steinberg J, Ahmadiyar M, Rost A, Frings A, Filev F, Katz T et al. Anterior and posterior corneal changes after crosslinking for keratoconus. *Optometry and Vision Science*. 2014; 91:178-86.
6. Wollensak G, Spoerl E, Seiler T. Riboflavin/ultraviolet-a-induced collagen crosslinking for the treatment of keratoconus. *Am J Ophthalmol*. 2003; 135:620–627.
7. O'Brart D. Corneal collagen cross-linking for corneal ectasias. *Keratoconus*. Cham, Switzerland: Springer International Publishing. 2016; 136:219–238.
8. Chan TC, Biswas S, Yu m, JHANJI v. Comparison of corneal measurements in keratoconus using swept-source OCT and combined placido-scheimpflug imaging. *Acta ophthalmol*. 2016; 95:486-494.
9. Kovács, I., Kránitz, K., Juhász, É., Takács, Á., Dienes, L., Gergely, R., et al. Accuracy of machine learning classification using bilateral data from a scheimpflug camera for identifying eyes with pre-clinical signs of keratoconus. *J cataract refract surg*. 2016; 42:275-283.
10. Gokul, A., H.R. Vellara, and D.V. Patel. Advanced anterior segment imaging in keratoconus: review. *Clin Exp ophthalmol*. 2018; 64:122-132.
11. Belin, M.W. and S.S. Khachikian. An introduction to understanding elevation-based topography how elevation data are displayed -a review. *Clin Exp ophthalmol* . 2009; 37:14-29.
12. Kanellopoulos AJ, Asimellis G. OCT corneal epithelial topographic asymmetry as a sensitive diagnostic tool for early and advancing keratoconus. *Clin Ophthalmol*. 2014; 8:2277–87.
13. Chen W, McAlinden C, Pesudovs K, Wang Q, Lu F, Feng Y et al. Scheimpflug–Placido topographer and optical low-coherence reflectometry biometer: Repeatability and agreement. *Journal of Cataract & Refractive Surgery*. 2012; 38:1626-32.
14. Zhao, Y., Chen, D., Savini, G., Wang, Q., Zhang, H., Jin, Y., et al. The precision and agreement of corneal thickness and keratometry measurements with SS-OCT versus Scheimpflug imaging *Eye. Vis Lond*. 2020; 19:7-32.
15. Li, X., Zhou, Y., Young, C. A., Chen, A., Jin, G., & Zheng, D. et al. Comparison of a new anterior segment optical coherence tomography and Oculus Pentacam for measurement of anterior chamber depth and corneal thickness. *Ann Transl Med*. 2020; 14:8-857.
16. Szalai E., Berta A., Hassan Z., and Módos L., Jr. Reliability and repeatability of swept-source Fourier-domain optical coherence tomography and Scheimpflug imaging in keratoconus. *J Cataract Refract Surg*. 2012; 38:485–494.
17. Viswanathan D, Kumar NL, Males JJ, Graham SL. Comparative analysis of corneal measurements obtained from a Scheimpflug camera and an integrated Placido-optical coherence tomography device in normal and keratoconic eyes *Acta Ophthalmol*. 2015; 93(6): 488–494.

18. Mencucci, R., Paladini, I., Virgili, G., Giacomelli, G., & Menchini, U. et al. Corneal thickness measurements using time-domain anterior segment OCT, ultrasound, and Scheimpflug tomographer pachymetry before and after corneal cross-linking for keratoconus J Refract Surg. 2012; 28:562–566.
19. Tiago Mendes Baiao, Jascha Wendelstein, and Theo G. Seiler Comparison of Corneal Thickness Measurements After Customized Corneal Crosslinking Using High-Resolution Optical Coherence Tomography and Scheimpflug Tomography Cornea. 2023; 42:1104-1109.
20. Ashour A. Roshdy M. and Khaled A. Assessed corneal thickness in healthy and diseased corneas using different imaging techniques. Egypt J Hosp Med. 2018; 72:1-6.

To cite this article: Hoda R. Mohammed, Hamdy A. Al-Gazzar, Taher K. Eleiwa, Ahmed Sh. Mostafa. Schimplflug versus Anterior Segment Optical Coherence Tomography after Epi-on Corneal Cross Linking in Keratoconus. BMFJ 2025;42(3):24-37.