

EVALUATION OF PIEZO-ASSISTED RIDGE SPLITTING USING OSSEODENSIFICATION DRILLS IN NARROW ANTERIOR MAXILLA WITH SIMULTANEOUS IMPLANT PLACEMENT (CLINICAL TRIAL)

Mahmoud A. Elbayaa^{1*} BDS, Ahmed M. Shaaban², Mohamed M. Shokry³

ABSTRACT

BACKGROUND: One of the most effective methods for horizontal bone augmentation, particularly in the maxilla, is the alveolar ridge splitting technique. But it is a highly sensitive technique that requires some experience, so using a piezoelectric device for ridge splitting provides high accuracy with fewer complications.

AIM OF THE STUDY: This study aimed to assess maxillary anterior ridge splitting using piezotome and osseodensification drills with immediate implant placement.

MATERIAL AND METHODS: Eight patients (12 dental implants) with a narrow anterior maxillary ridge without an undercut participated in this clinical study. They were given the assignment of ridge splitting in the anterior segment of the maxilla along with simultaneous implant insertion. Clinical evaluation was done to determine implant stability, postoperative edema and the incidence of intra- or postoperative complications. Radiographic evaluation (CBCT), which uses on-demand software to determine bone density surrounding the implant and bone width gain at the crest of the bone, was done. Clinical and radiographic follow up were done over 6 months.

RESULTS: All patients had uneventful wound healing, with the exception of one who had a malformed split and another who had a slight infection that was treated conservatively. Six months postoperatively, bone width was $17.56 \pm 10.75\%$ wider than preoperatively, with a statistically significant difference (P value = 0.007*). After six months, there was a $40.56 \pm 10.86\%$ increase in bone density, with a statistically significant difference (P value = 0.013*).

CONCLUSION: Alveolar ridge splitting using piezotome and osseodensification drills with immediate implant placement appears to be efficient in the treatment of narrow anterior maxillary ridges with less time-consuming.

KEY WORDS: Narrow anterior maxilla, ridge splitting, densah burs, and piezosurgery.

1-BDS Faculty of Dentistry Alexandria University

2 - Professor of Oral Maxillofacial Surgery Oral & Maxillofacial Surgery Department Faculty of Dentistry, Alexandria University.

3- Professor of Oral & Maxillofacial Surgery Oral & Maxillofacial Surgery Department Alexandria University, Faculty of Dentistry

***Corresponding author:**

Mahmoud.moghazy.dent@alexu.edu.eg

INTRODUCTION

A minimum 1–1.5 mm bone width is needed on the buccal and palatal sides of the dental implant to ensure a favorable treatment outcome. There is a significant decrease in the bucco-palatal dimension of the alveolar ridge when a tooth is extracted, by 3.8 and 6.1 mm over 3–12 months, respectively (1,2).

Patients suffering from long-term edentulous segments of the alveolar ridge have severe bone resorptions (horizontally and vertically) that are usually evident, especially in the anterior maxillary region. Consequently, staged surgical bone augmentation techniques for implant placement are required (3).

Different techniques, such as Guided Bone Regeneration (GBR) with resorbable or non resorbable

membranes combined with autogenous bone particles or autogenous bone mixed with xenogenic bone material (3), autogenous bone block onlay grafts obtained intraorally or extraorally (4,5), inlay technique (6), or distraction osteogenesis (7) have been suggested for augmentation of the alveolar ridge.

Although these techniques are commonly used to increase inadequate alveolar bone, they have a number of drawbacks, including the need for additional surgical interventions, which elevate the cost of the treatment, duration, and morbidity of the donor site (9).

Dr. Hilt Tatum developed a technique for ridge splitting or bone spreading in the 1970s, which was presented by Simion and colleagues (10) in 1992 as an effective approach for augmentation of the

horizontally deficient alveolar bone with simultaneous implant insertion, eliminating morbidity of the donor site and reducing the duration of the treatment. In general, this procedure induces a greenstick fracture by labial placement of the buccal segment of the resorbed alveolar bone (11, 12).

The alveolar ridge splitting technique (ARST) can be employed independent of the quality of the bone using a microsaw (13) or piezoelectric devices (14) for splitting hard alveolar bone under proper control. To keep enough blood supply after bone splitting, a minimum of 1 mm of cancellous bone is required (12).

The primary drawback of traditional ridge splitting is the higher possibility of significant crestal bone loss surrounding the implants, as well as poor splits, labial plate fractures, or fenestration during separation (11).

The drilling protocol has undergone several changes, and while the under sizing protocol may be a viable option; it does not appear to possess a significant impact on the quality and biology of the bone. The use of osteotomes may contribute to good bone compaction, but the repeated malleting effect may have a negative impact on bone density and primary stability. In addition, the tapping force may cause patient discomfort and dizziness. Also, expanders might be a valuable option, but the pressure could result in a buccal bone plate fracture (8).

Osseodensification (OD) is novel biomechanical bone preparation technique before placing dental implants. OD, a bone compaction nonextraction technique, was introduced by Huwais and Meyer in 2013 (9).

It is based on the distinctive characteristics of specifically designed drills for the preparation of the implant osteotomy (Densah™ burs) that help densify bone. The normal drills had a smaller number of flutes and lands, which results in the excavation of more bone and, consequently, worse bone quality and quantity around the implant. The densah drills have unique characteristics, for example, more flutes and lands with a negative rank angle, which conserve bone by compaction rather than excavation and autografting the particulate bone at the osteotomy site by pushing it outward, which increases the contact between the bone and the implant, thereby shortening the healing period (10).

There is a lack of research regarding using osseodensification drills with piezo-assisted ridge splitting; hence, this research has been conducted with the aim of evaluating clinically and radiographically the maxillary anterior splitting of the alveolar ridge using piezotome and osseodensification drills with simultaneous implant placement.

MATERIALS AND METHODS

After obtaining the Ethical Committee's approval, Faculty of Dentistry, Alexandria University (Approval No. 0411-03/2022), this research was conducted as a clinical trial. Assuming 5% alpha error and 80% research power, the sample size was calculated using G*Power Version 3.1.9.4 with the aid of a similar study conducted by Hamzah et al. (18). The minimal sample size was determined to be 7 based on the comparison of means; this was later expanded to 8 to account for cases that were lost to follow-up. The needed total sample size is 8 patients (19).

MATERIALS

Piezotome device* (Acteon®)

Crestal Split tip (CS1) was used with a thickness of 0.5 mm and length of 8 mm

Osseodensification drills**

For preparation of the implant site

Ridge splitting chisels***

Implant system****

Osstell (ISQ®)*****

Non invasive method for measuring implant stability.

This study was done at Alexandria University's Faculty of Dentistry's Oral and Maxillofacial Surgery Department and was conducted as a clinical trial on 8 patients of both genders who suffered from horizontal deficiency in the anterior maxillary bone and required horizontal ridge augmentation procedures and implant-supported restorations. All patients received ridge splitting procedure using piezotome and osseodensification drills in the anterior maxilla.

Patients were chosen if they satisfied the inclusion criteria; which included being in the 20–60 age range, needing implants to replace missing maxillary anterior teeth, having a residual bone width of 3–5 mm with sufficient bone height, lacking any prior history of grafting procedures in the relevant location, and sticking to good oral hygiene.

Exclusion criteria included, severe concavity of the alveolar ridge, the presence of acute infections or periapical lesions in adjacent teeth, being a heavy

* ACTEON® Group, France.

** <https://versah.com/>

*** Neobiotic, (GURO) 10F, E-space Bldg., 36, Digital-ro 27 gil, Guro-gu, Seoul, 08381, Republic of Korea

**** CMI dental implant, Neobiotic, (GURO) 10F, E-space Bldg., 36, Digital-ro 27 gil, Guro-gu, Seoul, 08381, Republic of Korea

***** Osstell ISQ, Stampgatan 14 SE 411 01 Gothenburg, Sweden, phone: +46 31 340 8250, fax: +46 31 413 115, <http://osstell.com>

smoker, exhibiting bad oral hygiene, exhibiting parafunctional habits, and having medical conditions affecting the surgery.

Preoperative assessment:

Full personal data (name, age, occupation, etc.), the medical history or the medications taken by the patient, the history of any periodontal disorder or previous dental experiences or surgeries, and the patient's chief complaint, concerns, desires, and expectations were all listed.

A clinical assessment of the soft tissue overlying the preplanned implant site and any horizontal or vertical defects of the bone that contraindicate simultaneous implant placement was done. The size of the implants and the remaining width and height of the bone were measured using Cone Beam Computed Tomography (CBCT). Scaling and root planning were performed on each patient in an effort to achieve the best possible health for both the patient's periodontium and the possible implant location. To guarantee their satisfaction and safety, all patients were told of the procedure's benefits and hazards prior to signing a form of informed consent.

Operative phase:⁽¹¹⁾

The surgery was performed under local anesthesia, Articane hydrochloride 4% (Inibsa Artinibsa 4% 1:100.000), which was injected as an infiltration anesthetic solution at the site of the surgery five minutes before starting the procedure. A blade no. 15 was used to perform a para crestal incision with two small vertical incisions at its distal and mesial end not extended beyond mucogingival line. A molt # 9 periosteal elevator was used to elevate the mucoperiosteal flap, exposing the crestal part of the alveolar bone. A para crestal bony cut 5 mm in depth with two small vertical cuts at the distal and mesial ends at least 1mm away from the adjacent tooth using piezoelectric crestal split tip (cs1) (ACTEON® Group, France) were done. A hand Chesil was used carefully to refine the cut and lateralize the labial bony segment. (Fig. 1)

Osteotomy preparation for implant (IS-II active, Neobiotech Co., Korea) placement was carried out using the osseodensification drills; the planned number of implants (according to the case) was placed simultaneously in the prepared osteotomy within the alveolar split; and the implant stability was evaluated by resonance frequency analysis (RFA) using an Osstell device (Osstell ISQ®, Sweden). The bone gap was allowed to fill with a blood clot, allowing the wound to heal normally and resemble an extraction socket.

Following the replacement of the mucoperiosteal flap, the incision was sutured by a simple interrupted suturing technique using 4-0 polypropylene suture material (Ethicon J&J Medical Supply, New Jersey, United States). (Fig. 2)

Postoperative care:

Following the surgery, on the first day, all patients were directed to apply cold fomentation (10min/hour), hot warm saline mouthwash for the second 24 hours (3-6 times/day). Patients were also instructed to take the prescribed medications for 5 days following surgery, which included antibiotics (Augmentin 1g; Amoxicillin 875mg + Clavulanic acid 125mg, tablets: GlaxoSmithKline, UK) and (Flagyl: metronidazole 500mg: GlaxoSmithKline, UK.), anti-inflammatory and analgesics drugs (Cataflam: Diclofenac Potassium 50mg: Novartis, Switzerland), antiseptic mouth wash (Hexitol: Chlorhexidine 125mg/100ml, concentration 0.125%: Arabic drug company, ADCO). After 10 – 14 days the sutures were removed.

After six months, a small incision was done to expose the implant, the healing abutment was applied, and after three weeks of healing, the fabrication of the final zirconia fixed prosthesis was done. (Fig. 3)

Clinical follow up

Postoperative edema (12)

This was assessed on the 2nd day, 1 week, and 2 weeks after surgery and evaluated as follows:

None (no inflammation)

Mild (intraoral swelling confined to the surgical field)

Moderate (extraoral swelling in the surgical zone)

Severe (extraoral swelling spreading beyond the surgical zone)

Incidence of intraoperative or postoperative complications

Labial segment fracture, bone fenestration, wound dehiscence, surgical site infection and peri implantitis and others.

Implant stability

Using the Osstell (ISQ®, Sweden) helps to objectively and non-invasively determine implant stability and to assess the progress of osseointegration without jeopardizing the healing process. The stability of the implant was assessed immediately following implant insertion and after a 6-month follow-up period.

Radiographic evaluation

A CBCT was obtained preoperatively T1 and after 6 months T2 to assess:

Horizontal bone width gain

It was measured using OnDemand 3D software from cross-sectional cut by measuring the distance between labial and palatal plate of bone at its crest. The amount of bone width gain was calculated (T2-T1). (Fig 4)

Bone density

The density of the bone was evaluated before surgery and six months following implant insertion. A virtual dental implant that was identical in position and size to the real one would be placed in the preplanned position on 3D software (On Demand) using CBCT. The average density of the bone around the virtual implant

by 2 mm was assessed (before the surgery) by the softwar automatically. Using the same softwar after 6 months, a virtual implant that matched the real one was superimposed over each other to prevent artifacts from the actual implant's metal stray beam, and the average density of the bone around the real implant by 2mm was assessed. (Fig. 5)

Statistical analysis

The computer was fed data, and IBM SPSS software package version 20.0 was used for analysis. (IBM Corp, Armonk, NY). Numbers and percentages were used to represent the qualitative data. The Shapiro-Wilk test and the Kolmogorov-Smirnov test were employed to confirm that the distribution was normal. The terms range (minimum and maximum), mean, and standard deviation were used to characterize quantitative data. The results were deemed significant at the 5% level.

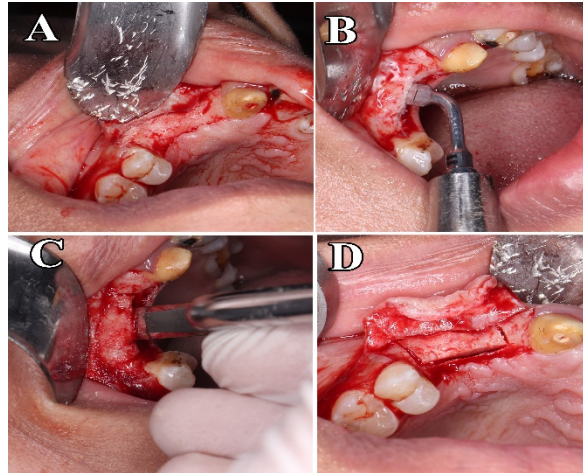


Figure (1): (A) Elevation of the mucoperiosteal flap and exposing the alveolar bone crest. (B) Ridge splitting using cs1 tip (ACTEON® Group, France). (C) Refining the alveolar split using a hand chisel. (D) Alveolar bone after finishing the splitting procedure.

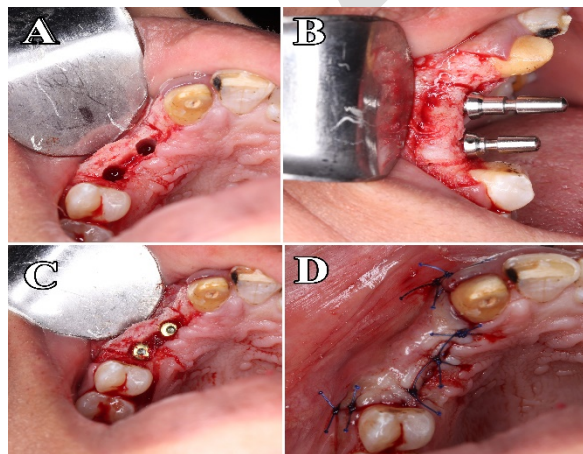


Figure (2): (A) Preparation of the implant osteotomy site. (B) Paralleling pen to check implant parallelism.

(C) Implant insertion. (D) Suturing the incision using polypropylene suture material.

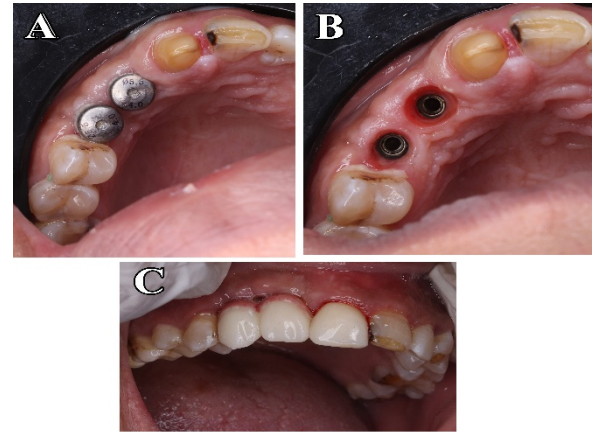


Figure (3): (A) Healing abutments after implant exposure. (B) Emergence profile of the soft tissue after healing. (c) Final screw-retained zirconia prosthesis.

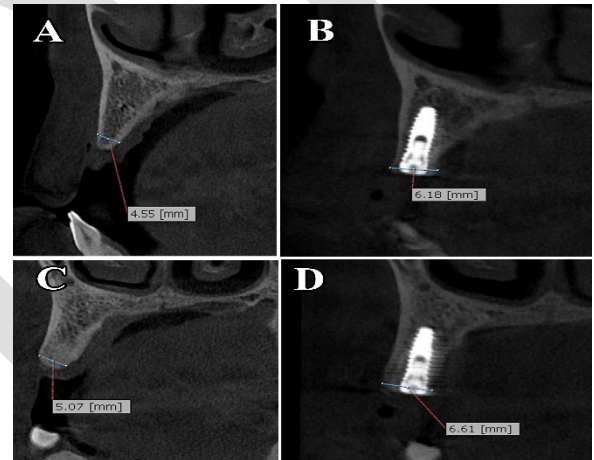


Figure (4): showing radiographic assessment for bone width gain
Upper lateral; (A) Bone width before surgery, (B) Bone width after 6 months.
Upper canine; (C) Bone width before surgery. (D) Bone width after 6 months.

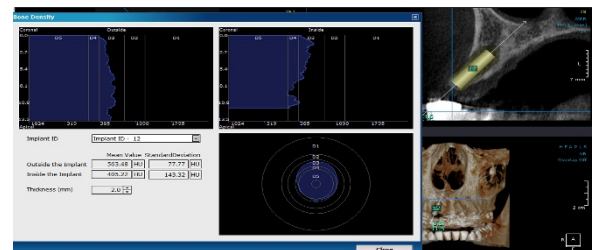


Figure (5): measurements of bone density.

RESULTS

There have been eight patients in this study (three males and five females) suffering from previous extraction of

their anterior teeth at least 6 months ago due to carries or periodontal diseases. Twelve implants were inserted, and eight surgeries of the alveolar ridge splitting were carried out for each patient. The patients' age range was 26 to 51 years, with an average age of 40.38 ± 8.40 .

Clinical Evaluation Data

Postoperative edema:

All patients showed mild edema confined to the surgical field on the second day that subsided by the first week.

Intra or postoperative complications:

In one case, a mal-split happened during the splitting process. As it was more labially leading to an incomplete fracture of the labial segment.

One patient showed a mild wound infection, which subsided totally by the 2nd postoperative week with conservative management.

Implant stability

The mean of primary stability immediately after implant insertion was 55.95 ± 9.17 , while the secondary stability after 6 months of osseointegration was 64.30 ± 4.46 , with an increase of 8.36 ± 5.44 .

There was a statistically significant difference between primary and secondary stability in favor of secondary stability ($P = 0.003^*$). (Table 1)

Radiographic evaluation

Horizontal bone width gain.

The mean bone width prior surgery was 4.64 ± 0.30 mm, and it increased by 1.31 ± 0.49 mm on average to 5.95 ± 0.56 mm after 6 months. The increase in bone width was statistically significant ($P = 0.007^*$), indicating a rise of $27.56 \pm 10.75\%$. (Table 2)

Bone density

The mean bone density prior surgery was 592.9 ± 78.28 HU, and six months later it was 833.1 ± 121.1 HU.

Regarding the preoperative and postoperative density of the bone, there was a significant difference ($P = 0.013^*$), which showed an increase of $40.56 \pm 10.86\%$. (Table 3)

Table (1): Evaluation of the Implant Stability immediately and after 6 months (n=8).

Implant Stability	Participants (n = 8)
Immediate	
Min. – Max.	41.60 – 67.40
Mean \pm SD.	55.95 ± 9.17
6 months	
Min. – Max.	58.20 – 71.0
Mean \pm SD.	64.30 ± 4.46
P value	0.003*
Increase	8.36 ± 5.44
% of increase	16.87 ± 14.01

Table (2): Evaluation of the bone width preoperatively and after 6 months (n=8).

Width gain	Participants (n = 8)
Preoperative	
Min. – Max.	4.0 – 5.03
Mean \pm SD.	4.64 ± 0.30
6 months	
Min. – Max.	4.80 – 6.39
Mean \pm SD.	5.95 ± 0.56
P value	0.007*
Increase 6m–pre	1.31 ± 0.49
% of Increase 6m–pre	28.57 ± 10.75

Table (3): Evaluation of the bone density preoperatively and after 6 months (n=8).

Density	Participants (n = 8)
Preoperative	
Min. – Max.	516.4 – 761.3
Mean \pm SD.	592.9 ± 78.28
6 months	
Min. – Max.	638.7 – 1022.1
Mean \pm SD.	833.1 ± 121.1
P value	<0.001*
Increase 6m–pre	240.3 ± 66.54
% of Increase 6m–pre	40.56 ± 10.86

DISCUSSION

Although the splitting of the alveolar ridge approach is regarded as a noninvasive and trustworthy method that may be employed with high rates of success, particularly with the easily lateralizable resilient bone of the maxilla, it's unfortunately an operator-dependent and sensitive procedure (18).

According to Jamil FA et al., (2011), the splitting of the alveolar ridge using a piezoelectric device is a well-established method for gaining alveolar bone width before implant insertion and is shown to be an advantageous procedure compared to other procedures of bone grafting, such as autogenous bone blocks.

According to researches, the alveolar ridge splitting technique (ARST) meets all criteria for optimal healing and regeneration of bony defects, including the preservation of bony walls, the minimization of bone loss, the availability of space for new bone formation, and the stability of mechanical wounds (3,13,21).

In this study, all patients suffered from mild edema confined to the surgical field on the second day, which subsided by the first week. Also in one case, a mal-split happened during the bony splitting process. As it was more labially leading to an incomplete

fracture of the labial segment and because it was still attached to the bone and the periosteum that ensured the repositioning and immobilization of the labial segment after implant placement and wound closure. One patient showed a mild wound infection, which subsided totally by the 2nd postoperative week with conservative management that included local curettage, antibiotics, and mouthwashes. Hamzah B et al., (11) obtained similar results regarding the edema and reported rates of complications.

Regarding stability of the implant, for the examination of the total implant stability across the healing unloaded time in a non-invasive way, a post-surgical and six-month postoperative Implant Stability Quotient (ISQ) analysis was done. Quesada et al., (2009)(16) performed a review article that indicated that Resonance Frequency Analysis (RFA) can be used to assess implant stability in a non-invasive manner.

The measurements showed a statistically significant difference between immediate and 6-month postoperative results, and the P value was **(0.003*)**. This result follows the results of Huwais S et al., (16), Lopez et al., (23), and Elgrany et al., (24). The density of the bone around the implant was increased by the motorized widening of the prepared site for the implant and the distinctive criteria of osseodensification drills, as we proved in this study. This results can be explained by the elastic recoil and spring back effect of the bone on the implant interface after implant placement, in addition to the intact, well-organized trabecular bone pattern around the implant, also increased the mechanical locking between the implant and surrounding bone. All these factors increased the primary stability of the dental implant and facilitated additional healing of the bone over the following six months, increasing the secondary stability as well. (16,17)

For the bone width, the mean bone width gain was $1.31 \pm 0.49\text{mm}$ and ($P=0.007^*$) with a significant increase in bone width which showed an increase of $27.56 \pm 10.75\%$ in agreement with Santagata M et al., (25) in 2015 with an overall mean BW gain of 3.5 mm, Albanese M et al., (26) in 2019 with a mean BW gain of 3.25mm, they show more BW gain but this may be explained by that they used bone graft material with or without barrier membrane to fill the split gap on the other hand in our study we didn't use any graft materials or membrane and depend totally on the blood clot to fill the split gap that cause bone remodeling during the healing and dimensional changes.

Also, Z Mahmoud et al. (27) included that the single -stage alveolar ridge splitting procedure is considered more predictable, efficient, and less complicated regarding the bone width gain than the conventional staged horizontal grafting procedures using autologous blocks of the bone because it avoids

the morbidity of the donor site and the oxygenation disruption of the bony segment, leading to better healing of the bone. It also demonstrated that using this approach results in higher short- and long-term survival rates for dental implants placed in both jaws.

The density of the bone surrounding the implant sides plays a major role in osseointegration, mainly in the maxillary bone. This study showed a statistically significant difference in favor of postoperative results of bone density, in agreement with Huwais et al. (16), who used densah burs with specific criteria in anti-clockwise densifying mode to compact rather than excavate the bone at the osteotomy site, producing consistent and uniform compaction around the implant sides, resulting in increased density of the bone and dental implant stability. Fanuscu et al. (28) found in their study that using bone expanders for bone expansion leads to an increase in the density of the bone compared with other drilling protocols that aid in the primary stability of the implant. A number of limitations have been encountered during the course of this research, including the need to collect a sample that meets the inclusion and exclusion criteria to thoroughly evaluate each participant clinically throughout the follow-up period, patient withdrawal, fracture of the labial segment, and a lack of a histological evaluation revealing the amount of viable bone regenerated around the implants.

CONCLUSION

According to the results of this study and with respect to the limitations, piezo-assisted ridge splitting using osseodensification drills with simultaneous implant placement in the horizontally deficient anterior maxilla could be considered an efficient technique with promising results.

CONFLICT OF INTEREST

The writers declared that they had no conflicts of interest.

FUNDING

For this work, the authors did not receive any special funding.

REFERENCES

1. Nedir R, Bischof M, Szmukler-Moncler S, Bernard JP, Samson J. Predicting osseointegration by means of implant primary stability: A resonance-frequency analysis study with delayed and immediately loaded ITI SLA implants. Clin Oral Implants Res. 2004 Oct;15(5):520–8.
2. Schropp L, Wenzel A, Kostopoulos L, Karring T. Bone healing and soft tissue contour changes following single-tooth extraction: a clinical and radiographic 12-month prospective study. Int J

- Periodontics Restorative Dent. 2003 Aug;23(4):313–23.
3. Urban IA, Monje A. Guided Bone Regeneration in Alveolar Bone Reconstruction. *Oral Maxillofac Surg Clin North Am* [Internet]. 2019 May 1 [cited 2022 Jan 20];31(2):331–8. Available from: <https://pubmed.ncbi.nlm.nih.gov/30947850/>
4. Misch CM. Comparison of intraoral donor sites for onlay grafting prior to implant placement. *Int J Oral Maxillofac Implants*. 1997;12(6):767–76.
5. Pikos MA. Block autografts for localized ridge augmentation: Part I. The posterior maxilla. *Implant Dent*. 1999;8(3):279–85.
6. El M, Bds Z, Abd | Said, Taha Bds AK, Ragia |, Bds M, et al. Assessment of vertical ridge augmentation and marginal bone loss using autogenous onlay vs inlay grafting techniques with simultaneous implant placement in the anterior maxillary esthetic zone: A randomized clinical trial. 2019; Available from: www.random.com
7. Takahashi T, Funaki K, Shintani H, Haruoka T. Use of horizontal alveolar distraction osteogenesis for implant placement in a narrow alveolar ridge: a case report. *Int J Oral Maxillofac Implants*. 2004;19(2):291–4.
8. Lahens B, Neiva R, Tovar N, Alifrag AM, Jimbo R, Bonfante EA, et al. Biomechanical and histologic basis of osseodensification drilling for endosteal implant placement in low density bone. An experimental study in sheep. *J Mech Behav Biomed Mater*. 2016 Oct;63:56–65.
9. Huwais S, Meyer EG. A Novel Osseous Densification Approach in Implant Osteotomy Preparation to Increase Biomechanical Primary Stability, Bone Mineral Density, and Bone-to-Implant Contact. *Int J Oral Maxillofac Implants*. 2017;32(1):27–36.
10. Pai UY, Rodrigues SJ, Talreja KS, Mundathaje M. Osseodensification - A novel approach in implant dentistry. *J Indian Prosthodont Soc*. 2018;18(3):196–200.
11. Hamzah B, Mounir R, Ali S, Mounir M. Maxillary horizontal alveolar ridge augmentation using computer guided ridge splitting with simultaneous implant placement versus conventional technique: A randomized clinical trial. *Clin Implant Dent Relat Res*. 2021 Aug;23(4):555–61.
12. Zitzmann NU, Margolin MD, Filippi A, Weiger R, Krastl G. Patient assessment and diagnosis in implant treatment. *Aust Dent J*. 2008 Jun;53 Suppl 1:S3-10.
13. Bassetti MA, Bassetti RG, Bosshardt DD. The alveolar ridge splitting/expansion technique: A systematic review. *Clin Oral Implants Res*. 2016;27(3):310–24.
14. Suh J-J, Shelemay A, Choi S-H, Chai J-K. Alveolar ridge splitting: a new microsaw technique. *Int J Periodontics Restorative Dent*. 2005 Apr;25(2):165–71.
15. Sculean A, Stavropoulos A, Bosshardt DD. Self-regenerative capacity of intra-oral bone defects. *J Clin Periodontol*. 2019;46:70–81.
16. Quesada García M, Prados Sánchez E, Olmedo Gaya MV, Muñoz Soto E, González Rodríguez M, Vallecillo Capilla MF. Measurement of dental implant stability by resonance frequency analysis: a review of the literature. 2009;