

OUTCOMES OF LEVEL I TEMPOROMANDIBULAR JOINT ARTHROSCOPY IN WILKES III INTERNAL DERANGEMENT: (A CASE SERIES)

Mohamed H. Fayad^{1*} MD, Rafael M. Granizo² PhD, Gamal A. Swaify³ PhD, Mohamed M. Fata³ PhD, Aly M. Atteya⁴ PhD, Ahmed Y. Kosba⁴ PhD

ABSTRACT

BACKGROUND: Minimally invasive temporomandibular joint (TMJ) arthroscopy has been recently evolving for treatment of TMJ disorders with ineffective conservative therapy.

AIM: The main objective is to report results of Arthroscopic Lysis and Lavage (ALL) in patients with TMJ internal derangement (ID) Wilkes III as regard maximal interincisal mouth opening (MIO) with documentation of disc position in magnetic resonance imaging (MRI).

PATIENTS & METHODS: A single institutional case series study was conducted on ten patients with Wilkes III TMJ ID who failed conservative measures for more than six months. Measured outcomes included MIO, pain visual analog scale (VAS), lateral movement (LM) and protrusive movement (PM), clicking and disc position. All of which were recorded preoperatively. Postoperative (PO) records were at 1,3, and 6 months except for the disc position at 6-month PO only.

RESULTS: Both MIO and pain score recorded a significant difference from the 3rd month PO; from 27.00 ± 1.41 to 30.50 ± 2.84 mm for MIO and from 65.30 ± 4.62 to 34.50 ± 7.62 points for pain ($P 0.011^*$, 0.002^* , respectively). LM and PM showed significant improvement at 6-months; from 4.20 ± 1.03 to 5.80 ± 0.92 mm for LM and from 3.10 ± 0.32 to 4.40 ± 0.84 mm for PM ($P 0.044^*$, 0.011^* , respectively). 80% of patients still had clicking and 90% still had anteriorly displaced disc at the 6M PO MRI.

CONCLUSION: ALL is an effective modality to improve MIO in Wilkes III ID patients who are refractory to conservative treatment even with persistent radiographic anterior disc displacement. Consequently, it is recommended for patients refractory to the initial conservative treatment.

KEYWORDS: TMJ arthroscopy, Level I arthroscopy, Lysis and lavage, Internal derangement, Wilkes III, Case series.

RUNNING TITLE: Level-I arthroscopy in Wilkes-III internal derangement: case series.

1-Assistant Lecturer of Maxillofacial and Plastic Surgery, Maxillofacial and Plastic Surgery Department, Faculty of Dentistry, Alexandria University, Alexandria, Egypt

2-Professor of Oral and Maxillofacial Surgery, Oral and Maxillofacial Surgery Department, Clínico San Carlos University Hospital, Faculty of Medicine, Complutense University, Madrid, Spain

3 -Professor of Maxillofacial and Plastic Surgery, Maxillofacial and Plastic Surgery Department, Faculty of Dentistry, Alexandria University, Alexandria, Egypt

4-Lecturer of Maxillofacial and Plastic Surgery, Maxillofacial and Plastic Surgery Department, Faculty of Dentistry, Alexandria University, Alexandria, Egypt

***Corresponding author:**

mohamed.fayad@alexu.edu.eg

INTRODUCTION

Temporomandibular disorders (TMDs) are a broad category of clinical issues which include arthrogenous, myogenous or mixed pathology. Temporomandibular joint (TMJ) Internal derangement (ID) is regarded as one of the most prevalent TMDs (1). Dolwick described it as an anomalous relationship between the disc and the temporal eminence of the TMJ, the glenoid fossa, and the mandibular condyle (2).

Wilkes was the first to create a classification system in 1989 to link radiological and clinical signs

to surgical findings. it entails five stages (3). Subsequently, in 1992, Bronstein and Merrill added arthroscopic findings to the radiologic and clinical findings of prior research (4). Most of the patients diagnosed with disc displacement without reduction (DDwoR) display signs of dysfunction with or without persistent joint pain. Degenerative changes in radiological imaging become apparent as the disease advances (5, 6).

Conservative management with medication, occlusal splint insertion, and physiotherapy has recorded 90% success. On the other hand,

nonrespondents are candidates for more invasive procedures. Smolka et al., recommended arthroscopic lysis and lavage (ALL) to be the next intervention for refractory cases (7). A meta-analysis was conducted to compare arthroscopic lysis and lavage versus arthrocentesis revealed its superiority in improving MIO and pain score (8). Additionally, long-term results were favorable concerning increasing MIO and decreasing pain and dysfunction (9).

Primarily, ALL concept involves irrigation of the superior joint space with ringer lactate, washing out inflammatory mediators and cytokines, and lysis of adhesions with a reported 80% success rate for patients with Wilkes stage III (10, 11)

The primary goal of this study was to assess the effectiveness of ALL on maximal interincisal opening (MIO) in patients with Wilkes III internal derangement, documented with pre- and six-month postoperative MRI for detection of disc position and its correlation with MIO.

PATIENTS AND METHODS

1. Study design

This is a prospective case series study conducted at the Maxillofacial and Plastic Surgery Department, Faculty of Dentistry, Alexandria University, Alexandria, Egypt from January 2022 to January 2023. Ethical approval was obtained from our university ethics committee (IRB No. 001056 – IORG 0008839).

2. Study subjects

Inclusion criteria

Wilkes III internal derangement patients (3) complained of pain, restricted mouth opening, had anteriorly displaced disc without reduction on MRI, and did not show an improvement with the initial conservative measures for more than six months. Conservative measures involved medications as (Non-Steroidal Anti-Inflammatory drugs (NSAID) and muscle relaxants), occlusal splint and physiotherapy.

Exclusion criteria

Temporomandibular disorders (TMDs) due to malocclusion (a skeletal anterior open bite, > 4mm overjet, ≥ 5 missing and unrestored posterior teeth) (12).

Medically compromised patients (ASA III – VI) (13). History of previous TMJ surgery.

3. Sample size calculation

Based on 80% study power and a 5% alpha error, the sample size was estimated. The mean (SD) improvement in MIO after 6 months compared to the preoperative measurements was calculated (12). The minimum sample size was determined to be 7 joints based on the difference between dependent means

using the highest SD = 5.4 to ensure adequate study power. To account for samples lost to follow-up cases, the sample size was increased to 9 joints. Based on Rosner's method (14) and determined by G*Power 3.1.9.7 (15), the sample size was determined.

4. Intervention

4.1. Presurgical phase

All patients were assessed clinically for pain, clicking, and functional movements including a maximal interincisal opening (MIO), contralateral lateral excursion movement (LM), and protrusive movement and radiologically with Magnetic Resonance Imaging (MRI) to detect the disc position. All patients signed an informed consent explaining the procedure with the possible complications and outcomes with implementation of Helsinki Declaration statement (16).

4.2. Surgical phase

4.2.1. Armamentarium

A 1.9 mm and 30-degree approach arthroscope (HOPKINS™, Storz, Tuttlingen, Germany) with a diameter of 1.9 mm and a length of 6.5 cm connected to a light cable and camera head, cannula (sheath) 2.5 mm in diameter and 4 cm in length, sharp and blunt trocars were used.

20 ml blood was obtained preoperatively for Platelet-rich plasma (PRP) preparation, then centrifuged at 1200 rpm for 8 minutes to obtain 4 ml PRP. PRP was activated using 0.2 ml CaCl₂ 10% before its intraarticular injection.

4.2.2. Preparation and patient positioning

All patients were operated in the supine position, under general anesthesia. Both eyes were protected by transparent sticky films while both external auditory canals (EAC) were protected by a small gauze.

4.2.3. Approaches

The first step in detecting the puncture sites involved drawing the Holmlund-Hellsing line from the tragus to the outer canthus. Two points were marked in relation to this line.

The first point was (10 mm in front of the tragus and 2 mm below this line) which represented the site of trocar insertion (the fossa puncture site). The second point was (20 mm in front of the tragus and 7 mm below this line) which represented the site of the outflow needle.

4.2.4. Surgical technique (17)

Examination under anesthesia with palpation of TMJ anatomy is usually the first step, following that, the superior joint space is distended with 3ml of 2% lidocaine without vasoconstrictor.

Single-puncture technique with an outflow needle was adopted. Initially, the sharp trocar was used to penetrate the skin at the fossa puncture site with a

controlled rotational movement. Then, the zygomatic arch periosteum was scraped, and the joint capsule was penetrated at a depth of 10 and 15 mm. After that, the sharp trocar was replaced by the blunt one to introduce the cannula further into the joint, approximately 20 to 25 mm from the skin. Finally, the arthroscope was inserted through the cannula.

With an open and protruded mandible, A 22 gauge, 1 ½ inch needle was inserted approximately 10 mm anterior and 5 mm inferior to the fossa puncture site. This was followed by an intraarticular diagnostic sweep with examination of the seven anatomical points of Maccain (17). Lysis, and lavage with 500 ml Ringer's lactate solution that was delivered intraarticularly through the previously inserted cannula by an infusion pump to maintain continuous infusion under pressure that help in adhesiolysis and inflammatory mediators drainage through the outflow needle. Finally, 3 ml of PRP was injected intraarticularly under direct arthroscopic vision through the fossa portal cannula's lavage track following the removal of the outflow needle. (Figure 1).

Postoperative management

Non-steroidal anti-inflammatory drugs (NSAIDs) were prescribed for 5-7 days. Clear fluids were started immediately postoperative followed by a soft diet for 4-6 weeks. Physiotherapy preceded by cold compresses was initiated on the first day postoperatively followed by hot compresses. Occlusal stabilization splint was provided also for all patients from post-operative day one to decrease the joint load.

5. Outcome assessment

All patients were followed up clinically at 1, 3, and 6 months. Primary outcome was maximal interincisal opening (MIO) improvement by using a disposable millimeter ruler between the incisal edges of the upper and lower central incisors at the maximal mouth opening. Secondary outcome parameters were: joint pain using a visual analog scale (VAS) with a range of 0 to 100. The VAS was divided into four categories: no pain (0-4), mild pain (5-44), moderate pain (45-74), and severe pain (75-100) (18), lateral excursion movement to the contralateral side (LM) that was measured between the midline of the upper and lower central incisors when moving the mandible to the contralateral side using a disposable millimeter ruler, protrusive movement measuring between the incisal edges of the upper and lower central incisors in the midline when protruding the mandible using a disposable millimeter ruler, clicking and finally disc position in the 6 months post-operative MRI compared to the preoperative one.

6. Statistical analysis

Data were analyzed using IBM SPSS, version 23, (Armonk, NY, USA). Normality of quantitative data was checked using the Shapiro-Wilk test and Q-Q

plots. All Quantitative variables were not normally distributed. except "Age" was found to be normally distributed. Mean, standard deviation (SD), median, and inter quartile range (IQR) were used for quantitative data presentation while frequency and percentage were used for qualitative variables. Comparison between different time points within each group was performed using Friedman test followed also by the post hoc test. All these tests were performed using Bonferroni correction to adjust for type I error due to multiplicity. Cochran's test was used to assess differences in qualitative variables across different time intervals. All tests were two-tailed and the significance level was set at p value ≤ 0.05 .

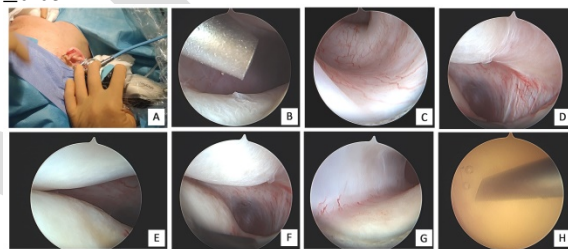


Figure (1): Surgical phase: A- external view of the first cannula and arthroscope, B- arthroscopic view of outflow needle, C- arthroscopic view of inflamed retrodiscal synovium, D- arthroscopic view of inflamed medial capsule, E- arthroscopic view of disc, eminence, Intermediate zone, F- arthroscopic view of anteriorly displaced disc, G- arthroscopic view of anterior pseudowall, H- arthroscopic view of PRP injection.

RESULTS

The study included ten female patients with a mean age of 36.50 ± 5.02 years. Preoperatively, all of them had pain for a mean duration of 14.40 ± 7.93 months and limited mouth opening which lasted for a mean duration of 12.00 ± 5.42 months while only nine patients had clicking for 11.40 ± 8.06 months.

A statistically significant decrease in the pain (VAS) score and increase in the maximal interincisal opening (MIO) was observed from the 3rd month postoperative (PO) follow-up (FU) while both lateral movement to the contralateral side and protrusive movements recorded this significant improvement at the 6th month PO FU (Table 1).

Unlike pain and functional movements, both clicking and disc position in MRI did not show any obvious improvement where eight patients (80%) still had clicking at all time intervals of PO FU compared to nine patients (90%) preoperatively (Figure 2). Also, nine patients (90%) still had anteriorly displaced disc without reduction at the 6M PO MRI compared to (100%) preoperatively (Figure 3,4).

Regarding complications, only one patient had temporary postoperative cheek numbness with no intraoperative complications recorded during the study.

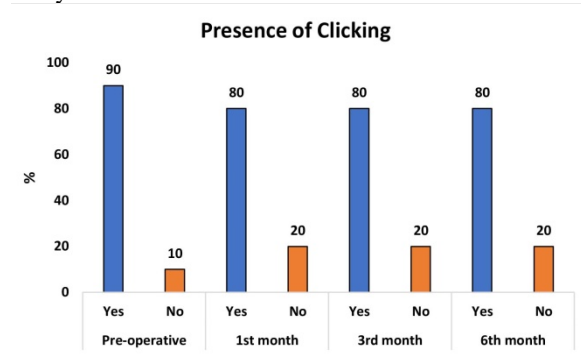


Figure (2): Comparison of clicking presence at different time intervals among the study group.

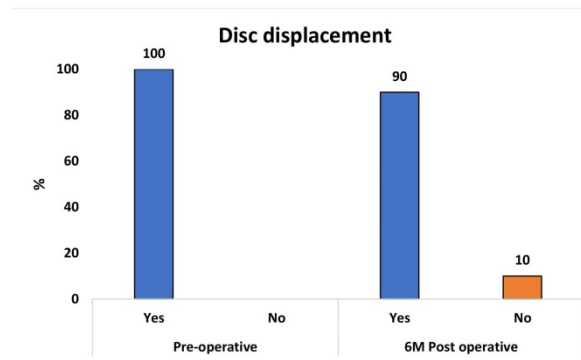


Figure (3): Comparison of presence of disc displacement in Pre and 6M Postoperative MRI among the study group.

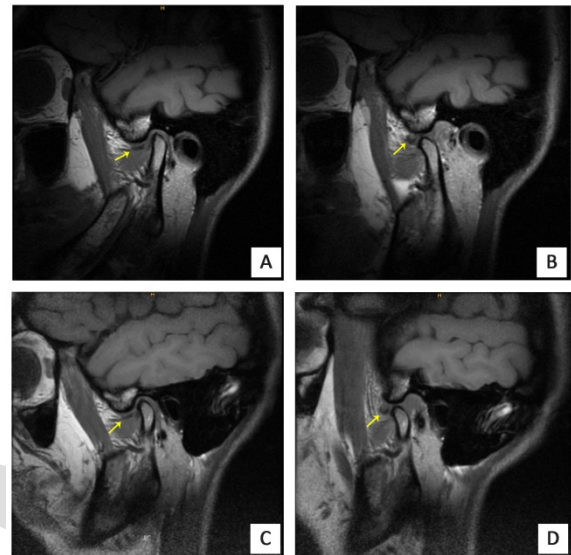


Figure (4): A-B preoperative MRI, sagittal view, T1 sequence, the arrow refers to the anteriorly displaced disc in both closed and open mouth positions respectively, C-D 6M PO MRI, sagittal view, T1 sequence, the arrow refers to the persistently displaced disc in both closed and open-mouth positions.

Table 1: Comparison of pain score, Maximal Interincisal Opening (MIO), lateral and protrusive movements at different time intervals among the study group.

		Pain	MIO	Lateral Movement	Protrusive movement
Pre-operative	Mean \pm SD	65.30 \pm 4.62	27.00 \pm 1.41	4.20 \pm 1.03	3.10 \pm 0.32
	Median (IQR)	65.50 (10.00)	27.00 (2.00)	4.00 (2.00)	3.00 (0.00)
1 st month	Mean \pm SD	43.50 \pm 8.18	29.00 \pm 2.36	4.90 \pm 1.37	3.00 \pm 0.82
	Median (IQR)	47.50 (12.50)	28.50 (2.75)	5.00 (1.75)	3.00 (2.00)
3 rd month	Mean \pm SD	34.50 \pm 7.62	30.50 \pm 2.84	5.40 \pm 1.17	3.60 \pm 0.70
	Median (IQR)	35.00 (11.25)	29.50 (4.75)	5.00 (2.25)	3.50 (1.00)
6 th month	Mean \pm SD	25.90 \pm 14.87	32.10 \pm 4.38	5.80 \pm 0.92	4.40 \pm 0.84
	Median (IQR)	29.00 (19.00)	30.00 (3.8)	5.50 (2.00)	5.00 (1.30)
Test		F _r =28.091	Fr=24.20	F _r =10.726	F _r =20.077
(p-value)		(<0.0001*)	(<0.0001*)	(0.013*)	(<0.0001*)

*Statistically significant difference at p value ≤ 0.05 , H test: Kruskal Wallis test, Fr test: Friedman test, SD: Standard deviation, IQR: Interquartile range.

DISCUSSION

Minimally invasive surgery has become the first alternative choice for TMJ patients who are refractory to conservative measures. Al-Moraissi et al., endorsed its early application as soon as the patient doesn't show an improvement with the initial

conservative procedures (19) as it gives a better outcome in terms of pain reduction and increased mouth opening. The success rate of the procedure was reported to be over 80% on long-term follow-up. Additionally, the procedure delayed the need for open joint surgery (20).

Temporomandibular joint arthroscopy has its superiority over arthrocentesis regarding direct vision of joint pathology, the ability to take a biopsy, and minimal surgical interventions with subsynovial injections (21). Al-Moraissi, reported a statistical significance between arthrocentesis and arthroscopy regarding their clinical outcome on MIO and pain reduction, However, no difference was observed concerning postoperative complications for both groups.

Arguments about the effectiveness of ALL alone in treating patients with chronic closed lock (CCL) are still present. Many authors advocated its use alone without the need for more advanced arthroscopic procedures (operative arthroscopy (OA) or discopexy techniques) (22-24). They reported better clinical outcomes regarding the pain (VAS) score decline and improvement of MIO as we noted in our study. Furthermore, long-term results for ALL also reported an outstanding clinical outcome where Sanders et al., had a five years follow-up (25) and Sorel et al., had up to ten years FU (26).

González-García et al., published two retrospective studies comparing ALL and OA. They concluded that both groups showed a significant enhancement for both pain score and MIO without any documentation of a statistically significant difference between them (27, 28). Consequently, these results support White et al., opinion that opposes the need for more advanced arthroscopic surgeries that have more morbidities and costs to the patients (23). Another retrospective comparative study was conducted by Corcuera et al., which included 205 patients (310 joints), 30% had ALL and 70% OA, showed no significant difference between both techniques (29). On the other hand, other publications supported the privilege of arthroscopic surgery over ALL alone reported a significant improvement in MIO between them (30-32).

In the present study, both MIO and pain (VAS) score showed a significant improvement at 3 and 6 months PO FU compared to the preoperative measures. Liebur et al. conducted a prospective study on 29 patients (35 joints) and reported similar improvements in both maximal interincisal opening (MIO) and pain score at short-term (6 months) and long-term (5 years) follow-up. (9). In accordance with our results, a significant decline in pain and a rise in MIO was reported by González-García et al., ($p < 0.0001$) but earlier from the first month (27).

Both lateral and protrusive movements increased significantly at the 6th month PO FU, ($p = 0.013^*$ and $<0.0001^*$) respectively. Concomitant results were recorded from the 3rd month by other investigators ($p < 0.0001^*$) for both movements (27).

Regarding clicking, only 10% of patients had a resolution of clicking compared to the preoperative percentage (90%) at all time intervals of FU. This can be explained by the surgical concept of lysis and lavage which aim to release adhesions and remove inflammatory mediators from the joint space.

Although 90% of patients still had ADDwoR at 6M PO MRI, all of them showed significant enhancement of functional movements. Argument about disc position in MRI and its consequences on clinical outcome has been investigated previously in the literature. Machoñ et al; reported an improvement in patients with Wilkes stage III who were subjected to ALL regardless of the disc position in magnetic resonance imaging (MRI) (10). Moses et al. found that 92% of FU postoperative MRI still had persistent anteriorly displaced disc. (33) while Montgomery stated unchanged disc position in 80% of the joints (34).

Complications are divided into intraoperative and postoperative ones (35, 36). Only one patient in the current study experienced transient cheek numbness following surgery. This is explained by the authors as a temporary affection of auriculotemporal nerve during trocar insertion. He was managed conservatively during the follow-up period with systemic steroids (oral prednisolone 0,5-1mg/kg/day) for two weeks plus neuro-supportive medications as vitamin B12 supplies for three months.

The short-term follow-up period (6 months) and few numbers of patients included are considered limitations of this study. Further studies with a long-term FU and more included patients are recommended.

CONCLUSION

Significant improvement of all functional movements and pain score was noted in the current study despite the persistence of the disc displacement in the 6M PO FU MRI in most of the Wilkes III ID patients with less postoperative complications and rapid recovery. Consequently, level I arthroscopy should be considered for patients who are refractory to the initial conservative treatment.

CONFLICT OF INTEREST

The authors declare that they have no conflicts of interest.

FUNDING STATEMENT

The authors received no specific funding for this work.

REFERENCES

1. Peck CC, Goulet JP, Lobbezoo F, Schiffman EL, Alstergren P, Anderson GC, et al. Expanding the taxonomy of the diagnostic criteria for

- temporomandibular disorders. *Journal of oral rehabilitation*. 2014;41(1):2-23.
2. Dolwick MF, Katzberg RW, Helms CA. Internal derangements of the temporomandibular joint: fact or fiction? *The Journal of prosthetic dentistry*. 1983;49(3):415-8.
3. Wilkes CH. Internal derangements of the temporomandibular joint: pathological variations. *Archives of Otolaryngology-Head & Neck Surgery*. 1989;115(4):469-77.
4. Bronstein SL, Merrill RG. Clinical Staging for TMJ Internal Derangement: Application to Arthroscopy. *Journal of Craniomandibular Disorders*. 1992;6(1).
5. Suenaga S, Nagayama K, Nagasawa T, Indo H, Majima HJ. The usefulness of diagnostic imaging for the assessment of pain symptoms in temporomandibular disorders. *Japanese Dental Science Review*. 2016;52(4):93-106.
6. Orhan K, Driesen L, Shujaat S, Jacobs R, Chai X. Development and validation of a magnetic resonance imaging-based machine learning model for TMJ pathologies. *BioMed Research International*. 2021;2021.
7. Smolka W, Yanai C, Smolka K, Iizuka T. Efficiency of arthroscopic lysis and lavage for internal derangement of the temporomandibular joint correlated with Wilkes classification. *Oral Surgery, Oral Medicine, Oral Pathology, Oral Radiology, and Endodontology*. 2008;106(3):317-23.
8. Al-Moraissi E. Arthroscopy versus arthrocentesis in the management of internal derangement of the temporomandibular joint: a systematic review and meta-analysis. *International journal of oral and maxillofacial surgery*. 2015;44(1):104-12.
9. Leibur E, Jagur O, Mürsepp P, Veede L, Voog-Oras Ü. Long-term evaluation of arthroscopic surgery with lysis and lavage of temporomandibular joint disorders. *Journal of Cranio-Maxillofacial Surgery*. 2010;38(8):615-20.
10. Machoň V, Levorová J, Hirjak D, Beňo M, Drahoš M, Foltán R. Does arthroscopic lysis and lavage in subjects with Wilkes III internal derangement reduce pain? *Oral and Maxillofacial Surgery*. 2021;1-8.
11. Waseem Abboud D, Sahar Nadel D, Noam Yarom D, Ran Yahalom D. arthroscopy of the temporomandibular Joint for the treatment of chronic closed lock. *risk*. 2009;9:13.
12. Pullinger A, Seligman D, Gornbein J. A multiple logistic regression analysis of the risk and relative odds of temporomandibular disorders as a function of common occlusal features. *Journal of dental research*. 1993;72(6):968-79.
13. ASo A. ASA physical status classification system. ASA House of Delegates. 2014.
14. Rosner B. Discrete probability distributions. *Fundamentals of Biostatistics 7th Edition Boston: Brooks/Cole, Cengage Learning*. 2011:71-107.
15. Faul F, Erdfelder E, Buchner A, Lang A-G. Statistical power analyses using G* Power 3.1: Tests for correlation and regression analyses. *Behavior research methods*. 2009;41(4):1149-60.
16. Cantín M. World Medical Association Declaration of Helsinki: ethical principles for medical research involving human subjects. Reviewing the latest version. *International Journal of Medical and Surgical Sciences*. 2014;1(4):339-46.
17. González-García R, Usandizaga JLG-D, Rodríguez-Campo FJ. Arthroscopic anatomy and lysis and lavage of the temporomandibular joint. *Atlas of the Oral and Maxillofacial Surgery Clinics of North America*. 2011;19(2):131-44.
18. Jensen MP, Chen C, Brugger AM. Interpretation of visual analog scale ratings and change scores: a reanalysis of two clinical trials of postoperative pain. *The Journal of pain*. 2003;4(7):407-14.
19. Al-Moraissi EA, Wolford LM, Ellis III E, Neff A. The hierarchy of different treatments for arthrogenous temporomandibular disorders: A network meta-analysis of randomized clinical trials. *Journal of Cranio-Maxillofacial Surgery*. 2020;48(1):9-23.
20. Murakami K. Current role of arthrocentesis, arthroscopy and open surgery for temporomandibular joint internal derangement with inflammatory/degenerative disease; pitfalls and pearls. *Journal of Oral and Maxillofacial Surgery, Medicine, and Pathology*. 2022;34(1):1-11.
21. Hossameldin RH, Ahmed MS. OUTCOME OF ARTHROSCOPIC LYSIS AND LAVAGE FOR INTERNAL DERANGEMENT OF THE TEMPOROMANDIBULAR JOINT. *Egyptian Dental Journal*. 2017;63(1-January (Oral Surgery)):345-53.
22. Miyamoto H, Sakashita H, Miyata M, Goss AN. Arthroscopic surgery of the temporomandibular joint: comparison of two successful techniques. *British Journal of Oral and Maxillofacial Surgery*. 1999;37(5):397-400.
23. White RD. Arthroscopic lysis and lavage as the preferred treatment for internal derangement of the temporomandibular joint. *Journal of oral and maxillofacial surgery*. 2001;59(3):313-6.
24. Murakami K. Rationale of arthroscopic surgery of the temporomandibular joint. *Journal of oral biology and craniofacial research*. 2013;3(3):126-34.

25. Sanders B. A 5-year experience with arthroscopic lysis and lavage for the treatment of painful temporomandibular joint hypomobility. *Advances in diagnostic and surgical arthroscopy of the temporomandibular joint*. 1993;31-4.
26. Sorel B, Picuch JF. Long-term evaluation following temporomandibular joint arthroscopy with lysis and lavage. *Int J Oral Maxillofac Surg*. 2000;29(4):259-63.
27. González-García R, Rodríguez-Campo F, Monje F, Sastre-Pérez J, Usandizaga JG-D. Operative versus simple arthroscopic surgery for chronic closed lock of the temporomandibular joint: a clinical study of 344 arthroscopic procedures. *International journal of oral and maxillofacial surgery*. 2008;37(9):790-6.
28. González-García R, Rodríguez-Campo FJ. Arthroscopic lysis and lavage versus operative arthroscopy in the outcome of temporomandibular joint internal derangement: a comparative study based on Wilkes stages. *Journal of oral and maxillofacial surgery*. 2011;69(10):2513-24.
29. Corcuera ODL, Cruz AM, Bascones AE, Reyes EV, Martín-Granizo R, Berguer A. Effectiveness of TMJ arthroscopy for the treatment of temporomandibular disorders, comparing lysis and lavage with operative arthroscopy. *International Journal of Oral and Maxillofacial Surgery*. 2013;42(10):1370.
30. Moses JJ, Poker ID. TMJ arthroscopic surgery: an analysis of 237 patients. *Journal of Oral and Maxillofacial Surgery: Official Journal of the American Association of Oral and Maxillofacial Surgeons*. 1989;47(8):790-4.
31. Segami N, Murakami K, Hosaka H, Lizuka T. Arthroscopic antero-lateral capsular release for internal derangement of the temporomandibular joint. *Jpn Arthroscopy ASS*. 1993;18:105-10.
32. Indresano AT. Surgical arthroscopy as the preferred treatment for internal derangements of the temporomandibular joint. *Journal of oral and maxillofacial surgery*. 2001;59(3):308-12.
33. Moses JJ, Sartoris D, Glass R, Tanaka T, Poker I. The effect of arthroscopic surgical lysis and lavage of the superior joint space on TMJ disc position and mobility. *Journal of Oral and Maxillofacial Surgery*. 1989;47(7):674-8.
34. Montgomery MT, Van Sickels JE, Harms SE, Thrash WJ. Arthroscopic TMJ surgery: effects on signs, symptoms, and disc position. *Journal of oral and maxillofacial surgery*. 1989;47(12):1263-71.
35. González LV, López JP, Díaz-Báez D, López RM-G. Intraoperative complications in temporomandibular joint arthroscopy: A retrospective observational analysis of 899 arthroscopies. *Journal of Cranio-Maxillofacial Surgery*. 2022;50(8):651-6.
36. González-García R, Rodríguez-Campo FJ, Escorial-Hernández V, Muñoz-Guerra MF, Sastre-Pérez J, Naval-Gías L, et al. Complications of temporomandibular joint arthroscopy: a retrospective analytic study of 670 arthroscopic procedures. *Journal of oral and maxillofacial surgery*. 2006;64(11):1587-91.