

Analysis of Imaging Modalities for Detecting Liver Lesions: (Review Artical)

NASSER SIHLI ALSHAMMARY, MOHAMMED NUHAYR ALWAHDANI, FARES MOTALQ ALONAZI, FAHAD MADALLAH ALNUWMASIU and SHAYEM HAMDAN ALHARBI and MARAM MOHAMMED FAWAZ ALANAZI and SARAH FAHAD MOHAMMED ALMUTAIRI and NORAH OWAYDHAH ALARJANI and ASMA HASSAN JAHAZ ALHARBI

E-Mail: Alshammaryna@ngha.med.sa

KSA, National Guard Health Affairs

Abstract

Background: Liver metastases are a common occurrence in metastatic illness and play a crucial role in determining treatment and prognosis. Various imaging methods, including ultrasonography, computed tomography (CT), magnetic resonance imaging (MRI), positron emission tomography (PET)/CT, and PET/MRI, can be used for non-invasive evaluation of liver metastases.

Aim of Study: This study aims to provide a comprehensive analysis of imaging results of liver metastases, focusing on the unique benefits and possible drawbacks of each imaging method. The significance of different imaging techniques for treatment, monitoring, and evaluation of liver metastases is also evaluated.

Methods: The study involves a review and analysis of existing literature on imaging techniques for liver metastases. Imaging methods such as ultrasonography, CT, MRI, PET/CT, and PET/MRI are examined, and their strengths and limitations are discussed.

Results: Both CT and MRI are considered suitable imaging techniques for detecting early liver lesions, monitoring progression, and assessing treatment effectiveness. Multiparametric MRI, in particular, has shown significant advancements in recent years, offering improved hardware, software, and specialized contrast agents. MRI has demonstrated superior performance in detecting small-sized metastases and cases of hepatic steatosis. However, despite the higher sensitivity of MRI, CT remains the preferred approach for imaging liver metastases.

Conclusion: CT and MRI are the primary imaging methods for liver metastases, with each having its advantages and limitations. While MRI has shown promising results, CT continues to be the preferred choice due to factors such as cost-effectiveness. Further research and discussions are necessary to address the economic implications of using CT instead of MRI for liver metastasis imaging.

Key Words: Liver metastases – Magnetic resonance imaging – Computed tomography – Oncology – Ultrasound – Follow-up.

Introduction

THE liver is often affected by metastatic illness. Secondary lesions are far more prevalent than initial liver tumors, with a frequency that is about 18-40 times higher [1,2]. The most common causes of liver metastases are colorectal carcinoma (40%), stomach cancer (20%), pancreatic cancer (20%), lung cancer (10%), and breast cancer (10%) [3]. Less common primary malignancies include neuroendocrine tumors (NETs), gastrointestinal stromal tumors (GISTs), and renal cell carcinomas [3].

The range of possible presentations is extensive. Liver metastases often appear as several and distinct lesions, however they may also be solitary or, less often, appear as merged masses [4]. Colon cancer is most often linked with the single mass style of presentation. Occasionally, breast cancer metastases may spread extensively throughout the liver, resembling cirrhosis, especially after chemotherapy.

Typically, solid liver metastases get their blood supply via arteries, which allows them to be categorized as either hypovascular or hypervascular [1]. The primary category of hypovascular metastases include colorectal cancer (CRC), gastric cancer, breast cancer, and lung cancer [5]. In contrast, hypervascular liver metastases are often seen in renal cell carcinoma, particularly the clear-cell variety, as well as in NETs, melanoma, thyroid carcinoma, and GISTs. Breast cancer liver metastases may exhibit both hypovascular and hypervascular characteristics. In addition, liver metastases may be cystic, originating from cystic primary tumors, such as ovarian carcinoma or mucinous cystadenocarcinoma of the gastrointestinal tract and pancreas. These may also occur as a result of GIST, leiomyosarco-

ma, malignant melanoma, carcinoid, and pheochromocytoma [1]. Calcification may occur in mucinous adenocarcinomas originating from the gastrointestinal tract or the ovaries, as well as in breast, lung, renal, and medullary thyroid carcinoma [6,7].

Imaging plays a crucial role in the identification, description, and precise localization of metastases in patients with stage IV illness, particularly in the context of oncologic liver resection or local ablation. Selected individuals with oligometastatic illness undergo surgery and other interventional radiologic procedures. Stage IV colorectal cancer (CRC) is characterized by the presence of distant metastasis, which may be limited to a single organ or location (stage IVa) or might include several organs or sites, as well as the peritoneum (stage IVb). The last decade has witnessed a paradigm change in stage IV or metastatic CRC (mCRC) care, resulting to a dramatic improvement in overall survival for these patients, from less than 6 mo to over 2 years [6]. The success of treating individuals with oligometastatic liver disease may be largely attributed to the greater use of hepatectomy, the advancement of chemotherapy regimens, and the discovery of novel molecular targets and their inhibitors. Imaging is crucial in evaluating patients with mCRC as it aids in quantifying the quantity and locations of metastases, determining whether surgery is possible, evaluating the effectiveness of systemic and liver-directed treatments, and detecting medication side effects and disease relapses.

Aim of work:

This study seeks to provide a concise overview of each imaging technology and thereafter analyze their effectiveness in detecting, characterizing, diagnosing, and evaluating treatment response for liver metastases.

Medical Imaging Techniques

Ultrasonography:

Ultrasonography (US) is a secure, easily available, and cost-effective method. However, there are significant limitations associated with this technique, such as reliance on the operator's experience, the patient's body structure, their level of cooperation, and the presence of intestinal gas interposition [8]. The decreased effectiveness of this method may also be attributed to its restricted spatial resolution, which may result in the failure to detect tiny (<3-5mm), isoechoic, and deeply located metastases [1,8]. The usual sensitivity of ultrasound (US) in the United States for identifying liver metastases is around 69%. This sensitivity range is based on studies that used a real gold standard, such as intraoperative US or resection, with reported sensitivities ranging from 50% to 76% [1,9]. The sensitivity is

likely to be reduced in individuals with lesions below the diaphragm, chronic liver disease, and severe fatty liver, which may be caused by chemotherapy. Furthermore, the uncertainty in segmental localization results in a deficiency in the ability to reproduce findings, in contrast to computed tomography (CT) and magnetic resonance imaging (MRI).

Metastases on ultrasonography have a varied appearance, however the majority have a spherical shape with either sharp or smooth edges. The echogenicity of the shown objects varies, with some being hypoechoic, some being isoechoic, and others being hyperechoic compared to the surrounding parenchyma. The hypoechoic pattern is the most often seen, accounting for 65% of cases [7]. Occasionally, a hypoechoic halo is seen in around 40% of cases, particularly when the lesion appears iso- or hyperechoic (Fig. 1) [7]. Hepatic metastases of colorectal cancer (CRC) are usually well defined, solid, and show as dark areas with reduced echoes on Doppler ultrasonography. They also tend to have a decreased blood supply and may sometimes exhibit a peripheral halo, resembling a "target" or "bull's-eye" pattern. The wide range of appearances makes it challenging to differentiate between benign and malignant tumors, resulting in decreased specificity [8].

CEUS has raised the sensitivity in detecting liver metastases. A research conducted by Kong et al., [10] examined 240 patients with liver metastases and found that the most prevalent pattern on contrast-enhanced ultrasound (CEUS) was diffuse homogeneous hyperenhancement followed by fast washout, with a prevalence of 55.4% and 96.2% respectively.

Regarding CEUS, there are conflicting findings, mostly due to variations in operator proficiency and other technical variables. Bernatik et al., [11] discovered that CEUS accurately identified 97% of the lesions that were diagnosed by CT [8,11]. Piscaglia et al., [12] analyzed a cohort of 109 individuals diagnosed with colorectal and stomach cancer. The study shown that Contrast-Enhanced Ultrasound (CEUS) significantly enhances the accuracy of detecting liver metastases, with a sensitivity of 95.4%, compared to conventional Ultrasound (US) at 76.9% and Computed Tomography (CT) at 90.8% [12]. Cantisani et al., [8,13] shown that the use of contrast-enhanced ultrasound (CEUS) significantly increased the sensitivity of ultrasound (US) from a range of 67.4%-71.6% to a range of 93.4%-95.8%. However, Vialle et al., [14] found that the sensitivity of CEUS in identifying hepatic metastases from colorectal cancer was lower compared to CT (CEUS 64.5% vs CT 80.4%). Furthermore, due to the presence of many lesions in metastatic liver disease, evaluating each lesion would require administering repeated doses of ultrasonography contrast agent [7].

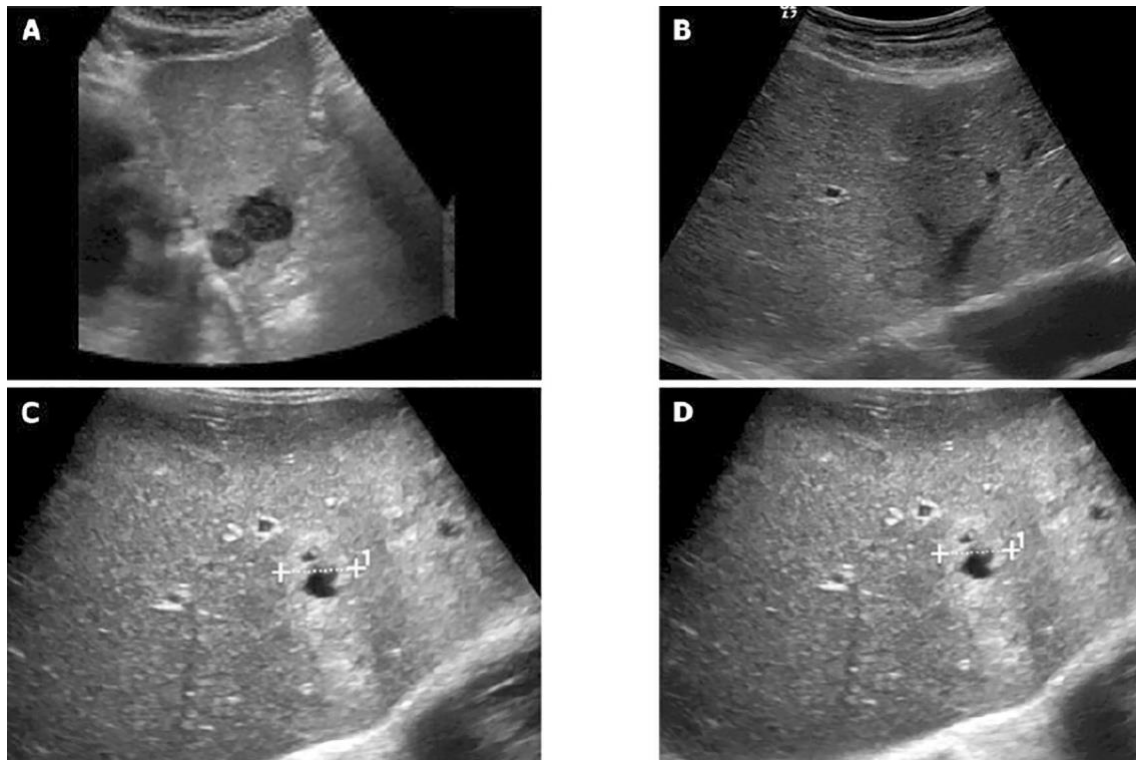


Fig. (1): Ultrasound pictures showing the varying levels of brightness in liver metastases.

The accuracy of hepatic lesion identification may vary depending on the ultrasound mode used. The evaluation of liver metastases using two-dimensional (2D) CEUS is limited due to its susceptibility to sampling mistakes, such as capturing the image of just one part and variations in perfusion across different planes. In contrast, three-dimensional (3D) CEUS imaging systems have the capability to capture the whole tumor, provide spatial details, and generate volumetric pictures. El Kaffas et al., [15] demonstrated that 3D dynamic CEUS outperforms 2D dynamic CEUS imaging by minimizing sampling errors caused by variations in tumor perfusion. Previous research has shown that there are no notable disparities in sensitivity between the two approaches [16]. However, the 3D CEUS enhances the visualization of the feeding arteries, perhaps aiding in the treatment of hypervascular liver metastases [16].

Computed Tomography:

Advancements in cross-section imaging methods, such as CT and positron emission tomography (PET)/CT, have significantly improved the early and precise identification of liver metastasis [17]. Multi-detector CT is a dependable method for identifying liver metastases and assessing the stage before surgery. It enables the collection of volumetric data and the creation of high-quality pictures in many planes. Additionally, it allows for the computation of liver volume and the generation of 3D models to aid in preoperative planning for tumor removal [3]. Com-

puted tomography (CT) is a rapid and easily accessible imaging technique that provides high-quality images of the liver as well as the whole abdomen and chest. Additionally, CT may accurately detect diseases outside of the liver. The CT scan has a specificity of 77.3% and a sensitivity of up to 73.5% in detecting liver metastases [19].

Liver metastases often manifest as nodules with lower or similar density on unenhanced CT scans. These nodules typically have clear boundaries, however their shape may vary depending on their size [6]. Necrosis and cystic transformation may be seen, manifesting as a core region with reduced density. In addition, liver metastases might sometimes exhibit substantial attenuation as a result of hemorrhagic content [3].

Dynamic imaging is essential, and its concept, perception, and assessment are comparable across CT and MRI (Fig. 2). The majority of liver metastases have reduced blood supply and may be most effectively identified during the portal venous phase (PVP), which typically starts about 60-80 seconds after the first injection. During this stage, the liver tissue is stimulated to increase in size and function due to the primary blood supply from the portal vein. Hypovascular metastases are seen as lesions that have lower density or attenuation relative to the surrounding liver tissue [1]. The typical presentation is a peripheral rim enhancement during the late arterial phase (LAP), which gradually diminishes to-

wards the center during the venous phase, creating a “target appearance” [5,6]. However, hypervascular metastases show early enhancement in the liver arterial phase (LAP), as seen by contrast in the portal vein and lack of contrast in the hepatic veins. These

abnormalities may diminish and become of equal density with the rest of the liver tissue or exhibit varying levels of contrast washout in the portal venous phase (PVP) and delayed imaging sequences [5,6,20].

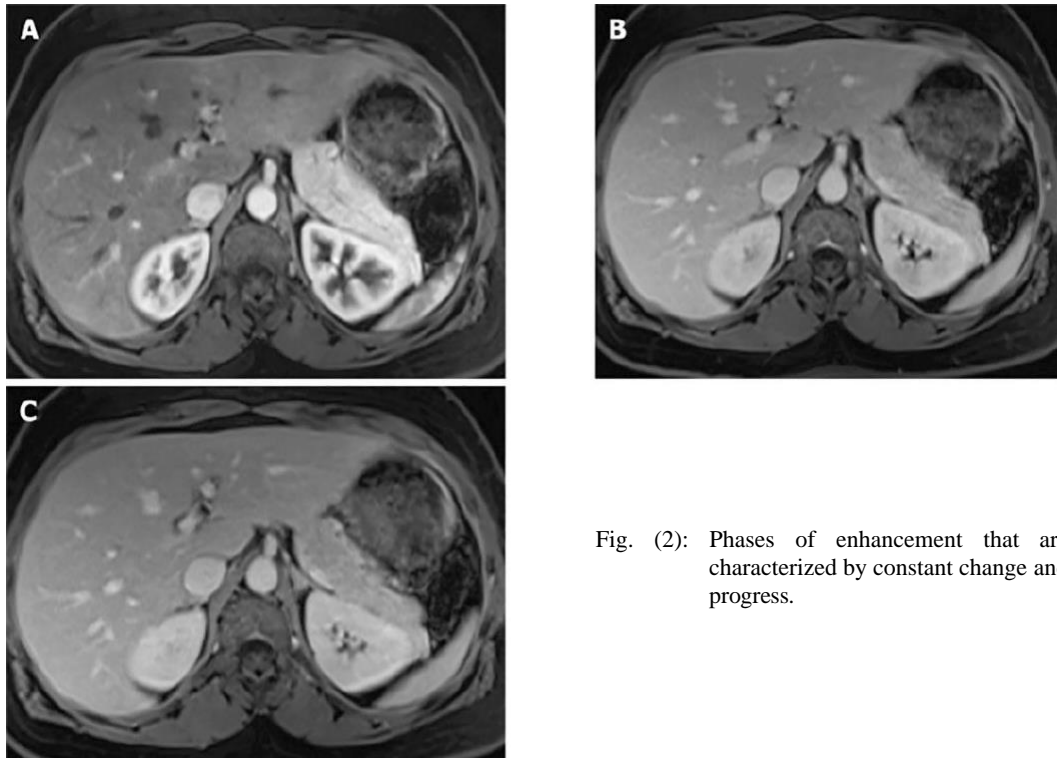


Fig. (2): Phases of enhancement that are characterized by constant change and progress.

The PVP, or portal venous phase, is often regarded as the most crucial stage due to its high sensitivity of 91.5% in identifying hypovascular metastases [21]. Nevertheless, there is still ongoing discussion over the most advantageous number and selection of acquisition phases, due to the possible hazards associated with increased radiation exposure [1]. Honda et al., [22] demonstrated that the use of a liver acquisition with volume acceleration protocol (LAP) enhanced the capacity to identify liver metastases, especially in lesions measuring less than 10mm. Nevertheless, another research conducted by Ferlay et al., [23] revealed that the inclusion of the LAP and delayed phases did not enhance the effectiveness of assessing CRC liver metastases when compared to using just the PVP.

Based on current data, non-contrast-enhanced CT (NE-CT) provides only a little additional benefit compared to contrast-enhanced CT (CE-CT) in detecting and characterizing hypervascular metastases. It seems that there is no benefit in exposing oneself to further radiation and increasing the amount of pictures for interpretation that come with NE-CT acquisition [24]. However, NE-CT may be beneficial as calcifications are detected in as many as 11% of liver metastases on the first presentation [25,26].

CT is often used for abdominal imaging staging; nevertheless, it is possible for liver metastases to go undetected. The CT detection rate of lesions reduces as their diameter decreases. Lesions measuring 10-20mm have an estimated detection rate of 72%, whereas lesions smaller than 10mm have a detection rate of 16% [19]. Benoist et al., [27] shown that the incidence of undetected liver lesions during chemotherapy might reach up to 83%. A recent research found that liver metastases without adequate contrast enhancement, as well as subcapsular lesions, were more likely to be missed in situations of hepatic steatosis or when the examination was not specifically focused on identifying malignant tumors [17].

Research has shown that capturing images at the precise vascular phase of contrast and with a sufficient iodine content (300-400mg/mL) is crucial for enhancing the capacity to identify hypoattenuating metastases [28]. Nevertheless, it is shown that increased contrast concentration might have detrimental effects on individuals with compromised renal function and may result in contrast-induced nephropathy. Given that patients often need several tests and prolonged follow-up periods, it is crucial to evaluate the potential harm of radiation exposure, which is a significant drawback of CT scans. The

availability of dual-energy CT (DE-CT) scanners is increasing steadily. It requires obtaining several CT readings with different energy spectra. DE-CT utilizes the differential attenuation of tissues and materials at various X-ray energy to distinguish tissues and materials in a more advanced manner compared to traditional CT [29].

A research comparing the use of DE-CT-driven low-keV virtual monoenergetic imaging to conventional linearly blended pictures found that the low-keV images enhanced the accuracy of measuring the extent of colorectal cancer liver metastases and increased diagnostic accuracy [30]. Furthermore, this novel approach enhances the precision of CT scans in distinguishing between liver abscesses and liver metastases, particularly in cases with hypovascular metastases, which is a frequently encountered clinical challenge. This approach has the potential to enhance the visibility of both hypervascular and hypovascular liver lesions, hence boosting the accuracy of CT scans in identifying metastases, particularly in situations where there is also hepatic steatosis [31].

Magnetic resonance imaging (MRI):

Multiparametric MRI is often used as a diagnostic method to address issues related to the assessment of liver abnormalities. Over the last decade, MRI has seen significant advancements, including improvements in both technology and software, as well as the introduction of particular intravenous contrast agents [3]. Technological advancements have the potential to enhance the quality of imaging in patients who are uncooperative, which is a major obstacle in MRI. Hence, while evaluating the efficacy of this imaging technology, it is crucial to take into account the latest advancements in the area of MRI and give preference to the most current research.

MRI enables the assessment of anatomical and morphological characteristics, as well as the visualization of functional processes. The ability to identify hepatic metastases is roughly 87% and has improved with the use of diffusion-weighted imaging (WI) and hepatocyte-specific contrast agents, achieving a sensitivity of 95% [21,26]. This technology greatly enhances the diagnostic effectiveness and precision in the approach to liver metastases. Multiple studies have shown that CT scans are less effective than other methods, particularly when it comes to identifying tiny liver lesions [32,33].

In contrast to computed tomography (CT), magnetic resonance imaging (MRI) relies on non-enhanced sequences to effectively identify and characterize liver metastases. Metastases often seem darker to the same intensity on T1-weighted imaging sequences and somewhat brighter on T2-weighted imaging [1]. Nevertheless, some liver metastases, particularly those originating from NETs and sar-

comas, could have a modestly elevated signal on T2-weighted imaging (T2-WI). Furthermore, cystic and necrotic metastases originating from ovarian tumors, NETs, melanoma, and sarcomas might exhibit a significant increase in T2 signal strength, ranging from mild to marked [3]. In certain cases, liver metastases may exhibit intralesional bleeding, fat, or glycogen deposition, causing them to look hyperintense on T1-weighted images. Furthermore, it is worth noting that melanoma and mucinous adenocarcinoma metastases provide a strong signal on T1-weighted images as a result of their elevated melanocytic and mucin composition, respectively. At times, they may be seen as a target indication on T2-WI sequences, with a bright center indicating necrosis surrounded by a less intense ring of live tumor. The doughnut sign refers to the presence of a hypointense rim encircling a core of even lower signal intensity on T1-weighted images [1,6].

Diffusion-weighted imaging (DWI)-MRI enables the examination of the cellularity of lesions by using the movement of water molecules. Tissues that have a large number of cells, such as tumors, fibrosis, abscesses, and cytotoxic edema, have limited diffusion [1]. The quantification of diffusion may be done using the apparent diffusion coefficient (ADC), where low ADC values indicate limitation. The reported range of ADC values is 0.94-2.87. However, there is a possibility of overlap between the ADC values of primary malignant hepatocellular lesions, such as hepatocellular carcinoma, and benign hepatic lesions [34]. In clinical practice, the assessment of DWI depends on subjective perception. DWI may have drawbacks because of its naturally limited ability to accurately depict spatial details, its low ratio of signal strength to background noise, and its tendency to produce artifacts, particularly when imaging lesions located behind the liver capsule or below the diaphragm. Kim et al., [35] found that DWI has a better sensitivity than CT (79% vs 50%) in detecting tiny liver metastases (<1cm). Additional research has shown that diffusion-weighted imaging (DWI) is more responsive than unenhanced T2-weighted imaging (T2-WI), with sensitivity rates of 88%-91% compared to 45%-62%. This disparity becomes even more pronounced when focusing just on tiny metastases, with rates of 85% for DWI against 35% for T2-WI [36,37].

In order to accurately characterize liver metastases, it is essential to integrate both pre- and post-contrast sequences, as previously stated. Once the extracellular gadolinium-based contrast agent (GBCA) enters the liver via the portal vein and hepatic artery, it is disseminated throughout the extracellular interstitial space [1]. The intended outcome is to improve the visibility of tissues on T1-weighted images (T1-WI) by reducing the T1 and T2 relaxation durations of nearby hydrogen protons. The recommended dosage for liver imaging is 0.1 millimoles per kilogram, given as a rapid injection at a

rate of 2-3 milliliters per second [38]. When comparing iodine-based contrast agents used on CT scans, we discover that gadolinium-based contrast agents (GBCAs) have a higher sensitivity and a larger ability to enhance the image. GBCAs are deemed safe due to their lack of nephrotoxicity at approved dosages and lower incidence of acute responses compared to iodinated contrast agents. While some institutions may still choose not to administer GBCAs to patients with renal impairment, it is important to note that class II contrast agents are seldom linked to nephrogenic systemic fibrosis. It is necessary to do a risk-benefit analysis for each individual [39,40].

In addition to chemotherapy, ablative treatments such as microwave ablation, transarterial chemoembolization, and radioembolization result in a low-density lesion on CT scans and a high T1 signal / low T2 signal on MRI scans owing to coagulative necrosis [3]. Over time, these patches have a tendency to gradually decrease in size. The presence of a prominent thick linear peripheral enhancement encircling the lesion or nodular enhancement may indicate the likelihood of recurrence. Partial response is indicated by a reduction in enhancement, whereas a full response or effective embolization is characterized by the lack of enhancement on CT/MRI and a low T2 signal [3].

Conclusion:

The liver is often affected by metastatic illness. CT and MRI are now the most effective diagnostic modalities for determining therapeutic response and follow-up. Research has shown that MRI is essential and has a greater ability to detect and assess liver metastases. Thus, it is potentially the optimal imaging modality for treatment planning before to and during neoadjuvant chemotherapy, and is widely regarded as the superior approach for detection and monitoring in several academic medical centers.

References

- 1- LINCKE T. and ZECH C.J.: Liver metastases: Detection and staging. *Eur. J. Radiol.*, 97: 76-82, 2017.
- 2- NAMASIVAYAM S., MARTIN D.R. and SAINI S.: Imaging of liver metastases: MRI. *Cancer Imaging*, 7: 2-9, 2007.
- 3- MATOS A.P., ALTUN E., RAMALHO M., VELLONI F., ALOBAIDY M. and SEMELKA R.C.: An overview of imaging techniques for liver metastases management. *Expert Rev. Gastroenterol. Hepatol.*, 9: 1561-1576, 2015.
- 4- SILVA A.C., EVANS J.M., MCCULLOUGH A.E., JATOI M.A., VARGAS H.E. and HARA A.K.: MR imaging of hypervascular liver masses: A review of current techniques. *Radiographics*, 29: 385-402, 2009.
- 5- GORE R.M., THAKRAR K.H., WENZKE D.R., NEW-MARK G.M., MEHTA U.K. and BERLIN J.W.: That liver lesion on MDCT in the oncology patient: Is it important? *Cancer Imaging*, 12: 373-384, 2012.
- 6- SICA G.T., JI H. and ROS P.R.: CT and MR imaging of hepatic metastases. *AJR Am. J. Roentgenol.*, 174: 691-698, 2000.
- 7- ALBRECHT T.: Detection and Characterisation of Liver Metastases. In: *Enhancing the Role of Ultrasound with Contrast Agents*. 1st ed. Lencioni R editor. Milano: Springer, 53-67, 2006.
- 8- CANTISANI V., GRAZHDANI H., FIORAVANTI C., ROSIGNUOLO M., CALLIADA F., MESSINEO D., BERNIERI M.G., REDLER A., CATALANO C. and D'AMBROSIO F.: Liver metastases: Contrast-enhanced ultrasound compared with computed tomography and magnetic resonance. *World J. Gastroenterol.*, 20: 9998-10007, 2014.
- 9- TIRUMANI S.H., KIM K.W., NISHINO M., HOWARD S.A., KRAJEWSKI K.M., JAGANNATHAN J.P., CLEARY J.M., RAMAIIYA N.H. and SHINAGARE A.B.: Update on the role of imaging in management of metastatic colorectal cancer. *Radiographics*, 34: 1908-1928, 2014.
- 10- KONG W.T., JI Z.B., WANG W.P., CAI H., HUANG B.J. and DING H.: Evaluation of Liver Metastases Using Contrast-Enhanced Ultrasound: Enhancement Patterns and Influencing Factors. *Gut Liver*, 10: 283-287, 2016.
- 11- BERNATIK T., STROBEL D., HAHN E.G. and BECKER D.: Detection of liver metastases: Comparison of contrast-enhanced wide-band harmonic imaging with conventional ultrasonography. *J. Ultrasound Med.*, 20: 509-515, 2001.
- 12- PISCAGLIA F., LENCIONI R., SAGRINI E., PINA C.D., CIONI D., VIDILI G. and BOLONDI L.: Characterization of focal liver lesions with contrast-enhanced ultrasound. *Ultrasound Med. Biol.*, 36: 531-550, 2010.
- 13- CANTISANI V., RICCI P., ERTURK M., PAGLIARA E., DRUDI F., CALLIADA F., MORTELE K., D'AMBROSIO U., MARIGLIANO C., CATALANO C., MARIN D., DI SERI M., LONGO F. and PASSARIELLO R.: Detection of hepatic metastases from colorectal cancer: Prospective evaluation of gray scale US vs SonoVue® low mechanical index real time-enhanced US as compared with multidetector-CT or Gd-BOPTA-MRI. *Ultraschall Med.*, 31: 500-505, 2010.
- 14- VIALLE R., BOUCEBCI S., RICHER J.P., VELASCO S., HERPE G., VESSELLE G., INGRAND P. and TASU J.P.: Preoperative detection of hepatic metastases from colorectal cancer: Prospective comparison of contrast-enhanced ultrasound and multidetector-row computed tomography (MDCT) *Diagn Interv Imaging*, 97: 851-855, 2016.
- 15- EL KAFFAS A., SIGRIST R.M.S., FISHER G., BACHAWAL S., LIAU J., WANG H., KARANANY A., DUROT I., ROSENBERG J., HRISTOV D. and WILLMANN J.K.: Quantitative Three-Dimensional Dynamic Contrast-Enhanced Ultrasound Imaging: First-In-Human Pilot Study in Patients with Liver Metastases. *Theranostics*, 7: 3745-3758, 2017.
- 16- LEE J.C., YAN K., LEE S.K., YANG W. and CHEN M.H.: Focal Liver Lesions: Real-time 3-Dimensional Contrast-Enhanced Ultrasonography Compared With 2-Dimen-

- sional Contrast-Enhanced Ultrasonography and Magnetic Resonance Imaging. *J. Ultrasound Med.*, 36: 2015-2026, 2017.
- 17- NAKAI H., ARIZONO S., ISODA H. and TOGASHI K.: Imaging Characteristics of Liver Metastases Overlooked at Contrast-Enhanced CT. *AJR Am. J. Roentgenol.*, 212: 782-787, 2019.
 - 18- KULEMANN V., SCHIMA W., TAMANDL D., KACZIREK K., GRUENBERGER T., WRBA F., WEBER M. and BA-SSALAMAH A.: Preoperative detection of colorectal liver metastases in fatty liver: MDCT or MRI? *Eur. J. Radiol.*, 79: e1-e6, 2011.
 - 19- SAHANI D.V., BAJWA M.A., ANDRABI Y., BAJPAI S. and CUSACK J.C.: Current status of imaging and emerging techniques to evaluate liver metastases from colorectal carcinoma. *Ann. Surg.*, 259: 861-872, 2014.
 - 20- KAMAYA A., MATUREN K.E., TYE G.A., LIU Y.I., PARTI N.N. and DESSER T.S.: Hypervascular liver lesions. *Semin Ultrasound CT MR*, 30: 387-407, 2009.
 - 21- TORRE L.A., BRAY F., SIEGEL R.L., FERLAY J., LORTET-TIEULENT J. and JEMAL A.: Global cancer statistics, 2012. *CA Cancer J. Clin.*, 65: 87-108, 2015.
 - 22- HONDA Y., HIGAKI T., HIGASHIHORI H., MONZEN Y., TATSUGAMI F., DATE S. and AWAI K.: Re-evaluation of detectability of liver metastases by contrast-enhanced CT: Added value of hepatic arterial phase imaging. *Jpn. J. Radiol.*, 32: 467-475, 2014.
 - 23- FERLAY J., COLOMBET M., SOERJOMATARAM I., DYBA T., RANDI G., BETTIO M., GAVIN A., VISSER O. and BRAY F.: Cancer incidence and mortality patterns in Europe: Estimates for 40 countries and 25 major cancers in 2018. *Eur. J. Cancer*, 103: 356-387, 2018.
 - 24- SADIGH G., APPLGATE K.E. and BAUMGARTEN D.A.: Comparative accuracy of intravenous contrast-enhanced CT vs noncontrast CT plus intravenous contrast-enhanced CT in the detection and characterization of patients with hypervascular liver metastases: A critically appraised topic. *Acad Radiol.*, 21: 113-125, 2014.
 - 25- HALE H.L., HUSBAND J.E., GOSSIOS K., NORMAN A.R. and CUNNINGHAM D.: CT of calcified liver metastases in colorectal carcinoma. *Clin. Radiol.*, 53: 735-741, 1998.
 - 26- PAULATTO L., DIOGUARDI BURGIO M., SARTORIS R., BEAUFRÈRE A., CAUCHY F., PARADIS V., VILGRAIN V. and RNOT M.: Colorectal liver metastases: Radiopathological correlation. *Insights Imaging*, 11: 99, 2020.
 - 27- BENOIST S., BROUQUET A., PENNA C., JULIÉ C., EL HAJJAM M., CHAGNON S., MITRY E., ROUGIER P. and NORDLINGER B.: Complete response of colorectal liver metastases after chemotherapy: Does it mean cure? *J. Clin. Oncol.*, 24: 3939-3945, 2006.
 - 28- JO B.G., SONG Y.G., SHIM S.G. and KIM Y.W.: Comparison of enhancement and image quality: Different iodine concentrations for liver on 128-slice multidetector computed tomography in the same chronic liver disease patients. *Korean J. Intern. Med.*, 31: 461-469, 2016.
 - 29- RAJIAH P., PARAKH A., KAY F., BARUAH D., KAMBADAKONE A.R. and LENG S.: Update on Multienergy CT: Physics, Principles, and Applications. *Radiographics*, 40: 1284-1308, 2020.
 - 30- LENGA L., LANGE M., ARENDT C.T., BOOZ C., YEL I., BODELLE B., D'ANGELO T., HAMMERSTINGL R.M., HUIZINGA N.A., VOGL T.J., MARTIN S.S. and ALBRECHT M.H.: Measurement Reliability and Diagnostic Accuracy of Virtual Monoenergetic Dual-Energy CT in Patients with Colorectal Liver Metastases. *Acad. Radiol.*, 27: e168-e175, 2020.
 - 31- LENGA L., LANGE M., ARENDT C.T., YEL I., BOOZ C., DURDEN J., LEITHNER D., VOGL T.J., ALBRECHT M.H. and MARTIN S.S.: Can Dual-energy CT-based Virtual Monoenergetic Imaging Improve the Assessment of Hypodense Liver Metastases in Patients With Hepatic Steatosis? *Acad. Radiol.*, 28: 769-777, 2021.
 - 32- VREUGDENBURG T.D., MA N., DUNCAN J.K., RIITANO D., CAMERON A.L. and MADDERN G.J.: Comparative diagnostic accuracy of hepatocyte-specific gadoteric acid (Gd-EOB-DTPA) enhanced MR imaging and contrast enhanced CT for the detection of liver metastases: A systematic review and meta-analysis. *Int. J. Colorectal Dis.*, 31: 1739-1749, 2016.
 - 33- LEE K.H., LEE J.M., PARK J.H., KIM J.H., PARK H.S., YU M.H., YOON J.H., HAN J.K. and CHOI B.I.: MR imaging in patients with suspected liver metastases: Value of liver-specific contrast agent gadoteric acid. *Korean J. Radiol.*, 14: 894-904, 2013.
 - 34- KANEMATSU M., KONDO H., GOSHIMA S., KATO H., TSUGE U., HIROSE Y., KIM M.J. and MORIYAMA N.: Imaging liver metastases: Review and update. *Eur. J. Radiol.*, 58: 217-228, 2006.
 - 35- KIM H.J., LEE S.S., BYUN J.H., KIM J.C., YU C.S., PARK S.H., KIM A.Y. and HA H.K.: Incremental value of liver MR imaging in patients with potentially curable colorectal hepatic metastasis detected at CT: A prospective comparison of diffusion-weighted imaging, gadoteric acid-enhanced MR imaging, and a combination of both MR techniques. *Radiology*, 274: 712-722, 2015.
 - 36- BRUEGEL M. and RUMMENY E.J.: Hepatic metastases: Use of diffusion-weighted echo-planar imaging. *Abdom Imaging*, 35: 454-461, 2010.
 - 37- WARD J.: New MR techniques for the detection of liver metastases. *Cancer Imaging*, 6: 33-42, 2006.
 - 38- GIUGA M., DE GAETANO A.M., GUERRA A., INFANTE A., IEZZI R., SPINELLI I., SICILIANO M., GRIECO A., RAPACCINI G.L., GASBARRINI A., POMPILI M. and BONOMO L.: An update on clinical applications of hepatospecific contrast media in magnetic resonance imaging of liver parenchyma. *Eur. Rev. Med. Pharmacol. Sci.*, 20: 2515-2525, 2016.
 - 39- SCHIEDA N., MARALANI P.J., HURRELL C., TSAMPALIEROS A.K. and HIREMATH S.: Updated Clinical

- Practice Guideline on Use of Gadolinium-Based Contrast Agents in Kidney Disease Issued by the Canadian Association of Radiologists. Can Assoc. Radiol J., 70: 226-232, 2019.
- 40- GOLDSTEIN K.M., LUNYERA J., MOHOTTIGE D., AMRHEIN T.J., ALEXOPOULOS A.S., CAMPBELL H., CAMERON C.B., SAGALLA N., CROWLEY M.J., DIETCH J.R., GORDON A.M., KOSINSKI A.S., CANTRELL S., WILLIAMS Jr. J.W. and GIERISCH J.M.: Risk of Nephrogenic Systemic Fibrosis after Exposure to Newer Gadolinium Agents. Washington (DC): Department of Veterans Affairs, 2019.

تحليل وسائل التصوير لاكتشاف آفات الكبد:

مراجعة

الخلفية: تعتبر الانتقالات الكبدية حدوثاً شائعاً في الأمراض الانتقالية وتلعب دوراً حاسماً في تحديد العلاج والتشخيص. يمكن استخدام طرق التصوير المختلفة، بما في ذلك الأمواج فوق الصوتية، والتصوير بالحاسوب المقطعي (CT)، والتصوير بالرنين المغناطيسي (MRI)، وتصوير الانبعاث الإيجابي بالتصوير المقطعي (PET/CT)، وPET/MRI، للتقييم غير الغازي للانتقالات الكبدية.

هدف العمل: يهدف هذا الدراسة إلى تقديم تحليل شامل لنتائج التصوير للانتقالات الكبدية، مع التركيز على الفوائد الفريدة والعيوب المحتملة لكل طريقة تصوير. كما يتم تقييم أهمية التقنيات التصويرية المختلفة لعلاج ومراقبة وتقييم الانتقالات الكبدية.

المنهجية: تتضمن الدراسة مراجعة وتحليل الأدبيات الحالية حول تقنيات التصوير للانتقالات الكبدية. يتم فحص طرق التصوير مثل الأمواج فوق الصوتية، وCT، وMRI، وPET/CT، وPET/MRI، ويتم مناقشة قواها وضعفها.

النتائج: يُعتبر كل من CT وMRI تقنيات تصوير مناسبة لاكتشاف الآفات الكبدية المبكرة، ومراقبة التطور، وتقييم فعالية العلاج. أظهرت MRI متعدد البرامترات تقدماً كبيراً في السنوات الأخيرة، مع تقديم تحسينات في الأجهزة والبرمجيات ووكلاء التباين المتخصصة. أظهرت MRI أداءً متفوقاً في اكتشاف الانتقالات الصغيرة الحجم وحالات الدهون الكبدية. ومع ذلك، على الرغم من الحساسية الأعلى لـ MRI، يظل CT الخيار المفضل لتصوير الانتقالات الكبدية.

الاستنتاج: CT وMRI هما الطرق الأساسية لتصوير الانتقالات الكبدية، حيث لكل منهما مزاياه وعيوبه. بينما أظهرت MRI نتائج واعدة، يستمر CT في كونه الخيار المفضل بسبب عوامل مثل التكلفة الفعالة. من الضروري إجراء مزيد من البحوث والنقاشات لمعالجة الآثار الاقتصادية لاستخدام CT بدلاً من MRI لتصوير الانتقالات الكبدية.