



Journal of Medical and Life Science
<https://jmls.journals.ekb.eg/>



SPBH

Histopathological and Hormone receptor changes associated with breast cancer in Missan province

Abbas, Ch. Mraisel, Sawsan A. Ibrahim, Eman K. Aati

Basic Medical Science Department, Nursing College, / Missan University, Iraq.

Abbas, Ch. Mraisel / Ph.D. Toxopathology / Basic Medical Science Department /Nursing College / Missan University,
Iraq.

Sawsan A. Ibrahim/ Ph.D. Toxicology/ Basic Medical Science Department /Nursing College / Missan University, Iraq.

Eman K.Aati/MSc Physiology/ Basic Medical Science Department /Nursing College / Missan University, Iraq.

DOI: [10.21608/jmls.2024.364033](https://doi.org/10.21608/jmls.2024.364033)

Abstract

Aim: The present study was performed to evaluate the histopathological examination and Immunohistochemical examination of Estrogen and Progesterone receptors according to the Allred scoring system and the detection of HER2 (c-erbB-2oncoprotien) according to the ASCO immunohistochemical scoring system. **Method:** The data and tissue specimens were collected from (83) women diagnosed with breast cancer after surgical operation from the laboratory of histopathology in Al-Sadder Teaching Hospital in Missan Province. **Results:** Histopathological examination of the tissue specimens observed the most breast cancer type was invasive ductal carcinoma (66.2%), followed by intraductal carcinoma (20.4%) and most of the breast cancer states were found in Stage II (40.4), followed Stage III (33.7). The commonest breast cancer was in GradII (54.2), followed by Grad III (28.9), and GradI (16.8). Immunohistochemical expression for ER and PR receptors found strong positive ER receptors (48.1%), moderately positive ER receptors (33.7%) and negative ER receptors (18.2%), also observed strongly positive PR receptors (51.8%), moderately positive PR receptors (31.3%) and negative PR receptors (16.8%). HER2/neu overexpression revealed positive scores in percentage (30.1%) while negative scores were observed in percentage (69.8%) of all cases of breast cancer.

Conclusion: Most breast cancer types were invasive ductal carcinoma followed by intraductal carcinoma. Immunohistochemical expression of ER and PR receptors were strongly positive ER receptors and strongly positive PR receptors. HER2/neu overexpression revealed negative scores, where HER2/neu negative means, the cancer does not tend to grow and spread faster than the HER2/neu positive but is not more likely to respond to the treatment with drugs that target the HER-2 protein.

Keywords: Breast cancer, Histopathological, Immunohistochemical (IHC), ER receptors, PR receptors, HER2 (c-erbB-2 oncoprotein).

Introduction

Breast cancer (BC) is the most common malignancy among women throughout the industrialized world. The incidence rate of breast cancer has increased steadily over the past 40 years. It is the second leading cause of cancer-related deaths in women in the world between the ages of 20 and 59 (1). The risk of breast cancer is influenced by multiple factors that make it difficult to modify menarche before 12 years and family history. A family history is a risk factor for the development of cancer in women if her mother, sister, or daughter had breast cancer, especially at a young age (before age 40); Also, genetics may play predisposal factors in breast cancer (2).

Breast cancer may increase in women who began their menstrual period at an early age or menopausal late (after age 55) or who never had children (3). The excess weight is another risk factor where weighing more than is healthy may develop the breast cancer, also the race may play a role in breast cancer where white women are more likely to be infected with breast cancer than the black women, but the black women are more likely to die (4).

Recent studies have shown that estrogen metabolites can bind to DNA and trigger damage suggesting that estrogen might be a complete carcinogen that can directly cause genetic alteration and effect in tumor initiation (5).

Breast cancer is classified by whether the cancer started in the ducts or lobules and whether the cells can be invaded (grow or spread) through the duct or lobule, but when the cancer is still in the breast lobules or ducts (referred to as noninvasive or carcinoma in situ), also when the cancer spreads beyond the walls of the ducts or lobules (6).

The estrogen receptor (ER), progesterone receptor (PR), and proto-oncogene *HER2/neu* (HER2) profile of a female primary breast carcinoma plays a significant role as a predictive marker in patient management. Current therapeutic strategies for the management of primary breast

carcinomas rely on the accurate immunohistochemical (IHC) determination of hormone receptor status to determine the clinical utility of hormone-directed therapies such as selective estrogen receptor modulators SERMs (7).

Patients with tumors that are diagnosed with positive ER and/or PR status have lower risks of mortality compared to women with negative ER and/or PR disease. Clinical trials have also demonstrated that the survival advantage for women with hormone receptor-positive tumors is increased by treatment with adjuvant hormonal and/or chemotherapeutic regimens. *HER2-neu*, which encodes a receptor tyrosine kinase, is amplified and over-expressed in 20-25% of breast cancers and such tumors are often resistant to hormone therapy (8).

Hormone receptors, such as the estrogen receptor (ER) and progesterone receptor (PR), are determinants of breast tumor behavior and may suggest etiologic pathways. ERs bind estrogen and facilitate protein synthesis, cell division, and breast cell proliferation. PRs, in turn, are regulated by circulating levels of estrogen. The presence of both estrogen and progesterone receptors in breast tumors has been associated with better survival and overall outcome (7).

HER-2/neu, a proto-oncogene, is the most commonly amplified oncogene in human breast cancer. *HER-2/neu* and ER alterations occur early in breast carcinogenesis (8). There is some evidence that *HER-2/neu* overexpression reflects distinct risk factor patterns, such as an association with early use of oral contraceptives. Tumors with *HER-2/neu* overexpression are characterized by poor prognosis and tend to be higher grade with hormone receptor-negative (9).

The presence or absence of estrogen receptors in the cytoplasm of tumor cells is of prime importance in managing patients with breast cancer. Patients whose primary tumors are receptor-positive have a more favorable course than those whose tumors are receptor-negative. On the other hand, many studies

suggested that breast cancer cells under estrogen control contain estrogen receptors, which bind with estrogen hormone to form a complex, then this complex is bound to promoter regions of specific genes to activate transcription of new mRNA and continue this process (10).

The present study was performed to evaluate histopathological examination to detect the common types of breast cancer, Immunohistochemical examination, and evaluation of Estrogen and Progesterone receptors according to the Allred scoring system and detection HER2 (c-erbB-2 oncoprotein) according to the ASCO immunohistochemical scoring system, which is important status to known prognostic as well as predictive markers in both node-negative and node-positive patients also consider as critical in determination of patients appropriate for treatment the breast cancer.

Material and methods

The data and tissue specimens were collected in the period between the first of October 2022 to the first of May 2023 from 83 patients women diagnosed with breast cancer after surgical operation at the oncology center, the samples were examined in the Laboratory of Histopathology in Al-Sadder Teaching Hospital in Missan Province. Tissue samples after collected fixed in 10% buffered formaldehyde for 72 hours and the sections were prepared by following the methods which were described by (Luna, 1968). Evaluation immunohistochemical (IHC) test for ER, PR, and HER-2/neu analysis was performed on specimens embedded in wax paraffin from the main tumors. (5 μ m) thick histological sections to detect the presence of hormone receptor (ER, PR) expression according to the following procedure described by (11). Primary tumors were assessed by using the Allred scoring system (ASCO System) based on scoring guidelines for ER and PR include A proportion score (PS) was estimated through the assessment of the proportion of tumor cells with positive nuclear staining and includes five grades.

An intensity score (IS) was estimated by the average staining intensity of all positive tumor cells and includes three grades and there are three levels of positivity, with scores (3–4), (5–6) and (7–8) representing the three levels. Scoring of the IHC staining for HER2/neu overexpression was according to ASCO (American Society of Clinical Oncology) as a guideline where the HER-2 expression based on the cell membrane staining pattern and to be considered affirmative, the staining reactions had to be seen in at least 10% of the malignant cells. The staining strength was assessed as strong (+3), medium (+2), or weak (+1). It was shown that 30% of malignant cells had a total black membrane staining that was positive and graded (+3) by HER2 testing. The equivocal staining reactions and/or heterogeneous staining distribution in less than 30% of cells were evaluated as (+2) in cases with thin membrane dubious staining reactions. The staining strength was assessed as strong (+3), medium (+2), or weak (+1). If the IHC examination is found in (0%) the breast cancer is considered negative and does not respond to the treatment with drug for target HER2, If the IHC examination is found in (+1 %) the breast cancer is considered negative and don not response to the treatment with drug for target HER2. If the IHC examination is found in (+2 %) breast cancer is considered equivocal and in some cases response to the treatment with drug for target HER2. If the IHC examination is found in (+3 %) breast cancer is considered positive and responds to the treatment with the drug for target HER2.

Statistical analysis.

Statistical analyses of the results were made with a one-way analysis of variance (ANOVA) using SPSS 17. The criterion for statistical significance was ($P < 0.05$).

Results

The data that were collected from the patients observed a high incidence of breast cancer in patients ages (46-55) years old represented (38.5%), followed by the ages (56-65) years old

which represented (32.5%) of all cases, while the lowest incidence of breast cancer observed in ages between (66 -75 or more) years which represented by (6.2 %) cases, (Fig. 1).

The histopathological examination of the tissue specimens of this study observed the most breast cancer type were invasive ductal carcinoma in percentage (66.2%), followed by intraductal carcinoma in percentage (20.4%) and invasive

lobular carcinoma in percentage (9.6 %), while the lowest type of breast cancer found squamous metaplasia in percentage (3.6%), Fig (2).

Clinicopathological examination observed that most of the breast cancer states were in **Stage II** in percentage (40.9), followed by **Stage III** in percentage (33.7), while less commonly observed in **Stage IV** in percentage (10.8), fig (3).

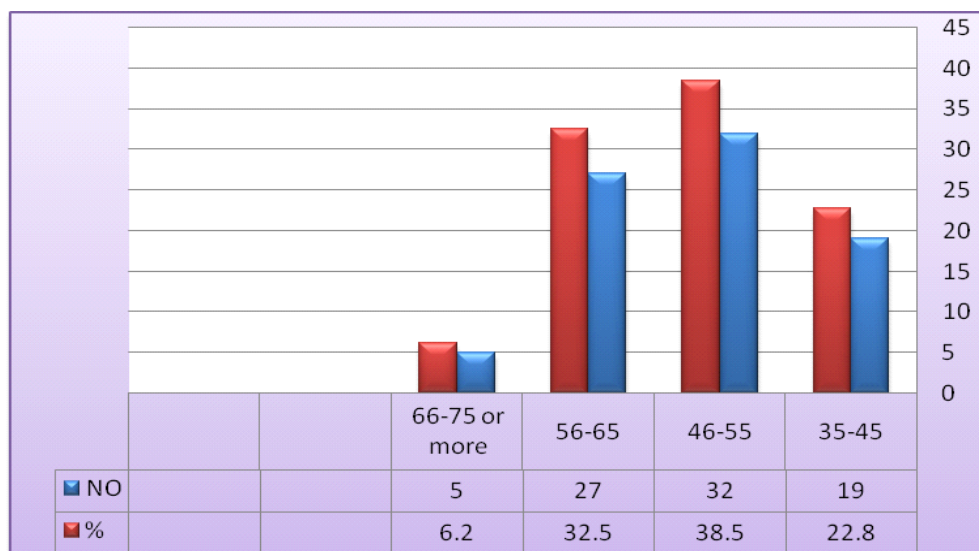


Fig (1) Observed the distribution of breast cancer among the patients based on ages

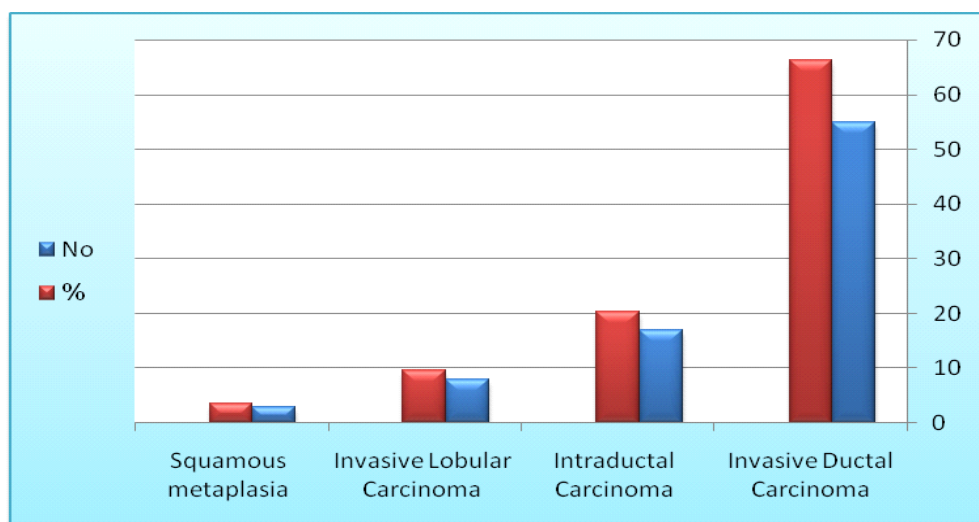


Fig (2) Shows the most common types of breast cancer observed in this study.

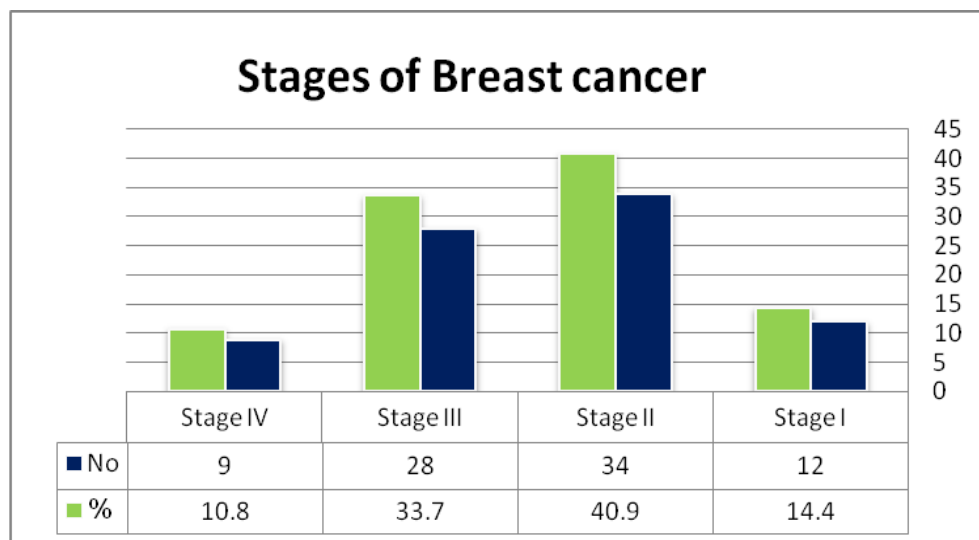


Fig (3) Shows the most common stages of breast cancer observed in this study.

Histopathological examination of the tissue specimens observed the commonest breast cancer was in **Grad II** in percentage (54.2), followed by **Grad III** in percentage (28.9), and **Grad I** in percentage (16.8), fig (4).

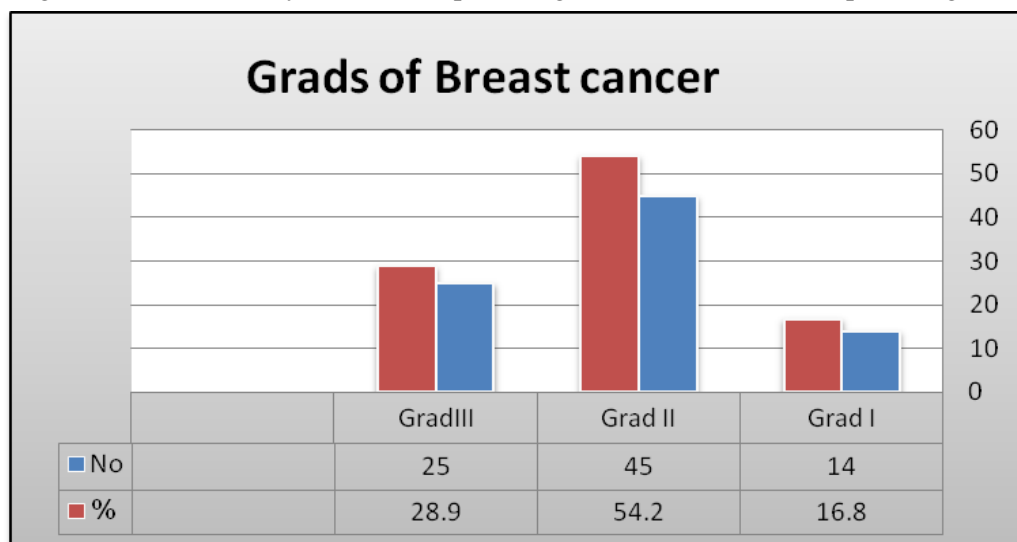


Fig (4) Shows the Grades of the breast cancer that were observed in this study.

The results of this study observed that the immunohistochemical expression of ER and PR receptors found strong positive ER in percentage (48.1%), moderately positive ER percentage (33.7%), and negative ER in percentage (18.2%), fig (5).

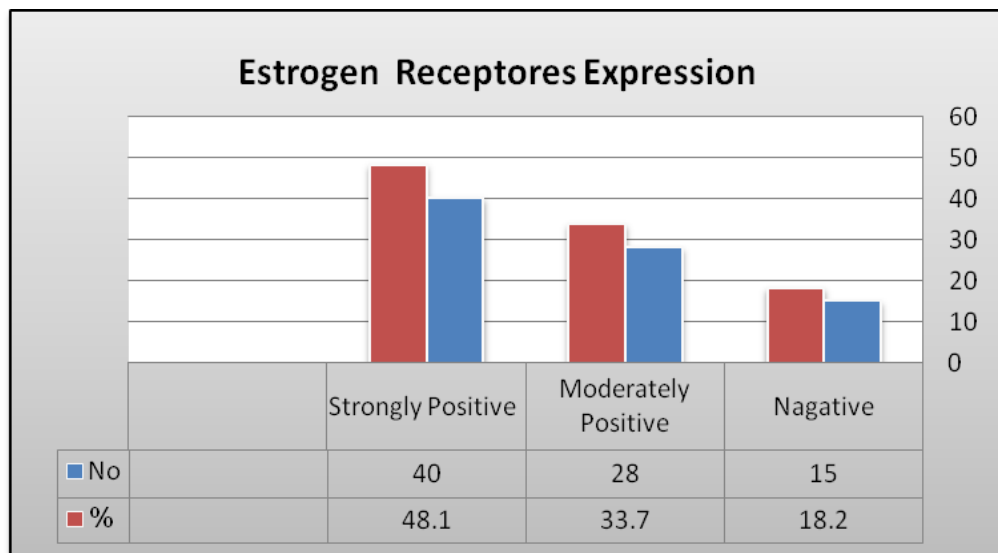


Fig (5) Shows the expression of estrogen receptors in the patients with breast cancer that was observed in this study.

Also, the results observed strongly positive PR in percentage (51.8%), moderately positive PR in percentage (31.3%), and negative PR in percentage (16.8%).

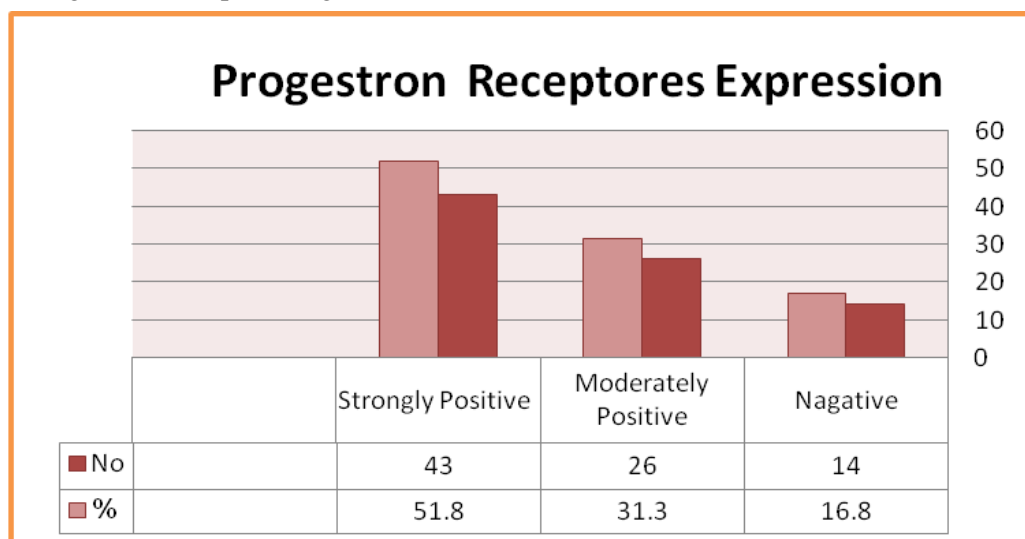


Fig (6) Shows the expression of progesterone receptors for the patients with breast cancer observed in this study.

Determination of human epidermal receptor protein-2 (c-erbB-2; HER2/neu) status is also important, where HER2/neu overexpression revealed positive scores in percentage (30.1%) while the negative scores observed in percentage (69.8%) of all cases.

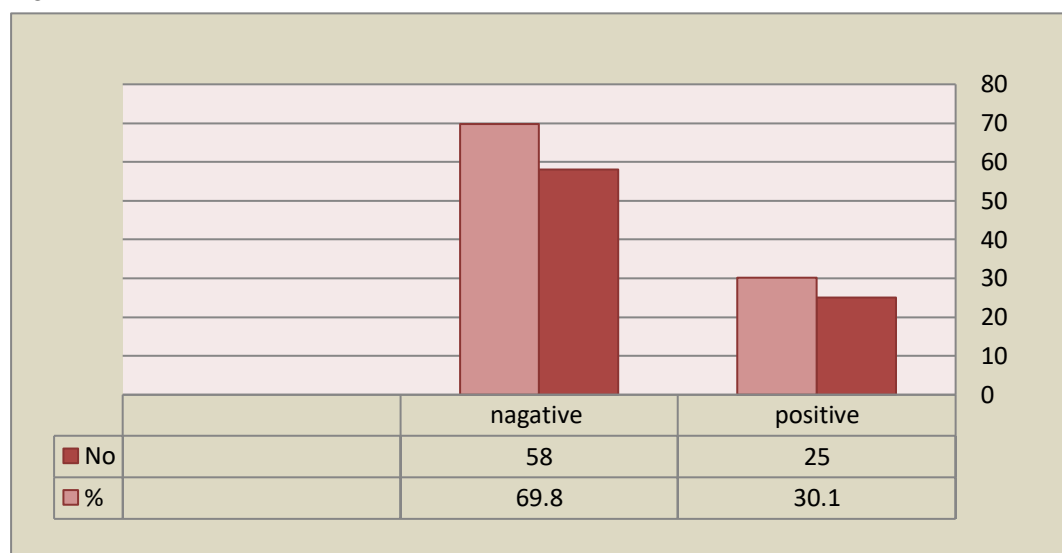


Fig (7) Show overexpression of c-erbB-2; HER2/neu for the patients with breast cancer that was observed in this study.

Histopathological results.

Invasive Ductal Carcinoma or Infiltrating Ductal Carcinoma indicates that the cancer cells that are in the milk ducts are now beginning to infiltrate and replace the normal surrounding tissues of the duct walls. The cancer cells have broken through the basement membrane of the duct and into the surrounding breast tissue, resulting in a mass. Invasive ductal carcinoma accounts for up to **80 %** of all breast cancers. The results of this study observed milky duct contains dense collagenous fibrous tissue among which lie small groups and strands of cancer cells, the ducts and the veins incorporated into the tumor often become unsheathed in a thick layer of elastic tissue, fig (8). Ductal carcinoma in situ, also called intraductal carcinoma, is a non-invasive or pre-invasive breast

cancer. This means the cells that line the ducts have changed to cancer cells but they have not spread through the walls of the ducts into the nearby breast tissue, it can't spread (metastasize) beyond the breast to other parts of the body. However, DCIS can sometimes become an invasive cancer. At that time, the cancer spread out of the duct into nearby tissue, and from there, it could metastasize to other parts of the body. The results of this study observed neoplastic cells are still within the ducts and have not broken and are infiltrated through into stroma, the duct is filled with carcinoma cells, the wall of the duct is irregular and the cancer cells grow to the lumen of the ducts, the myoepithelial layer is indistinct and the basement membrane appears to have been breached at several points, The stroma around the ducts are myxoid, fig (9).

Invasive lobular carcinoma starts in the milk-producing gland, or lobules of the breast, and has spread into surrounding breast tissue. It accounts for about 10% to 15% of all breast cancers and is the second most common type of breast cancer. Left untreated, lobular breast cancer spreads to nearby lymph nodes, and then to other areas of the body. The lobular carcinoma in this study starts in the milk-producing gland penetrates the basement membrane at one or more points in the duct and invades the stroma, the tumor cells are lying in a densely collagenous stroma with elongated nuclei, figs (10,11).

Squamous cell carcinoma (squamous metaplasia) of

the breast is an extremely rare type, representing less than 1% of all invasive breast carcinomas. The most common sources of metastatic squamous cell carcinoma of the breast are the lung, esophagus, cervix, and urinary bladder. There are no specific clinical and radiological signs for squamous cell carcinoma. For this reason, the nature or origin of the lesion needs to be determined. Microscopically the Squamous cell carcinoma in this study found the ducts are lined with large cells with deeply eosinophilic cytoplasm and relatively small nuclei, epithelial cells have secretory snouts and the layer of myoepithelial cells beneath the epithelial cells are visible, fig (12).

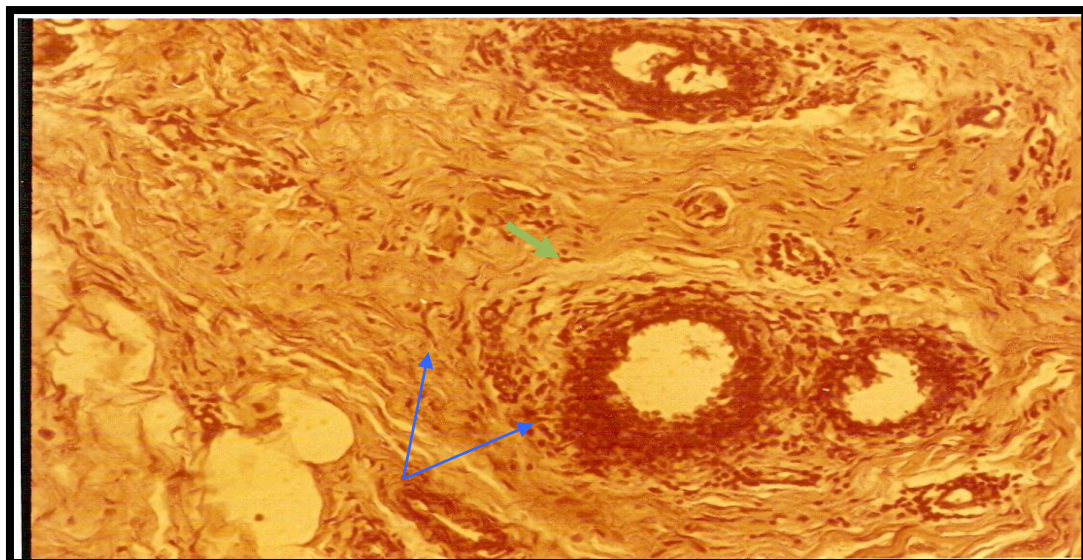


Fig (8): Invasive Ductal carcinoma of the breast note the small nests and infiltrating strands of neoplastic cells with prominent bands of collagen between them, also increased dense fibrous tissue stroma→ that produced the characteristic hard or cirrhoses appearance (400 X.H&E)

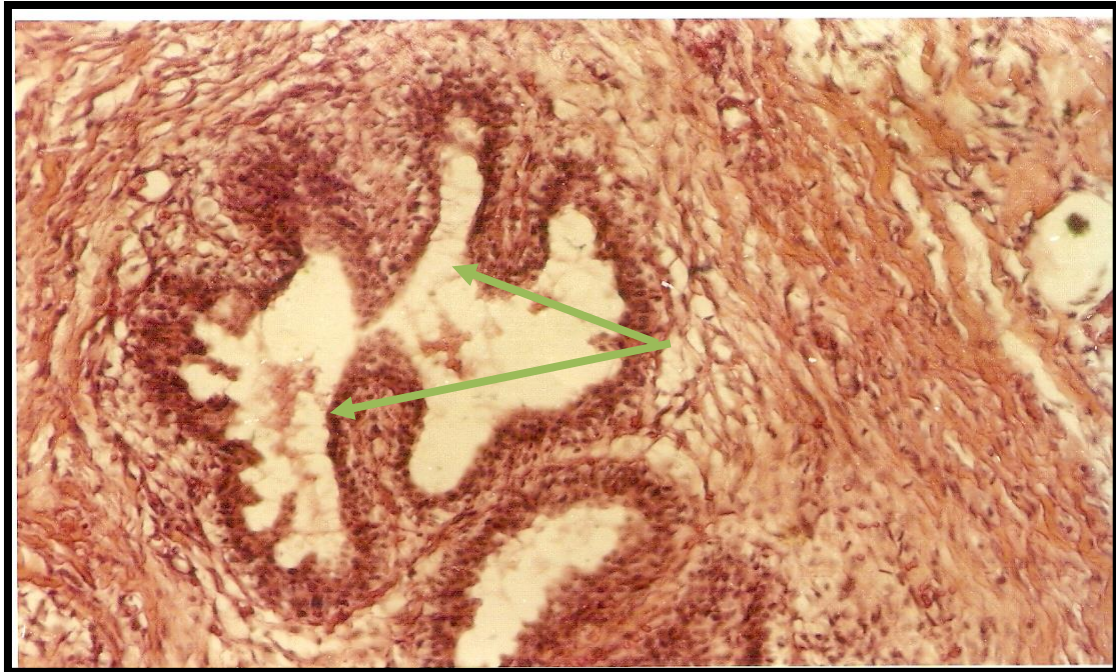

Fig (9): Intraductal carcinoma in which neoplastic cells are still within the ducts and have not broken through into stroma grade I. (400 X.H&E).

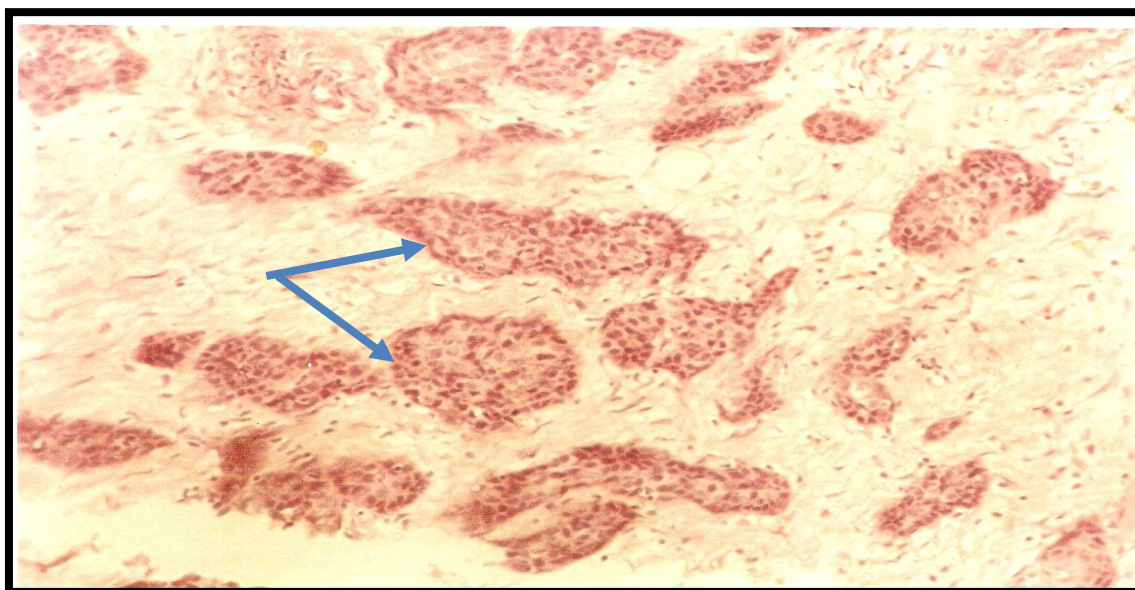


Fig (10): Lobular carcinoma consists of proliferation of cells in the neoplastic terminal breast ducts and acini, the cells are small and round grade III. (400X .H&E)

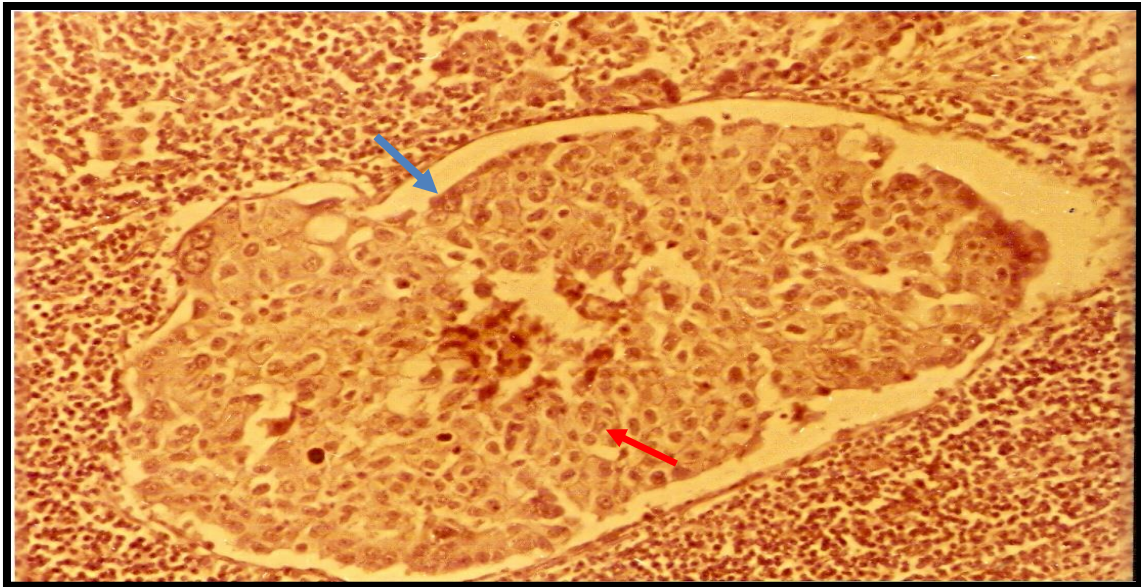


Fig (11): Lobular carcinoma consists of proliferation of cells in the neoplastic terminal breast ducts and acini, the cells are small and round grade III. (400X .H&E)

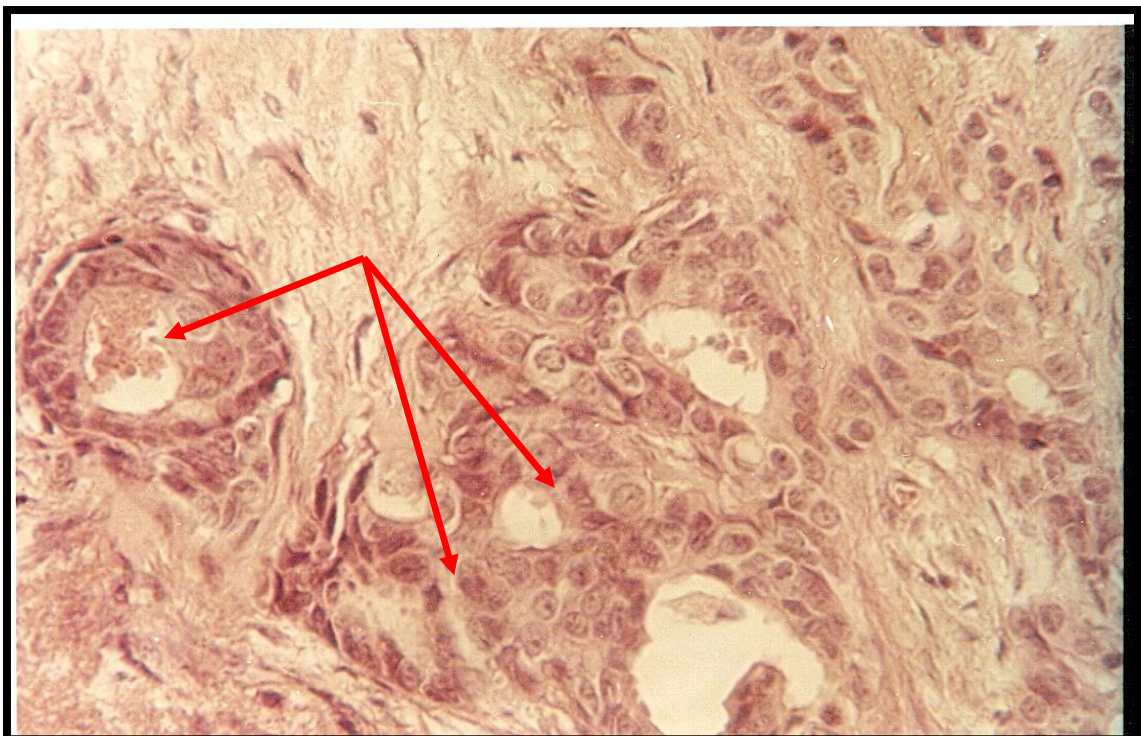

Fig (12): Breast carcinoma which appears as squamous metaplasia the cells of this breast carcinoma are better differentiated. (400X.H&E)

Discussion

The patients in this study observed a high incidence of breast cancer that has been seen in patients with ages (46-55) years. These results agree with (12) who found that breast cancer increases with the advance in age except in certain familial cases, and the increase of breast cancer occurs rapidly between (35-50) or more years after that it rises more slowly to the maximum in old age and most breast cancer death reported in ages 50 years or older, also agreement with (13) that found the risk of the breast cancer is high for women age 60 years or older and the incidence rates of the invasive breast cancer did not increase for women under age 40 but Ductal Carcinoma "insitu" (DCIS) increased for women of all ages during the same time. The study observed that most breast cancer types were invasive ductal carcinoma, followed by intraductal carcinoma and invasive lobular carcinoma while the lowest type of breast cancer was squamous metaplasia. Most (81%) breast cancers are invasive or infiltrating which means the abnormal cells have broken through the walls of the glands or ducts where they originated and grown into surrounding breast tissue and about 50% to 80% of newly diagnosed breast cancer cases are called invasive ductal carcinoma, while the rest of the cases are classified as invasive lobular carcinoma (14).

(12) reported that invasive ductal carcinoma is the most common type of breast cancer, which starts in the milk passage duct of the breast, and microscopically the duct contains dense collagenous fibrous tissue among which lie small groups and strands of cancer cells, the ducts and the veins incorporated into the tumor often become ensheated in a thick layer of elastic tissue.

Intraductal carcinoma was found in (20.4%) of cases of breast cancer in which neoplastic cells are still within the ductal and have not broken or infiltrated through into stroma, the duct filled with carcinoma cells, and the wall of the duct is irregular in outline, the myoepithelial layer is indistinct and the basement membrane appears to have been

breached at several points (arrows) and The stroma around the ducts are myxoid. (15) described intraductal carcinoma (Ductal carcinoma in situ) which is the most common type of non-invasive breast cancer where the cancer cells are inside the ducts but have not spread through the walls of the ducts into surrounding breast tissue.

Lobular carcinoma was reported in (9.6 %) of all cases infected with breast cancer characterized by the presence of tumor nests that consist of neoplastic proliferation of the cells in the terminal breast ducts and acini, the cells are small and rounded, also there's well-defined basement membrane around the ducts. The stroma around the ducts loses fibrous tissue and the lesion diagnosed lobular carcinoma insitue. (12) described invasive lobular carcinoma as a type of breast cancer that begins in the milk-producing gland and grows through the wall of the lobules and the ducts are filled with polygonal small cells with rounded or ovoid nuclei. The neoplastic proliferation of cells in the terminal breast duct and acini may develop into invasive carcinoma when the malignant cells break the duct and infiltrate lobular carcinoma, and the lesion consists of a small duct filled with tumor cells which are small and rounded.

Squamous metaplasia (also known as metaplastic carcinoma) is a very rare variant of invasive ductal carcinoma and is reported in (3.6%) of all breast cancer cases. This type of tumor includes cells that are not found normally in the breast such as cells that look like skin cells or cells that make bone (16).

Microscopically the ducts are lined with large cells with deeply eosinophilic cytoplasm and relatively small nuclei, epithelial cells have secretory snouts and the layer of myoepithelial cells beneath the epithelial cells is visible (17).

The results observed that most of the breast cancer states were found in Stage II (40.4), followed by Stage III (33.7). Giaquinto *et al* (18) reported that the overall increase in breast cancer incidence is large because of an increase in local-stage disease.

From 2012 to 2016 the incidence rate increased by 1.1% per year for local-stage breast cancer but declined by 0.8% per year for regional-stage disease, which may reflect a shift toward earlier stage at diagnosis. The incidence rate for distant-stage disease increased by 2.5% annually during 2001-2011 but has since stabilized. The increase in distant-stage disease may be partly explained by the decrease in unknown stage, because of more complete staging of advanced tumors and this trend may also reflect increased detection of asymptomatic metastases due to the rise in the use of advanced imaging (18). Approximately 64% of breast cancer patients have local-stage breast cancer, 27% have regional stage, and 6% have distant (metastatic) disease (14).

In stage IV the tumor can spread beyond the breast under the internal mammary lymph nodes located at the base of the neck, the lungs, liver, bone, or brain which is called (metastasis) in which the cells have jumped from the milk duct to the bloodstream of the breast (15). Histopathological examination of the tissue specimens observed the commonest breast cancer was in Grad II (54.2), followed by Grad III (28.9), and Grad I (16.8). Grade II observes the breast cancer tissues characterized by neoplastic proliferation of cells in terminal breast ducts and acini. Grade III was found in poorly differentiated cancer cells in the breast from the normal cells, also the cancer cells are small, rounded, and found as nests tend to grow and spread more aggressively (19).

(20) described that grade II moderately differentiated the breast cells and has characteristics between Grade III. Grade I mean breast cancer where the neoplastic cells are still within the ductulus and have not broken through to the stroma.

The results of this study observed that the immunohistochemical expression of ER and PR receptors found strong positive ER in (48.1%), moderately positive ER (33.7%), and negative ER (18.2%) of all breast cancer cases, also the results

observed strongly positive PR in (51.8%), moderately positive PR (31.3%) and negative PR (16.8%) of all cases. Human epidermal receptor protein-2 (c-erbB-2; HER2/neu) status is also revealed positive scores (30.1%) while negative scores observed in (69.8%) of all cases.

Normal breast cells and some breast cancer cells have receptors that attach to the hormones estrogen and progesterone and need these hormones for the cells to grow (21).

Expression of estrogen receptors (ER) and progesterone receptors (PR) is a very powerful and useful predictor. Because the response rate to hormonal treatment in breast cancer is associated with the presence of ER and PR and assessment of receptor expression profile allows clinicians to predict breast cancer response to hormonal treatment, where the higher the content of ER and PR in breast cancer, the greater the likelihood of response to hormonal therapy (22).

This study observed a significant correlation of ER, PR, or HER2/neu with the type of mammary carcinoma and both progesterone and estrogen receptors showed a significant correlation with histopathological grading of breast cancer, HER2/neu receptors overexpression revealed a significant association.

Some studies showed that 75% of patients with (ER+/ PR+, 40%) of patients with (ER+/ PR-, 25%) of patients with (ER-/ PR+, and 5%) of patients with ER-/PR- respond to endocrine therapy. Positive estrogen (ER+) of breast cancers is more commonly found in older women and screening mammograms are more frequently used in older women, the detection method may have resulted in a greater relative increase in the age-adjusted rates for ER+ cancers than for ER-cancers (23). ER-positive tumors are correlated with better survival than ER-negative tumors and decreased breast cancer mortality in afflicted patients, so patients with ER-positive/PR-positive tumors have a better prognosis than patients with ER-positive/PR-negative tumors, who have a better prognosis than

patients with ER-negative/PR-negative tumors (24). Determination of human epidermal receptor protein-2 (c-erbB-2; HER2/neu) status is also important as it is known to be a prognostic as well as predictive marker in both node-negative and node-positive patients (25).

Conflicts of Interest:

The authors declare no conflict of interest.

Fund:

No funds, grants, or other support were received.

References

- 1-Miller KD, Siegel RL, Lin CC. (2019). Cancer treatment and survivorship statistics, 2019. *CA Cancer J Clin*:1-23.
- 2- Lima SM, Kehm RD, Terry MB. (2021). Global breast cancer incidence and mortality trends by region, age groups, and fertility patterns. *E Clinical Medicine.*; 38: 100985.
- 3-SKmch & RCnursdiv. (2005). Breast cancer (patient information). Sht. KH. Cancer and Res. center, M.A. Johar Twon, Lahore – Pakistan.UAN:111-155-555.
- 4-Rojas, K.; Stuckey, A. (2016). Breast Cancer Epidemiology and Risk Factors. *Clin. Obstet. Gynecol.* 59, 651–672
- 5- Servic, R.F. (1998). New role for estrogen in cancer? *Science* (Washington. DC). 279: 1631 – 1633
- 6- NCCN (National. Comprehensive Cancer Network) (2007). Breast cancer, Treatment. Guidelines for patients. Clin Practice Guidelines, version IX
- 7- Guarneri V., Dieci M.V., Bisagni G., Frassoldati A., Bianchi G.V., De Salvo, G.L., Conte P.F. (2019). De-escalated therapy for HR+/HER2+ breast cancer patients with Ki67 response after 2-week letrozole: results of the PerELISA neoadjuvant study, *Annals of Oncology*: 30:921
- 8- Alwan N.A.S., Tawfeeq F.N., Muallah F.H. (2017). Breast cancer subtypes among Iraqi patients: identified by their ER, PR and HER2 status, *Journal of the Faculty of Medicine Baghdad*, 59:304
- 9- Liu X.Y., Ma D., Xu X.E., Jin X., Yu K.D., Jiang Y.Z., Shao Z.M. (2018). Genomic landscape and endocrine-resistant subgroup in estrogen receptor-positive, progesterone receptor-negative, and HER2-negative breast cancer, *Theranostics*, 8:6386
- 10- Allemani C, Sant M, Berrino F (2004). Prognostic value of morphology and hormone receptor status in breast cancer– a population-based study. *Br J Cancer* 2004; 91: 263-8
- 11- Tousson, E., Ali, E.M., Ibrahim, W. and Mansour, M.A. (2011). Proliferating cell nuclear antigen as a molecular biomarker for spermatogenesis in PTU-induced hypothyroidism of rats. *Reprod Sci* 18: 679–686
- 12- Anderson, J.R. (1985). Murr`s Textbook of Pathology. 11th Ed University Glasgow. P:24 (30- 48)
- 13- A.C. S, (American Cancer Society). (2001). what is the Breast cancer? ACS – California. Div. inc. (510): 835 – 893.
- 14- Henry NL, Cannon-Albright L. (2019). Breast Cancer Histological Subtypes Show Excess Familial Clustering. *Wiley Cancer*. 125(18):3131-8

- 15- **Laster, SC.& Cotran, R.S. (2003).** The Breast: Robbins & Cotran pathologic of medicine Basis, 7th Ed. Uni. Chicago. P.Sch of medicine, P: 23(1093)
- 16- **A.C.S. (American Cancer Society). (2008).** Detailed guide: Breast cancer. can. information. A.C.S.inc
- 17- **Rosen and Oberman, J.S. (1993).** Tumors of the mammary gland. Atlas of tumor pathology, third series, Fascicle (7). Washington, DC, Armed forces Institute of pathology.
- 18- **Giaquinto AN, Sung H, Miller KD. (2022).** Breast cancer statistics. *CA Cancer J Clin*; **72**(6): 524-541.
- 19-**Jamkit. (2006).** Breast cancer in men. can. reg. ch. NO. 1019719
- 20- **Sampson, V.; Fenlon, D. (2002).** The breast book. infom. Amer. Ref book, vermilion. London
- 21-**Tsang JYS, Tse GM. (2020).** Molecular Classification of Breast Cancer.*Adv Anat Pathol*;27(1):27-35
- 22-**Elledge RM, Green S, Pugh R. (2000).** Estrogen receptor (ER) and progesterone receptor (PgR), by ligand-binding assay compared with ER, PgR and pS2, by immuno-histochemistry in predicting response to tamoxifen in metastatic breast cancer: a Southwest Oncology Group Study. *Int J Cancer*; **89**: 111-7
- 23-**Rocca A, Farolfi A, Maltoni R, Carretta E, Melegari E, Ferrario C (2015).** Efficacy of endocrine therapy in relation to progesterone receptor and Ki67 expression in advanced breast cancer. *Breast Cancer Res Treat.*;152(1):57-65
- 24-**Gao JJ, Swain SM. Luminal A. (2018).** Breast Cancer and Molecular Assays: A Review. *Oncologist*;23(5):556-65
- 25-**Kumar P, Aggarwal R. (2016).** An overview of triple-negative breast cancer. *Arch Gynecol Obstet.*;293(2):247-69.