

LISTONELLOSIS IN CLARIAS GARIEPINUS : PHENOTYPIC AND SEROLOGICAL IDENTIFICATION OF LISTONELLA ANGUILLARUM ISOLATED FROM ULCERATIVE LESIONS

AMANY A. ABBASS AND MONA M. SOBHY*

Dept of Fish Diseases and Management Fac. Vet Med. (Moshtohor) Benha Univ.

*Animal Reproduction Research Institute - El-Haram, Egypt.

Received: 9.8.2006

Accepted: 17.9.2006

SUMMARY

In the present study ten isolates of *Listonella anguillarum* were isolated from *Clarias gariepinus* exhibited ulcerative lesions. The prevalence of infection was 16.7 %. The organisms were identified phenotypically to be a variant strains of *L. anguillarum* and the biochemical deviation were found in Voges Proskauer test and fermentation of mannitol. Experimentally, the infected fish showed severe skin ulcerations and high mortality rate. Electrophoresis of serum proteins revealed a significant decrease in δ , β and α globulins on day 4 post infection (PI) and for β globulin only on day 8 PI. In addition, the total serum globulin was dropped significantly on day 4 PI and non-significantly on day 8 PI when compared with its value for control group. Moreover, the albumin / globulin ratio was significantly elevated in the infected groups than in control one. The application of an indirect fluorescent antibody technique

(IFAT) confirms the diagnosis of *L. anguillarum* and the results revealed presence of green-yellowish fluorescent bacteria in the most stained tissue sections. A very strong immunofluorescence reaction was observed in spleen and kidneys while, the intestine showed reaction in its posterior portion only. In conclusion *L. anguillarum* considered as a causative agent of ulcerative syndrome in *Cl.-gariepinus* and IFAT is a sensitive, rapid and specific test for diagnosis of *L. anguillarum* in fish.

INTRODUCTION

Listonellosis is one of the most important infectious diseases of marine and freshwater fish throughout the world caused by *Listonella anguillarum* (McDowell and Colwell, 1985), but the causative agent is still referred to as *Vibrio anguillarum* in many publications. *Vibriosis* is associated with high mortalities and shares in invasive

septicaemic diseases in humans (Actis et al., 1999) therefore, new techniques are needed to trace the pathogen in its natural reservoir and in the environment as well as, to evaluate the risk of human infections. Molecular technique as nucleic acid probes are useful for identification of vibrio species (Arias et al., 1995) and also immunological techniques as ELISA assay and IFAT are useful for detecting *V.vulnificus* in eel tissue samples (Biosca et al., 1997 and Marco Noales et al., 2000). Moreover, IFAT technique used for diagnosis of several fish diseases as infectious salmon anemia virus (Giray et al 2005); microsporidium, *Glugea epinephelusis*, (Zhang et al., 2005) and Rickettsia-like organisms, *Piscirickettsia salmonis* (McCarthy et al., 2005 and Yuksel et al., 2006).

Epizootic ulcerative syndrome (EUS) is a fish disease characterized by severe-open dermal ulcers that develop on the fish bodies (McGarey et al., 1991). The etiological agent(s) of EUS isolated from lesions and blood samples of infected fish were belonging to the potentially fish pathogenic genera *Aeromonas*, *Vibrio*, *Plesiomonas* and *Pseudomonas* (Chowdhury, 1997 and Rahman, 2002). In light of the public health importance of these epizootic diseases, it is of great importance to identify the etiological agents. The current study was planned to demonstrate the clinical picture of listonellosis among infected *Clarias gariepinus* showing ulcerative lesions, isolation and identification of etiological agent. Besides, esti-

mation of the change in serum proteins profile accompanying listonella infection. As well, a quantitative evaluation of indirect fluorescent antibody technique as a rapid procedure for diagnosis of *Listonella anguillarum*.

MATERIALS AND METHODS

Naturally infected fish:

A total number of 60 *Clarias gariepinus* naturally suffered from ulcerative syndrome weighted 250 ± 10 g were collected from their natural sources (El-Riah El-Tawfikii and their tributaries). The fish were transported according to Brown and Gratzek (1980) to the wet lab at Fac. of Vet. Med. Moshtohor. The collected fish were examined clinically as described by Noga (1996). Signs and lesions that observed were recorded.

Isolation and identification of bacterial isolates:

Samples for bacteriological investigation were taken from ulcer scraps and inoculated into thio-glycolate semisolid media and incubated at 37°C for 2-3 days . Culture characters on thiosulfate citrate bile sucrose (TCBS) agar and sheep blood agar supplemented with 1.5% NaCl were studied. The inoculated plates were incubated at 37°C for 2-3 days. The growing cultures were examined by phase contrast microscope at 400 X at Animal Reproduction Research Institute El-Haram, Egypt. The isolated bacteria was identified phenotypically using a standard set of biochemical tests as de-

scribed by Austin and Austin (1993) and Holt et al. (1994).

Experimental infection:

Fish :

Thirty six apparently health male *Cl. gariepinus* weighted 250 ± 10 g were obtained from a private fish farm transported in well prepared tanks to the wet lab. where they put in fiber glass tanks for acclimation. Random samples of 4 fish were used for bacteriological investigation to indicate a negative vibrio infection. The remaining fish were divided into 4 groups each of 8 fish and kept in glass aquaria, each measured 1 x 1 x 0.5 m and supplied with dechlorinated tap water (Innes, 1966) and sufficient aerators. The temperature adjusted at $22 \pm 1^{\circ}\text{C}$. The fish received commercial pelleted diet.

Experimental desgin

A strain from biochemically identified variant L. anguillarum isolates was taken for experimental infection. Broth culture was prepared containing approximately 10^8 cells/ml using McFarland's opacity tubes. Each fish of the first three groups was inoculated by intraperitoneal injection with 0.25 ml of broth culture containing approximately 10^8 cells/ml (Abbass et al., 2000). While, the fish of the remaining group were inoculated with sterile broth in a dose of 0.25 ml per fish and used as a control. Both inoculated and control groups were kept under observation for 10 days post infection (PI).

Blood samples were collected using plastic syringe from the caudal blood vessel of four fish from the infected first two groups on the day 4 and the day 8 PI respectively, as well as from the control group (day 0) and allowed to clot. The separated sera were stored at -20°C until needed. Four fish were sacrificed on 0, 4 and 8 day PI and the tissues were carefully dissected out (gills, skin and underlying musculature, liver, spleen, kidney, and intestine) and preserved at -70°C until used. Mortality rate in the experimentally infected fish was estimated at 10 day post infection for the third group, comparing with the control one.

Electrophoresis for serum proteins:

Serum protein profiles were investigated using sodium dodecyl-sulphate polyacrylamide gel electrophoresis (SDS - PAGE) according to Laemmli (1970). After electrophoresis the gels were stained with silver stain and distained as described by Hitchcock and Brown (1983).

Indirect Fluorescent Antibody Technique (IFAT):

a- Tissue preparation:

Tissue specimens from gills, musculature , liver, spleen, kidney and intestine of experimentally infected fish were taken. Sections of $4\mu\text{m}$ thickness were prepared using cryostat microtome and then fixed in acetone for 20 minute (Kechen et al., 1984).

b- Preparation of immune sera:

Well identified *L. anguillarum* strain kindly supplied by Animal Reproduction Research Institute "Compylobacter Lab". El-Haram Egypt and was used for preparation of antigen.

The antigen was prepared as described by Walsh and White (1968). Rabbit antisera against formalinised whole cells of *L. anguillarum* were prepared by multiple intravenous injection according to previously described procedure (Walsh and White 1968).

c- Procedure of IFAT:

Fluorescein isothiocyanate-conjugated anti-rabbit hyper immune sera (Baltimore Biological Lab., Baltimore, Maryland) were used and added at the manufacturer's recommended working dilution. The procedure of IFA test was applied as described by Riggs et al. (1958). The prepared slides were examined at a magnification of X 40 and X 60 with a zeiss epifluorescence microscope.

Statistical analysis of the data was done using statistical analysis system (SAS, 1987).

RESULTS AND DISCUSSIONS

In the present study 10 out of 60 fish naturally suffered from ulcerative lesions were positive for vibrio infection. The prevalence of infection was 16.7 %. The infected fish showed hemorrhagic spots, eroded fins and open dermal ulcers on the

middle of the body and on the tail region. The musculature at the base of ulcers were severely congested. Internally, paleness of internal organs was noticed. Enlargement of gall bladder and congestion of spleen and liver were observed. These observations were nearly similar with those recorded by McGarey et al. (1991); Actis et al., (1999); Austin and Austin (1999) and El-Bouhy et al. (1999), and Abbass and Sobhy (2005).

Ten vibrio isolates were isolated from ulcerative lesions. The organisms grow on TCBS agar as yellow colonies and produce haemolysis on sheep blood agar. Biochemically they were positive for catalase, oxidase; simmon's citrate, produce indole and acid from saccharose. The organisms produce acid from glucose, maltose, and sucrose but not from lactose fermentation. Also, they gave negative results toward methyl red test and H₂S production (TSI). These results agreed with that recorded by Baumann et al. (1984); Austin and Austin (1993) and Holt et al. (1994). In addition, the isolated bacteria could not produce Voges Proskauer reaction and acid from mannitol. Moreover, the obtained isolates in this work were able to grow in the media supplemented with 1.5% NaCl, and all but two of these isolates could not grow at 3.5% NaCl. Conversely, all could not grow at 6% NaCl. From the presented data, the isolates could be identified biochemically as a variant strains of *L. anguillarum*. Similar observation were recorded by Pazos et al. (1993) and Tiainen et al. (1997) who isolated *V. anguillarum*

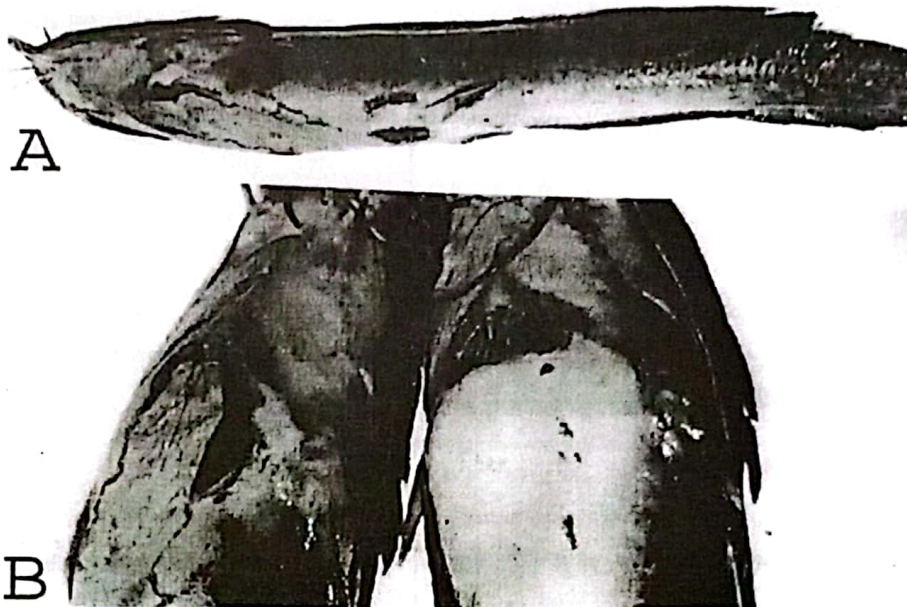


Fig. (1): *Cl. gariepinus* experimentally infected with variant *L. anguillarum* on day 4 PI showing A-Open dermal ulcer over the body. B- Hemorrhagic areas on the skin; wide ulcers with severely congested musculature at their bases and gray patches of sloughed skin.

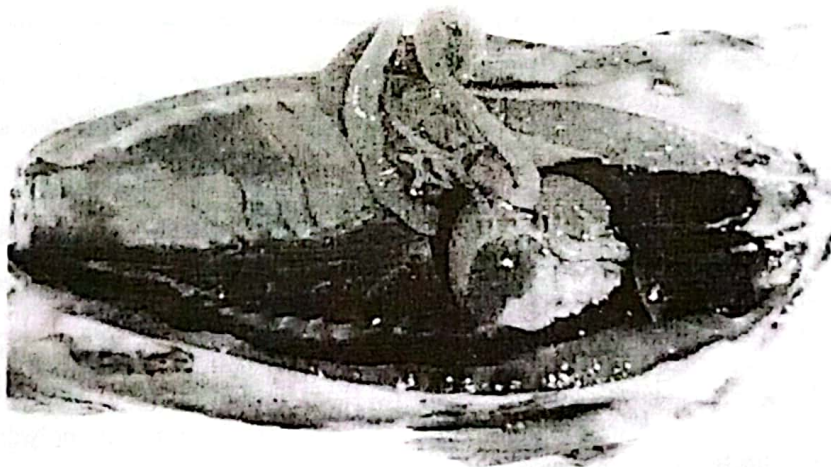


Fig. (2): *Cl. gariepinus* experimentally infected with variant *L. anguillarum* on day 4 PI showing congested kidney, distended gall bladder, pale spleen and the liver had grey-white patches (arrow)

related strains showing the same biochemical variations.

Concerning experimental infection, all the infected fish showing hemorrhagic spots in the skin, gray patches of detached skin, severe open dermal ulcers on the head, on the trunk and tail (Fig.1 A, B). Wide ulcers on the ventral region and the musculature at their bottoms were severely congested (Fig.1 B). Internally the infected musculature were severely congested, livers were pale greenish or congested, gall bladders were distended, pale or congested spleen and kidneys (Fig. 2). The intestine filled with yellow viscous material. These observations nearly agree with those recorded by Chowdhury (1997). Similar findings were also recorded in other fish species suffered from vibriosis (Moustafa et al., 1990; Shaaban et al., 1995; Austin and Austin, 1999 and Actis et al., 1999). In addition, most of the infected fish showed severe ulceration of the skin and deaths may be due to osmoregulatory failure. The mortality rate reached 87.5% among the infected group compared with control (0%). Similar findings were observed by El-Bouhy et al. (1999) and Abdel-Gaber et al. (1997).

Electrophoresis of serum proteins using SDS PAGE as presented in Fig. 3 & 4 and Table 1 revealed presence of several protein fraction bands. There was a significant increase in the amount of

albumins in serum of *Cl. gariepinus* after infection with *L. anguillarum* on day 4 (53.31 ± 1.04 KDa) and day 8 PI (51.55 ± 1.78 KDa) than non infected control on 0 day (47.01 ± 0.84 KDa). Meanwhile, all globulin fraction were significantly decreased following infection on day 4 for δ , β and α globulins (15.45 ± 1.40 , 15.35 ± 1.01 and 15.55 ± 0.71 KDa, respectively) and on day 8 PI for (globulin only (15.08 ± 0.80 KDa) than in control group for δ , β and α fractions (19.14 ± 0.71 , 19.65 ± 0.49 and 12.88 ± 0.78 KDa, respectively). However, the reduction in content of both γ and α -globulins on day 8 PI (17.54 ± 0.87 and 15.23 ± 0.91 KDa, respectively) did not reach the level of significance when compared with their values in control. These observations were partially agreed with those of Harbell et al. (1979) who found a significant reduction in globulin fractions in Coho salmon infected with *V. anguillarum*. In addition, the total serum globulin was dropped significantly on day 4 PI (46.38 ± 1.01 KDa) and non significantly on day 8 PI (47.85 ± 1.88 KDa) when compared with its value for control group (51.66 ± 0.76 KDa). Moreover, the albumin / globulin ratio was significantly elevated on day 4 and 8 PI (1.15 ± 0.05 and 1.08 ± 0.08 , respectively) when compared with that recorded in control group (0.91 ± 0.03). Similar findings were recorded by Sivaram et al. (2004) who found a significant reduction in globulin and significant increase in both albumin and albumin / globulin ratio in

Table (1): Changes in serum protein profiles of *Cl. gariepinus* during variant *L. anguillarum* infection (M \pm SE).

Days P.I	Serum sample (lane)	Sum. of proteins (KDa)	Albumins (KDa)	Globulins (KDa)				A/G
				δ	β	α	Total	
0 day (control)	1	98.62	45.05	18.89	21.31	13.37	53.57	0.84
	2	98.64	47.21	21.54	19.33	10.56	51.43	0.91
	3	98.97	49.59	17.94	18.74	12.70	49.38	1.00
	4	98.34	46.17	18.20	19.20	14.87	52.27	0.88
Overall mean		98.64 $\pm 0.11^B$	47.01 $\pm 0.84^B$	19.14 $\pm 0.71^A$	19.65 $\pm 0.49^A$	12.88 $\pm 0.78^A$	51.66 $\pm 0.76^A$	0.91 $\pm 0.03^B$
4 day PI	1	99.64	52.71	13.13	16.43	17.37	46.93	1.12
	2	99.79	56.82	13.71	13.14	16.12	42.97	1.32
	3	99.73	51.50	14.78	18.10	15.25	48.23	1.07
	4	99.59	52.20	20.18	13.74	13.47	47.39	1.10
Overall mean		99.68 $\pm 0.04^A$	53.31 $\pm 1.04^A$	15.45 $\pm 1.40^B$	15.35 $\pm 1.01^B$	15.55 $\pm 0.71^B$	46.38 $\pm 1.01^B$	1.15 $\pm 0.05^A$
8 day PI	5	99.47	56.12	14.65	14.72	13.98	43.35	1.29
	6	99.77	46.50	19.24	15.65	18.38	53.27	0.87
	7	98.81	53.23	18.38	12.77	14.43	45.58	1.17
	8	99.56	50.36	17.90	17.16	14.14	49.20	1.02
Overall mean		99.40 $\pm 0.18^A$	51.55 $\pm 1.78^A$	17.54 $\pm 0.87^{AB}$	15.08 $\pm 0.80^B$	15.23 $\pm 0.91^{AB}$	47.85 $\pm 1.88^{AB}$	1.08 $\pm 0.08^A$

Means with different capital alphabetical superscripts are significantly different from each other at level $P < 0.05$.

A/G = Albumin globulin ratio.





Fig. (3): Electrophoretic patterns of serum protein of *Cl. gariepinus* experimentally infected with variant *L. anguillarum*. Lanes 1-4 represent sera obtained on day 4 PI and Lanes 5-8 represent sera obtained on day 8 PI.

Fig. (4): Electrophoretic patterns of serum protein of *Cl. gariepinus* (non infected control). Lanes 1-4 represent sera obtained on 0 day.



Epinephelus tauvina infected by *V. harvey*. In this work increased value of A/G ratio indicates immunosuppressive state in the infected fish.

The traditional plate culture technique and phenotypic testes for detecting and identifying *L. anguillarum*, is time consuming and may be problematic as a result of phenotypic variations of its isolates. To confirm the diagnosis of the isolated variant *L. anguillarum* strains and to evaluate how useful the IFAT is in tracing of *L. anguillarum* in tissue samples, samples from different tissues of experimentally infected *Cl. gariepinus* were analysed. All tissue sections from infected fish gave positive results. Green-yellowish fluorescent bacteria of coccoid or spiral forms were detected in stained sections of gills (Fig. 5), kidneys (Fig. 6), spleen (Fig. 7), liver (Fig. 8) and musculature (Fig. 9) of experimentally infected *Cl. gariepinus*. Very strong immunofluorescent reactions in various tissues were observed in those obtained on day 4 PI and weak fluorescence reaction found in tissues taken on day 8 PI except for kidney and spleen. No fluorescent cells were detected in the tissues of control group. Similar observations were recorded by Nelson et al. (1985 a,b) who used IFAT to detect *V. anguillarum* from most tissues of experimentally infected *Salmo gairdneri* with severe reactions recorded in spleen and kidneys and by Vigneulle and Laurencin (1991) who used IFAT to determine the intestinal uptake of *V.*

anguillarum in rainbow trout and seabass. Moreover, the same technique was used for diagnosis of *V. vulnificus* (Sung and Song, 1996) in shrimp and *V. parahaemolyticus* (Chen and Chang, 1996 and Zhang et al., 1997) in *Penaeus chinensis* and oysters respectively. In the present study, detection of the organism from all the examined tissues confirmed that septicemia produced by this microorganism and circulate to all organs. These opinion was supported by the findings of Marco Noales et al. (2000). Intestinal sections revealed fluorescence reaction in the posterior part of intestine (Fig. 10) and no reaction in the anterior one.

These observations were agreed with that recorded by Miyazaki et al. (1990) and Vigneulle and Laurencin (1991). Absence of organism from the anterior intestine may be due to mild acidic shift of its content. These results supported the finding of Ranson et al. (1984) who demonstrated that *V. anguillarum* can not grow in an acidic medium.

In conclusion, it may be very difficult to define a single organism as a causative agent for ulcerative syndrome in *Cl. gariepinus*. However, the present study suggested that *L. anguillarum* can be considered as a possible causative agent of ulcerative syndrome in *Cl. gariepinus* and induces an immunosuppression state. Moreover, the IFAT described is a sensitive, rapid, specific and useful method of identifying *L. anguillarum* in fish.




Fig. (5): Epifluorescence microphotograph of gills of *Cl. gariepinus* 4 day PI stained with anti-rabbit fluorescent conjugate to *L. anguillarum* showing fluorescent coccoid forms (arrow) (x 40).

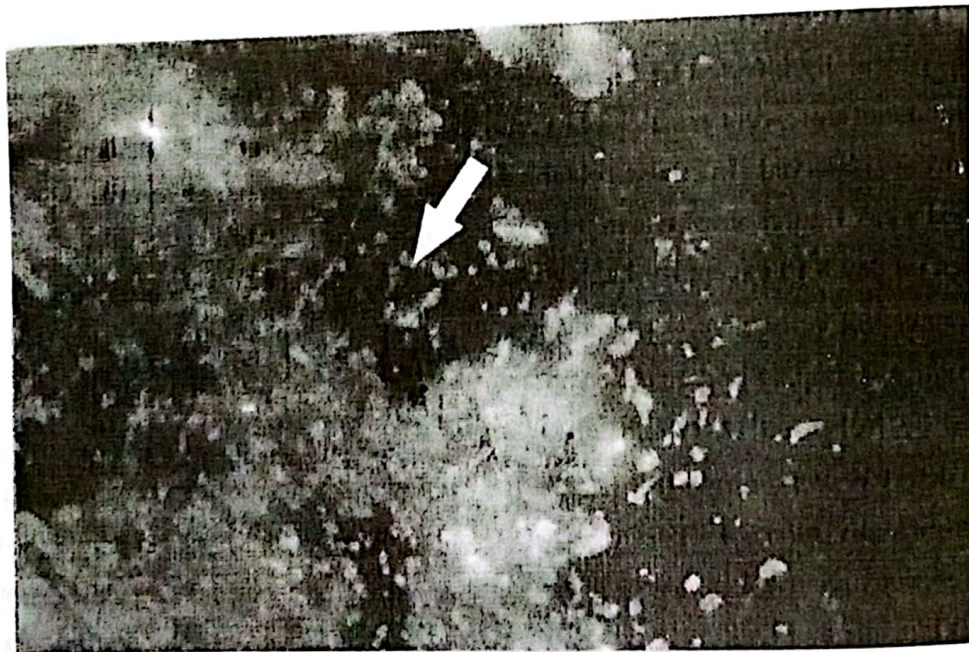


Fig. (6): Epifluorescence microphotograph of anterior kidney of *Cl. gariepinus* 4 day PI stained with anti-rabbit fluorescent conjugate to *L. anguillarum* showing fluorescent coccoid and long spiral forms (arrows) (x 60).




Fig. (7): Epifluorescence microphotograph of spleen of *Cl. gariepinus* 4 day PI stained with anti-rabbit fluorescent conjugate to *L. anguillarum* showing fluorescent coccid forms (X 60).




Fig. (8): Epifluorescence microphotograph of liver of *Cl. gariepinus* 4 day PI stained with anti-rabbit fluorescent conjugate to *L. anguillarum* showing positive fluorescence for vibrio strain (arrows X 40).



Fig. (9): Epifluorescence microphotograph of musculature of *Cl. gariepinus* 4 day PI stained with anti-rabbit fluorescent conjugate to *L. anguillarum* showing coccoid and spiral forms (arrows X 40).



Fig. (10): Epifluorescence microphotograph of intestine of *Cl. gariepinus* 4 day PI stained with anti-rabbit fluorescent conjugate to *L. anguillarum* showing fluorescent coccoid forms (arrow X 60).

REFERENCES

- Abbass, A. Amany and Sobhy, M. Mona (2005): Vibriosis in some fishes: Molecular characterization of fish pathogenic vibrios. *Vet. Med. J. Giza*. 53 (4): 911-923.
- Abbass, A. Amany; Shaheen, A.A. and Abdel- Aziz, A.M. and Sobhy, M.M. (2000): Clinico pathological and laboratory investigations on vibriosis in some fishes. *Zag. Vet. J.* 28 (3) 115-125.
- Abdel-Gaber, G.; Naguib, M. and Abdel-Aziz, E.S. (1997): *Vibrio* species infections to *Oreochromis niloticus* and *Mugil cephalus*; Sodium chloride tolerance, pathogenicity, serological relatedness and Antibioqram sensitivity of recovered vibrios. *Vet. Med. J., Giza*. 45 (1): 87-99.
- Actis, L.M.; Tomalsky, M.E. and Crosa, J.H. (1999): Vibriosis P. 523-557. In P.T.K. Woo and E.W. Bruno[9ed]. *Fish diseases and disorders Vol. 3 : viral, bacterial and fungal infection* . Cab International Publishing, Wallingford, United Kingdom.
- Arias, C.R.; Garay, E. and Aznar, R. (1995): Nested PCR method for rapid and sensitive detection of *Vibrio vulnificus* in fish, sediments and water. *Applied and Environmental Microbiology* 61, 3476-3478.
- Austin, B. and Austin, D.A. (1993): Bacterial fish pathogens. Disease in farmed and wild fish. 2nd Ed. printed and bound in Great Britain by Hartnolls, Bodmin.
- Austin, B. and Austin, D.A. (1999): Bacterial fish pathogens; disease of farmed and wild fish Springer and Praxis publishing Ltd., Chichester, United Kingdom.
- Baumann, P., Furnsis, A.L. and Lee, J.V. (1984): Genus I . *vibrio pacini* 1859, 411 AL. In: krieg, N, R and Holt, J. (eds), *Bergey's Manual Systematic Bacteriology*, Vol. I. Baltimore, Williams and Wilkins, P. 518-538.
- Biosca, E.G.; MarcoNoales, E.; Amaro, C. and Alcaide, E. (1997): An enzyme-linked immunosorbent assay for detection of *Vibrio vulnificus* biotype 2. development and field studies. *Applied and Environmental Microbiology*. 63, 537-542.
- Brown, E.E. and Gratzek, J.B. (1980): *Fish Farming Hand Book*. Publishing Company INC West Port Connecticut, U.S.A.
- Chen, H.C. and Chang, T.C. (1996): Rapid detection of *Vibrio parahaemolyticus* in oysters by immunofluorescence microscopy. *Int. J. Food Microbiol.* 29 (2-3): 311-319.
- Chowdhury, M.B.R. (1997): Bacteria involved in fish diseases in Bangladesh. International symposium on diseases in marine aquaculture. Society of Fish Pathology, Hiroshima, Japan.
- El-Bouhy, Z.M.; Abdel-Monem, A.A.; Mohamed, E. and Moustafa, M.B. (1990): Preliminary studies on vibrios in some freshwater fishes. *Zagazig Vet. J.* 18 (5): 68-86.
- Giray, C.; Opitz, H.M.; Maclean, S. and Bouchard, D. (2005): Comparison of lethal versus non lethal sample sources for the detection of infectious salmon anemia virus (ISAV). *Dis. Aquat. Organ.* 23; 66 (3): 181-185.
- Harbell, S.C.; Hodgins, H.O. and Schiewe, M.H. (1979): Studies on the pathogenesis of vibriosis in Coho salmon *Oncorhynchus kisutch* (Walbaum). *J. Fish Diseases*. 2 (5): 399-404.
- Hitchcock, P.J. and Brown, T.M. (1983): Morphological heterogeneity among *Salmonella* lipopolysaccharide types in silver- stained polyacrylamide gels. *J. Bacterial*, 184: 269-277.
- Holt, J.H.; Krieg, N.R. and Smeeth, P.H.A. (1994): *Berge's Manual of determinative Bacteriology*, 9th Ed. Williams and Wilkins, Baltimore. P. 559.

- Innes, W.T. (1966): Exotic aquarium fish 19th Ed., Inoc., New Jersey, 530P.
- Keehen, C.; Harold, J.K.; Gilbert, E.W. and Connie, J.G. (1984): Immuno fluorescent demonstration of *Campylobacter byointestinalis* and *Campylobacter sputorum* subsp. mucosalis in swine intestines with lesions of proliferative enteritis. American J. Vet., 97: 703-707.
- Laemmli, U.K. (1970): Cleavage of structural proteins during the assembly of the head of bacteriophage T4. Nature, 227:680-685.
- Marco Noales, E.; Biosca, E.G.; Milan, M. and Amaro, C. (2000): An indirect immunofluorescent antibody technique for detection and enumeration of *Vibrio vulnificus* serovar E (biotype 2): development and applications. J. Applied Microbiology, 89 (4): 599-606.
- McCarthy, U.; Steiropoulos, N.A.; Thompson, K.D.; Adams, A.; Ellis, A.E. and Ferguson, J.W. (2005): Confirmation of *Piscirickettsia salmonis* as a pathogen in European seabass *Dicentrarchus labrax* and phylogenetic comparison with salmonid strain. Dis. Aquat. Organ. 18: 64 (2): 107-119.
- McDowell, M. and Colwell, R.R. (1985): Phylogeny of the Vibrionaceae, and recommendation for two new genera, *Listonella* and *Shewanella*. Systematic and Applied Microbiology, 6, 171-182.
- McGarey, D.J.; Milanesi, D.; Reyes, J.; Fryc, C. and Lim, D.V. (1991): The role of motile aeromonads in the fish disease. Ulcerative disease syndrome (UDS) Experientia Rev. 47: 441-444.
- Miyazaki, T.; Kajihara, N.; Fujiwara, K. and Egusa, S. (1990): Histopathological study on intestinal necrosis of larval Japanese flounder. J. Fish Pathology. 25 (1): 7-13.
- Moustafa, M.; Eissa, I.A.M. and Hanafi, M.S. (1990): Vibriosis in marine fishes of Qarun lake. Zagazig Vet. J., 18 (195): 94-105.
- Nelson, J.S.; Rohovec, J. and Fryer, J.L. (1985 a): Location of *Vibrio anguillarum* in tissues of infected rainbow trout (*Salmo gairdneri*) using the fluorescent antibody technique. Fish Pathology. 20 (2-3): 229-235.
- Nelson, J.S.; Rohovec, J. and Fryer, J.L. (1985 b): Tissue location of vibrio bacteria delivered by intraperitoneal injection, immersion and oral routes to *Salmo gairdneri*. Fish pathology. 19 (4): 263-269.
- Noga, E.J. (1996): Fish Diseases. Diagnosis and treatment. Mosby. New York, pp. 367.
- Pazos, F.; Santos, M.; Magorinos, B.; Bandin-Nunez, S. and Toranzo, A.E. (1993): Phenotypic characteristics and virulence of *V. anguillarum* related organisms. Applied Environ. Microbiol. 59 (9): 2969-2976.
- Rahman, M.; Patricia, C.N.; Inger, K.; Geert, H.; Jean, S. and Roland, M. (2002): Identification and characterization of pathogenic *Aeromonas veroni* biovar sobria associated with epizootic ulcerative syndrome in fish in Bangladesh. Applied and Environ. Microbiology. 68 (2): 650-655.
- Ranson, D.P.; Lannan, C.N.; Rohovec, J.S. and Fryer, J.L. (1984): Comparison of histopathology caused by *Vibrio anguillarum* and *V. ordalii* in three species of pacific salmon. J. Fish Diseases. 7, 107-115.
- Riggs, J.; Burch, K. and Metcalf, J. (1958): Isothiocyanate compounds as fluorescent labeling agents for immune serum. American J. Pathology. 34, 1081-1087.
- Shaaban, A. L; Easa El-S. M. and Diab, S.A. (1995): Characterization of *V. anguillarum* isolated from wild fish eels (*Anguilla japonica*) in Egypt. J. Egypt. Vet. Med. Ass., 55 (1, 2): 141-145.

- Sivaram, V.; Babu, M.M.; Immanuel, G.; Murugadass, S.; Citarasu, T. and Marian, M.P. (2004): Growth and immune response of juvenile greasy groupers (*Epinephelus tauvina*) fed with herbal antibacterial active principle supplemented diets against *Vibrio harveyi* infections. *Aquaculture*. 237, 9-20.
- Statistical Analysis System (SAS) (1987): User's Guide: Statics. SAS Institute, Cary., North Carolina.
- Sung, H. and Song, Y. (1996): Tissue location of vibrio antigen delivered by immersion to tiger shrimp (*Penaeus monodon*). *Aquaculture*. 145 (1-4): 41-54.
- Tiainen, T.; Pedersen, K. and Larsen, J.L. (1997): *Vibrio anguillarum* serogroup O3 and *V. anguillarum*-like serogroup O3 cross-reactive species - comparison and characterization. *J. Applied Microbiology*. 82 (2): 211-218.
- Vigneulle, M. and Laurencin, F.B. (1991): Uptake of *Vibrio anguillarum* bacteria in the posterior intestine of rainbow trout *Oncorhynchus mykiss*, seabass *Dicentrarchus labrax* and turbot *Scophthalmus maximus* after oral administration or oral intubation. *Diseases of Aquatic Organisms*. 11 (2): 85-92.
- Walsh, A.F. and White, F.H. (1968): Biochemical and serological characteristics of vibrio isolate from cattle. *American J. Vet. Res.* 29, 1377-1383.
- Yuksel, S.A.; Thompson, K.D.; Ellis, A.E. and Adams, A. (2006): Improved purification of *Rscirickettsia salmonis* using percoll gradients. *J. Microbiol Methods*. 66 (2): 251-262.
- Zhang, J.Y.; Wu, Y.S.; Wu, H.B.; Wang, J.G.; Li, A.H. and Lu, M. (2005): Humoral immune responses of the grouper *Epinephelus akaara* against the microsporidium *Glugea epinephelusis*. *Dis. Aquat. Organ.* 18, 64 (2): 121-126.
- Zhang, X.H.; Huaishu, X.U.; Bing, X.U.; Weishang, J.; XueSong, Y. and Jiankang, M. (1997): Diagnosis of vibriosis in *Penaeus chinensis* by indirect fluorescent antibody staining. *Oceanologia-et-Limnologia-Sinica*. 28 (6): 604-610.