

EFFECT OF CLOSANTEL ON SOME BLOOD PARAMETERS, HISTOPATHOLOGICAL CHANGES AND FETAL DEVELOPMENT IN PREGNANT FEMALE RABBITS

MONA M.H. ALA-EL-DEEN*, SAMIRA, A.EMARA*, S. A.SELIM
and UMIMA M.MANSOUR*.**

*Biology of Reproduction Department, **Pathology Department

Animal Reproduction Research Institute, 5 Hadayk El-Ahram Street, P.O. Box 12556, Giza, Egypt

Received: 21-8-2001.

Accepted: 31-10-2001.

SUMMARY

The effect of closantel on some blood parameters, histopathological changes and fetal development was studied on 3 groups of 10 pregnant rabbits each. The first group was used as a control whereas, the other groups were injected subcutaneously with closantel in a dose of 10 mg/kg body weight twice with one week apart at days 0 (day of mating) and 7 of pregnancy (group A) and days 6 and 13 of pregnancy (group B). The results revealed increased γ -globulin concentration in the 20th and 28th day of pregnancy in both groups. Eosinophil and monocyte numbers were significantly increased in the 20th and 28th day of pregnancy in group A and in the 28th of pregnancy in group B. There was no significant effect of the treatment on total leukocytic count, numbers of lymphocytes, neutrophils, basophiles and red

blood cells. Hemoglobin concentration, packed cell volume (PCV), total protein, albumin, and globulin in the blood (α and β) were within normal levels.

Histopathological examination demonstrated activation in the mesenteric lymph nodes, splenic corpuscles and thymus gland in treated animals at both periods. Atretic oocytes in primary follicles in the ovary of the treated rabbits at day 0 and 7 of pregnancy and necrotic changes in hepatic parenchyma and uriniferous tubules were clearer in rabbits treated at days 6 and 13 of pregnancy. The anthelmintic closantel did not cause embryonic or teratogenic effects in rabbits.

It is concluded that closantel has immune stimulatory effects which may contribute to the death of the parasite. It decreased the ovulation rate so it

is highly advisable to avoid exposure of females to the drug during ovulation time. The drug also caused some necrotic changes in liver and ureteric tubules. It is contraindicated in animals having liver and kidney problems.

INTRODUCTION

Closantel (Flukiver) is a salicylanilide derivative with a good efficacy against several species and developmental stages of nematodes, trematodes and arthropods of sheep, cattle and dogs (Jenkins et al., 1987) and it has antibacterial activity against drug resistant *Staphylococcus aureus* and *Staphylococcus faecium* (Hlasta et al., 1998). The most common use of the drug is against *Fasciola hepatica* and *Haemonchus contortus*.

Closantel has a long terminal plasma half life of two to three weeks (Maes et al., 1990). This long terminal half life is probably related to the high (>99%) plasma protein binding of the drug (Mckellar and Kinabo, 1991) which is responsible for its residual effect against haematophagous nematodes (Maes et al., 1988). Closantel possesses a detachable proton and has the ability to alter ion transport across cell membrane and affect a variety of membrane related activities in parasitic and mammalian cells (Stryer, 1995). Laboratory examinations including hematology, serum analysis and urine analysis did not reveal persistent drug or dose-related changes of the tested param-

eters. Gross pathology showed no abnormal findings except for a focal swelling in the epididymus of treated males (Janssen 1994 personal communication). Its kinetic expulsion of helminthes and its efficacy for treating parasites were extensively studied whereas its pharmacological action in animals still requires investigations.

The present work was conducted to reveal the effects of the anthelmintic closantel on some blood parameters, histological changes and fetal development in pregnant female rabbits.

MATERIAL AND METHODS:

Animals:

The present study was carried out on 30 mature New Zealand female rabbits obtained from animal house of Helwan Farm. They were 5-6 months old, 2.5-3 kg body weight. Rabbits were free from external, internal and blood parasites, normal health and were kept under hygienic conditions, fed on balanced ration and watered ad libitum.

Treatment:

Closantel (Flukiver) is developed by Janssen (UVEDCO, United Veterinary Drugs Industries Corporation) and its chemical structure is (N-[4-chloro-4-[4-chloro phenyl]cynaomethyl-2-methylphenol]-2-hydroxy 3,5-di-iodo benzamide). Closantel was obtained in liquid form at room temperature, in 5% of 100 ml injectable solution.

The suggested dose in rabbit was 10 mg/kg applied in 2 subcutaneous doses with one week apart (recommended by Janseen pharmaceutical Co).

Experimental work:

The effects of closantel on some blood parameters, histopathological changes and fetal development were studied on three groups each of 10 proven pregnant rabbits. A randomly selected buck of proven fertility served each doe. Does were immediately re-mated by the same buck to ensure adequate serving (Szendro et al., 1984). Pregnancy was confirmed by palpable fetal masses at the 10th day after matting. The first group of pregnant females was kept as control. The second group (A) was administered closantel subcutaneous in a dose of 10 mg/kg body weight at zero day (day of matting) and 7th day of pregnancy while the third group (B) was injected closantel subcutaneously in a dose of 10 mg/kg body weight at the 6th day and 13th day of pregnancy. These periods corresponds to the ovulation and organogenesis of the fetus (Richardson, 2000).

Sampling:

Blood samples were collected from the ear vein at the 10th day of pregnancy, 20th day of pregnancy and after slaughter (at 28th day of pregnancy). About 2 ml of the blood were collected in sterile vials containing anticoagulant for the determina-

tion of blood picture. Another blood samples were taken without anticoagulant, then centrifuged at 3000 rpm for 15 minutes to separate serum for the determination of total protein and its fractions.

Analyses performed on blood samples

- 1- Total protein: Total Serum protein was determined by the Biuret reaction according to Weichsalbaum (1946) where copper in alkaline media react with peptide bond in protein forming a violet color.
- 2- Albumin level: Albumin was estimated by chromogenic reaction that occurs between albumin in serum and bromo cresol green in proper buffer solution according to the method of Drupt (1974).
- 3- Electrophoretic pattern of serum protein: The principle of electrophoresis is based on the separation of charged proteins according to their movement under the influence of an applied electric field (Melvin, 1987). Serum samples were applied to the buffered cellulose acetate stripes, after electrophoresis, the strips were removed carefully, immersed in fixative dye solution. Destaining was applied to remove excess stain, then strips were fixed on a special glass plate and immersed in clearing solution, dried and quantitated by scanning (Melvin, 1987 and Kaneko, 1989).

4- Determination of total leukocytic counts: Total leukocytes were counted using the improved Neubuer Hemocytometer and Turkey's solution which was prepared according to Jain, 2000.

5- Differential leukocytes count: Differential leukocytic count was done using stained blood films which were prepared and stained with Leshman stain according to Jain, 2000.

6- Total RBCs: Red blood cells were counted according to Jain, 2000.

7- Determination of hemoglobin concentration: Blood was treated with Drabkin's reagent by method of Jain, 2000.

8- Determination of packed cell volume: It was measured using heparinized micro hematocrit tubes, using the method of Bezubie et al., 1980.

Histopathological examination.

Tissue samples (liver, spleen, ovary, mesenteric lymph nodes, kidney and thymus gland) were quickly collected from slaughtered does and fixed in 10% formalin solution. The samples were then dehydrated in different concentrations of ethyl alcohol, cleared in xylol and embedded in Parafin. Sections of 3-5 (m were prepared and stained with H&E and examined with light microscope

(Luna, 1968).

Examination of the feti

a- Morphological examination of feti: This was carried out as described by Hayes (1986) where the horns of the gravid uteri were exteriorized, opened and the feti were gently pulled out. The feti were examined for revealing the gross abnormalities and weighed. The number of implantation sites and live and dead feti were counted. Two thirds of the obtained feti were kept in Bouin's solution for at least 1 week for exploring the visceral abnormalities. The other third of feti was eviscerated and kept in 95% ethanol for revealing the skeletal malformations.

b- Visceral examination of the feti: The feti preserved in Bouin's solution were rinsed with cold water and examined grossly. Sections were made using the technique described by Hayes, 1986.

c- Skeletal examination: The feti were stained in Mallory's solution with alizarin red for 24 hours (Staples and Schnell, 1964). Then the feti were passed in 20, 50, 80, and 100% glycerol. The stained skeletons were examined under dissecting microscope for exploring any abnormalities in shape, size and absence of bones.

Statistical analysis:

T-test was used to analyze the obtained data as described by Snedecor (1969).

RESULTS

Effect of closantel on some blood parameters in pregnant female rabbits were recorded in tables 1, 2, 3, 4, 5 and 6.

Samples obtained at the 10th day of pregnancy after subcutaneous administration of closantel in a dose of 10 mg/kg to pregnant rabbits at day 0 (day of mating), day 7 (group A) and days 6 and 13 of pregnancy (group B) did not significantly affect any of the parameters measured (Tables 1 and 2).

Table (1): Effect of s/c injection of closantel (10 mg/kg body weight) given twice weekly apart at day 0 and 7 of pregnancy (group A) and day 6 and 13 of pregnancy (group B) on serum total protein, albumin concentration, α - β - γ -globulin concentration, red blood cells, hemoglobin concentration and packed cell volume in female rabbits compared with control group at the 10th day of pregnancy.

	¹ T.P (gm%)	Albumin (gm%)	α - globulin (gm%)	β - globulin (gm%)	γ - globulin (gm%)	² RBCs (n.mm ³)	³ HB	⁴ PCV %
Control	4.35± 0.3	1.89± 0.15	0.95± 0.12	0.84± 0.1	0.84± 0.1	5078000 ±779274	12.74 ±1.14	35.2± 1.6
Group A	4.8± 0.29	1.75± 0.2	1.02± 0.1	0.69± 0.11	1.03± 0.3	4479000 ±473632	12.41 ±0.8	35.8± 1.1
Group B	4.5± 0.01	1.71± 0.3	1± 0.12	0.77± 0.15	0.90± 0.2	4753000 ±563211	11.91 ±1.21	32.5± 2.0

¹T.P.: Total protein.

²RBCs: red blood cells.

³HB: Hemoglobin.

⁴PCV: Packed cell volume.

Table (2) Effect of S/C injection of closantel (10 mg/kg body weight) given twice weekly apart at days 0 and 7 of pregnancy (group A) and days 6 and 13 of pregnancy (group B) on white blood cell count, lymphocyte, neutrophil, monocyte, eosinophil and basophil numbers in pregnant female rabbits compared with control group at the 10th day of pregnancy.

	WBC n/mm ³	Lymphocytes %	Neutrophils %	Monocyte %	Esinophil %	Basophile %
Control	7850±1103	66.67±0.8	28.17±0.87	2.17±0.37	1.17±0.17	1.97±0.21
Group A	8458±1314	64.67±1.73	26.33±1.45	2.15±0.42	1.34±0.32	2.2±0.21
Group B	8420±1055	65.4±1.21	27.13±0.9	2.23±0.31	1.33±0.61	2.1±0.4

Day 0 is the day of mating.

mples obtained at 20th day of pregnancy after subcutaneous administration of closantel in a dose of 10 mg/kg to pregnant rabbits at day 0 (day of mating), day 7 (group A) and days 6 and 13 of pregnancy (group B) did not significantly affect total protein concentration, albumin, globulin

(α and β) number of red blood cells, hemoglobin concentration, packed cell volume %, white blood cell numbers, lymphocyte count, neutrophils and basophil count. On the other hand, closantel treatment group. Also, it significantly increased monocyte and eosinophil counts in group A compared with the control one (Tables 3 and 4).

Table (3) Effect of S/C injection of closantel (10 mg/kg body weight) given twice weekly apart at days 0 and 7 of pregnancy (group A) and days 6 and 13 of pregnancy (group B) on concentration of total protein, albumin, α -, β -, and γ -globulin, red blood cell count, hemoglobin concentration and packed cell volume (PCV) in pregnant female rabbits compared with control group at the 20th day of pregnancy.

	¹ T.P (gm%)	Albumin (gm%)	α - globulin (gm%)	β - globulin (gm%)	γ - globulin (gm%)	² RBCs (n/mm ³)	³ HB	⁴ PCV %
Control	4.55± 0.2	1.65± 0.2	0.92± 0.21	0.71± 0.01	0.82± 0.1	5078521 ±672432	11.42 ±1.03	34.2± 1.2
Group A	4.86± 0.31	1.55± 0.12	1.12± 0.1	0.69± 0.21	1.5± 0.1*	4299012 ±473250	11 ±1.8	33.8± 1.1
Group B	4.68± 0.21	1.74± 0.62	1.74± 0.2	0.72± 0.2	1.6± 0.2*	4752190 ±652123	10.95 ±1.21	32.5± 2

¹T.P.: Total protein.

²RBCs: red blood cells.

³HB: Hemoglobin.

⁴PCV: Packed cell volume.

Day 0 is the day of mating.

*Significantly different at P< 0.05.

Table (4) Effect of S/C injection of closantel (10 mg/kg body weight) given twice weekly apart at days 0 and 7 of pregnancy (group A) and days 6 and 13 of pregnancy (group B) on white blood cell count, lymphocyte, neutrophil, monocyte, eosinophil and basophil numbers in pregnant female rabbits compared with control group at the 20th day of pregnancy.

	WBC n/mm ³	Lymphocytes %	Neutrophils %	Monocyte %	Eosinophil %	Basophile %
Control	7758±1148	65.61±0.7	26.13±0.37	2.47±0.57	1.25±0.17	2.1±0.2
Group A	8215±1214	65.67±0.92	25.33±3	6.3±0.42*	4.22±0.91*	2.3±0.2
Group B	8420±1055	66.3±1	27.52±1.9	3.04±0.31	2±0.51	2.4±0.7

Day 0 is the day of mating.

*Significantly different at P< 0.05.

Samples obtained at 28th day of pregnancy (after slaughter) after subcutaneous administration of closantel in a dose of 10 mg/kg to pregnant rabbits at day 0 (day of mating), day 7 (group A) and days 6 and 13 of pregnancy (group B) did not significantly affect total protein concentration, albumin, globulin (α and β), number of red blood cells, hemoglobin concentration, packed

cell volume %, white blood cell numbers, lymphocyte count, neutrophils and basophil count. On the other hand, closantel treatment in both groups significantly increased γ - globulin concentration in serum compared with the control group. Also, it significantly increased monocyte and eosinophil counts in group A and B compared with the control one (Tables 5 and 6).

Table (5): Effect of S/C injection of closantel (10 mg/kg body weight) given twice weekly apart at day 0 and 7 of pregnancy (group A) and day 6 and 13 of pregnancy (group B) on concentration of total protein, albumin, α - β -, and γ -globulin, red blood cell count, hemoglobin concentration and packed cell volume (PCV) in pregnant female rabbits compared with control group at the 28th day of pregnancy.

	¹ T.P (gm%)	Albumin (gm%)	α - globulin (gm%)	β - globulin (gm%)	γ - globulin (gm%)	² RBCs (n.mm ³)	³ HB	⁴ PCV %
Control	4.35± 0.25	1.77± 0.16	0.94± 0.31	0.83± 0.1	0.69± 0.05	6080000 ±791113	12.34 ±1.21	34.2± 1.5
Group A	4.5± 0.31	1.72± 0.2	1.12± 0.7	0.68± 0.11	1.7± 0.25*	5478000 ±483631	11.82 ±0.7	35.3± 1.1
Group B	4.32± 0.11	1.69± 0.3	1± 0.14	0.79± 0.09	1.65± 0.18*	5213246 ±563124	11.92 ±1.31	34.2± 1.3

¹T.P.: Total protein.

²RBCs: red blood cells.

³HB: Hemoglobin.

⁴PCV: Packed cell volume.

Day 0 is the day of mating.

Significantly different at P< 0.05.

Table (6) Effect of S/C injection of closantel (10 mg/kg body weight) given twice weekly apart at days 0 and 7 of pregnancy (group A) and days 6 and 13 of pregnancy (group B) on white blood cell count, lymphocyte, neutrophil, monocyte, eosinophil and basophil numbers in pregnant female rabbits compared with control group at the 28th day of pregnancy.

	WBC n/mm ³	Lymphocytes %	Neutrophils %	Monocyte %	Esinophil %	Basophile %
Control	8243±1056	64.37±1	25.34±0.82	2.57±0.45	1.52±0.11	1.92±0.2
Group A	8742±1512	63.68±1.78	24.57±1.3	7.9±0.37*	5.83±1.03*	2.2±0.18
Group B	8720±1057	65.2±1.24	26.14±0.9	7.1±0.3*	4.8±0.9*	2.1±0.8

Day 0 is the day of mating.

*Significantly different at P< 0.05.



Figure 1. Liver of treated animal, group B, showing vacuolar degeneration of hepatocytes particularly around central vein with many necrotic cells (X100).

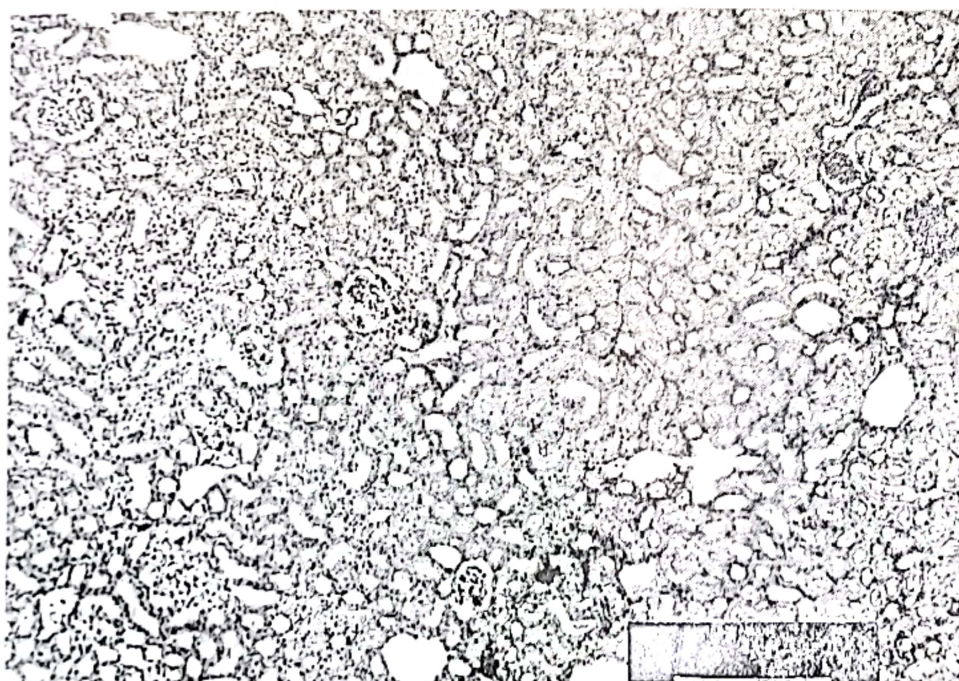


Figure 2. Kidney tissue of treated animal, group B, showing area of coagulative necrosis (upper right) with hyaline renal casts observed in renal tubes (X100).




Figure 3. Spleen of treated animal, group A, showing hyperplastic lymphoid follicles (X100).

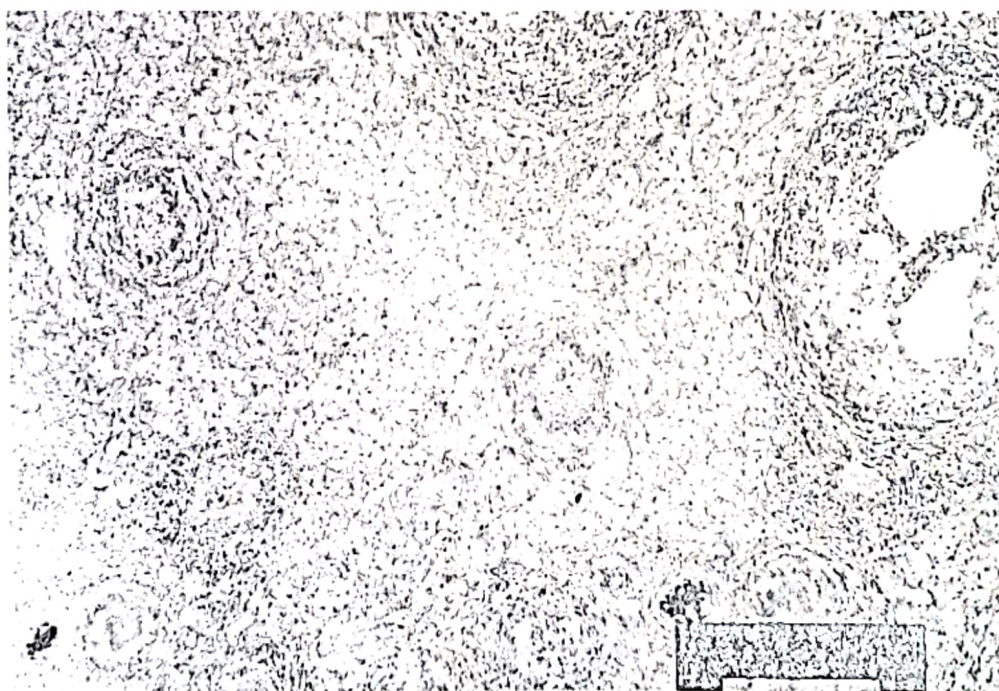


Figure 4. Ovarian tissue of treated animal, group A, showing 2 necrotic basophilic primary follicles (X100).

Histopathological findings:

Subcutaneous injection of closantel in a dose of 10 mg/kg body weight twice a week apart in female rabbits at days 0 and 7 of pregnancy (group A) and days 6 and 13 of pregnancy (group B) revealed microscopic but not gross lesions in parenchymatous organs examined. The liver tissue showed vacuolar degeneration of hepatocytes particularly those cells around central veins. Necrobiotic changes were also observed in cells of both groups manifested by nuclear pyknosis, karyorrhexis or karyolysis. All pathological changes were observed in both groups but not in control group. However, necrobiotic changes were seen more in group B (Figure 1).

Examination of the kidneys revealed a sporadic necrotic desquamated cells and hyaline casts in renal tubules that appear more in group B. Focal areas of coagulative necrosis were also observed in animals in group B (Figure 2) and in one animal in group A. Blood vessels were moderately

congested in both groups.

Microscopic examination of lymphoreticular organs revealed follicular hyperplasia of spleen corpuscles (Figure 3). Cortical hyperplasia in thymus gland and mesenteric lymph nodes in both groups. This was more seen in group A. Hemodrin pigments were moderately increased in splenic tissues in both groups compared with control group.

Microscopic study of the ovarian tissue showed atretic oocytes in primary follicle stage with basophilic cytoplasm of group A (Figure 4).

Effect of closantel on fetal development:

Closantel treatment in both periods did not significantly affect fetal development by morphological (table 7), visceral and skeletal examinations. There was decreased number of feti in the group treated with closantel at days 0 and 7 of pregnancy compared with control group.

Table (7) Morphological changes in feti obtained from mother rabbits given closantel (10 mg/kg body weight) subcutaneously twice, week apart, at days 0 and 7 (group A) and days 6 and 13 (group B) of pregnancy.

	Fetal body weight gm	Number of feti	Number of viable feti	Implantation site
Control	27±2.13	8.33±0.80	7.5±1.02	8.33±0.8
Group A	31.1±2.21	5.40±0.81*	5.4±0.81	5.4±0.81
Group B	32.2±3.1	6.5±0.95	6.25±1.1	6.5±0.95

Significantly different at $P < 0.05$.
Day 0 is the day of mating.

DISCUSSION

In the present study closantel treatment enhanced plasma (-globulin concentration at the 20th and 28th day of pregnancy in both groups. Also eosinophils and monocytes were increased in group A at the 20th and 28th day of pregnancy and at 28th of pregnancy in group B. Histopathological finding (after slaughter) revealed that there is activation in the mesenteric lymph nodes, splenic corpuscles and thymus gland.

γ -globulin fraction in serum contains antibody molecules which secreted from the B-cells after its activation and changed into secretory plasma cells (Fudenberg, 1977). Lymphocytes possess receptors on their plasma membrane for a wide range of mediators. Increased intracellular calcium is required for white blood cells responses and it has been suggested that calcium is the key to control lymphocyte responses (Sandborg and Smolen, 1988; Shaafi and Molski, 1988). Closantel as an ionophore probably enhanced, directly or indirectly, lymphocytes to secrete immunoglobulins and activate lymph nodes to increase the number of eosinophils and monocytes. In vitro proton ionophores which have immunostimulatory effects (Ca^{2+} ionophore and monensin) occur through its action on $\text{Na}^+/\text{Ca}^{2+}$ exchange translocation occurring in mitochondrial membranes (Yolande et al, 1992, Vicraso and Jennifer, 1984).

The anthelmintic activity of closantel is linked to its capacity for uncoupling electron - transport associated oxidative phosphorylation. These "uncouplers" are hydrogen ionophores, translocating proton through the inner mitochondrial membrane of the parasite and inhibit coupling between the electron transport and phosphorylation reactions and thus inhibit ATP synthesis. Concurrent with these changes and depression in ATP levels are depression in parasite motility (Pax and Bennett, 1989, Martin, 1997). Similar effects of closantel on vertebrate liver cells and mitochondria has been proposed and that it may affect a number of biochemical and physiological processes (Bacon et al, 1998). Moreover, it is possible that closantel may alter pH of the integument of the parasite before significant changes in ATP levels are detectable (Pax and Bennett 1989). Proton ionophores such as monensin and nigracin enhance the cytotoxic potency of antibody-delivered "RICINA" chain by raising the pH within the cell (Vicraso and Jennifer 1984, Finbloom, 1986). So the suggested effects of closantel may reside in the pH alteration and in electron transport.

Immunoglobulins are actively involved in parasitic elimination. They bind to the surface of the parasite (integument) in large numbers and allow the entrance of killer molecules of eosinophils and macrophages (Metzger et al, 1985). Therefore, the increased number of eosinophils in this study may assist in parasitic elimination. Moreover, monocytes contain large numbers of active metab-

olites and enzymes that kill the invading parasite (Daniel et al, 1987). This immuno-potential effect may be another mode of action of the anthelmintic activity of closantel and may explain its protection against re-infection.

It is worth mentioning that closantel treatment at therapeutic dose did not affect or alter many blood parameters (total WBC count, total RBC count, hemoglobin concentration, packed cell volume, lymphocyte number, basophile number, and neutrophil number). Closantel not related with imidazole compounds, that represents a high safety. The LD₅₀ of closantel is 35.9 mg/kg (Trailovic and Zivanov, 1991) means acceptable safety margin.

Histopathological examinations of the liver and kidney of the treated groups showed vacular degeneration around central veins and necrobiotic changes in hepatic parenchyma. The kidneys examination revealed sporadic desquamated necrotic cells in the urineferous tubules with focal areas of coagulative necrosis. These changes were seen more in closantel treated group at 6 and 13 day of pregnancy than treated group at 0 and 7 days of pregnancy. Similar observations have been reported previously by (Traitovic et al., 1992 and Mcentee et al., 1995). the daily subcutaneous injection of male and female rats over the 15-day administration period with closantel resulted in a steady reduction in the weight of some organs such as heart, lungs, liver, and testes (Trailovic et

al, 1992 Mcentee et al., 1995). The highest concentration of closantel residues are found in the kidney with slightly lower levels in the liver. The residues persist in most tissues for at least 42 days (Heitzman, 1994). These changes may be attributed to a direct cytotoxic effect of the studied anthelmintic or its metabolites during its excretion through the kidney and detoxification in the liver. Closantel binds to plasma proteins and slowly eliminated by urine (Hennessy et al, 1993).

The group given closantel at 0 and 7 days of pregnancy showed improvement and less necrobiotic changes in hepatic parenchyma and uriniferous tubules that means these changes may be reversible because hepatic parenchyma and urineferous tubules cells are rapidly proliferating cells. A case of over dosage with closantel in a dog induced optic neuritis, retinal degeneration, partial deafness, hepatotoxicosis and myopathy, only blindness was irreversible (Traitovic et al., 1992 and Mcentee et al., 1995).

Subcutaneous administration of closantel in a dose of 10 mg/kg body weight at 0 and 7 days of pregnancy significantly decreased the number of feti compared with the control one. This result may be attributed to the effect of closantel on the ovary. Histopathological examination of the ovary of closantel-treated rabbits showed atretic oocytes in primary follicles with basophilic cytoplasm (calcification). These atretic oocytes may be due to a direct ion exchange effect of the studied an-

thelminthic. There are some evidences which suggested that calcium has a regulatory role in the control of ovulation (Tse and Hille, 1993). Extracellular calcium ions are obligatory for successful fertilization in mammals (Kile and Nett, 1994).

Closantel did not cause embryotoxic or teratogenic effect in rabbit by morphological, visceral and skeletal examinations of the offspring. The present result could be attributed to prevention of passage of closantel via the placental barrier as its molecular weight is 662.82. This is consistent with Harbison et al., (1975) who stated that drugs with a molecular weight of <600 do readily cross the placenta.

Van Cauteren et al., 1995 revealed that embryotoxic or teratogenic potential effects of closantel in rats and rabbits was absent in a three-generations study. Uppal et al., (1995) recorded that lambs born to ewes following treatment with closantel at 10 mg/kg body weight twice during the gestation period had significantly higher weights and a similar trend was observed at weaning. Also A-Qudah et al., 1999 studied the effect of oral administration of closantel 10mg/kg in pregnant she camels and concluded that no adverse effects of the treatment.

REFERENCES

- Al-Qudah K.M., Sharif, L.A., Al-Rawashdeh, O.F., and Al-Ani, F.K (1999). Efficacy of closantel plus albendazole liquid suspension against natural infestation of gastrointestinal parasites in camel. *Veterinary parasitology*, 82 (2) 173-178.
- Bacon, J.A., Ulrich, R.G., Davis, J.P., Thomas, E.M. (1998). Comparative in vitro effects of closantel and selected beta-ketoamide anthelmintics on a gastrointestinal nematode and vertebrate liver cells. *Journal of veterinary pharmacology and therapeutics*, 21 (3) 190-198.
- Bezubic, B., Byszewska, S.F and Sankiewicz, M. (1980). Immunological studies on experimental haemonchosis. *Acta Parasitology*, 27 (44):391-398.
- Daniel, S., John, D.S. and Vivian, J. Basic and Clinical Immunology. (1987) Lang medical publication, page 100.
- Drupt, F. (1974). Calorimetric determination of albumin. *Biology*. 2, 765.
- Finbloom, D.S. (1986). Subcellular characterization of the endocytosis of small oligomers of mouse immunoglobulin G in murine macrophages. *Journal of immunology*, 136 (3), 844-851.
- Fudenberg, H.H (1977). Basic immunogenetics, 2nd Ed. Oxford. Univ Press, Ames, Iowa, U.S.A, P.91.
- Harbison, R.D., Olubadewo, J.D. and Sastry, B.V. (1975). Basic and Therapeutic Aspects of Prenatal Pharmacology. Raven Press, NY. 107-120.
- Hayes, A.W (1986). "Principles and methods of toxicology" Raven Press, New York, P.141-184.
- Heitzman, R.J. (1994). Veterinary Drug Residues, Second edition, Black Well Science page 75.
- Hennssy, D.R; Sangster, N.C; Steel, J.W and Collins, G.H (1993) Comparative pharmacokinetic disposition of Closantel in sheep and goats. *Journal of veterinary pharmacology and therapeutics*, 16, 254-260.

- Hlasta, D.J., Demers, J.P., Foleno, B.D., Fraga-Spano, S.A.
- Guan, J. and Hilliard, J.J. (1998). Novel inhibitors of bacterial two-component system with gram positive antibacterial activity. *Bioorg Med. Chem. Lett.* 21,8: 1923-1928.
- Jain, N.C. (2000). *Schalm's Veterinary Hematology*, 5th edition. Lea and Febiger, Philadelphia, USA.
- Janssen (1994). Closantel ® anthelmintic. Toxicology, tolerance and withdrawal time. United Veterinary Drugs Industrial Co, Ltd, (UVEDCO), Sult-Jordan. personal communication.
- Jenkins, D.C., Topley, P Rapson, E.B (1987) *Fasciola hepatica* in vitro: increased susceptibility to Fasciolicides in a defined serum-free medium. *Parasitology*, 95, 307-311.
- Kaneko, J.J. (1989). *Clinical biochemistry of domestic animals*. Fourth Ed., Academic Press, London.
- Kile, J.P. and Nett, T. M. (1994). Differential secretion of follicle stimulating hormone and lutenizing hormone from ovine pituitary cells following activation of protein kinase A, protein kinase C or increased intracellular calcium. *Biology of Reproduction*, 50, 49-54.
- Luna, L.G (1968)" *Manual of histologic staining methods of the armed forces institute of pathology* "McGraw-Hill Book Co.New York, P.58.
- Maes, L. Vanparijs, O. and Marsbo, M.R. (1988). *Proceedings of the 4th congress of the European association of veterinary pharmacology and toxicology* (Budapest) Volume 2 page 330.
- Maes, L. Vanparijs, O., Lauwers, H. and Deckers, W. (1990). Comparative efficacy of closantel and tricalbin-dazol against *fasciola hepatica* in experimentally infected sheep. *Veterinary Record*, 127, 450-452.
- Martin, R.J. (1997). Modes of action of anthelmintic drugs. *The veterinary journal*. 154, 11-34.
- Meentee, K. Grauweis, M. Clerex, C. and Henroteaux, M (1995). *Veterinary and human toxicology*. 37,234-236.
- Mckellar, Q.A. and Kinabod, D. (1991). The pharmacology of flukicidal drugs. *British Veterinary Journal*. 1-47, 306-619.
- Melvin. (1987). *Electrophoresis*. Ed; John Wiley and Sons, London, U.K.
- Metzger, H.G., Alcaraz, R.H., Kinet, J.P., Pribluda, V. and Quarto, R (1985). The receptor with high affinity for immunoglobulin E. *Annu. Rev. Immunol.* 4:419-470.
- Pax, R. A. and Bennett, J. L.(1989; Effect of closantel on intrategumental pH in *Schistosoma mansoni* and *Fasciola hepatica* . *Journal of parasitology*, 75, 169-171.
- Pearse, A. G. (1961): *Histochemistry, Teoretical and Applied*", 2nd Ed J. A. Churchill, Ltd, London, P. 217-219.
- Richardson, V. C. (2000): *Rabbits Health, Husbandry and Diseases*, Black Well Science, Page 45-77.
- Sandborg, R. R. and Smolen, J. E. (1988): Early biochemical events in leukocyte activation *Lab Invest*, 59, 300.
- Shaafi, R. I. and Molski, T. F. (1988): Activation of the neutrophil, *Prog. Allergy*, 42,1.
- Staples, R. E. and Schnell, V. L. (1964): Refinements in rapid clearing technique in the KOH-Alizarin red method for fetal bone, *Stain technology* 1, 39, 61.
- Snedecor, G. W. (1969): "Statistical Methods". 4th edition The Iowa State University Press, Ames, Iowa, USA Page 91.
- Stryer, L. (1995): *Biochemistry*. NY. Freeman, W. H. and company.

- Szendro, Z., Tag, T. H., Den, E. L. and Nemeth, P. (1984): Effect of double matting on conception rate and litter size in rabbits. Proc. III World Rabbit Congress. Volume 2: 124.
- Trailovic, S., Knezevic, M. and Zivanov, D. (1992): Pathological changes in the organs of rats after multiple doses of closantel. Veterinarski-Glasnik. 46, 103-108.
- Trailovic, S. and Zivanov, D. (1991): Toxicity of closantel after the use of high doses for a prolonged period. Veterinarski-Glasnik, 45:11-12, 841-844, 6 ref.
- Tse, A and Hille, B. (1993): Role of voltage-gated sodium and calcium channels in GnRH-induced membrane potential changes in identified rat gonadotrophes. Endocrinology. 132, 1475-1481.
- Uppal, R. P., Yadav, C. L., Verma, S. P. and Kalra, S. (1995): Effect of closantel on periparturient FEC and lambing performance of ewes naturally infected with resistant *Hemonchus contortus*. Indian Veterinary Journal, 72 (5), 497-499.
- Van Cauteren, H., Vandenberghe, J., Herin, V., Vamparys, P. and Marsboom, R. (1995): Toxicological properties of closantel. Drug chemioistry and toxicology, 8 (3) 101-123.
- Vicroaso and Jennifer. (1984): Carboxylic ionophors enhance the cytotoxic potency of ligand- and antibody-delivered Ricin A chain. Journal of experimental medicine, 60, 1234-1240.
- Weichsalbaum, T. E. (1946): Colorimetric method for the determination of total proteins. Am. J. Clin. Path., 16:40.
- Yolande, B. R., Sally, B. V., and Jacques, M. (1992): Macrophage activation for intracellular killing as induced by Ca^{+2} - ionophor. Biochemistry journal. 284, 378-392.