



## VOLUMETRIC ANALYSIS OF TOTAL PHARYNGEAL AIRWAY SPACE USING CONE BEAM COMPUTED TOMOGRAPHY AMONG ADULT EGYPTIANS

Ahmad Mohamad El Rawdy\* and Walaa Elsayed Elgemeeay\*\*

### ABSTRACT

A typical airway is needed for typical improvement of the craniofacial structures. The objective of the research was to; analyse and contrast the pharyngeal airway volume in the class I and class II facial skeletal patterns using cone beam computed tomography.

**Methods:** The present retrospective study was led on 80 cone beam computed tomography (CBCT) records of adult egyptians ranging in age from 20-40 years. The records were equally divided into 2 groups; group I (G1) skeletal class I ANB =1°-4°), (group II, skeletal class II (G2) ANB >4°). Evaluation of the pharyngeal air way space volume was conducted and statistically analyzed to contrast between G1 and G2

**Results:** Statistically significant distinctions was found on total pharyngeal airway volume between G1&G2

**Conclusion:** The entire volume of pharyngeal airway space was much larger in G1 than G2 subjects.

**KEYWORDS:** Cone beam computed tomography, total volumetric analysis, pharyngeal airway space(PAS), on-demand software.

### INTRODUCTION

Total airway volume and respiratory function are strongly identified by the orthodontist. Studies have confirmed that airway problems are significantly related to different types of malocclusion. Interestingly, nasal blockage is

a significant etiological factor for dentofacial anomalies. <sup>(1-3)</sup> That is why analysis of the airway is an essential diagnostic step for patients with breathing disorders. In developing patients with skeletal malformation and signs of adenoid facies, early diagnosis, expectation, and appraisal of the functional etiological variables are basic for the

\* Lecturer of Oral Radiology, Faculty of Dentistry, Suez Canal University.

\*\* Lecturer of Orthodontics, Faculty of Dentistry, Suez Canal University

restoration of normal craniofacial growth and the stability of the treatment outcome.<sup>(2,4)</sup>

Significant relationships between the pharyngeal airway space and both dentofacial and craniofacial structures have been reported.<sup>(5,6)</sup> By reason of using the two-dimensional lateral or frontal cephalograms which are not able to identify the soft tissue contour in the third dimension, most of the airway studies relating respiratory tract anatomy as well as the craniofacial growth and development are limited. Therefore, limiting analysis of areas and volumes of prints. Currently, the advances in computed tomography imaging and the three-dimensional technology allow better visualization of the airway and volumetric analysis.<sup>(7)</sup>

Clinicians would more be able to effectively carry out volumetric measurements and determine the cross-sectional areas of the airway in all planes: coronal, sagittal, and axial. The axial plane, which is not seen on a lateral cephalogram, is the most physiologically significant plane since it is perpendicular to the airflow.<sup>(8,9)</sup> Cone-beam CT systems have been developed specifically for the maxillofacial region with an advantage of the reduced radiation doses compared with conventional CT making accurate and easy analysis of the airway anatomy been possible.<sup>(10)</sup> from those Benefits of CBCT over traditional multidetector computed tomography MDCT include considerable rapid scan time, isotropic voxels offering superior spatial resolution, decreased cost, reduced image artifact and its display modes that are easily employed by the operator and highly specific to maxillofacial imaging.<sup>(11-13)</sup>

The aim of the present study was to investigate whether the positional relationships between the jaws could affect the total volume of the pharyngeal airway in subjects with skeletal class I and skeletal class II according to the ANB angle.

## MATERIALS AND METHODS

The present retrospective research was carried out on the CBCT records obtained from the archives of the outpatient clinic of the Oral Radiology Department, Faculty of Dentistry, Suez Canal University. Out of respect for patient confidentiality, all personal information concerning the patients other than gender and age was hidden. The study was conducted on all available 80 CBCT scans of pharyngeal airway space of both genders with age ranging from 20 to 40 years. Foremost, any CBCT scans chosen to be incorporated into had essentially to reveal the entire region of the pharyngeal airway space and be of high quality images free from artifacts caused by metallic objects that may hinder pharyngeal airway visualization. Inclusion criteria additionally included: no pharyngeal pathology, no chronic mouth breathing, no permanent snoring, not undergo tonsillectomy or adenoidectomy, additionally, exclude subjects with obvious hyperplasia of tonsils and adenoids and no complaints of nasal obstruction nor cleft lip or palate, not subjected to any orthodontic treatment.

The picked out CBCT scans were then divided into 2 groups according to the ANB angle. G1 Class I, maxillomandibular relationship having ANB angle between 1°-4° included 40 subjects: G2 Class II maxillomandibular relationship having ANB angle larger than 4° included 40 subjects, Sample size calculation was carried out using G\*Power software Version 3.1.9.2.<sup>(14)</sup>

### CBCT scanning protocol:

All CBCT scans used in the available study were acquired using the Scanora 3D imaging system (Sordex, Helsinki, Finland) using a CMOS flat panel detector with isotropic voxel size 133  $\mu\text{m}$ , the x-ray tube used to scan the patients possess a current intensity 10 mA, 90 Kvp and a focal spot size 0.5mm. The scanning time was 10 seconds of pulsed exposure resulting in an effective exposure time of

2.4 seconds to scan FOV (field of view) of 14 cm height  $\times$  16.5 cm width. FOV adjustment was guided by three laser light beams to centralize the area of interest within the scanning field. The primary reconstruction time for DICOM data set was 2 minutes. Then, the raw DICOM data set images were imported to the On-Demand software (Cybermed, Seoul, Korea) for secondary reconstruction.

### Image analysis and volumetric analysis of the total volume of the pharyngeal airway space(PAS):

Volumetric calculation was done through “segmentation” of the pharyngeal airway space, the boundaries of pharyngeal airway analysis, proposed by **Grauer**<sup>(15)</sup> were chosen for this study. After defining the borders, a yellow marker (seed point) was placed within the selected boundary. In other words, defining the region or tissue of interest. This step has to be performed before extracting any quantitative data from the CBCT image. In this study, semiautomatic segmentation was conducted where the software defines the boundaries of the pharyngeal airway space using implemented mathematical and computer algorithms, then minimal manual

correction was carried out afterwards to delete the unwanted or include the deficient regions.

Images were examined and the region of interest (pharyngeal airway space) was selected to be incorporated in the three orthogonal planes (axial, coronal and sagittal).

The volume of the empty space within the pharyngeal airway was done using “thresholding” level. This was carried out by limiting the window level to allow only the structures having CT number same as air or less to be apparent in the DICOM data set of the segmented part.

“Region growing” was used to define pharyngeal airway from the image through marking a point called a seed point in the axial cut, then the software automatically grows a 3D volumetric region of interest by comparing the adjacent volume elements (voxel) with the seed point in terms of their image intensity characteristics and including only voxels with intensity similar to that of the seed point within the region of interest<sup>(16)</sup>. at the end of growing process, the interior of the pharyngeal airway filled with distinct color. (Fig 1)

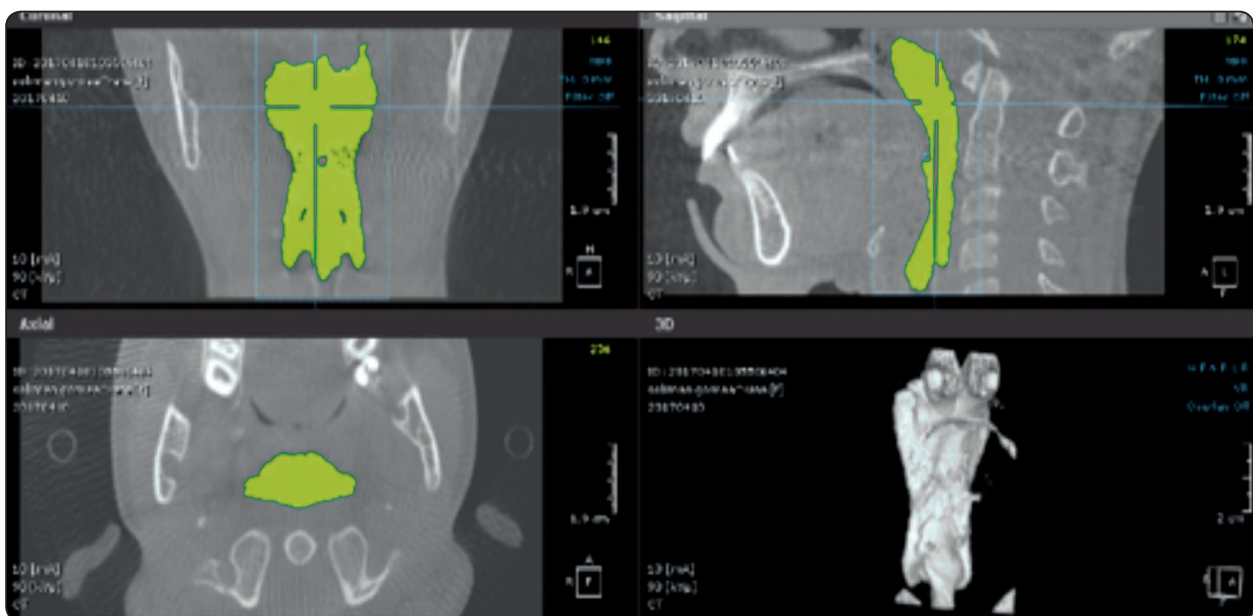


Fig (1): CBCT image revealing a defined and colored pharyngeal airway space in the axial, coronal and sagittal planes according to the threshold level.

Minimal manual correction was performed in the three orthogonal planes to remove the unwanted (neighboring air spaces or foramina) or include deficient regions. (17)

Finally, the segmented volume of pharyngeal airway was then displayed as a three-dimensional image, with the volume of the pharyngeal airway calculated in cubic centimeters (cc) (Fig 2).

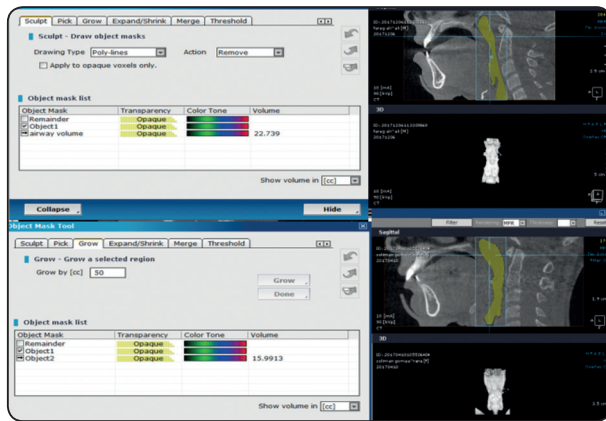


Fig. (2): 3D segmented pharyngeal airway revealing the volume in cubic centimeter.

Lateral cephalograms were constructed using the OnDemand software then the patients were divided into G1 ANB (1°-4°) and G2 ANB > 4° group depending on the ANB angle. Both the ANB angle and airway volume of all patients were analyzed separately by two independent oral radiologists. Each performed the analysis twice with two weeks' period in between the two readings to assess the intra-observer and inter-observer agreement.

The ANB angle and total volume of the pharyngeal airway space for all scans of subjects in groups G1 and G2 were measured and tabulated.

**Statistical analysis:**

Inter-observer and intra-observer agreement was assessed using Cronbach's alpha reliability coefficient and Intra-Class Correlation Coefficient (ICC).

Statistical analysis was performed with IBM® SPSS® Statistics Version 20 for Windows. The relationship between maxillomandibular relationship and total volume of pharyngeal airway space (PAS) was tested with the Pearson correlation coefficient (r) at significant level  $P \leq 0.05$ . Independent sample T-test was performed to compare the averages of total volume of pharyngeal airway space between the group I (G1) (ANB = 1°- 4°) and group II (G2) (ANB > 4°) at significant level  $P \leq 0.01$ .

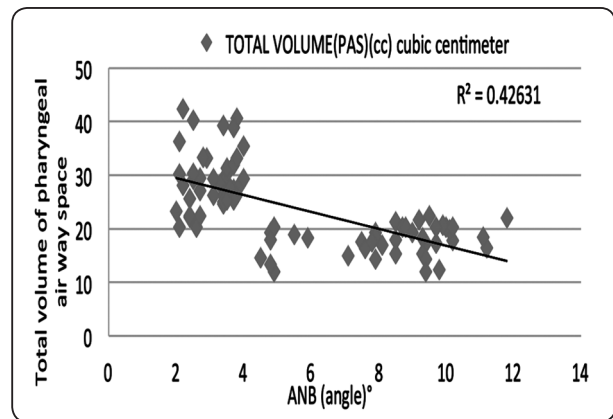


Fig. (3) Correlation between ANB angle and total volume of pharyngeal airway space.

TABLE (1) Correlation between ANB angle and Total Volume of pharyngeal airway.

Total volume pharyngeal airway space (PAS)	
Correlation coefficient (r)	-0.653
$P \leq 0.05$	0.00*

The results in Table 1 and Figure 3 showed that there are negative and significant correlations ( $r = -0.653$ ) between the ANB angle and total volume of pharyngeal airway space ( $P < 0.05$ ).

The total volume of the pharyngeal airway space in G1 ranged from 20.37 to 42.33 cubic centimeters (cc) with an average  $29.41 \pm 5.61$  while for the "G2" showed a minimum and maximum value of 12.00 and 22.37cc, respectively with average  $17.83 \pm 2.79$  cc for this variable [Table 2]. The independent two

sample *t*-test performed for comparison between the G1 and G2 group revealed that the total volume of the pharyngeal airway space was significantly different between the groups ( $P = 0.01$ ) [Table 2 and Figure 4].

TABLE (2) Mean values of Total Volume of pharyngeal airway space in G1 and G2

Groups	Min.	Max.	Mean	SD	T - cal	P-value (0.01)
Class I "G1"	20.37	42.33	29.41	5.61	11.685	0.00*
Class II "G2"	12.00	22.37	17.83	2.79		

(\*); Statistically significant, using T- test at  $P < 0.01$

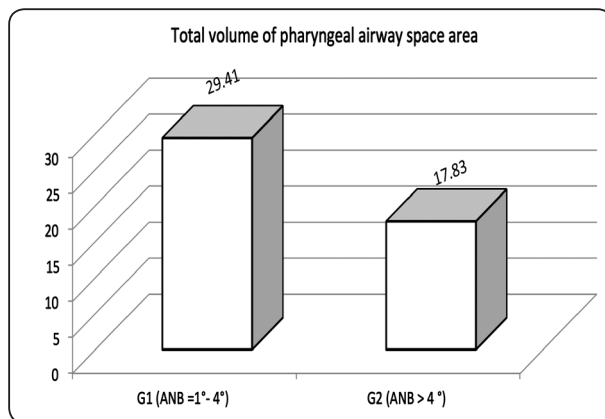


Fig. (4) Comparison of total volume of pharyngeal airway space area between G1 and G2.

The mean and standard deviation for the measurements of the PAS in the two skeletal patterns were smaller in the skeletal Class II "G2" and higher in the skeletal Class I "G1" (Figure 4). Results of independent *t*-test showed statistically significant *p*-value smaller pharyngeal airway dimensions in Class II "G2" patients.

**DISCUSSION:**

The main objective of this study was to compare the total volume of the pharyngeal airway of adult subjects with skeletal class I "G1" & class II "G2" malocclusion to see if there is any correlation between maxillomandibular relationship and the total volume of the pharyngeal airway space. **Kumar et al.**,<sup>(18)</sup> stressed that, because assessment of anatomic landmarks in 3D is still under development, the transition from the 2D to the 3D analysis could be achieved using CBCT synthesized cephalograms. Therefore, in this study also lateral cephalograms were constructed from the CT volumetric data with the help of OnDemand software to distinguish the skeletal pattern.

The sample was divided into Class I "G1" and Class II "G2" skeletal patterns in line with the ANB angle was chosen because as this is one of the most used standards in the determination of the anteroposterior relationship between the maxilla and the mandible<sup>(19,20)</sup>. Nevertheless, this angle might be influenced by the anteroposterior position of nasion relative to Points A and B, among other factors, and some experts have suggested that the diagnosis of such differences must be based on more than one anteroposterior appraisal.<sup>(21&22)</sup>

However, as previously mentioned, two-dimensional radiographic cephalometry is a limited method to analyze the 3D pharyngeal airway space in all three dimensions. The airway is visualized only in a sagittal view on conventional cephalometric radiographs, and a complete evaluation may not be accurate. CBCT is an accurate and a more reliable technique to assess the airway in three dimensions. Cone beam computed tomography employed in our study being a reliable and appropriate three dimensional technique that offers lower radiation dosage to the patient.<sup>(13)</sup> Automatic segmentation with manual adjusting (semiautomatic segmentation) of images was performed for evaluation of the total volume of the pharyngeal air passage space since

it provides higher accuracy than automatic or programmed segmentation. In addition, it is less subjective than manual segmentation, easier, and requires even less time for image analysis<sup>(10,23,24)</sup>

In this examination, we watched that pharyngeal airway volume was significantly reduced in skeletal Class II “G2” patients compared to skeletal Class I “G1”, this agrees with the findings of **Ceylan** and **Oktay**<sup>(25)</sup> and in addition to **Kerr**<sup>(26)</sup> who reported that Class II “G2” malocclusion subjects showed narrow nasopharyngeal airway space compared with Class I “G1” and normal occlusion subjects. **Kim et al.**,<sup>(20)</sup> and **Muto et al.**,<sup>(27)</sup> expressed that patients with retrognathic mandible had a tendency to have a littler airway volume contrasted and patients with a typical anteroposterior skeletal relationship through using of conventional two-dimensional cephalometry generally short or potentially posteriorly set mandible may drive the tongue and the soft palate back into the pharyngeal space, causing a diminishment in oropharyngeal volume.

**Dedefreitas et al.**,<sup>(6)</sup> estimated the measurements of both upper and lower oropharynx and found no noteworthy contrast between Class I “G1” and Class II “G2” malocclusions. Be that as it may, that review ordered its sample by molar relationship, which does not speak to the genuine skeletal pattern of the patients. **Wenzel et al.**,<sup>(28)</sup> detailed no relations between airway size and mandibular morphology, despite the fact that a noteworthy relationship was seen between changes in nasopharyngeal airway size and maxillary prognathism.

## CONCLUSION

- A positive correlation was found between skeletal malocclusion and total airway volume.
- In patients with Class II “G2” skeletal malocclusion the total airway was narrower than skeletal class I “G1”.

## REFERENCES

1. Linder-Aronson S. Respiratory function in relation to facial morphology and the dentition. *Br J Orthod.* 1979; 6:59–71.
2. Kirjavainen M, Kirjavainen T. Upper airway dimensions in Class II malocclusion. Effects of headgear treatment. *Angle Orthod.* 2007; 77:1046–53.
3. Arun T, Isik F, Sayinsu K Vertical growth changes after adenoidectomy. *Angle Orthodontist* 2003; 73:146–150.
4. Ogawa T, Enciso R, Shintaku WH, Clark GT. Evaluation of cross-section airway configuration of obstructive sleep apnea. *Oral Surg Oral Med Oral Pathol Oral Radiol Endod.* 2007; 103:102–8.
5. Batool I, Shaheed M, Ali SA, Abbas A. Comparison of upper and lower pharyngeal airway space in Class II high and low angle cases. *Pak O Dent J.* 2010; 30:81- 4.
6. de Freitas MR, Alcazar NMPV, Janson G, de Freitas KMS, Henriques JFC. Upper and lower pharyngeal airways in subjects with Class I and Class II malocclusions and different growth patterns. *Am J Orthod Dentofacial Orthop.* 2006 Dec; 130:742–5.
7. Aboudara C, Nielsen I, Huang JC, Maki K, Miller AJ, Hatcher D. Comparison of airway space with conventional lateral head films and 3-dimensional reconstruction from cone-beam computed tomography. *Am J Orthod Dentofac Orthop.* 2009; 135:468–79.
8. Schwab RJ. Upper airway imaging. *Clin Chest Med.* 1998; 19:33–54.
9. Isono S, Morrison DL, Launois SH, Feroah TR, Whitelaw WA, Remmers JE. Static mechanics of the velopharynx of patients with obstructive sleep apnea. *J Appl Physiol.* 1993; 75:148–54.
10. El H, Palomo JM. Measuring the airway in 3 dimensions: A reliability and accuracy study. *Am J Orthod Dentofacial Orthop.* 2010 137: 50.
11. Mozzo P, Procacci C, Tacconi A, Martini PT, Andreis IA. A new volumetric CT machine for dental imaging based on the cone-beam technique: preliminary results. *Eur Radiol.* 1998; 8:1558–64.
12. Hashimoto K, Kawashima S, Kameoka S, Akiyama Y, Honjaya T, Ejima K, et al. Comparison of image validity between cone beam computed tomography for dental use and multidetector row helical computed tomography. *Dento Maxillo Facial Radiol.* 2007; 36:465–71.

13. Scarfe WC, Farman AG. What is cone-beam CT and how does it work? *Dent Clin North Am.* 2008; 52:707–730.
14. Faul, F., Erdfelder, E., Lang, A.-G., & Buchner, A.: A flexible statistical power analysis program for the social, behavioral, and biomedical sciences. *Behavior Research Method.* 2007; 175-191.
15. Grauer D, Cevidanes LS, Styner MA, Ackerman JL, Proffit WR. Pharyngeal airway volume and shape from cone-beam computed tomography: Relationship to facial morphology. *Am J Orthod Dentofacial Orthop.* 2009; 136:805–14.
16. Deeb R, Preeti N, Malanim MD, Baljinder G, Kouros JK, Hamid SZ and Mark AZ. Three dimensional volumetric measurements and analysis of the maxillary sinus. *Am J Rhinol Allergy.* 2011; 25: 152-156.
17. Gonzalez RC, and RE Woods. Morphological image processing. In *Digital Image Processing.* Upper Saddle River, NJ: Pearson/Prentice Hall. 2008; 627–664.
18. Kumar V, Ludlow J, Mol A, Cevidanes L. Comparison of conventional and cone beam CT synthesized cephalograms. *Dentomaxillofacial Radiol.* 2007; 36:263–9.
19. El H, Palomo JM. Airway volume for different dentofacial skeletal patterns. *Am J Orthod Dentofac Orthop.* 2011;139.
20. Kim Y-J, Hong J-S, Hwang Y-I, Park Y-H. Three-dimensional analysis of pharyngeal airway in preadolescent children with different anteroposterior skeletal patterns. 2003; 124:470–9.
21. Ferrario VF, Sforza C, Miani JA, Tartaglia GM. The use of linear and angular measurements of maxillo-mandibular anteroposterior discrepancies. *Clin Orthod Res.* 1999; 2: 34–41.
22. Forst D, Nijjar S, Flores-Mir C, Carey J, Secanell M, Lagravere M. Comparison of in vivo 3D cone-beam computed tomography tooth volume measurement protocols. *Prog Orthod.* 2014; 23:15.
23. Atılım AKKURT, Mehmet DOĞRUSeyit HEKİMOĞLU İrfan KARADEDE Three-dimensional comparison of maxillary sinus volume in patients with and without posterior crossbite Maxillary sinus volume. *International Archives of Medical Research.*2013; 5:1-8.
24. Ceylan I, Oktay H. A study on the pharyngeal size in different skeletal patterns. *Am J Orthod Dentofac Orthop Off.* 1995; 108:69–75.
25. Kerr WJ. The nasopharynx, face height, and overbite. *Angle Orthod.* 1985; 55:31–36.
26. Muto T, Yamazaki A, Takeda S. A cephalometric evaluation of the pharyngeal airway space in patients with mandibular retrognathia and prognathia, and normal subjects. *Int J Oral Maxillofac Surg* 2008; 37:22 8e31.
27. Wenzel A, Williams S, Ritzau M. Relationships of changes in craniofacial morphology, head posture, and nasopharyngeal airway size following mandibular osteotomy. *Am J Orthod Dentofacial Orthop.* 1989; 96:138–143.