

SURGICAL QUIZ

Mohammed Hedaya,¹ Ahmed Hazem Helmy²

¹Assistant Professor of General & Hepatobiliary Surgery, ²Professor of General & Hepatobiliary Surgery, Head of Department of General Surgery & Experimental Surgical Unit, Theodore Bilharze Research Institute, Egypt

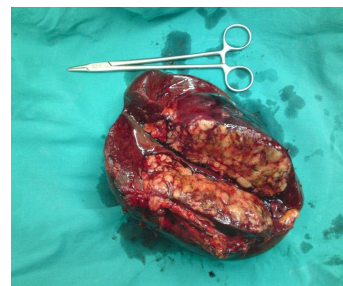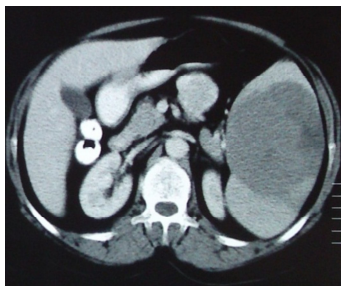
Correspondence to: Mohammed Said, Email: hedayamsm@yahoo.com

Female patient 48 years old complaining of left hypochondrial pain and swelling, no other swellings all over the body, Hg was 7mg%, upper endoscopy free, CT abdomen was done and exploration:

1-CT shows ----

2-Specimen shows ----

3-Most likely diagnosis



Please Send your answer to ejs@ess-eg.org

The correct answer and a short comment on the condition will be presented in the next issue of the journal.

The correct answer for previous Photo Quiz (Vol. 30, No. 4, October, 2011)

Answer:

1-This x ray shows ---- Free air in the peritoneal cavity.

2-What is the most likely diagnosis? Colonic perforation.

3-What is the proper management? Exploration and deal with perforation.

