

ORIGINAL ARTICLE

DYE-ASSISTED LYMPHATIC VESSELS SPARING DURING VARICOCELECTOMY, ITS SAFETY AND EFFICACY

Hosam Ghazy,¹ Basem saied²

¹Department of General Surgery, ²Pediatric Surgery Unit, Faculty of Medicine, Mansoura Univeristy, Egypt

Correspondence to: Hosam Ghazy, Email: hosamelbanna@hotmail.com

Abstract

Aim: To evaluate the practicability of isosulphan blue-based lymphatic vessel preservation during open varicocelectomy and its impact on the complication rate.

Methods: Two groups of 25 consecutive patients each were randomized. The indications for surgery included scrotal pain and fertility problems. All the patients underwent either standard open varicocelectomy using the high and the subinguinal approach (group A) and the other group had additional isosulphan blue dye-assisted open varicocelectomy (group B). After surgery, the patients were assessed at 3, 6 and 12 months for varicocele recurrence, hydrocele formation, testicular atrophy, pain or other complications.

Results: There were no intraoperative complications. There were no unfavorable reactions, scrotal haematomas, wound infection or testicular atrophy. At 3 months after surgery, the incidence of hydrocele in group A was 24% whereas in group B no hydroceles were detected ($P \leq 0.02$); at 6 months the 16% still had hydroceles. Two patients in group A had varicocele recurrence associated with persistent pain while, in group B only one patient had recurrence.

Conclusions: Varicocelectomy using isosulphan blue helps to identify and preserve the testicular lymphatic drainage. It prevents secondary hydrocele formation, the most common complication, with no supplementary risk to the patient. Also, postoperative testicular oedema can be avoided.

Keywords: Varicocelectomy, isosulphan blue, lymphatic vessels, hydrocele, infertility.

INTRODUCTION

Varicocele is associated with testicular atrophy and abnormal seminal factors contributing to male factor infertility.⁽¹⁾ Thus testicular volume discrepancy, poor seminal factors and chronic scrotal pain are major indications for varicocelectomy, but the surgical approach remains controversial.⁽²⁾

Some studies have challenged the role of varicocele in infertility, but the overwhelming majority of studies agree that varicocele is a major cause of male infertility.⁽³⁾

The severity of varicocele grading is negatively correlated with seminal variables⁽⁴⁾ and the duration of the disease has a negative influence on testicular function.⁽²⁾

Prophylactic varicocele ligation in selected adolescents is recommended to avoid impaired testicular growth, histology and function.⁽⁶⁾ The conventional treatment for varicoceles in childhood has been high ligation of the internal spermatic vessels via a retroperitoneal (Palomo) approach.⁽⁶⁾ Kass and Marcol⁽⁷⁾ reported that Palomo high-retroperitoneal ligation resulted in significant lower operative failure rates than did artery-sparing techniques.

Many surgical techniques for correcting varicoceles have been described, including laparoscopic ligation, high inguinal access and a subinguinal microsurgical access and sclerotherapy.⁽⁶⁾

Optical magnification and doppler probes allow identification and preservation of the internal spermatic artery, but artery preservation results in higher recurrence rates (3.5–20%) than mass ligation of the spermatic vessels (0–3.4%).⁽⁸⁾

The most common complication after internal spermatic mass ligation is hydrocele, which occurs in up to 25% of procedures.⁽⁹⁾ The cause is the disruption of the lymphatic drainage of the tunica vaginalis and testis.

Disrupted lymphatic drainage also impairs testicular function due to interstitial oedema.⁽¹⁰⁾

PATIENTS AND METHODS

This research was conducted between January 2009 and June 2011.

After obtaining informed consent, 50 patients were randomly assigned to two different groups: patients in group A, 25 patients (mean age 19.88 years, range 11–31) received conventional varicocele ligation, either high (11 patients) or subinguinal approach (14 patients) and patients in group B, 25 patients (mean age 17.52 years, range 8–28) had additional isosulphan blue administered.

Low sperm counts (in young men above 18 years) (36 patients), scrotal pain (44 patients) and testicular atrophy (two patients) were considered as indications for varicocelectomy.⁽⁵⁾

All patients treated for subfertility had at least three semen analyses before surgery that showed at least one abnormal variable (motility \square 50%, count \square 20 million/ml, and velocity \square 35 m/s).

The mean (range) follow-up after ligation was 14 (4–24) months. All patients underwent a complete physical examination, when both erect and supine, using the Valsalva manoeuvre. The varicocele was confirmed by Duplex ultrasonography.

The varicoceles were graded according to Steeno;⁽¹¹⁾ 26 were grade III (large, visible before palpation) and 12 grade II (moderate, detected with no Valsalva

manoeuvre) similarly distributed in both treatment arms. Bilateral varicocelectomy was used for all patients even in unilateral (4 patients) cases due to the inter-communicating veins.

At 15 min before starting the operation 1 mL of isosulphan blue (the isomer of Patent Blue, 1%) (Methylene blue, batch no.: MG/1593/03, Arabian Medical & Scientific Lab. Sup. Co., Dubai) was injected under the tunica albuginea (Fig. 1). The needle of the syringe was introduced through the scrotal skin till sense of release as it passes beneath the tunica albuginea. The internal spermatic vessels were delivered by a small high or low inguinal incision and all blood vessels ligated with 3/0 polyglactin 910. The blue-stained lymphatics are easily identified and preserved during the dissection.

After surgery, the patients were assessed by Doppler study at 3, 6 and 12 months for varicocele recurrence, hydrocele formation, atrophy, pain or other.

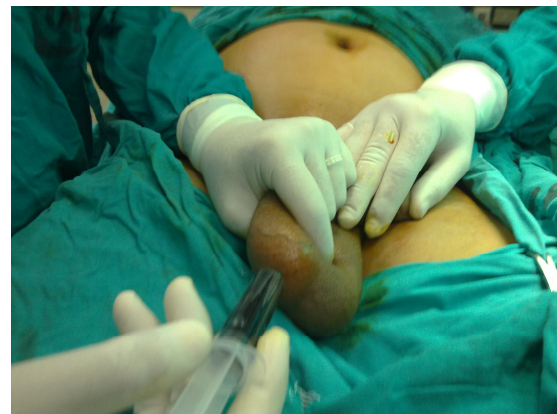

Fig 1. Scrotal subcutaneous injection of isosulphan blue before surgery.

RESULTS

Both groups were similar in age. There were no intraoperative complications related to anaesthesia or the operative manoeuvre, and all patients were discharged from hospital the day after surgery. There was no hypersensitivity to isosulphan blue dye, local inflammation after the scrotal injection, or wound infection. Only one patient developed scrotal haematoma in group B which was treated conservatively. Lymphatic vessel staining was successful in 100% (25/25) of patients in group B; after staining the draining lymphatics were clearly identified by their bluish appearance (Fig. 2) and could be easily preserved. In group B, no patient had a hydrocele at 3–6 months after surgery. By contrast, in group A (surgery alone) there were six cases of secondary hydrocele (24%; $P \square 0.025$). At 6 months, those patients continued to have

secondary hydroceles ($P=0.025$); four of them required hydrocelectomy.

At 1 year after surgery, no patients in group B developed a hydrocele. In group B, one patient had a blue-stained scrotum which resolved by 3 months after surgery. Otherwise there were no additional complications after isosulphan blue injection compared with conventional varicocelectomy. Recurrent varicocele was observed in two patients in group A (8%), while in group B no one developed recurrent varicocele.

Consequently there were no statistically significant difference in varicocele recurrence between both groups.

One patient in each group presented with persistent scrotal pain three months postoperatively, which needs assurance only. Therefore the both procedures were similar for ongoing testicular discomfort (3 months $P=0.695$; 6 months $P=0.5$). There were no cases of testicular atrophy in either group.

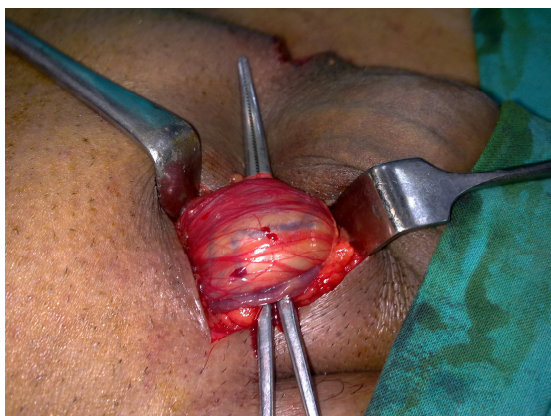


Fig 2. Lymphatic vessels staining.

DISCUSSION

Varicoceles are diagnosed in 15% of postpubertal men but rarely occur before puberty. They are generally accepted to be the most common cause of subfertility in adult men. Although recent surveys questioned the value of varicocelectomy for treating infertility, most studies indicate its importance for the therapeutic regimen.⁽³⁾

There is controversy over the management of varicoceles in children. The variety of different treatment options indicates that the ideal technique for surgical management has not yet been found.^(1,8)

The best varicocelectomy approach should be easily reproducible, with a high success rate, minimal complications and with a low technical and financial effort.

Some recent papers direct attention to the effect of lymphatic vessel division during varicocelectomy: hydrocele formation is not the only complication, because testicular enlargement due to parenchymal edema is a frequent finding.⁽¹²⁾

Kocvara et al. demonstrate a decrease in testicular function in those patients with postvaricocelectomy testicular edema, and they stress the importance of lymphatics preservation to ensure a better andrological outcome.⁽¹³⁾

During recent years, new 'lymphatic sparing' techniques have been introduced to achieve better results; one choice is magnification during microsurgery/laparoscopy,⁽¹⁴⁾ while most recently there has been mapping of lymphatic drainage with isosulphan blue.

Oswald et al.⁽¹⁵⁾ first described the use of isosulphan blue in varicocele surgery, administered in 28 boys before Palomo varicocelectomy. The lymphatics were clearly stained in 86% after scrotal injection and there was no postoperative hydrocele formation that goes in hand with our results.

Mapping with blue dye is a good technical option for all surgical varicocelectomy approaches. To achieve good mapping the vital dye should be injected into a space that is easily available to the surgeon, with minimal error, and can give a rapid onset, so that the injection could be performed when the patient is already under general anesthesia.

There are three different modes of injection: subdartoic, intravaginal and intraparenchymal.

In the conducted study, intraparenchymal (subtunical) injection is achieved with a fine needle just within the body of the testis. This is the faster and most specific compared to other approaches because related to the regional lymphatic drainage. It gives the highest rate of successful mapping and also represents a safe approach, as neither toxicity nor adverse reactions are reported in the literature.

From an anatomical point of view, the higher the ligation of the spermatic veins, the lower should be the incidence of hydrocele. This statement does not appear to be true, because the Palomo (classic or laparoscopic) technique and recently the retroperitoneoscopic approach are also aggravated by this complication. Hydrocele complicates even percutaneous sclerotherapeutic treatment, may be due to a high number of anastomoses between lymphatic and venous systems.

Our series demonstrates a great reduction in the rate of this complication; the incidence of hydrocele was 0% in all cases even if small lymphatic vessels were cut during surgery. We can conclude that very small vessels (not visible with magnification and not mapped by the vital dye) can be divided during varicocelectomy without

complications. The most important factor is the preservation of big collecting trunks that are rapidly mapped after intraparenchymal injection; from our findings this is enough to ensure a good outcome. Mapping of testicular lymphatic drainage with intraparenchymal vital dye (methylene blue) is an easy, safe, rapid and cost-free technique that virtually eliminates postoperative hydrocele, whatever the surgical approach used and also ensure better andrological outcome.

REFERENCES

1. Francesca AB, Pietro I, Pietro A, Alessandra F, Gianfranco S, Francesco A, Ciro E, Carmelo R. Laparoscopic vs open varicocelectomy in children and adolescents: review of the recent literature and meta-analysis. *JPUrol*. 2010;45:2464-69.
2. John-Paul C, Mohamed S, Alex B, Waleed E, Roman J. Dye-assisted lymphatic-sparing laparoscopic varicocelectomy in children. *JPUrol* 2011; In Press, Available online.
3. Jean W, Sherman C, Murali P, Steven F. Lymphatic Sparing Microscopic Retroperitoneal Varicocelectomy: A Preliminary Experience. *J Urol*. 2009;182:2460-63.
4. Natalya AL, Thomas JW. Surgical techniques for the management of male infertility. *Asian Journal of Andrology*. 2012;14:94-102.
5. Liang Z, Guo J, Zhang H, Yang C, Pu J, Mei H, Zheng L, Tong Q. Lymphatic Sparing Versus Lymphatic Non-Sparing Laparoscopic Varicocelectomy in Children and Adolescents: A Systematic Review and Meta-Analysis. *Eur J Pediatr Surg*. 2011;21:147-53.
6. Palomo A. Radical cure of varicocele by a new technique: preliminary report. *J Urol*. 1949;61:604-7.
7. Kass EJ & Marcol B. Results of varicocele surgery in adolescents: a comparison of techniques. *J Urol*. 1992;148:694-6.
8. Riccabona M, Oswald J, Koen M, Lusuardi L, Radmayr C, Bartsch G. Optimizing the treatment of boys with varicocele: sequential comparison of 4 techniques. *J Urol*. 2003;169:666-817.
9. Jean W, Sherman C, Murali P, Steven F. Lymphatic Sparing Microscopic Retroperitoneal Varicocelectomy: A Preliminary Experience. *J Urol*. 2009;182:2460-63.
10. Kocvara R, Dolezal J, Hampl R et al. Division of lymphatic vessels at varicocelectomy leads to testicular oedema and decline in testicular function according to the LH-RH analogue stimulation test. *Eur Urol*. 2003;43:430-5.
11. Steeno OP. Varicocele in the adolescent. In Zorngiotti AW ed. *Temperature and Environmental Effects on the Testis*. Appendix A. New York: Plenum Press. 1991:295-321.
12. Kenneth IG, Stephen AP, Carl KG, Joel DeCastro G, Rosalia M. Laparoscopic Lymphatic Sparing Varicocelectomy in Adolescents. *J Urol*. 2008;180:326-31.
13. Kocvara R, Dolezal J, Hampl R, Povysil G, Dvoracek KJ, Hill M, et al. Division of lymphatic vessels at varicocelectomy leads to testicular oedema and decline in testicular function according to the LH-RH analogue stimulation test. *Eur Urol*. 2003;43:430e5.
14. D'Alessio A, Piro E, Beretta M, Marinoni F, Abati L. Lymphatic preservation using methylene blue dye during varicocele surgery: A single-center retrospective study. *JPUrol*. 2008;4:138-40.
15. Oswald J, Korner I, Riccabona M. The use of isosulphan blue to identify lymphatic vessels in high retroperitoneal ligation of adolescent varicocele-avoiding postoperative hydrocele. *BJU Int*. 2001;87:502-4.