

ORIGINAL ARTICLE

CLINICAL TRENDS AND SURGICAL OUTCOME IN MANAGEMENT OF GASTROINTESTINAL STROMAL TUMORS

Omar Abdelraheem,¹ Magdy Khalil,¹ Afaf T Elnashar²

¹Departments of General Surgery, ²General Pathology, Faculty of Medicine, Sohag University, Egypt

Correspondence to: Magdy Khalil, Email: mgkh11@gmail.com

Abstract

Background: Gastrointestinal stromal tumors (GISTs) are the most common mesenchymal tumors of the gastrointestinal tract. Our aim in this study is to find out clinical evaluation and surgical outcome in management of these types of tumors.

Methods: 11 consecutive patients subjected to surgical treatment, diagnosed histopathologically as GISTs and enrolled in a prospective study from October 2007 to March 2011.

Results: 7 gastric and 4 small intestinal GISTs presented mainly by Gastrointestinal bleeding (36%) and abdominal pain (36%). 6 cases (55%) were discovered incidentally during laparotomy. All patients were managed surgically and confirmed by postoperative histopathologic study. Surgical resection with safety margin was done to all patients except one case with duodenal GIST was irresectable.

5 patients with poor prognostic factors and inoperable lesions required a second therapy in Oncology Unit. During the follow up period (ranged from 6-34months) 2 patients died due to progression of the disease and distant metastasis.

Conclusion: GISTs are commonly diagnosed incidentally during laparotomy and most of them presented with gastrointestinal bleeding and abdominal pain. Complete surgical resection is the mainstay of their management. Surgical treatment of incidentally discovered advanced GISTs carried very poor prognosis even with the use of postoperative neoadjuvant therapy.

Keywords: GIST; Gastrointestinal tumors; Management outcome.

INTRODUCTION

Gastrointestinal stromal tumors (GISTs) are the most common mesenchymal tumors of the gastrointestinal tract.⁽¹⁾ Historically, these were classified as leiomyomas or leiomyosarcomas because they possessed smooth muscle features when examined under light microscopy.⁽²⁾ Since the term GIST was introduced by Mazur and Clark in 1983, who demonstrated that GISTs

do not arise from smooth muscle cells, but from another mesenchymal derivative such as the progenitors of spindle and epithelioid cells.⁽³⁾

GISTs are usually kit positive, that are believed to originate from interstitial cell of Cajal, the gut pace maker of the autonomic nervous gut system, or their related stem cells.^(4,5) The incidence of GISTs in the United States is estimated to be 3000-4000 cases per

year,⁽⁶⁾ with the age of majority of the diagnosed patients being in the range of 40-80 and a median age of 60 years.⁽⁷⁾

GISTs may develop through the entire gastrointestinal tract: 50-70 % in the stomach, 25-30% in the small intestine, 5-10% in colon and rectum, < 5% in the oesophagus, the remaining may arise within the omentum or within the peritoneal layers and termed extra-gastrointestinal stromal tumors (EGISTs).⁽⁸⁾

The most common clinical presentation of these tumors is gastrointestinal bleeding (with acute hematemesis, melena, or chronic anaemia), they may cause GI obstruction, abdominal pain, weight loss or a palpable mass, otherwise they can be incidentally detected during surgery or endoscopic / radiological procedures.⁽⁹⁻¹²⁾

The strategy of GIST treatment is based on two gold standards: surgery and target molecular therapy.⁽¹³⁾ Localized GIST has historically been treated with combination of surgery and chemotherapy; however, because chemotherapy has been proven ineffective in the treatment of GIST, surgical resection is now the primary treatment for respectable tumors.⁽¹⁴⁾

The aim of surgical treatment is complete resection, avoiding tumor rupture, preferring wedge resection whenever possible; lymphadenectomy is not recommended due to the rarity of nodal metastasis.⁽¹⁵⁾

Although surgical resection is currently the standard,⁽¹⁶⁾ complete gross resection of localized GIST is associated with a 5- year survival of 48-65%.⁽¹⁷⁻¹⁹⁾ Poor survival is mainly associated with high recurrence rates which are >40% within the first 2 years following surgical resection.⁽¹⁸⁾

Prognosis is related to the size of the tumor and to the mitotic rate: tumors >10 cm or with a mitotic rate > 5 per 50high- powered fields (HPF) have a higher risk of recurrence and metastasis. Other prognostic factors are tumor location, persistence of tumor residuals within the surgical resection margins, tumor rupture, and c-kit mutation that may interfere with efficacy of target molecular therapy.⁽⁹⁻¹²⁾ Neoadjuvant target molecular therapy can be considered for patients with inoperable GISTs (unresectable, metastatic or recurrent tumors) or for downsizing the tumor before surgical resection.⁽¹⁾

The majority of GISTs with kit -mutant proteins are sensitive to agents that block kit and platelet-derived growth factor receptor (PDGFR), with a response rate that reaches almost 70% even in advanced disease;⁽²⁰⁾ however resistance to the therapy has been widely reported.⁽²¹⁾

The primary aim of this study is to find out the clinical evaluation and the surgical outcome in management of GIST patients.

PATIENTS AND METHODS

This retrospective observational study was carried out in Surgery Department at Sohag University Hospital from October 2007-to March 2011. All eligible cases had consented.

Patients in this study included 11 cases diagnosed histopathologically as GIST and subjected to surgical treatment whether operable or inoperable. They were diagnosed preoperatively via endoscopic biopsy or discovered incidentally during laparotomy.

Our patients were subjected to: complete clinical evaluation; abdominal ultrasound, CT abdomen and pelvis, endoscopy was used in some cases. Routinely postoperative block histopathological biopsy was recommended to assess the extent of safety margin and the grade of mitotic index.

As a rule, surgical treatment was recommended for all resectable tumors. Our goal in the surgical management of primary respectable GISTs was complete resection with safety margin. Excision of the tumor with negative resection margin is termed (Ro), R1 (Persistence of microscopic tumor deposits within the resection margin) and R2 (persistence of macroscopic tumor residual).⁽²²⁾

Postoperatively, patients with poor prognostic factors and inoperable cases (distant metastasis, peritoneal deposits, recurrent and irresectable tumors) were referred to Oncology Unit for target molecular therapy (imatinib mesylate).

Clinical evaluation and follow up was done to all patients every 3 month during the first year and each 6 months later on in a regular outpatient visits. The patients were evaluated clinically and by imaging studies via abdominal ultrasound and CT.

RESULTS

This retrospective study included 11 patients with GIST, 7 males (64%) and 4 females (36%), their ages ranged from 32-73 years with mean of 51 ± 4 .

The definite preoperative diagnosis was detected only in 5 patients (45%) with gastric GIST where they were evaluated clinically, CT abdomen and confirmed by endoscopic biopsy; the other 6 cases were discovered incidentally during laparotomy due to abdominal pain (3 cases), gastrointestinal obstruction (2 cases) and abdominal mass in the last case.

Tumor's localization (Table 1, Fig 1-3):

It was found that 7 patients had gastric GIST, 2 cases in the jejunum, 1 in the ileum and the last patient in the duodenum.

Table 1.Tumor's localization.

Localization	Patients(n)	(%)
Gastric	7	64
Jejunal	2	18
Ileal	1	9
Duodenal	1	9

Symptoms and clinical presentation (Table 2):

The symptoms were variable according to location of the lesion. The most common symptoms were GI bleeding, abdominal pain, gastrointestinal obstruction and a palpable mass.

Operative findings (Table 3, Figs 4,5):

Elective surgical interference was done to all cases except in 2 patients; one with intestinal obstruction (jejunal GIST) and the other with acute abdomen that was misdiagnosed as acute appendicitis (ileal GIST).

Primary resection was done to all patients except in one case with duodenal GIST that was fixed to the posterior abdominal wall and associated with peritoneal deposits (Gastrojejunostomy was done to bypass the obstruction and biopsy was taken).

Preoperative imaging studies and intraoperative clinical assessment proved the presence of distant metastasis in 3 cases (2 with liver metastasis and one with peritoneal deposits).

Histopathologic study (Table 3):

Successful primary resection with safety margin (Ro)

was found in 8 cases, while 2 cases showed persistence of microscopic tumor deposits (R1) and the remaining one was irresectable.

The mitotic index was <5/50 HPF in 6 cases; ranged from 5-10/50 HPF in 3 specimens and >10/50HPF in 2 cases.

The diameter of the studied resectable GISTs was found in gastric series ranged from 3-11cm with a mean 6.4 cm ; in jejunal GIST ranged from 6-7.5 (mean is 6.8 cm) , in ileal GIST 3.5 cm and the duodenal type was irresectable.

Follow up and outcome (Table 4):

Last update of follow up has been reported on September 2011. Two patients were lost to follow up, while the remaining 9 cases were followed up with a mean 22 months (range 6-34 months).

During the first month after operation , the early postoperative complications occurred in 4 patients, which included wound infection in 2 patients, wound dehiscence in 1 case and the last one developed prolonged ileus ; all of them improved by conservative measures. Late postoperative morbidity occurred in 2 cases with gastric GISTs that developed local recurrence, 8 and 10 months respectively after surgery, the first one died due to progression of the disease with distant metastasis.

Five patients (with unresectable, metastatic and recurrent tumors) required a second therapy in Oncology Unit Department during their follow up period.

Two cases died 7 and 10 months postoperatively, the first one showed irresectable duodenal GIST with peritoneal deposits, while the other with large gastric GIST (11cm in diameter) showed local recurrence and liver metastasis. The cause of death in both cases was due to disease progression and distant metastasis.

Table 2. Symptoms and clinical presentation.

GIST localization	Clinical presentation			
	GI bleeding	Abdominal pain	GI Obstruction	Palpable mass
Gastric	4	2	-	1
Jejunal	-	1	1	-
Ileal	-	1	-	-
Duodenal	-	-	1	-

Table 3. Operative findings and histopathologic study.

GIST localization	Operative finding			Extent of resection			Mitotic activity (/50HPF)		
	Resectable without metastasis	Resectable with metastasis	Irresectable with metastasis	RO	R1	Irresectable	<5	5-10	>10
Gastric	6	1 (liver metastasis)	-	5	2	-	4	2	1
Jejunal	1	1 (liver metastasis)	-	2	-	-	1	1	-
Ileal	1	-	-	1	-	-	1	-	-
Duodenal	-	-	1 (peritoneal metastasis)	-	-	1	-	-	1
Total	8	2	1	8	2	1	6	3	2

Table 4. Postoperative morbidity and mortality.

	Gastric GIST	Jejunal GIST	Ileal GIST	Duodenal GIST	Total No.
Wound infection	1			1	2
Wound dehiscence		1			1
Prolonged ileus			1		1
Local recurrence	2				2
Mortality	1			1	2

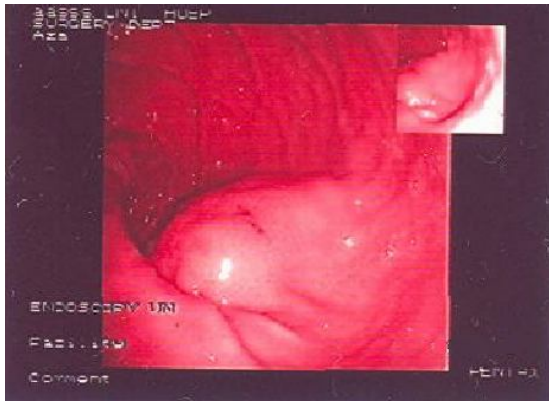


Fig 1. Upper endoscopy showing gastric GIST with intact mucosa.

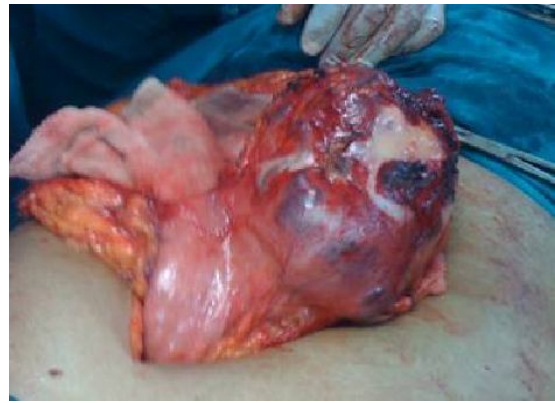

Fig 4. Gastric GIST.

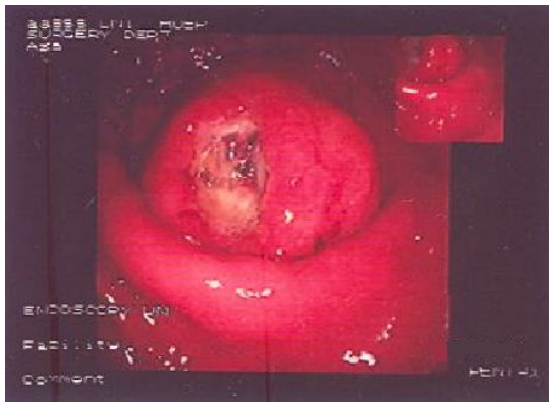


Fig 2. Upper endoscopy showing ulcerating gastric GIST.

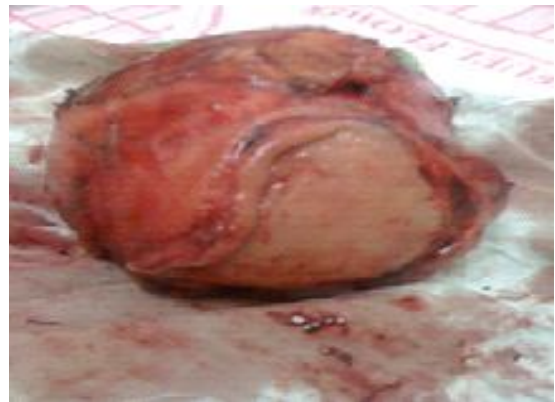

Fig 5. Resected gastric GIST (11cm in diameter).

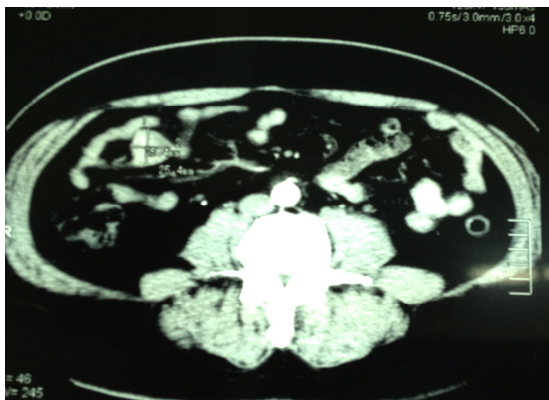

Fig 3. CT abdomen showing small intestinal GIST.

DISCUSSION

GIST is the most common mesenchymal tumor of the gastrointestinal tract. Surgery with complete removal of the tumor is the primary treatment for resectable GIST and the only chance of cure. However, recurrence after surgery is common.⁽¹⁾

GISTs usually affect both sexes equally,⁽²²⁾ however we reported a mild prevalence of males, with a male: female rate of 1.75. Preoperative histological diagnosis is very uncommon; Horowitz 1995⁽²³⁾ reported 50% of success rate, higher if obtained with ultrasound endoscopy, however percutaneous biopsy is not recommended due to high dissemination risk.

In this literature, the definite preoperative histological diagnosis was detected in 5 patients with gastric GIST, only 45% via diagnostic upper endoscopic biopsy and the remaining cases diagnosed incidentally due to different aetiological findings that necessitating laparotomy.

Gastrointestinal bleeding and abdominal pain were the commonest symptoms in our series and this is in agreement with many other studies.⁽²⁴⁻³⁰⁾

In this study, it is noticed that the 4 cases with small intestinal GIST, 2 of them (50%) had acute symptoms and underwent urgent laparotomy and this is consistent with other studies which stated that small intestinal GIST usually discovered incidentally during urgent laparotomy.⁽²⁸⁻³¹⁾

During the follow up period (ranged from 6-34 months) 2 patients were lost to follow up, while the remaining cases (9 patients), 2 of them (22%) died in the postoperative 7 and 10 months respectively due to progression of the disease and distant metastasis. These 2 cases presented with acute symptoms (acute abdominal pain and massive upper gastrointestinal bleeding), while the remaining cases especially those with elective surgical resection showed good postoperative outcome and this is consistent with the study of Salvator et al; 2011⁽²²⁾ who concluded that patients presented with acute abdomen reported a worse survival rate if compared with other presentations, but the symptoms cannot be considered per se predictive of survival and outcome. They added that patients presenting with acute abdomen were those more likely to have more than one, unfavorable prognostic factor.

The mortality rate in our study is 22%; it is fairly considered to be acceptable as compared with other many studies that reported the 5 year survival rate is (48-65%)⁽¹⁷⁻¹⁹⁾ after complete gross resection of localized GIST, considering our recorded results performed in a small number of investigated cases and during less follow up period.

This variation in the results of the surgical outcome may

be due to the difference in patient selection criteria, tumor size and location, extent of mitotic activity, in addition to the facilities of early diagnosis.

In conclusion GISTs are commonly diagnosed incidentally during laparotomy due to various aetiological findings. Most GISTs are presented with gastrointestinal bleeding and abdominal pain. Surgical resection with safety margin is still the mainstay of management of GIST. Surgical treatment of incidentally discovered advanced GISTs presenting with unresectable primary lesion or metastasis carried very poor prognosis even with the use of postoperative neoadjuvant therapy.

REFERENCES

1. Deshaies, Jovenel C, Niraj JG, Yixing J, Harold AH, Eric TK, et al. Gastrointestinal stromal tumor (GIST) recurrence following surgery: review of the clinical utility of imatinib treatment. *Therapeutics and Clinical Risk Management*. 2010;6:453-58.
2. Kindblom LG, Remotti HE, Aldenborg F, Meis-Kindblom JM. Gastrointestinal pacemaker cell tumor (GIPACT): gastrointestinal stromal tumors show phenotypic characteristics of the interstitial cells of Cajal. *Am. J Pathol*. 1998;152:1259-69.
3. Mazur MT, Clark HB. Gastric stromal tumors. Reappraisal of histogenesis. *Am J Surg Pathol*. 1983;7:507-19.
4. Miettinen M, Lasota J. Gastrointestinal Stromal Tumors. Review on morphology, molecular pathology, prognosis, and differential diagnosis. *Arch Pathol Lab Med*. 2006;130:1466-78.
5. Miettinen M, Lasota J. Gastrointestinal Stromal Tumors - definition, clinical, histological, immunohistochemical, and molecular genetic features and differential diagnosis. *Virchows Arch*. 2001;438:1-12.
6. Gold JS, DeMatteo RP. Combined surgical and molecular therapy: the gastrointestinal stromal tumor model. *Ann Surg*. 2006;244:176-84.
7. Van der Zwan SM, DeMatteo RP. Gastrointestinal stromal tumor: 5 years later. *Cancer*. 2005;104:1781-8.
8. Miettinen M, Majidi M, Lasota J. Pathology and diagnostic criteria of gastrointestinal stromal tumors (GISTs): A review. *Eur J Cancer*. 2002;38:S39-51.
9. Casali PG, Jost L, Reichardt P, Schlemmer M, Blay JY, ESMO Guidelines Working Group. Gastrointestinal stromal tumors: ESMO clinical recommendations for diagnosis, treatment and follow-up. *Ann Oncol*. 2008;19:35-38.
10. Joensuu H, Roberts PJ, Sarlomo-Rikala M, Andersson LC, Tervahartiala P, Tuveson D, et al. Effect of the tyrosine kinase inhibitor STI 571 in a patient with a metastatic gastrointestinal stromal tumor. *N Engl J Med*. 2001;344:1052-6.

11. Rutkowski P, Symonides M, Zdzienicki M, Siedlecki JA. Developments in targeted therapy of advanced gastrointestinal stromal tumors. *Recent Pat Anticancer Drug Discov.* 2008;3:88-99.
12. Joensuu H. Risk stratification of patients diagnosed with gastrointestinal stromal tumor. *Hum. Pathol.* 2008;39:1411-9.
13. Rubin JL, Myrlene S, Douglas CA, John C, Vamsi B, Leonardo S. Epidemiology, survival, and costs of localized gastrointestinal stromal tumors. *International Journal of General Medicine.* 2011;4:121-30.
14. Demetri GD. Identification and treatment of chemoresistant inoperable or metastatic GIST: experience with the selective tyrosine kinase inhibitor imatinib mesylate (STI571). *Eur J Cancer.* 2002;38:S52-9.
15. Zhang L, Smyrki TC, Young WF, Stratakis CA, Carney JA. Gastrointestinal stromal tumors in Carney triad are different clinically, pathologically, and behaviorally from sporadic gastric gastrointestinal stromal tumors: findings in 104 cases. *Am J Surg Pathol.* 2010;34:53-64.
16. NCCN.org [homepage on the Internet]. The NCCN Clinical Practice Guidelines in Oncology™ Soft Tissue Carcinoma (Version 1.2009). National Comprehensive Cancer Network, Inc. Available from: <http://www.NCCN.org>. Accessed. 2009.
17. Ng EH, Pollock RE, Munsell MF, Atkinson EN, Romsdahl MM. Prognostic factors influencing survival in gastrointestinal leiomyosarcomas. Implications for surgical management and staging. *Ann Surg.* 1992;215:68-77.
18. DeMatteo RP, Lewis JJ, Leung D, Mudan SS, Woodruff JM, Brennan MF. Two hundred gastrointestinal stromal tumors: recurrence patterns and prognostic factors for survival. *Ann Surg.* 2000;231:51-8.
19. Shiu MH, Farr GH, Papachristou DN, Hajdu SI. Myosarcomas of the stomach: natural history, prognostic factors and management. *Cancer.* 1982;49:177-87.
20. Wardelmann E, Merkelbach-Bruse S, Pauls K, Thomas N, Schildhaus HU, Heinicke T, et al. Polyclonal evolution of multiple secondary KIT mutations in gastrointestinal stromal tumors under treatment with imatinib mesylate. *Clin Can Res.* 2006;12:1743-9.
21. Bulusu VR, Jephcott CR, Fawcett S, Cook N, Hatcher H, Moyle P, et al. RECIST and Choi criteria for response assessment (RA) in patients with inoperable and metastatic gastrointestinal stromal tumors (GISTs) on imatinib mesylate. Cambridge GIST study group experience. *J Clin Oncol ASCO MEETING ABSTRACTS.* 2007;25:10019.
22. Salvatore C, Laura L, Niccolò P, Elsa I, Emanuela P, Adriana R, et al. Gastrointestinal stromal tumors: correlation between symptoms at presentation, tumor location and prognostic factors in 47 consecutive patients. *World Journal of Surgical Oncology.* 2011;9:13.
23. Horowitz J, Spellman JE, Driscoll DL, Velez AF, Karakousis CP. An institutional review of sarcomas of the large and small intestine. *J Am Coll Surg.* 1995;180:465-71.
24. Pierie JP, Choudry U, Muzikansky A, Yeap BY, Souba WW, Ott MJ. The effect of surgery and grade on outcome of gastrointestinal stromal tumors. *Arch Surg.* 2001;136:383-9.
25. Darnell A, Dalmau E, Pericay C, Musulén E, Martín J, Puig J, et al. Gastrointestinal stromal tumors. *Abdom. Imaging.* 2006;31:387-99.
26. Aparicio T, Boige V, Sabourin JC, Crenn P, Ducreux M, Le Cesne A, et al. Prognostic factors after surgery of primary resectable gastrointestinal stromal tumours. *Eur J Surg Oncol.* 2004;30:1098-103.
27. Rajappa S, Muppavarapu KM, Uppin S, Digumarti R. Gastrointestinal stromal tumors. A single institution experience of 50 cases. *Indian J Gastroenterol.* 2007;26:225-9.
28. Tryggvason G, Gislason HG, Magnusson MK, Jónasson JG. Gastrointestinal stromal tumors in Iceland, 1990-2003: the Icelandic GIST study, a population-based incidence and pathologic risk stratification study. *Int J Cancer.* 2005;117:289-93.
29. Goh BK, Chow PK, Yap WM, Kesavan SM, Song IC, Paul PG, et al. Which is the optimal risk stratification system for surgically treated localized primary GIST? Comparison of three contemporary prognostic criteria in 171 tumors and a proposal for a modified Armed Forces Institute of Pathology risk criteria. *Ann Surg Oncol.* 2008;15:2153-63.
30. Ahmed I, Welch NT, Parsons SL. Gastrointestinal stromal tumours (GIST) -17 years' experience from Mid Trent Region (United Kingdom). *Eur J Surg Oncol.* 2008;34:445-9.
31. Hassan I, You YN, Shyyan R, Dozois EJ, Smyrk TC, Okuno SH, et al. Surgically managed gastrointestinal stromal tumors: a comparative and prognostic analysis. *Ann Surg. Oncol.* 2008;15:52-9.