

Left Ventricular Dyssynchrony Associated with Myocardial Stunning in Acute ST Elevation Myocardial Infarction: Gated Single Photon Emission Computed Tomography Study

Walid Mohamed Ahmed Ahmed

OBJECTIVE

Explore relationship between stunned myocardium, LV dilatation and LV dyssynchrony in post-STEMI settings and role of revascularization

METHODS AND RESULTS

Acute STEMI patients, eligible for primary PCI. Gated SPECT examination, shortly following successful primary PCI and 5-7 days later, to document temporal changes in left ventricular (LV) functional parameters and dyssynchrony indices. Sixty patients were recruited. Paired comparison showed significant improvement in LV functional and dyssynchrony parameters, following primary PCI; LVED 131.7 ± 87.6 to 113.4 ± 61.8 , $P (<0.001)$; LVES 88.8 ± 80.5 to 72.8 ± 57.9 , $P (0.001)$; histogram BW 79.2 ± 54.4 to 67.4 ± 48.2 , $P (0.012)$; histogram SD 21.6 ± 15.2 to 17.7 ± 13.2 , $P(0.004)$. Multivariate regression analysis showed that that LV dyssynchrony was closely related to LV stunning (OR -0.40 CI 95% (-0.741) – (-0.145), $P 0.004$, adjusted $R^2 0.492$) and LV dilatation (OR 0.44 CI 95% 0.975 – 3.663, $P 0.001$, adjusted $R^2 0.517$). An improvement of LV dyssynchrony was closely related to the recovery of dilated LV state; (Adjusted $R^2 0.57$; OR 0.583; CI 95% 0.252-0.534; $P<0.001$).

CONCLUSION

Successful primary PCI promoted partial recovery of LV function and dilated dimensions, along the short-term in-hospital stay, which was accompanied with substantial improvement in LV dyssynchrony parameters. Left ventricular dyssynchrony is closely associated with dilated and stunned LV conditions.

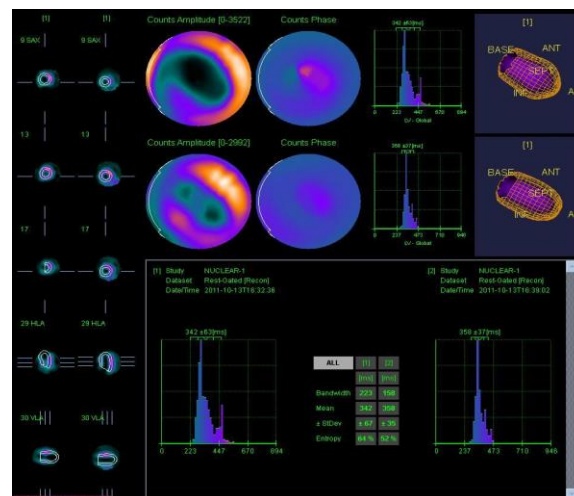


Figure1. Left ventricular Gated SPECT phase analysis of patient, presenting with anterior STEMI. His phase analysis show marked decrease in count amplitudes affecting mainly apex, the anterior wall and septum. First

set of images showed histogram BW: 223.0 ms (84.8°) and histogram SD: 67.0 ms (25.5°).

Second set of images showed histogram BW: 158.0 ms (60.1°) and histogram SD: 35.0 ms (13.3°). R-R 946 ms (360°). Anterior STEMI data showed increased dispersion of dyssynchrony parameters, denoting dyssynchronous LV contractions. This improved partially in the coming days, following primary PCI.