

EFFECT OF ADD SOME AROMATIC PLANTS OIL TO FRYING OIL ON PHYSIOLOGICAL CHANGES OF INTERNAL RATS ORGANS

Dr. Gehan Ibrahim Abd El-Wahab¹

Nutrition and Food Sci. Dept., Fac. Specific Education,
Ain Shams Univ., Cairo, Egypt

Prof. Dr. Ibrahim Mohamed Hassan²

Professor of Food Sci. and Technol., Fac. Agric., Ain
Shams Univ., Egypt

Prof. Dr. Ekbal Mahmoud Mohamed³

Professor of Food Sci. Dept., Fac. Specific Education,
Ain Shams Univ., Egypt

Prof. Dr. Adel Mohamed Bakeer⁴

Professor of Pathol., Fac. Vet. Med., Cairo Univ., Egypt

Prof. Dr. Akila Saleh Hamza⁵

Head Research Regional Center for Food and Feed,
Agric. Res. Cent., Giza, Egypt

Ahmed Zaki Amin Hassona⁶

Researcher Assistant of Regional Cent. for Food and Feed, Agric. Res. Cent., Giza,
Egypt



المجلة العلمية المحكمة لدراسات وبحوث التربية النوعية

المجلد الثاني - العدد الأول - مسلسل العدد (٣) - يناير ٢٠١٦

رقم الإيداع بدار الكتب ٢٤٢٧٤ لسنة ٢٠١٦

ISSN-Print: 2356-8690 ISSN-Online: 2356-8690

موقع المجلة عبر بنك المعرفة المصري <https://jsezu.journals.ekb.eg>

JSROSE@foe.zu.edu.eg

البريد الإلكتروني للمجلة E-mail

EFFECT OF ADD SOME AROMATIC PLANTS OIL TO FRYING OIL ON PHYSIOLOGICAL CHANGES OF INTERNAL RATS ORGANS

Dr. Gehan Ibrahim Abd El-Wahab¹, Prof. Dr. Ibrahim Mohamed Hassan², Prof. Dr. Ekbal Mahmoud Mohamed³, Prof. Dr. Adel Mohamed Bakeer⁴, Prof. Dr. Akila Saleh Hamza⁵ and Ahmed Zaki Amin Hassona⁶

1. Nutrition and Food Sci. Dept., Fac. Specific Education, Ain Shams Univ., Cairo, Egypt
2. Professor of Food Sci. and Technol., Fac. Agric., Ain Shams Univ., Egypt
3. Professor of Food Sci. Dept., Fac. Specific Education, Ain Shams Univ., Egypt
4. Professor of Pathol., Fac. Vet. Med., Cairo Univ., Egypt
5. Head Research Regional Center for Food and Feed, Agric. Res. Cent., Giza, Egypt
6. Researcher Assistant of Regional Cent. for Food and Feed, Agric. Res. Cent., Giza, Egypt.

Abstract:

The present study was carried out to investigating the effect of feeding rats on a balanced diet containing 10% of different oils (exposed to a certain number of fryings) on histological alterations occur in liver, kidney and heart organs. The different suggested treatments that carried out in this investigation could be summarized with their abbreviations as follows:

Treatment (T), Control Without any additives, Palm olein (PO), T1 PO+ 0.2% rosemary extracted (RE), T2 PO+ 0.2% Sage extracted (SE), T3 PO+ 0.2% Basil extracted (BE).

T4 PO+0.2% Butylated hydroxy toluene (BHT). The palm olein was heated to 60°C before addition of oil extracts (0.2%) rosemary; sage or basil then stirred to ensure that it was completely dissolved. BHT-containing palm olein (0.02%) and control samples (without any antioxidant) were used as positive and negative control. All frying oil samples were heated at frying temperature in about 2 minutes to elevate temperature from 25 to 180°C, followed by addition of potato chips at a rate of 400 g in 5 liters frying oil for 21/2 minutes to complete frying process in the 1st cycle of frying. The 2nd (heating and cooling) cycle of frying process was carried out after 1/2 min. When the frying oil temprature raised again from about 170 to 180°C and potato chips was added at a rate of 400 g. This process was repeated 10 times at the 1st day

of the experiment. The experimental ended after 50 frying processes at the 5th day. Samples were withdrawn at 0 time (60°C) then after 10, 30 and 50 frying processes at the 5th day. Samples size was 250ml for biological assay. Results showed that livers of rats fed on diet containing palm oil only used in zero time showed congestion of central vein. While, livers of rats fed on diet containing palm oil only used in 10 times showed hepatocellular necrosis and periductal mononuclear cellular infiltration. Revealed that the livers of rats fed on diet containing palm oil only used in 30 times had pronounced periductal mononuclear cellular infiltration. More pronounced alterations were observed in the livers of rats fed on diet containing palm oil only used in 50 times fibrosis and periductal monocellular infiltration were noticed. The kidneys of rats fed on used palm oil only had also shown significant changes. The livers of rats fed on diet containing palm oil and rosemary only used in 30 times revealed slight vacuolation of hepatocytes. While, the livers of rats fed on diet containing palm oil and rosemary only used in 50 times showed less pronounced periductal fibrosis. Both Sag and basil natural antioxidants administration with palm oil during different times of frying (zero, 10, 30; 50 times) have improved the morphological appearance of hepatocytes but to lesser degree than rosemary. The artificial antioxidants (BHT) did improve also the morphological changes. Rosemary added to palm oil used in zero and 10 times did improve the morphological appearance of both glomeruli, tubules, and interstitial tissue. Both Sag and basil natural antioxidants administration with palm oil during different times of frying (zero, 10, 30; 50 times) have improved the morphological appearance of the kidneys

Introduction:

Controlling frying oils and fats all over the world are still unsatisfactory. Most legislations and regulations in many countries only ensure that fats and oils used in food service establishments are obtained from unapproved source and are not adulterated. (Carmen et al., 2000)

Deep-fat frying may be defined as the process of cooking foods by immersing them in an edible oil or fat maintained at a temperature of about 150-200°C (Yamsaengsung & Moreira 2002).

A number of reactions occur in the frying oil when foods are fried causing oxidative and hydrolytic degradation as well as polymerization

of the oil. The question is whether these oxidized and polymerized materials in frying oil might cause adverse effects when consumed by human beings. The extent of these reactions depends on the frying conditions, principally temperature, duration, moisture content in the fried product, kind of food being fried and aeration involved (Komoda *et al.*, 2005).

In some countries, such as China and USA, oils and fats manufacturers normally treat the refined oils with antioxidants to retard the undesirable changes during storage and frying operations and, in eventuality, to prolong the shelf-life of the fried products. It is believed that antioxidants protect the fat from oxidation during the time that the oil is exposed to high temperature (Augustin & Berry 1983a).

Several European countries have specific regulations for frying fats and oils, as well as procedures and guidelines are particularly important for the most EEC.

The present study was carried out to investigating the effect of feeding rats on a balanced diet containing 10% of different oils (exposed to a certain number of fryings) on histological alterations occur in liver and kidney organs.

Materials and Methods

1. Essential oils:

Essential oils of sage (*Salvia officinalis*), basil (*Ocimum basilicum*) and rosemary (*Rosmarinus officinalis*) were obtained from unit of pressing and extracting natural oils, National Research Centre, Giza, Egypt.

2. Potato: From Local markets

3. Palm Oil Oils:

Refined bleached and deodorized palm olein free from additives was kindly supplied from Arma Food Industry Company, 10th Ramadan City, Cairo Egypt.

4. Chemicals:

All solvents and chemicals were used either analytical or of analytical grade unless otherwise specified. Acetic acid –isooctane-potassium

iodide-sodium thiosulphat and starch were obtained from Sigma-Aldrich GmbH, Steinheim.

5. Treatments:

The different suggested treatments that carried out in this investigation could be summarized with their abbreviations in Table (1).

Table (1): Suggested treatments for using various antioxidants (natural and /or chemical) in frying oil.

Item	Treatment palm Olein (PO)
Control	Without any additives
T1	PO+ 0.2% rosemary essential oil (R)
T2	PO+ 0.2% Sage essential oil (S)
T3	PO+ 0.2% Basil essential oil (B)
T4	PO+ 0.02% Butylatedhydroxytoluene (BHT)

T1: Palm Olein + 0.2% Rosemary; T2: Palm Olein + 0.2% Sage; T3: Palm Olein + 0.2% Basil; T4: Palm Olein + 0.02% Butylatedhydroxytoluene

6. Preparation of palm olein to frying process:

The palm olein was heated to 60°C before addition of oil extracts (0.2%) rosemary; sage and basil then stirred to ensure that it was completely dissolved. BHT- containing palm olein (0.02%) and control samples (without any antioxidant) were used as positive and negative control, respectively.

7. Preparation of potato chips

7.1. Frying protocol

All frying oil samples were heated at frying temperature in about 2 minutes to elevate temperature from 25 to 180°C, followed by addition of potato chips at a rate of 400 g in 5 liters frying oil for 21/2 minutes to complete frying process in the 1st cycle of frying. The 2nd (heating and cooling) cycle of frying process was carried out after 1/2 min..When the frying oil temp. raised again from about (170 to 180°C) and potato chips was added at a rate of 400 g to 4970cm³ frying oil no need to oil loss

compensation due to loss of this small amount of frying oil (0.6%). This process was repeated 10 times at the 1st day of the experiment. The experimental ended after 50 frying processes at the 5th day. Samples were withdrawn at 0 time (60°C) then after 10, 30 and 50 frying processes at the 5th day.

7.2. Description of frying experiments:

Deep frying experiments were carried out simultaneously using an aluminium open fryer with a concave shape which is almost used in all frying restaurants in Egypt and mainly sold in El-Gamalyia district. This frying pan capacity was 10 litre oil and equipped with autolift aluminum basket. The oil in each fryer was filtered to remove debris using separate filters.

The same frying process was repeated three times in three consecutive weeks and withdrawn samples from each trial were mixed together to form a representative composite sample.

After frying operations, the frying products were weighed and after each 10 fryings, samples were withdrawn and stored in brown bottles in a deep freezer at -20°C until analysis.

Oil (250ml) was sampled from each frying medium to represent 0, 10, 30 and 50 frying cycles, consecutive up to 5 days, and was kept in bottles. Oil samples were flushed with slow bubbles of nitrogen free the bottom of the bottles and stored in freezer at -20°C for physical and chemical analysis. The same sample weight was also withdrawn for biological evaluation.

After frying, the chips were removed from the frying pan and sensory evaluation was conducted in the same day using all batches of potato chips (0, 10, 30 and 50 fryings). The ratio between potato weight and frying oil volume (w/v) was almost stable depending on oil loss two samples of oil,. The whole procedure was repeated consecutively for 7 days.

8. Animals:

Eighty weanling male albino rats (70-80g) were purchased from the faculty of veterinary Medicine, Cairo, University, Egypt the animals were housed individually in wire bottomed cages under standard environmental

condition of temperature ($25 \pm 2^{\circ}\text{C}$), relative humidity (55%) and 12-hours dark/ light cycle. The animals were fed adlibitum with a basal diet and water for one week then were dividide into 20 groups each of 4 rats as shown Table (2). The experiment was carried out to estimate the effect of adding rosemary and sage as natural antioxidant as well as BHT(synthetic antioxidant) on the liver, heart and kidney of rats which fed on 10, 30 and 50 times of frying oils for eight weeks NRC (1995).

Table (2): Example of a commonly used purified diet (AIN-76A) for rats.

Ingredient	Amount, g/kg diet
Calcium phosphate, dibasic (CaHPO_4)	500.00
Potassium citrate, monohydrate ($\text{K}_3\text{C}_6\text{H}_5\text{O}_7 \cdot \text{H}_2\text{O}$)	220.0
Sodium chloride	74.00
Potassium sulfate	52.00
Magnesium oxide	24.00
Ferric citrate (16-17% Fe)	6.00
Manganous carbonate (43-48% Mn)	3.50
Zinc carbonate (70% ZnO)	1.60
Chromium potassium sulfate [$\text{CrK}(\text{SO}_4)_2 \cdot 12\text{H}_2\text{O}$]	0.55
Cupric carbonate (53-55% Cu)	0.30
Potassium iodate (KIO_3)	0.01
Sodium selenite ($\text{Na}_2\text{SeO}_3 \cdot 5\text{H}_2\text{O}$)	0.01
Sucrose, finely powdered	118.03

Table (3): Vitamin premix

Nicotinic acid or nicotinamide	3.000
Calcium d-pantothenate	1.600
Pyridoxine-HCL	0.700
Thiamin-HCl	0.600
Riboflavin	0.600
Folic acid	0.200
d-Biotin	0.020
Cyanocobalamin (vitamin B12)	0.001

Retinyl palmitate or acetate (vitamin A)	+b
□-Tocopheryl acetate (vitamin E)	+c
Cholecalciferol (vitamin D3)	0.0025
Menaquinone (vitamin K)	0.005
Sucrose, finely powdere	To make <1.000g

Table (4): Scheme of treatments for using various antioxidants (natural and /or synthetic) in biological experiment.

Item	Treatment palm Olein (PO)	Groups			
		F0	F10	F30	F50
Control	Without any additives	G1 Basal Diet + F0	G2 Basal Diet + F10	G3 Basal Diet + F30	G4 Basal Diet + F50
T1	PO + 0.2% rosemary extracted (R)	G5 Basal Diet + F0 + Rosemary	G6 Basal Diet + F10+ Rosemary	G7 Basal Diet + F30 + Rosemary	G8 Basal Diet + F50 + Rosemary
T2	PO + 0.2% Sage extracted (S)	G9 Basal Diet + F0 + Sage	G10 Basal Diet + F10 + Sage	G11 Basal Diet + F30 + Sage	G12 Basal Diet + F50 + Sage
T3	PO + 0.02% Basial extracted (B)	G13 Basal Diet +F0 + Basil	G14 Basal Diet +F10 +Basil	G15 Basal Diet +F30 + Basil	G16 Basal Diet +F50 +Basil
T4	PO + 0.02% Butylated hydroxy touloine (BHT)	G17 Basal Diet +F0 + BHT	G18 Basal Diet +F0 + BHT	G19 Basal Diet +F0 + BHT	G20 Basal Diet +F0 + BHT

T1: Palm Olein + 0.2% Rosemary; T2: Palm Olein + 0.2% Sage; T3: Palm Olein + 0.2% Basil; T4: Palm Olein + 0.02% Butylated hydroxy toluene; F0: Not Frying at Zero Time; F10: No. Frying at 10 times; F30: No. Frying at 30 times; F50: No. Frying at 50 times.

9. Histopathological alterations:

Autopsy samples were taken from the liver and kidney , testes and intestine of rats in different groups and fixed in 10% formal saline for twenty four hours. Washing was done in tap water then serial dilutions of alcohol (methyl, ethyl and absolute ethyl) were used for the dehydration process. Specimens were cleared in xylene and embedded in paraffin at 56°C in hot air oven for twenty four hours. Paraffin bees wax tissue blocks were prepared for sectioning at 4 microns thickness by slide, microtome. The obtained tissue section were collected on glass slides, deparaffinized, stained by hematoxylin and eosin stain for routine examination then examination was done through the light electric microscope (Banchroft *et al.*, 1996).

10. Statistical analysis:

Each analysis was done in triplicate. The Mini TAB 14 software was used to analyze data for determining ANOVA, standard deviation and Duncan's multiple range test for significance level at 5%.

Results and Discussion:

1. Histopathological changes:

1.1. Rats fed only on palm oil only:

The main histopathological alterations in the present study were observed in order mainly in the liver and kidneys of rats fed on the frying palm oil.

1.1.1. Liver:

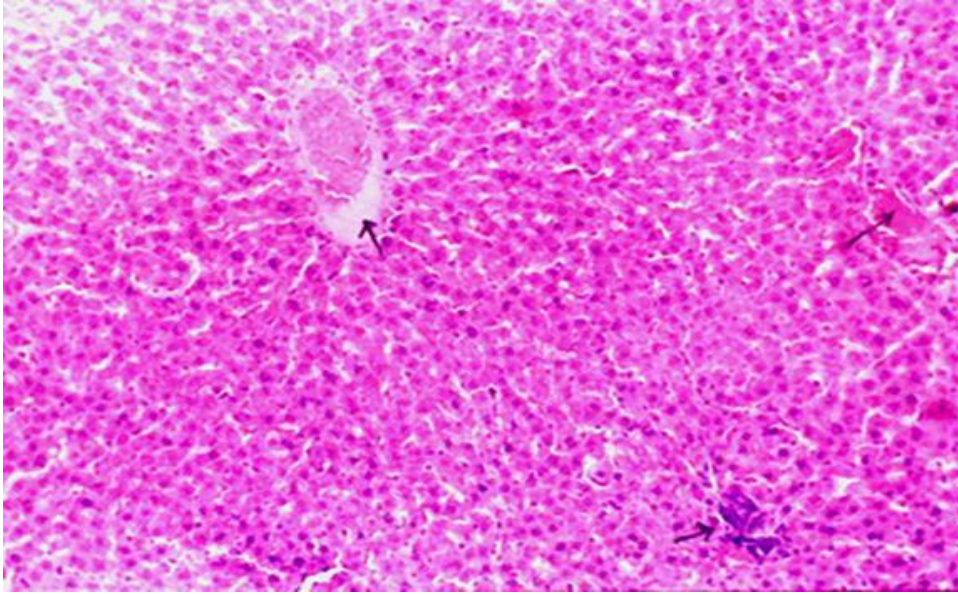


Fig. (1): Liver of rats fed on diet containing palm oil only used in zero time showing slight congestion of central vein (star). H.&E.X16.

Fig. (1) showed livers of rats fed on diet containing palm oil only used in zero time showed congestion of central vein. While, livers of rats fed on diet containing palm oil only used in 10 times showed hepatocellular necrosis and periductal mononuclear cellular infiltration (Fig. 2). Fig. (3) revealed that the livers of rats fed on diet containing palm oil only used in 30 times had pronounced periductal mononuclear cellular infiltration. More pronounced alterations were observed in the livers of rats fed on diet containing palm oil only used in 50 times; fibrosis and periductal monocellular infiltration were noticed (Fig. 4).

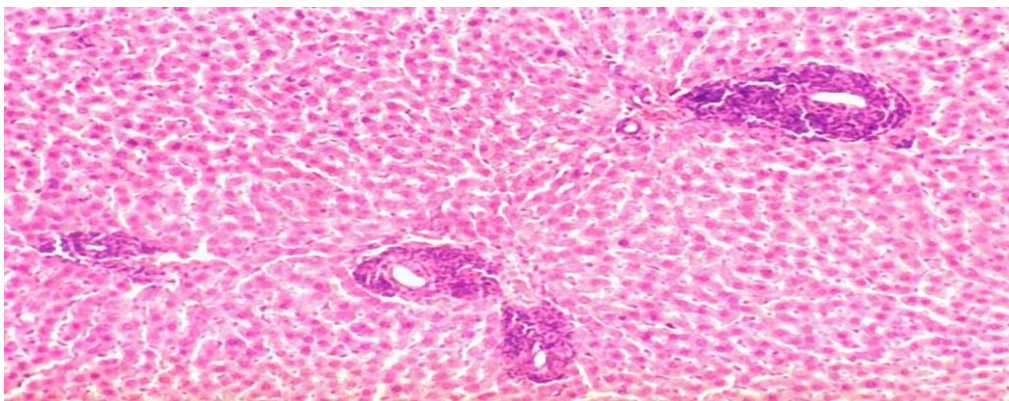


Fig. (2): Liver of rats fed on diet containing palm oil only used in 10 times showing and periductal mononuclear cellular infiltration (arrow). H.&16

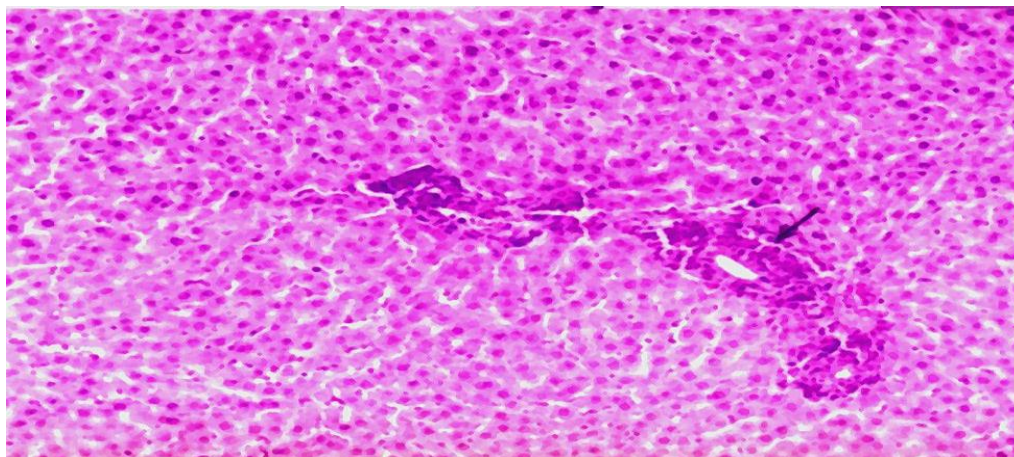


Fig. (3): Liver of rats fed on diet containing palm oil only used in 30 times showing hepatocellular necrosis (star) and more pronounced periductal mononuclear cellular infiltration (arrow).H.&E.X40.

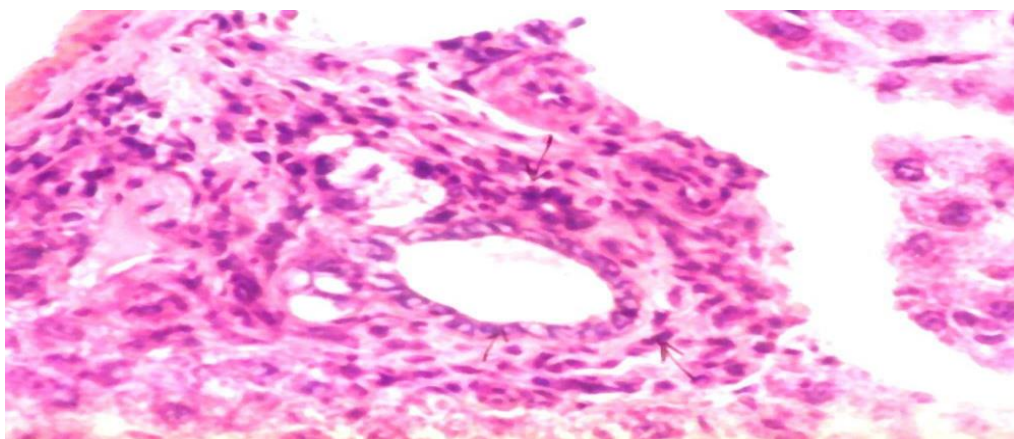


Fig. (4): Liver of rats fed on diet containing palm oil only used in 50 times showing pronounced periductal mononuclear cellular infiltration (arrow) around the bile duct (BD)and fibrosis. H.&E.X64.

1.1.2. Kidney:

The kidneys of rats fed on used palm oil only had also shown significant changes. Fig. (5) showed kidney of rats fed on diet containing

palm oil only used in zero time had and slight congestion of capillary tufts. While, the kidneys of rats fed on diet containing palm oil only used in 10 times had (Fig. 6). Fig. (7) revealed there were interstitial hemorrhage, and slight interstitial lymphocytic infiltration in the kidney of rats fed on diet containing palm oil only used in 30 times. The severe changes in the kidneys of rats fed on palm oil used were observed in 50 times. These changes were mainly of severe tubular hyaline casts and severe interstitial lymphocytic infiltration (Fig. 8).

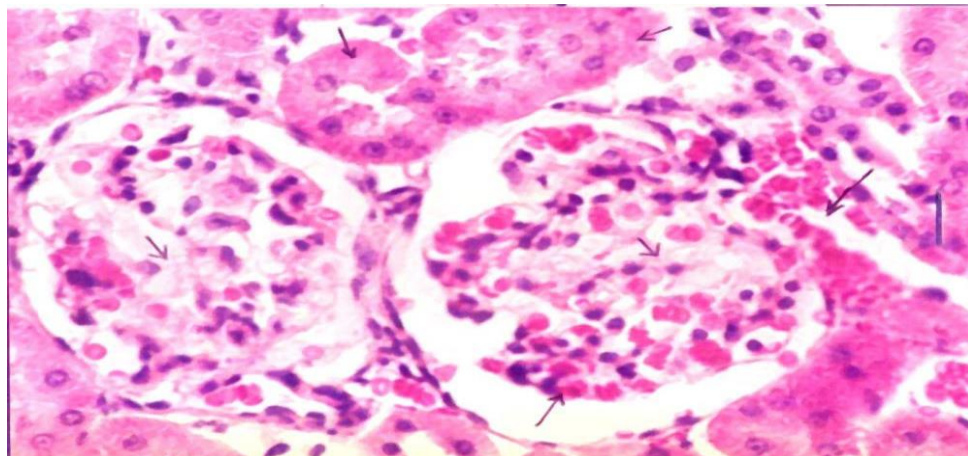


Fig. (5): Kidney of rats fed on diet containing palm oil only used in zero time showing Obliteration of tubular lumen (B) and slight hyperemia of capillary tufts with periductal haemorrhage (arrow). H. & E.X80.

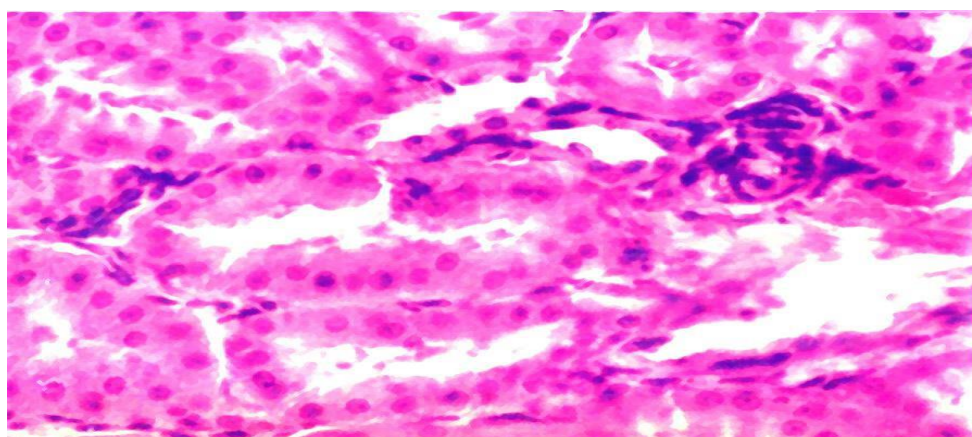


Fig. (6): Kidney of rats fed on diet containing palm oil only used in 10 times showing necrosis in the epithelial cells of both proximal (P) and distal convoluted tubules (D).H.&E.X80.

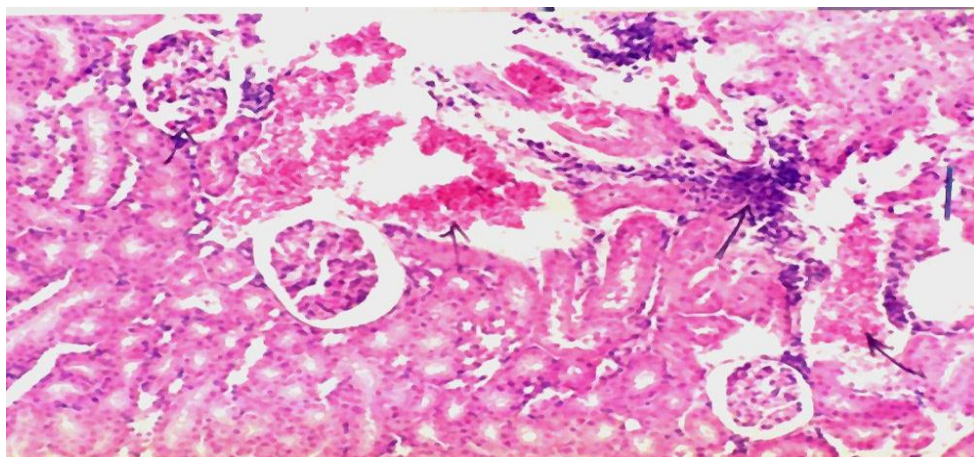


Fig. (7): Kidney of rats fed on diet containing palm oil only used in 30 times showing, interstitial hemorrhage (H) and slight fecal interstitial lymphocytic infiltration (arrow). H. & E.X40.

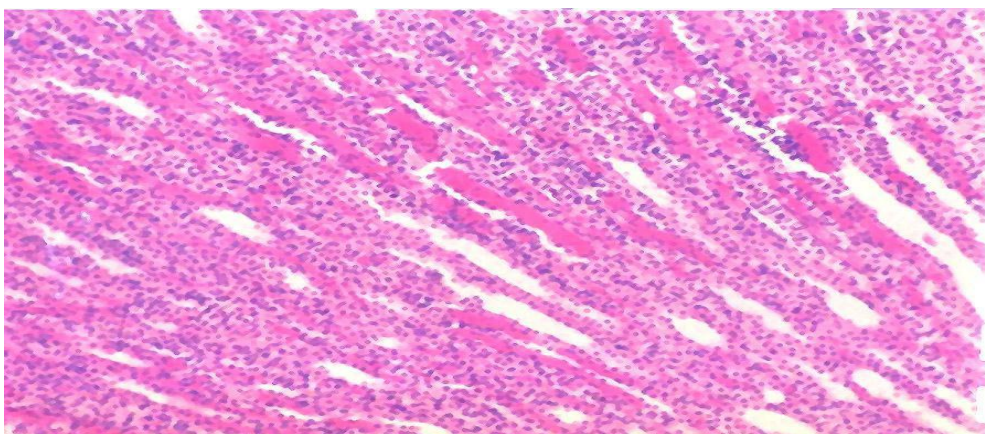


Fig. (8): Kidney of rats fed on diet containing palm oil only used in 50 times showing severe tubular hyaline casts (star) and severe interstitial lymphocytic infiltration (arrow). H. & E.X40.

1.2. Rats fed only on palm oil only and antioxidants:

1.2.1. Natural Antioxidants:

* Rats fed on palm oil and natural antioxidants including rosemary, sage and basil did improve the histopathological alterations compared to the group fed only to palm oil during the frying times at 10, 20, 30, and 50 times.

1.2.1.1. Liver:

Rosemary was the main natural antioxidant had better improvement than sage and basil. Fig. (9) showed more or less the normal architecture of hepatocytes with slight congestion of central vein in rats fed on diet containing palm oil and rosemary only used in zero; 10 times. The livers of rats fed on diet containing palm oil and rosemary only used in 30 times revealed slight vacuolation of hepatocytes (Fig. 10). While, the livers of rats fed on diet containing palm oil and rosemary only used in 50 times showed less pronounced periductal fibrosis (Fig. 11). Both Sag and basil natural antioxidants administration with palm oil during different times of frying (zero, 10, 30; 50 times) have improved the morphological appearance of hepatocytes but to lesser degree than rosemary. These improvements were manifested by absence of the vascular changes in the central veins and sinusoids. Only vacuolation of hepatocytes was observed (Figs. 4 ; 5).

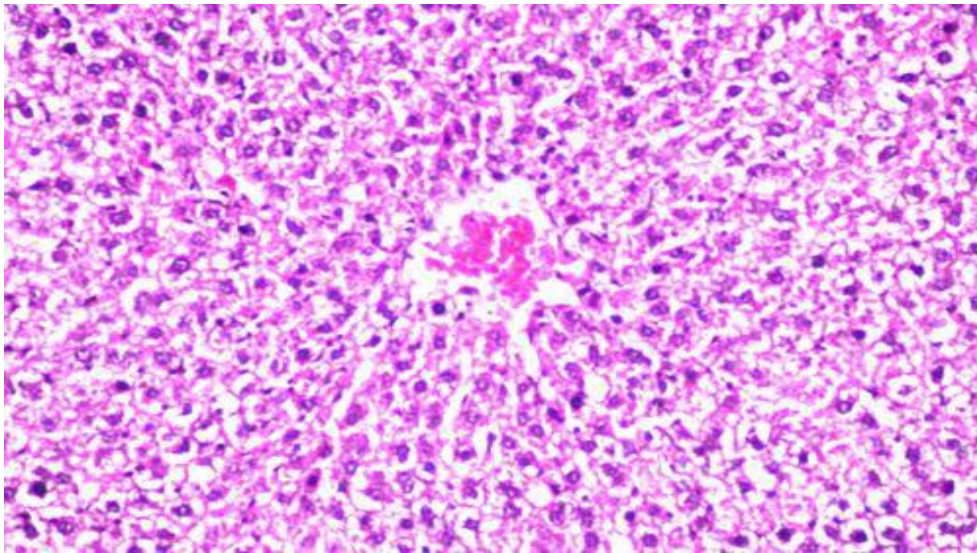


Fig. (9): Livers of rats fed on diet containing palm oil and rosemary only used in 10 times Showing mild with slight dilated central vein(cv). H & E. X 40

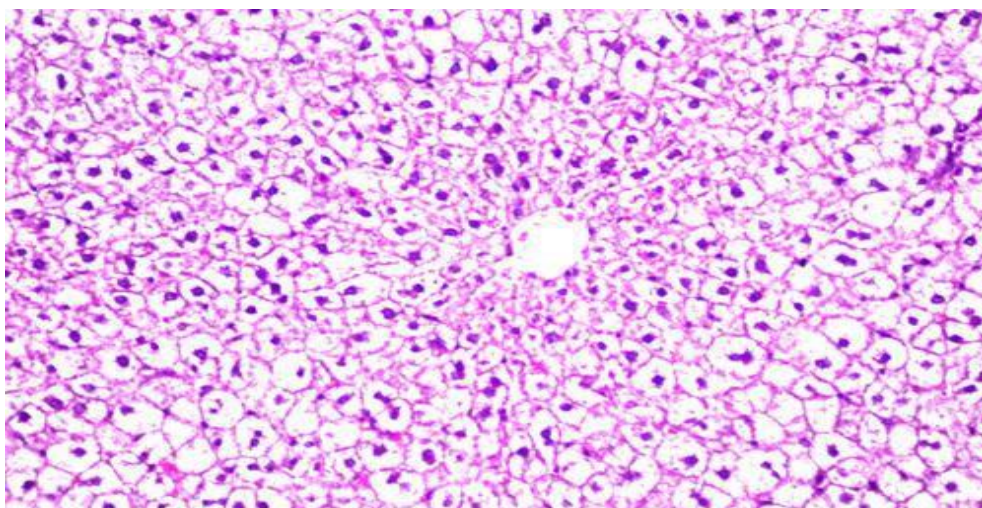


Fig. (10): Livers of rats fed on diet containing palm oil and rosemary only used in 30 times Showing vacuolation vacuolar degeneration of hepatocytes (arrow). H & E.X64

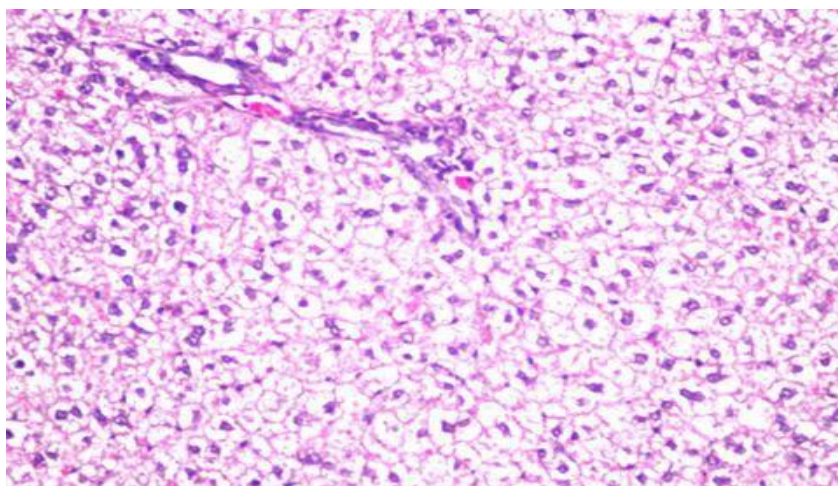


Fig. (11): Livers of rats fed on diet containing palm oil and rosemary only used in 50 times Showing less pronounced periductal fibrosis with vacuolar degeneration in hepatocytes (arrows). H&E.X64.

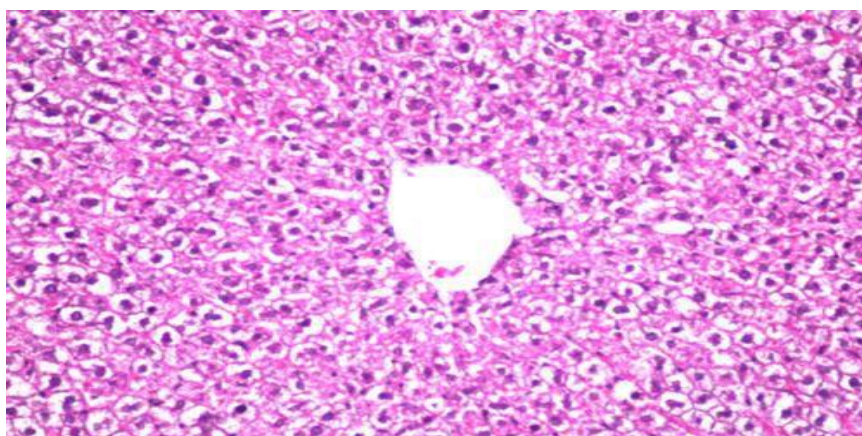


Fig. (12): Livers of rats fed on diet containing palm oil and sage at 50 times showed only slight vacuolation of hepatocytes. H&E.X40

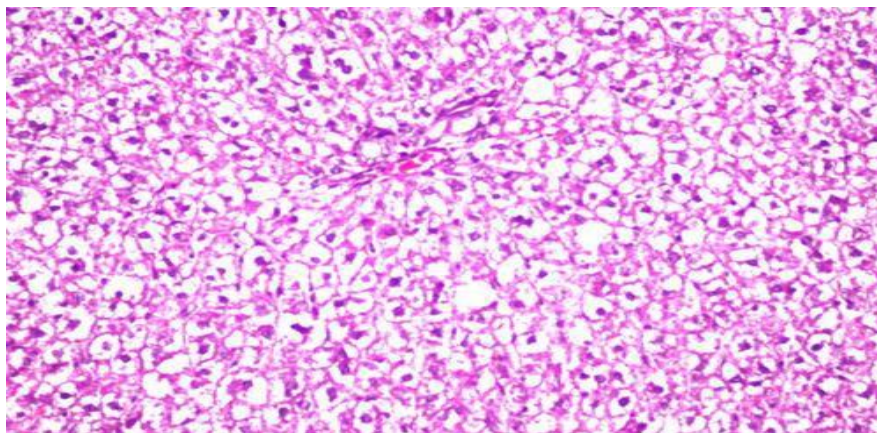


Fig. (13): Livers of rats fed on diet containing palm oil and basil at 50 times showed only vacuolation of hepatocytes (arrow). H&E.X40

1.2.2. Artificial antioxidants

The artificial antioxidants (BHT) did improve also the morphological changes, but there other severe changes were still observed. Widespread diffuse fatty change expressed by the signet-ring appearance of fat was observed. Moreover, different shapes of nuclei were observed (Figs. 14, 15; 16).

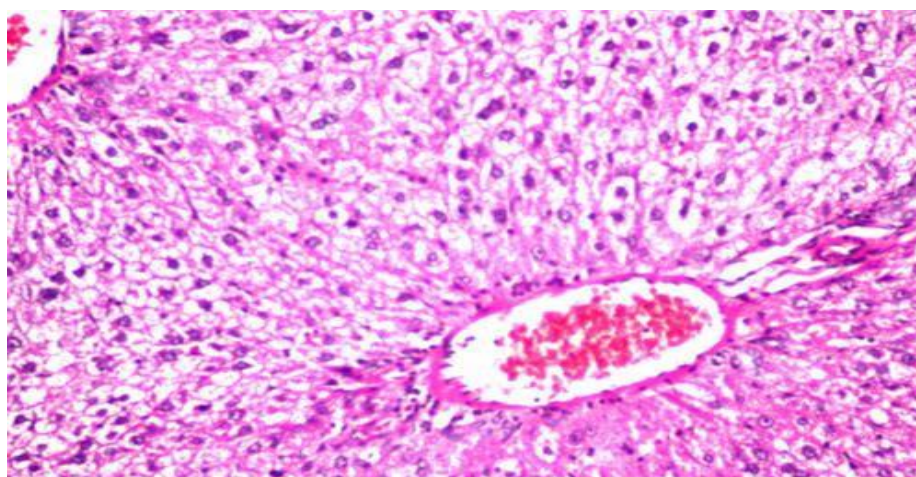


Fig. (14): Livers of rats fed on diet containing palm oil and BHT at 50 times showed pyknotic nuclei of hepatocytes (arrow). The portal vein is still engorged with blood H&E.X40

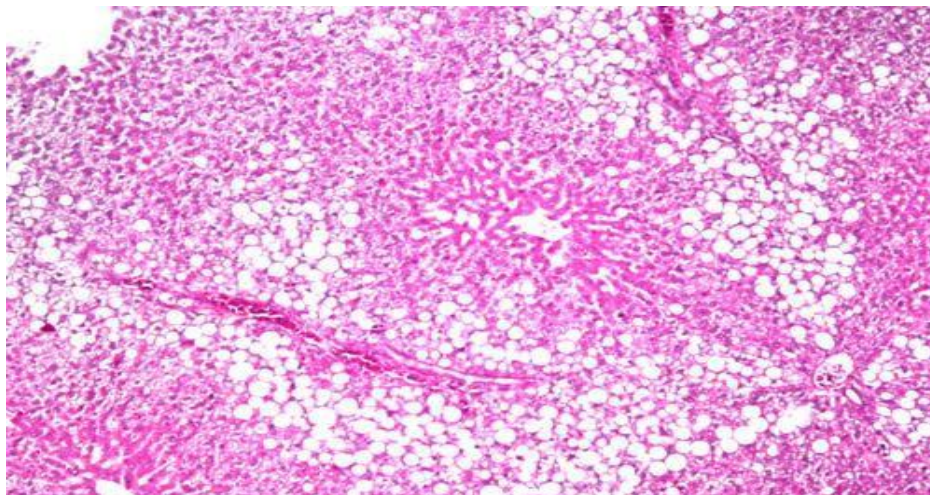


Fig. (15): Livers of rats fed on diet containing palm oil and BHT at 50 times showed diffuse fatty change (star). H&E. X16.

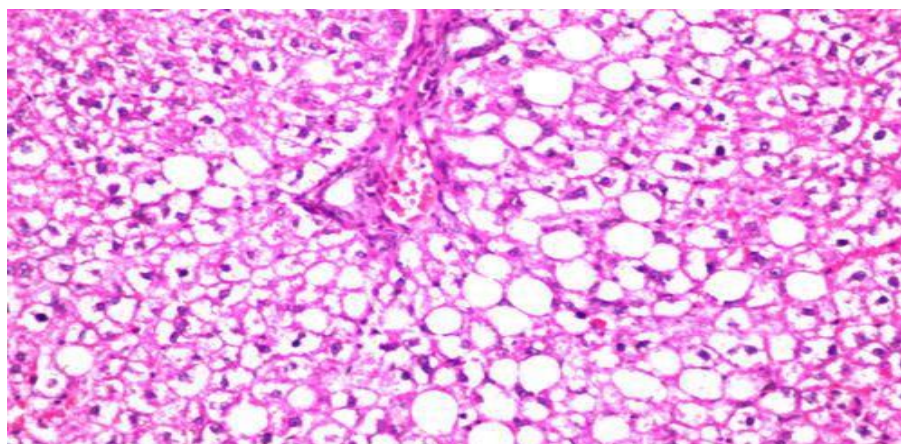


Fig. (16): Higher magnification of Fig. 17.H&E.X40

1.2.2.1. Kidney:

Rosemary added to palm oil used in zero and 10 times did improve the morphological appearance of both glomeruli, tubules, and interstitial tissue (Fig. 17). While, at 30 times, improvements have occurred except the obliteration of Bowmans space (Fig. 18). Marked improvements was

noticed at 50 times where there was no interstitial hemorrhage or inflammatory cellular reaction observed at this interval when palm oil was alone (Fig. 19).

Both Sag and basil natural antioxidants administration with palm oil during different times of frying (zero, 10, 30; 50 times) have improved the morphological appearance of the kidneys, but to lesser degree compared to rosemary. The glomeruli and tubules were more or less healthy except the obliteration of Bowmans space and the slight hyperemia of the interstitial hemorrhage (Figs. 20; 21).

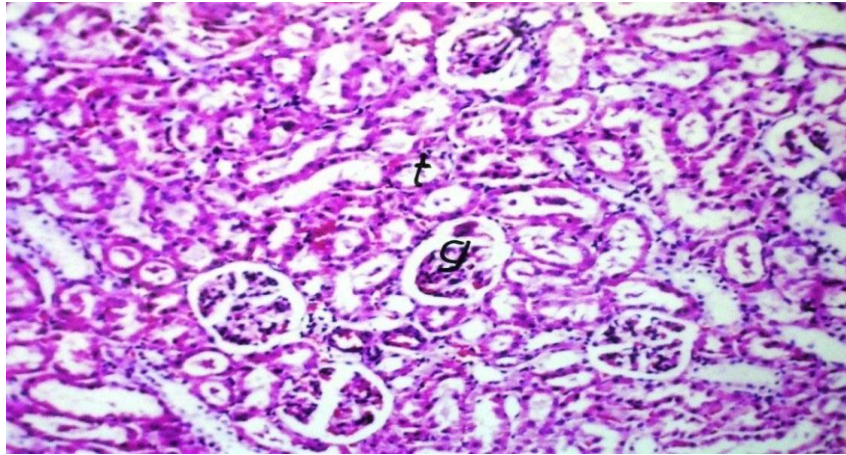


Fig. (17): Kidneys of rats fed on diet containing palm oil and rosemary only used in zero and 10times general appearance of glomeruli (g) and tubules (t) normal histological structure of the glomeruli & tubules (t). H. & E X 16

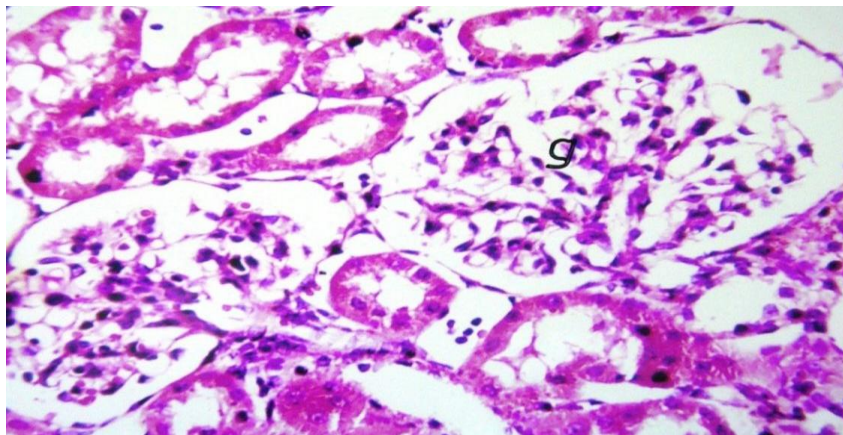


Fig. (18): Kidneys of rats fed on diet containing palm oil and rosemary only used in 30 times showed vacuolization in lining endothelium of glomerular tubules (9). H. & E X40.

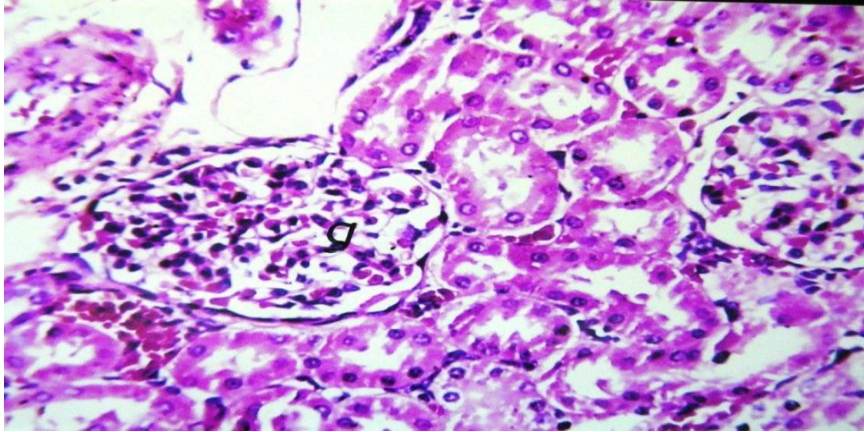


Fig. (19): Kidneys of rats fed on diet containing palm oil and rosemary only used in 50 times showed healthy glomeruli (g) and tubules (arrow) congestion of the glomerular tubules (9) H&E. X4.

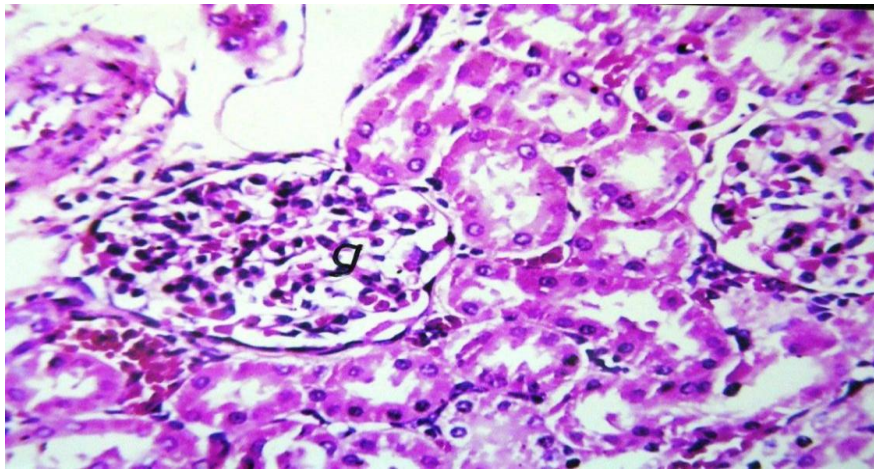


Fig. (20): Kidneys of rats fed on diet containing palm oil and sage showed re-establishment of the normal tissues, except H&E. X64.

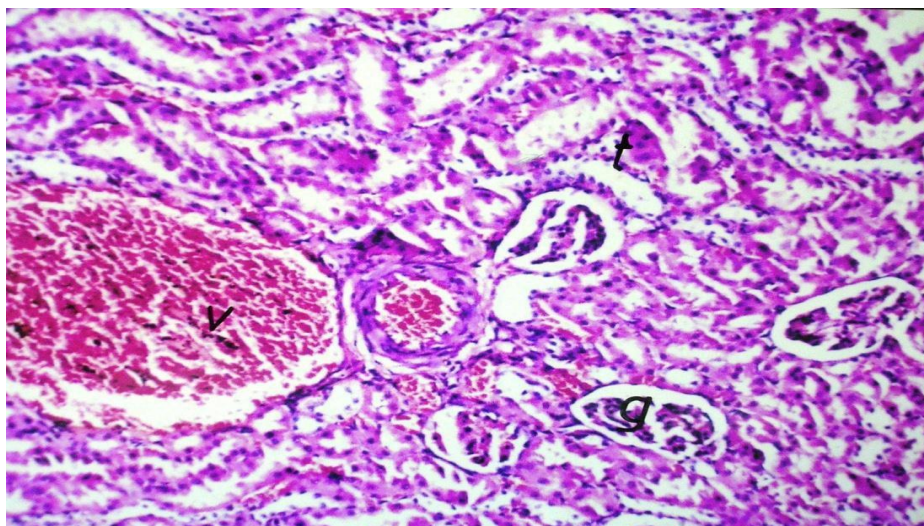


Fig. (21): Kidneys of rats fed on diet containing palm oil and basil showed re-establishment of the normal tissues, except the congestion of blood vessels (V). H&E. X40.

Artificial antioxidants:

The artificial antioxidants (BHT) did improve also the morphological changes, but there other severe changes were still observed. These changes were hemorrhage and mineralization of some tubules (Fig.22)

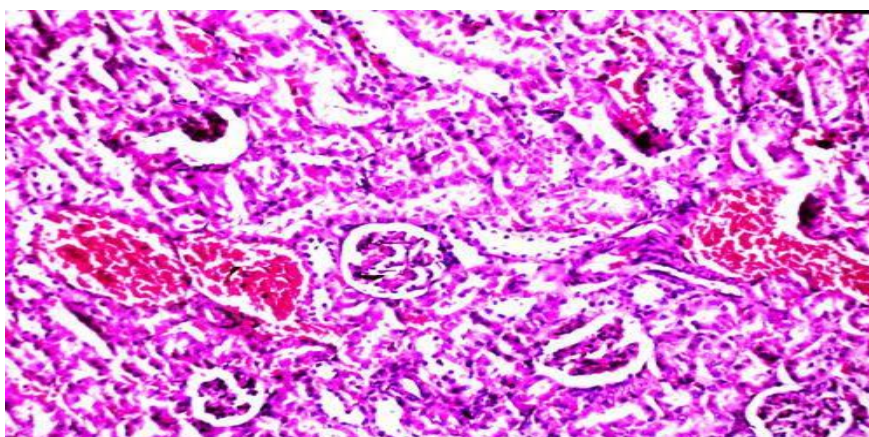


Fig. (22): Kidneys of rats fed on diet containing palm oil and BHT at zero, 10, 30 and 50 times Showed hemorrhage of the interstitial connective tissue (star) H. &E. X16.

Discussion:

The present study showed deleterious effects on the livers and kidneys of rats administered palm oil only, which has been used at zero, 10 times, 30 times, and 50 times of frying.

The liver is known to be the main target of detoxification to a wide variety of toxic compounds and / or its metabolites due to its content from the main enzyme known as Cytochrome P450. The cytochrome P450 superfamily of monooxygenases (officially abbreviated as CYP) is a large and diverse group of enzymes that catalyze the oxidation of organic substances. The substrates of CYP enzymes include metabolic intermediates such as lipids and steroidal hormones, as well as xenobiotic substances such as drugs and other toxic chemicals. CYPs are the major enzymes involved in drug metabolism and bioactivation, accounting for about 75% of the total number of different metabolic reactions (Guengerich, 2008). In the present study, the livers of rats fed on diet containing palm oil only used in zero time showing slight hyperemia of blood vessels and congestion of central vein. While, livers of rats fed on diet containing palm oil only used in 10 times showing hepatocellular necrosis and periductal mononuclear cellular infiltration. While, oil only used in 30 times had hepatocellular necrosis and more pronounced periductal mononuclear cellular infiltration. More pronounced alterations were observed in the livers of rats fed on diet containing palm oil only used in 50 times. These changes were expressed by fibrosis and periductal mono-cellular infiltration.

These results suggest that alterations in the liver increased by increasing the number of frying oil to the extent of fibrosis by 50 times of frying. The deleterious effects could be attributed to the metabolites produced by the oil frying. Also, suggests that these changes certainly will induce abnormal functions of the liver, especially those related to the enzymes of the livers, such as ALAT and ASAT.

(Gil and Pla, 2001) reported that the presence of a xenobiotic in the environment always represents a risk for living organisms. However, to talk about impregnation there is a need to detect toxicity in the organism, and the concept of intoxication is related to specific organ alterations and clinical symptoms. Moreover, the relationship between the toxic levels within the organism and the toxic response is rather complex and has a

difficult forecast because it depends on several factors, namely toxicokinetic and genetic factors. One of the methods to quantify the interaction with xenobiotics and its potential impact on living organisms, including the human being, is monitoring by the use of the so-called *biomarkers*. They can provide measures of the exposure, toxiceffect and individual susceptibility to environmental chemical compounds and may be very useful to assess and control the risk of long-term outcomes associated with exposure to xenobiotic (*i.e.*, heavy metals, halogenated hydrocarbons, pesticides).

On the other hand, addition of natural antioxidants in the present study, did improve the alterations produced by the palm oil alone at aero,10,30;50 times of frying the oil. Antioxidants are compounds capable of scavenging free radicals and consequently delaying or even preventing auto oxidation. One of the most important phenomena involved food deterioration is oxidation (Perez-Fons *et al.*, 2009). Antioxidant molecules must be potent with low quantity taking into account that changes in foodstuff aromas should be minimal (Pokorny *et al.*, 2001). Indeed antioxidant compounds cannot be added to foodstuff when still containing aromas (Areset *et al.*, 2009).

In the present study, rosemary as natural antioxidant was the better choice in improving the morphological alterations of the liver as indicated by less pronounced fibrosis. These results were confirmed by the chemical results in the present study, which showed antioxidants reduced the percentage of peroxide formation from about 65% to only 20-22% Rosemary sage Basil and BHT in order.

Bragagnolo *et al.* (2007) reported that the potential of rosemary (*Rosmarinus officinalis* L.) to inhibiting lipid oxidation in minced chicken breast and thigh muscle processed at 600 MPa for 10 min during subsequent heat treatment was investigated using electron spin resonance (ESR) spectroscopy and electrochemical detection of oxygen consumption. Chicken breast cooked at 95°C was found to have significantly higher rate of formation of free radicals and oxygen consumption rate than the samples cooked at 70°C and 120°C and this intermediate cooking temperature was used to evaluate the effect of pressure on oxidation during subsequent cooking.

Rosemary was found effective in retarding lipid oxidation since the pressurized, minced chicken breast and thigh with rosemary added showed lower rate of oxygen consumption and lower tendency of free radical formation following heat treatment than the samples without rosemary. Pressurized chicken thigh showed a higher susceptibility to oxidation than chicken breast upon subsequent heat treatment. Oxidation in pressurized and subsequently heat-treated chicken breast was from a higher tendency of radical formation concluded to be in an earlier phase of oxidation compared to thigh subjected to the same treatment

On the other hand artificial antioxidants in the present study, did slightly improve the morphological alterations of the liver, but not compared to the natural one. These results again were correlated with the chemical results obtained in the present study.

The alterations in the rat kidneys in the present study using palm oil only at frying times zero,10,30;50 times had interstitial hemorrhage and cellular infiltration, obliterations of bowman's capsule, and hyaline casts especially at 50 times of frying the oil. These results suggest that such alterations may be due to the frying process and/or its metabolites from the oxidation processes. Hyaline casts are pathognomonic feature for wide variety of toxins and toxic nephropathy Buczek (2003).

Fry *et al.* (1985) stated that the histopathology of diving seabirds exposed to crude oil by external application to the breast plumage or wings. Exposed birds exhibited hepatocellular dissociation and hemosiderosis, renal tubular necrosis, and hemolytic anemia. In the present study, more changes were presented and could be attributed to different experimental design or increase exposure frequency of frying oil.

The role of natural antioxidants in the present study in improving the kidneys morphology was similar to those observed in the livers and similar suggestions could be attributed to the improvements. While, addition of BHT to the oil in the present study had less improvement as compared to the natural ones

In conclusion, the frying oil did induce severe histopathological alterations on the livers and kidneys of rats at 10, 30, and 50 times of frying. These changes were mainly in the livers as fibrosis, and

hepatocellular necrosis. The kidneys had interstitial hemorrhage, and hyaline casts.

These changes were improved after the addition of natural antioxidants especially rosemary, followed by sagil and basil. While, BHT had less improvement compared to the natural antioxidants were observed. These results were correlated with the chemical results obtained in the present study and suggest the use of natural antioxidants as possible protective agents against the oxidative damage produced during frying processes.

Recommendations:

- 1- Frying oils may not contain more than 2% linolenic acid.
- 2- Synthetic antioxidants (BHA, BHT and gallates) and natural tocopherol concentrates are permitted in fats and oils intended for industrial use (minimum 5kg/ containers), but silicone additives are prohibited.
- 3- Kept at lower temperature and protect fat from day light or ultraviolet light when not in use.
- 4- Use suitable fryer materials; because iron and copper catalyze fat oxidation.
- 5- Use separate fryer for each fried product (Hassan, 2001); avoid risk of over heating; fat above 300°C (570°F) may cause fire.

References:

Ares, G., Barreiro, C., Deliza, R. and Gambaro. A. (2009). Alternatives to reduce the bitterness, astringency and characteristic flavour of antioxidant extracts. Food Research International, 42(7), 871-878.

Augustin, M. A. and Berry, S. K. (1983a). Effectiveness of antioxidants in refined, bleached and deodorized palm oil. Journal of the American Oil Chemists Society, 60(1), 105-107.

Bancroft, J.D.; Stevens, A. and Turner, D.R. (1996). Theory and practice of histological techniques. Fourth Ed.

177 Churchill Livingstone, New York, London, San Francisco, Tokyo.

Bragagnolo, N., Danielsen, B., and Skibsted, L.H. (2007). Rosemary as antioxidant in pressure in pressure processed chicken during subsequent cooking as evaluated by electron spin resonance spectroscopy. *Innovative Food Science and Emerging Technologies*, 8 (1): 24-29.

Buczek, B. (2003). Property changes of heated commercial edible oil treated with microporous active carbon. *Forum ware International*, 2: 25-30.

Carmen, D.; Gloria M. R. and J. Velasco (2000). Interactions between fat and food during deep frying. *J. Agric. Food Sci.*, <http://www3>.

Gil, F. and Pla, A. (2001). Biomarkers as biological indicators of xenobiotic exposure. *J. Appl. Toxicol* 21 (4), 245-255.

Guengerich, F.B. (2008). Cytochrome P450 and chemical toxicology. *Chem. Res. Toxicol.* 21, 70-83.

Hassan, I.M. (2001). Rationalizing Edible Oil Consumption in A.R.E. Fac. Agric., Ain Shames Univ., and Academy o; Scientific Resaerch and Technology.

Komoda, M.; Ishikawa, O.; Inoue, M.; Hatanaka, H.; Hattori, T.; Satoh, C.; Murokami, C.; Yamada, K. and Tsutsumi, T. (2005). Quantitative determination of polymerized triacylglycerols in frying oils and fats by size exclusion chromatography: A collaborative study. *Journal of Oleo Science*, 54 (10): 529 - 526.

NRC (1995). Nutrient Requirements of Laboratory Animals, Fourth Revised Edition (1995)

Perez.-Fons, L., Garzon, M.T. and Micol, V. (2009). Relationship between the antioxidant capacity and effect of rosemary (*Rosmarinus officinalis* L.) polyphenols on membrane phospholipid order. *Journal of Agricultural and Food Chemistry*, 58 (1): 161-171.

Pokorny, J., Yanishlieva, N. and Gordon, M. (Eds.) (2001). Antioxidants in Food. Practical Application Cambridge: Woodhead Publishing Ltd and CRC Press LLC.

Yamsaengsung, R. and Moreira, R.G. (2002). Modeling the transport phenomena and structural changes during deep fat frying. Part II: model solution & Validation. *Journal of Food Engineering*, 53 (1): 1-10.

تأثير إضافة بعض زيوت النباتات العطرية إلى زيوت التحمير على التغيرات الفسيولوجية لأعضاء الفئران الداخلية

د. جيهان إبراهيم عبدالوهاب^١ - أ.د. إبراهيم محمد حسن^٢ - أ.د. إكرام محمود محمد^٣

أ.د. عادل محمد بكير^٤ - أ.د. عقيلة صالح حمزة^٥ - أ. احمد ذكى امين^٦

١، ٣ - كلية التربية النوعية - جامعة عين شمس

٢ - كلية الزراعة - جامعة عين شمس

٤ - كلية الطب البيطرى - جامعة القاهرة

٥ - رئيس مركز الأغذية والأعلاف - مركز البحوث الزراعية

٦ - مساعد باحث قسم الأغذية والأعلاف - مركز البحوث الزراعية

الملخص :

أُجريت هذه الدراسة لتحقيق الأهداف التالية: دراسة تأثير تغذية الفئران على غذاء متوازن يحتوي على ١٠% من الزيوت المختلفة (المعرضة لعدد معين من مرات القلي) على التغيرات الهستولوجية الحادثة في الكبد والكلى.

وكانت المعاملات المقترحة في هذه الدراسة هي كالتالي:

- معاملة الكنترول (أولين النخيل بدون إضافات).

- معاملة 1 (T1) أولين النخيل + 0.2% مستخلص نبات الروزماري (حصا البان).

- معاملة 2 (T2) أولين النخيل + 0.2% مستخلص نبات الساج (المريمية).

- معاملة 3 (T3) أولين النخيل + 0.2% مستخلص نبات الريحان

- معاملة 4 (T4) أولين النخيل + 0.02% بيوتيلاتيد هيدروكسي تولوين.

تجهيز أولين النخيل لعملية القلي:

تم تسخين أولين النخيل لدرجة 60° مئوية قبل إضافة مستخلصات كل من الروزماري أو الريحان أو المريمية (بنسبة 0.2%) ثم أجرت عملية تقليب دائرية لتأكيد اكتمال ذوبان هذه

المستخلصات - واستخدمت المعاملة بدون أي إضافات كعينة ضابطة سالبة والمعاملة المضاف إليها بيوتيلاتيد هيدروكسي تولوين كعينة ضابطة موجبة.

نظام القلي:

تم تسخين عينات زيت القلي لدرجات القلي لمدة حوالي دقيقتين لرفع درجة الحرارة من 25 إلى 180 °م أعقبها إضافة رقائق البطاطس بمعدل 400 جم في 5 لتر زيت قلي لمدة 2.5 دقيقة لاكتمال عملية القلي في مرحلاتها الأولى، ثم أجريت مرحلة القلي الثانية (التبريد والتسخين) بعد نصف دقيقة، وتم إضافة رقائق البطاطس بعد رفع درجة الحرارة مرة أخرى من 170 إلى 180 °م.

وتم تكرار هذه العملية 10 مرات في اليوم الأول وانتهت التجربة في اليوم الخامس بعد إجراء 50 عملية قلي وتم تسجيل النتائج عند وقت الصفر (60 °م)، 10، 30، 50 مرة من مرات القلي وكان حجم عينة زيت القلي المأخوذة 250 مل للتقييم البيولوجي.

ويمكن تلخيص النتائج المتحصل عليها كالتالي:

أولاً: الفئران التي تغذت على أولين النخيل فقط

عند تغذية فئران التجارب على أولين النخيل لمدة شهرين حدثت بعض التغيرات الباثولوجية في الأعضاء المختلفة منها:

أ- الكبد:

- اظهر كبد الفئران التي تغذت على أولين النخيل فقط عند درجة حرارة صفر مئوي احتقاناً شديداً في الوريد الواقع في فص الكبد.

- الفئران التي تغذت على أولين النخيل المعامل حرارياً لمدة عشر مرات قلي (بطاطس شيبسي) فقد أظهرت تنقرس (موت) خلايا الكبد وتجمعات من خلايا أحادية الانوية حول القنوات المرارية.

- ظهرت تجمعات من الخلايا الالتهابية بصورة اكبر وأوضح عند تغذية فئران التجارب على أولين النخيل المعامل حرارياً لمدة ثلاثون مرة.

- الفئران التي تغذت على أولين النخيل المعامل حرارياً لمدة خمسون مرة أصيب كبد هذه الفئران بتليف لخلايا الكبد مع تجمعات التهابية شديدة.

ب- الكلى:

- كانت هناك تغيرات ملحوظة في كلى الفئران المغذاة على أولين النخيل بحدوث احتقان خفيف في الأوعية الدموية للوحدات المكونة للكلى عند صفر مؤوي.

- أما الفئران المغذاة على أولين نخيل معامل حرارياً لمدة عشر مرات فكان هناك نزيف بين الخلايا.

- أظهرت كلى الفئران المغذاة على أولين النخيل المعامل حرارياً لمدة ثلاثون مرة ترشح لخلايا الليمفوسايت.

- كان هناك تجمعات بروتينية (من طبيعة مادة الهالين) في الأنابيب الكلوية علاوة على ترشحات من خلايا الليمفوسايت للفئران المغذاة على أولين نخيل معامل حرارياً لمدة خمسون مرة.

ثانياً: الفئران التي تغذت على أولين نخيل مضافاً إليه مضادات أكسدة طبيعية

أ- الكبد:

- لوحظ أن التركيب الطبيعي للخلايا الكبدية مع حدوث احتقان خفيف في الوعاء الدموي الواقع في منتصف فص الكبد وذلك في الفئران التي تغذت على زيت النخيل مضافاً إليه مستخلص الروزماري عند صفر وعشر مرات.

- أظهرت الفئران التي تغذت على أولين النخيل مضافاً إليه الروزماري والمعامل حرارياً لمدة ثلاثون مرة فجوات في الخلايا الكبدية.

- أظهر كبد الفئران التي تغذت على أولين النخيل المضاف إليه مستخلص الروزماري والمعامل حرارياً لمدة خمسون مرة تليفاً واضحاً ملحوظاً حول القنوات المرارية.

- حسنت المريمية والريحان عند تغذية فئران التجارب على مستخلصاتها مضافة لأولين النخيل والمعامل حرارياً عند صفر، عشر، ثلاثون، خمسون مرة الشكل المورفولوجي "لخلايا الكبد" ولكن

بصورة اقل من مستخلص الروزماري وهذا التحسن عبر عنه بغياب التغيرات الدموية في الوعاء الدموي ولوحظ فقط بعض الفجوات في الخلايا الكبدية.

ب- الكلى:

- أدى إضافة مستخلص الروزماري إلى أولين النخيل عند صفر ، 10 مرات معاملة حرارية لحدوث تحسن ملحوظ في الشكل المورفولوجي ولكل مكونات الكلى (الأنابيب الكلوية - النسيج ما بين الأنابيب والوحدة الأساسية للكلى).

- كان التحسن واضحاً أيضاً عند التغذية على أولين النخيل المضاف إليه مستخلص الروزماري المعامل حرارياً ثلاثون مرة ما عدا اتساع فراغ (Bowmans).

- لوحظ تحسن ملحوظ عند التغذية على أولين النخيل المضاف إليه مستخلص الروزماري والمعامل حرارياً لمدة خمسون مرة حيث لم يستدل على نزيف ما بين الخلايا أو أي دلالة على وجود خلايا التهابية بالمقارنة باستخدام زيت النخيل فقط.

ثالثاً: الفئران التي تغذت على أولين نخيل مضافاً إليه مضادات أكسدة صناعية (BHT)

كانت أكثر الأعراض وضوحاً على الكبد فعلى الرغم من تحسن حالة لنسيج المورفولوجي إلا انه كان هناك تغيرات متمثلة في ترشحات دهنية واسعة في الكبد علاوة على ظهور أشكال مختلفة من الانوية مضافاً إليه (BHT) كمضاد كسدة صناعي عند معاملة الزيت حرارياً لمدة (صفر ، 10، 30، 50 مرة).