

Combining different treatment modalities in management of post acne scarring

*Yasser Abdallah Aboelatta, MD, MRCS;
Mohammed Mahmoud Abdelaal, MD, ABLs;
Nada Abdelsatar Bersy, MD*

*Department of Plastic and Reconstructive Surgery, Ain Shams University,
Cairo, Egypt.*

Abstract

Background: Acne is a very common disease affecting both sexes. The most important complication following active acne inflammation is post acne scars.

Patients and methods: This study included treatment of 30 patients suffering from post acne scarring. Patients were divided into 3 groups; group I had erbium YAG laser resurfacing, group II had subcision and fat transfer, and group III received triple therapy; laser resurfacing, subcision, and fat injection.

Results: The triple treatment modality showed overall better outcome without significant complications.

Conclusion: The triple treatment modality is a good and safe modality. Other treatment modalities can be added to this combined modality to be more effective.

Key words: Acne, subcision, fat injection, laser resurfacing.

Introduction:

Acne is a chronic inflammatory disease of the pilosebaceous units.¹ Scarring is a consequence following damage of sebaceous follicle during acne inflammation. A cell-mediated immune response has been found to be involved in these inflammatory events.² Acne scarring was found in 1.7 per 1000 for both sexes; 2.0 per 1000 in men and boys and 1.3 per 1000 in women and girls.³ Of those with acne, 74% wait greater than 1 year before seeking evaluation. Delay in treatment is thought to increase the probability of scarring.⁴

Inflammatory lesions may be superficial or deep, and many arise from non-inflamed lesions.⁵ Scarring usually follows deep inflammatory lesions, but may happen after superficial lesions in scar-prone patients.⁶ Close inspection of acne can reveal some scarring in up to 90% of patients⁷ but significant scarring occurs in about 22% of sufferers.¹ Acne and post acne scarring lead to significant psychological problems.⁸

Acne scars are broadly categorized as a result of increased tissue formation or, the more common, tissue loss.⁹ Atrophic scars are subdivided into 3 primary types by Jacob et al¹⁰ icepick, rolling, and boxcar scars.

The diversity of treatment of post acne scars actually reflects that the wide variations of the scars and the difficulty of a single treatment alone to solve the problem. The aim of this study is to present the effectiveness of the triple therapy composed of subcision, fat injection, and laser resurfacing in improving acne scarring.

Patients and methods:

The study was done over a period of 4 years (2007-2010) at the Plastic Surgery Department, Ain Shams University. Thirty patients (24 females and 6 males) suffering from atrophic facial acne scars were included. Patients' age ranged between 22-38 years with skin phototypes III-IV. Patients with infective or hypertrophic (keloidal) acne scars or with

history of isotretinoin use, filler substance injection, within the previous year were excluded from the study.

Patients were divided randomly into three groups, ten in each group. Patients of the first group(I) were treated by external laser resurfacing using Er:YAG laser (2,940 nm, wavelength, 350 μ sec pulse-width with energy fluence ranging from 10-15 J/cm²) in a single treating session. Er:YAG laser was used to ablate the acne scars with the surrounding normal skin (3-5 passes), till reaching macroscopic safe depth (upper reticular dermis).

Second group(II) were treated by lipo-filling the base of the scars at subdermal plane after subcision of scar tissue using long bi-forked needle by sweep it back and forth repeatedly to free the skin from the underlying scar tissue. Fat was harvested without tumescent usually from abdomen or trochanteric areas as available in each patient. No tumescent was used. Fat was allowed to sink down in liposuction syringe with no centrifugation or washing. Then fat was injected using injection canula. The amount of injected fat ranged from 10-20cc in each patient. Fat injection overcorrection by about 10-20 % was done.

Patients in third group(III) were treated by combining both modalities of the first and second group (Er:YAG laser for resurfacing plus subcision of scar tissue with lipofiling at

subdermal plane) at same session plus injecting more fat at deep subcutaneous and intramuscular layers for augmentation and stretching the skin.

Group I patients were done under local anesthesia, while patients of group II and III were done under general anesthesia. Extra-thin Duoderm dressing was applied after laser ablation for 5-7 days. Sunblock creams or lotions were advised to all patients after complete healing for three to six months. In addition, oral antibiotics and analgesics were used during the first week postoperative.

All patients were followed up for a period ranging from six to twelve months. Results were interpreted by comparing pre-treatment and post-treatment digital pictures taken at least six months after treatment session and every six months using Nikon-Coolpex 995 digital camera (3.3 Mpx, 5X optical zoom). Panel of three observers (physician, nurse, and patient relative) evaluated the degree of improvement by comparing the results without knowing the treatment modality that was used. Results were graded as excellent (> 75%), good (51-75%), fair (26-50%), and poor (<25%) based on degree of improvement. Complications (erythema, dyspigmentation, scarring,) were graded into either absent (0), mild (1), or moderate to severe (2).

Results:

Table (1): Summary of results in all groups.

		Excellent	Good	Fair	Poor
Group I	Laser resurfacing	1	2	3	4
Group II	Subcision & fat injection	2	3	3	2
Group III	Triple therapy	5	3	2	0

Patients of group III had an overall improvement better than the other two groups **Table(1)**. Eight patients (80%) in group III had good and excellent results compared to 3 (30%) patients in group I and 5 (50%) patients in group II. Group II patients had better results than Group I patients especially for deep scars. There was no correlation between treatment

response and patients' age, sex, previous treatment or duration of acne scars.

There was no difference in healing time of resurfaced skin in group I and group III (6-8 days). The recovery time was longer in patients who received laser treatment (group I and III). These patients took about 12-18 days to return to their work after resolution of erythema. In

group II, patients could return to work in 7-9 days after edema and mild bruising resolved.

Only 2 patients experienced mild transient hyperpigmentation for 4 weeks (1 patient in

group I and 1 patient in group III) that resolved by conservative treatment (topical hydroquinone and retinoic acid). No complications were recorded in group II.

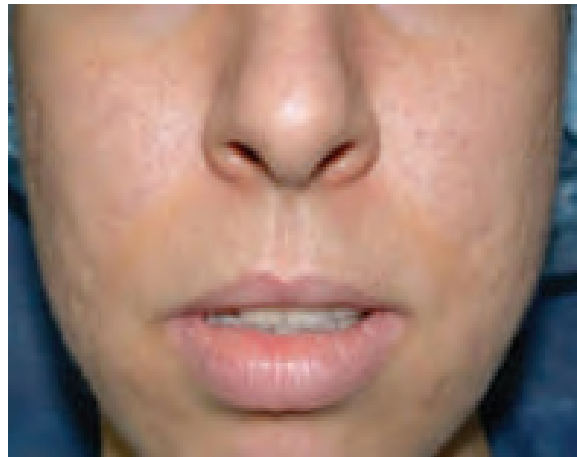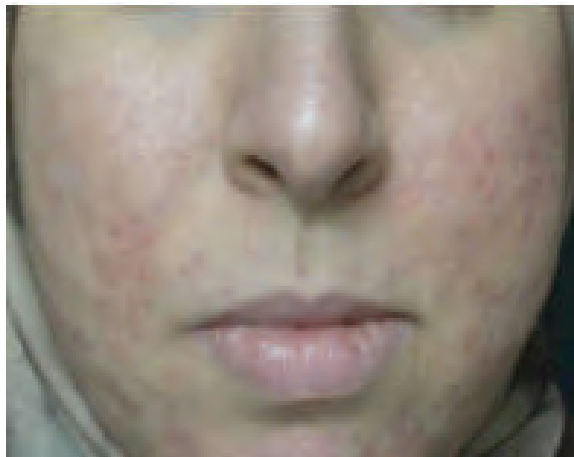


Figure (1): 24 years old female patient received laser resurfacing (group I).

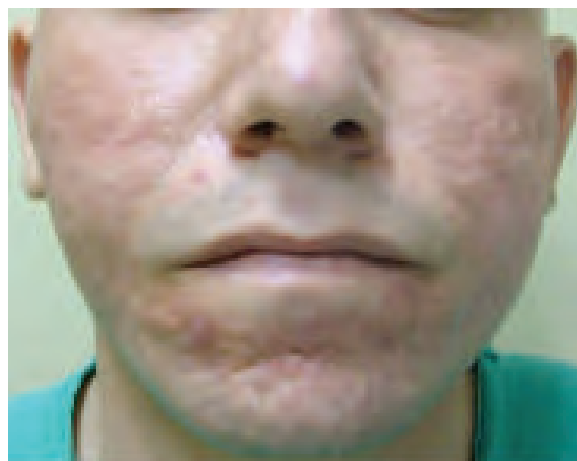
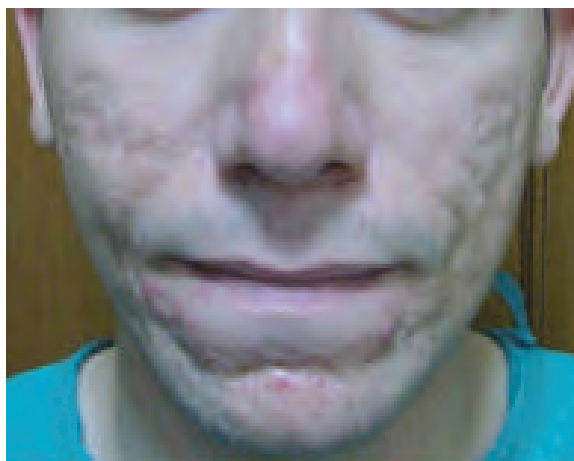


Figure (2): 27 years old male patient underwent subcision and fat injection (group II).

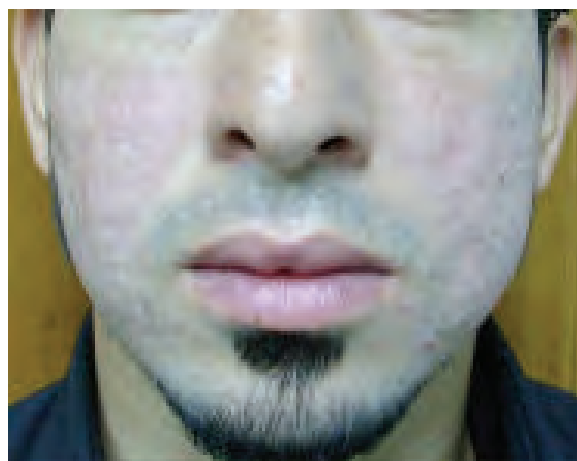
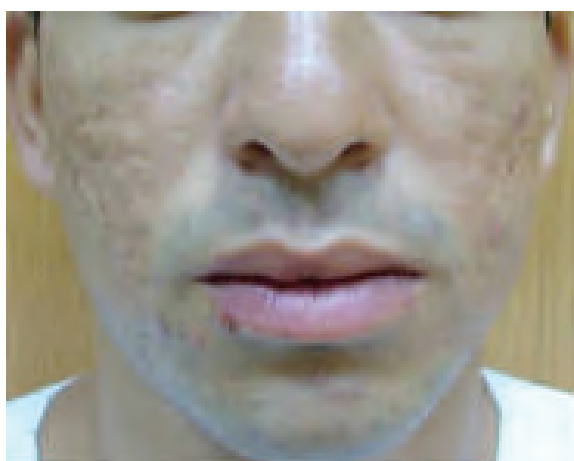


Figure (3): 25 years old male patient received triple therapy technique (group III).

Discussion:

Acne is a common disorder experienced by up to 80% of people between age of 11 and 30 years and by up to 5% of older adults.^{11,12}

For most patients acne remains a nuisance with occasional flares of lesions. Furthermore, the severe inflammatory response results in permanent scars. Post acne facial scarring affected up to 95% of both sexes.⁶ Acne scars can lead to severe psychologic problems.¹³

Once scarring has occurred, patients and physicians are left to struggle with the options available for improving skin appearance.¹⁰

Acne scars are either tissue hypertrophy or more commonly tissue atrophy which often worsens by age.¹⁴

Atrophic scars are 3 primary types as described by Jacob et al.¹⁰ icepick, rolling, and boxcar. The icepick scars are usually smaller in diameter and deep to the dermis or subcutaneous tissue. Treatment is frequently done by punch excision and closure by nonabsorbable suture.¹⁵ Boxcar scars are shallow or deep and have almost vertical walls. Shallow scars can be treated by resurfacing techniques or punch elevation. Deep scars are managed by punch excision, elevation, or other modality. Soft rolling scars can be circular or linear and have gently sloped edges. There may be dermal or subdermal tethering, so treatment is commonly by subcision. Many combining treatment modalities have been described including laser, surgery, peels, skin needling, fillers and dermabrasion.^{9,13,16-22}

A well known approach to treat acne is resurfacing of the epidermis and tightening of dermal collagen. This included dermaplaning²³ dermabrasion, and laser skin resurfacing.¹³ The limited efficacy of dermabrasion and microdermabrasion in deep scars¹³ and postoperative complications of dermabrasion²⁴ limited their use. Full-face laser skin improves overall texture and produces a homogeneous skin appearance.¹³ Nonablative and fractional lasers gained acceptance in the treatment of acne scars and photo-damaged skin.²⁵⁻³² However their results do not approach those of ablative lasers.¹⁶ Ablative lasers in acne included carbon dioxide laser³³⁻³⁵ Erbium:YAG laser³⁶⁻³⁸ and combine Erbium and CO₂ lasers.^{39,40} The Er:YAG laser is a more gentle

ablative therapy than the carbon-dioxide laser in treatment of acne scars. The Erbium YAG laser with long pulse duration achieved better results than short pulse mode.⁴¹ In addition, traditional resurfacing is more effective than the new fractional resurfacing systems.⁴²

For these reasons, we used ablative Erbium YAG laser in our study (group I and III). It showed better results in superficial scars than deep scars. It also showed low complication rate supporting its efficacy and safety. Lesions were treated as aesthetic units containing normal and scarred areas to obtain homogenous improvement.

Tissue augmentation is another alternative for managing acne scarring. This includes numerous substances such as collagen, hyaluronic acid, synthetics, silicone, implants, and fat.^{9,43,44} Autologous fat was first noted in 1893 to improve acne scars.⁴⁵ Fat is an excellent augmentation material. It is cheap, available in most patients and will not be rejected nor suffer allergic reactions.²¹

For all these reasons, we chose fat injection for tissue augmentation. Fat was injected subcutaneous as suggested by many authors²¹ as well as intramuscular injection which showed good fat survival and less resorption in other studies.⁴⁶⁻⁴⁹ Lipofilling was done in superficial and deep planes to add more stretch of the skin that makes scars less noticeable. Fat over-injection was performed by about 10-20% to overcome fat resorption. This mild overcorrection gave us good results and seems a good choice. Fat resorption reached about 20-25% after 1 year; although higher resorption (70%) was reported in other studies.⁴³ Despite fat resorption, no patient in our study needed other sessions of fat injection.

Subcision alone as a corrective technique was first described by Orentreich and Orentreich⁵⁰ in 1995 as a summation of the word "subcutaneous incisionless". In addition to scar release, controlled trauma and organization of hematoma are thought to stimulate connective tissue formation. However, it carries the risk of excess fibroplasias leading to nodule formation.^{9,21} The technique of scars undermining has been used widely as an adjunct to other maneuvers.²¹

In our study, subcision was combined with

fat injection (group II and III). This combination was more effective in deep scars than superficial scars. The complication of hematoma or nodule formation was not recorded in patients of group II or group III. However, direct scar excision seems more effective in very deep scars than subcision. This seems to produce more linear less noticeable scars.

Although attacking skin from above by laser resurfacing and from below by subcision and fat injection seems very risky, we did not report any case with skin flap compromise.

It is clear now that acne scars show great variability. Addressing all these variable types of scars using single treatment seems illogic. This explains our approach using triple therapy composed of subcision to release fibrotic bands from below, fat injection in 2 planes (subdermal and deep subcutaneous) to fill the tissue loss and contour skin, and laser resurfacing that treats surface irregularities and improves skin quality via stimulation of new collagen production. It must be clear for patients that scar improvement rather than total elimination is the ultimate goal.

Conclusion:

The combined treatment modality composed of simultaneous short pulse Erbium YAG laser resurfacing, subcision, and fat injection is a safe and effective treatment modality of post acne scarring. The addition of selective excision of deep scars and variable pulse Erbium YAG laser to the used modality may help in obtaining better and long lasting results.

References:

- 1- Simpson NB, Cunliffe WJ: Disorders of the sebaceous glands. In: Rook's Textbook of Dermatology. Tony Burns, Stephen Breathnach, Neil Cox, Christopher Griffiths (Editors); Blackwell Science (Publisher); 7th edn.; 2004, chapter 43.
- 2- Cowin AJ, Brosman MP, Holmes TM, Ferguson MWJ: Endogenous inflammatory response to dermal wound healing in the fetal and adult mouse. *Dev Dyn* 1998; 212: 385-93.
- 3- Johnson MT, Roberts J: US Department of Health, Education and Welfare, Vital and

Health Statistics: Skin conditions and related need for medical care among persons 1-74 years: United States, 1971-1974. Washington, DC; November 1978; Series 11 no. 212.

- 4- Tan JK, Vasey K, Fung KY: Beliefs and perceptions of patients with acne. *J Am Acad Dermatol* 2001; 44: 439-445.
- 5- Orentreich N, Durr NP: The natural evolution of comedones into inflammatory papules and pustules. *J Invest Dermatol* 1974; 62: 316-320.
- 6- Layton AM, Henderson CA, Cunliffe WJ: A clinical evaluation of acne scarring and its incidence. *Clin Exp Dermatol* 1994; 19: 303-308.
- 7- Varadi DP, Saqueton AC: Perifollicular elastolysis. *Br J Dermatol* 1970; 83: 143-150.
- 8- Koo J: The psychosocial impact of acne: Patients' perceptions. *J Am Acad Dermatol* 1995; 32(Suppl): 26-30.
- 9- Rivera AE, Missouri K: Acne scarring: A review and current treatment modalities. *J Am Acad Dermatol* 2008; 59(4).
- 10- Jacob CI, Dover JS, Kaminer MS: Acne scarring: A classification system and review of treatment options. *J Am Acad Dermatol* 2001; 45: 109-117.
- 11- Kraning KK, Odland GF: Prevalence, morbidity, and cost of dermatological diseases. *J Invest Dermatol* 1979; 73(Suppl): 395- 401.
- 12- Goulden V, Stables GI, Cunliffe WJ: Prevalence of facial acne in adults. *J Am Acad Dermatol* 1999; 41: 577-580.
- 13- Koo JY, Smith LL: Psychologic aspects of acne. *Pediatr Dermatol* 1991; 8: 185-188.
- 14- Kromayer E: Die Heilung der Akne durch ein neues nabenloses Operations verfahren. *Munchn Med Wochenschr* 1905; 52: 943.
- 15- Jemec JB, Jemec B: Acne: Treatment of scars. *Clin Dermatol* 2004; 22: 434-438.
- 16- Fulchiero G, Parham-Vetter P, Obagi S: Subcision and 1320-nm Nd:YAG nonablative laser resurfacing for the treatment of acne scars: A simultaneous split-face single patient trial. *Dermatol Surg* 2004; 30: 1356-1360.
- 17- Gold MH: Fibrel. *Dermatol Clin* 1995; 13: 353-361.

- 18-Pinski KS, Coleman WP: Microlipoinjection and autologous collagen. *Dermatol Clin* 1995; 13: 339-351.
- 19-Capon A, Mordon S: Can thermal lasers promote skin wound healing? *Am J Clin Dermatol* 2003; 4:1-12.
- 20-Souil E, Capon A, Mordon S, et al: Treatment with 815-nm diode laser induces long-lasting expression of 72-kDa heat shock protein in normal rat skin. *Br J Dermatol* 2001; 144: 260-266.
- 21-Goodman G, Baron J: The management of postacne scarring. *Dermatol Surg* 2007; 33: 1175-1188.
- 22-Whang KK, Lee M: The principle of a three-staged operation in the surgery of acne scars. *J Am Acad Dermatol* 1999; 40: 95-97.
- 23-Malherbe WD, Davies DS: Surgical treatment of acne scarring by a dermatome. *Plast Reconstr Surg* 1971; 47: 122-126.
- 24-Orentreich D, Orentreich N: Acne scar revision update. *Dermatol Clin* 1987; 5: 359-368.
- 25-Kim KH, Geronemus RG: Nonablative laser and light therapies for skin rejuvenation. *Arch Facial Plast Surg* 2004; 6: 398-409.
- 26-Sadick NS, Schechter AK: A preliminary study of utilization of the 1320-nm Nd: YAG laser for the treatment of acne scarring. *Dermatol Surg* 2004; 30: 995-1000.
- 27-Chua SH, Ang P, Khoo LS, Goh CL: Nonablative 1450-nm diode laser in the treatment of facial atrophic acne scars in type IV to V Asian skin: A prospective clinical study. *Dermatol Surg* 2004; 30: 1287-1291.
- 28-Tanzi EL, Alster TS: Comparison of a 1450-nm diode laser and a 1320-nm Nd: YAG: A prospective clinical and histologic study. *Dermatol Surg* 2004; 30(2 Pt 1): 152-157.
- 29-Chan HH, Lam LK, Wong DS, et al: Use of 1,320 nm Nd: YAG laser for wrinkle reduction and the treatment of atrophic acne scarring in Asians. *Lasers Surg Med* 2004; 34: 98-103.
- 30-Alster TS, Tanzi EL, Lazarus M: The use of fractional laser photothermolysis for the treatment of atrophic scars. *Dermatol Surg* 2007; 33: 295-299.
- 31-Goldberg DJ: Full-face nonablative dermal remodeling with a 1320- nm Nd:YAG laser. *Dermatol Surg* 2001; 26: 915-918.
- 32-Ang P, Barlow RJ: Nonablative laser resurfacing: A systematic review of the literature. *Clin Exp Dermatol* 2002; 27: 630-635.
- 33-Goodman GJ: CO₂ laser resurfacing: A subjective study 100 patients' attitudes outcomes. *Dermatol Surg* 1998; 24:665-672.
- 34-Dover JS: CO₂ laser resurfacing: Why all the fuss? *Plast Reconstr Surg* 1996; 98: 506-509.
- 35-Alster TS, West TB: Resurfacing of atrophic facial acne scars with a high-energy, pulsed carbon dioxide laser. *Dermatol Surg* 1996; 22: 151-154.
- 36-Fitzpatrick RE, Goldman MP: Skin resurfacing with carbon dioxide and Erbium lasers. In: Cutaneous laser surgery, the art and science of selective photothermolysis. Goldman MP, Fitzpatrick RE (Editors); St Louis: Mosby (Publisher); 2nd edn.; 1999; p. 339-436.
- 37-Tanzi EL, Alster TS: Single-pass carbon dioxide versus multiplepass Er:YAG laser skin resurfacing: A comparison of postoperative wound healing and side-effect rates. *Dermatol Surg* 2003; 29: 80-84.
- 38-Zachary CB: Modulating the Er: YAG laser. *Lasers Surg Med* 2000; 26: 223-226.
- 39-McDaniel DH, Lord J, Ash K, Newman J: Combined CO₂/Erbium: YAG laser resurfacing of perioral rhytids and side to side comparison with carbon dioxide laser alone. *Dermatol Surg* 1999; 25: 285-293.
- 40-Collawn SS: Combination therapy: Utilisation of CO₂ and Erbium: YAG lasers for skin resurfacing. *Ann Plast Surg* 1999; 42: 21-26.
- 41-Walia S, Alster TS: Prolonged clinical and histological effects from CO₂ laser resurfacing of atrophic acne scars. *Dermatol Surg* 1999; 25: 926-930.
- 42-Alexiades-Armenakas MR, Dover JS, Arndt KA: The spectrum of laser skin resurfacing: Nonablative, fractional, and ablative laser resurfacing. *J American Academy Dermatology* 58(5): 719-737.

- 43-Pinski KS, Roenigk HH: Autologous fat transplantation. *J Dermatol Surg Oncol* 1992; 18: 179-184.
- 44-Varnavides CK, Forster RA, Cunliffe WJ: The role of bovine collagen in the treatment of acne scars. *Br J Dermatol* 1987; 116: 199- 206.
- 45-Krauss MC: Recent advances in soft tissue augmentation. *Semin Cutan Med Surg* 1999; 18: 119-128.
- 46-Butterwick KJ, Lack EA: Facial volume restoration with the fat autograft muscle injection technique. *Dermatol Surg* 2003; 29: 1019-1026.
- 47-Amar RE, Fox DM: The facial autologous muscular injection (FAMI) procedure: An anatomically targeted deep multiplane autologous fat-grafting technique using principles of facial fat injection. *Aesth Plast Surg* DOI 10.1007/s00266-010-9645-0.
- 48-Donofrio LM: Techniques in facial fat grafting. *Aesthetic Surg J* 2008; 28(6): 681-687.
- 49-Amar RE: Adipocyte microinfiltration in the face or tissue restructuration with fat tissue graft. *Ann Chir Plast Esthet* 1999; 44: 593-608.
- 50-Orentreich DS, Orentreich N: Subcutaneous incision (subcision) surgery for the correction of depressed scars and wrinkles. *Dermatol Surg* 1995; 21: 543-549.