

قسم : التشريح والهستولوجيا - كلية العلوم البيطرية - جامعة بانث - الهند .  
رئيس القسم : د / برم براكاش

### التغيرات الهستولوجية للغدة الدرقية لذكور الجاموس بعد الخصى

برم براكاش ، راثور

أجريت دراسة عن مدى التغيرات الهستولوجية فى الغدة الدرقية لذكور الجاموس بعد الخصى ولقد أظهرت الدراسة أنه بعد الطريقة المفتوحة للخصى زاد متوسط قطر الفص من الغدة الدرقية وكانت اعلى نسبة للخلايا المكعبة الكثيرة فى مجموعة الضوابط فى حين كانت الخلايا المكعبة الصغيرة عالية فى الذكور المخصية بالطريقة المفتوحة وقل ارتفاع الخلايا البطينة المفتوحة للغدة الدرقية بعد الخصى بالطريقة المفتوحة وكانت التغيرات المذكورة فى هذه المجموعة مصاحبة للتغير المعنوى لقدرة امتصاص العترة الدرقية لليود  $^{131}$  وكذلك قدرة الكورات الدموية الحمراء لامتصاص اليود  $^{131}$  . ولم يتسبب الخصى بطريقة قطع الحبل المنوى عن حدوث أية تغيرات معنوية فى حيوانات هذه المجموعة فى أى من عناصر الدراسة .



STRUCTURAL CHANGES IN THE THYROID  
GLAND OF BUFFALO (*Bubalus bubalis*) FOLLOWING CASTRATION  
(With 1 Table & 3 Figures)

By  
PREM PRAKASH and V.S. RATHORE\*  
(Received at 17/1/1983)

SUMMARY

The effects of castration on the structural variations of the thyroid gland were studied in male buffaloes. Following castration (open method) the diameter of the thyroid follicles was somewhat larger. The percent of high cuboidal (6.5 - 10.5  $\mu$ m) type of follicular cells was greater (48.44%) in the control group, whereas in the castrated group (open method) low cuboidal (3.3 - 6.4  $\mu$ m) type of cells appeared to preponderate (56.08%). The height of the follicular cells was appreciably decreased ( $P/0.01$ ) in buffaloes castrated by open method. These changes in these emasculated buffaloes were also correlated with a significant decrease in thyroïdal uptake of  $^{131}\text{I}$  (UT) and percent erythrocyte uptake of  $^{131}\text{I}$  (EUT). However, no variations were observed in the size of the thyroid follicles, percent and height of follicular cells as also in the values of UT and EUT in the caudectomized animals.

INTRODUCTION

The correlation between thyroid structure and function has been reported by many in both normal and diseased condition, but only a few attempts have been made to study the structural changes in this gland after castration in different animals. NOON and TURNER (1960) noted reduction of functional activity of the thyroid gland in castrated female rats and D'ANGELO (1966) elucidated similar results in castrated rats of both the sexes. The structural changes in the thyroid gland after castration have been reported in guinea pig (STARR and BURNER, 1935), mouse (OHIDA, 1954), cattle (DAS *et al.*, 1965) and sheep (KALINOWSKA, 1977). Apparent lack of information in this regard in the buffalo prompted this study. In addition the current investigation forms part of a continuing study on the turnover of thyroïdal  $^{131}\text{I}$  in this species.

MATERIAL and METHODS

12 male buffalo calves of about 18 months of age were selected irrespective of breeding stock. The animals were divided into 3 groups of 4 animals each. Castration by caudectomy and open methods were performed on the animals of the first and second groups whereas the third group served as control. The animals were kept on normal ration for 6 months. The percent erythrocyte uptake  $^{131}\text{I}$  (EUT) was determined by the procedure of HAMOLSKY *et al.* (1957). The method as described earlier (PRAKASH and SHARMA, 1975), was followed for the determination of thyroïdal  $^{131}\text{I}$  uptake (UT). The animals were then slaughtered and the thyroid glands were collected. Immediately after collection 2-3 mm thick pieces of thyroid tissues were immersed in 10% buffered formalin and processed by routine paraffin-tissue technique. 5  $\mu$ m thick sections were cut and stained by HEMATOXYLIN and EOSIN (LILLIE, 1965) and MALLORY's triple stain (CROSSMAN, 1937).

In addition to the general architecture of the thyroid gland, the following quantitative parameters as per the procedures described earlier (PRAKASH and SHARMA, 1978) were determined for each sample:  
(i) size of thyroid follicles ( $\mu$ m); (ii) height of follicular cells ( $\mu$ m); (iii) percent of different types of follicular cells and (iv) number of blood vessels per mm.

The data of each parameter were subjected to statistical analysis (SNEDECOR and COCHRAN, 1967).



## RESULTS

The mean values alongwith standard error (+) of different quantitative parameters are indicated in Table (1). The general architecture of the sections of thyroid gland of control and castrated buffaloes are shown in Figs. (1-3).

The thyroid gland was made up of different sized follicles. Most of the thyroid follicles were oval in shape, while some were rounded or irregular in contour. The mean size (short diameter x long diameter) of the follicles in control, caudectomized and open method castrated buffaloes were  $43.92 \times 156.35 \mu\text{m}$ ,  $46.75 \times 160.29 \mu\text{m}$  and  $68.71 \times 210.01 \mu\text{m}$ , respectively. The buffaloes castrated by open method showed large-sized follicles (Fig. 3). However, no differences were seen in the follicle size between the caudectomized and control animals. Each follicle was filled with a homogenously, staining colloid material which was acidophilic. The colloid showed greater vacuolation in the control and caudectomized groups of buffaloes (Fig. 1,2). There was an increase in the amount of colloid in the castrated (open method) animals (Fig. 3).

The follicles were lined by follicular cells. In open method castrated buffaloes the majority of follicular cells were flattened (upto  $3.2 \mu\text{m}$ ) to low cuboidal ( $3.3 - 6.4 \mu\text{m}$ ) type (Fig. 3), whereas in the caudectomized and entire buffaloes the high cuboidal ( $6.5 - 10.5 \mu\text{m}$ ) and columnar ( $10.5 \mu\text{m}$  - above) type of cells appeared to preponderate (Fig. 1,2). The average follicular cell height in the control, caudectomized and open method castrated groups was  $9.20 \pm 0.13 \mu\text{m}$ ,  $9.35 \pm 0.15 \mu\text{m}$  and  $5.99 \pm 0.12 \mu\text{m}$ , respectively. The nuclei of the follicular cells were stained bright blue and the cytoplasm was stained light pink with HEMATOXYLIN and EOSIN. The nuclei of the flattened follicular cells were elongated, while cuboidal and columnar cells had large spherical nuclei located at the basal half of the cells (Figs. 1-3).

The percent values of EUT, UT and number of blood vessels per  $\text{mm}^2$  in the open method castrated, caudectomized and control groups of buffaloes are summarized in Table (1). The analysis of data showed that castrated (open method) buffaloes exhibited a decrease of 28.6% in EUT, 25.7% in UT and 19.9% in the number of blood vessels. These differences were found to be statistically significant ( $P \leq 0.05$ ). However, no significant variations were observed in the animals castrated by caudectomy method.

## DISCUSSION

The general histological structure of the follicular cells in the current study resembles that described by TOMONARI (1959) and MATHUR (1971). The control group had a higher percentage (48.44%) of high cuboidal ( $6.5 - 10.5 \mu\text{m}$ ) cells, but the castrated (open method) group had a higher percentage (56.08%) of low cuboidal ( $3.3 - 6.4 \mu\text{m}$ ) type of cells. An analysis of results revealed a reduction of 34.8% in the follicular cell height in these castrated group of animals. This observation is in conformity with the findings of KALINOWSKA (1977) in sheep and OHIDA (1954) in mouse.

It is further evident from the present study that as compared to controls, the diameter of the thyroid follicles appeared to be somewhat larger in buffaloes castrated by open method. This is in agreement with the findings of OHIDA (1954) in mouse, who has observed enlargement of follicles following castration. Contrary to this STARR and BURNER (1935) have failed to find any increase in the size of the follicles following castration in guinea pigs. The amount of colloid in the thyroid follicles of the castrated (open method) buffaloes increased in comparison with the control and caudectomized animals. The decrease in frequency of blood vessels per  $\text{mm}^2$  was also noted in the thyroid tissue of the castrated buffaloes (Table 1). These changes indicated that castration by open method inhibits the secretion of thyrotrophic hormone resulting in a direct retarding effect on the functional activity of the thyroid gland. A similar view has been expressed by FINERTY and COWDRY (1962) during hypothyroidism in man. In this study the hypoactivity of the thyroid gland could be further confirmed by an appreciable decrease in the percent values of EUT and UT. Reduction in UT has also been reported by MOON and TURNER (1960) and D'ANGELO (1966) in castrated rats.



# THYROID GLAND OF BUFFALO, CASTRATION

## ACKNOWLEDGEMENTS

Thanks are due to Shri Harbans Lal for the help extended in processing of tissues and to Shri D.N. Brijwasi for analysis of data.

## REFERENCES

- Crossman, G.A. (1937): A modification of Mallory's connective tissue stain with a discussion of principles involved. *Anat. Rec.*, 69, 33-38.
- D'Angelo, S.A. (1966): A comparative study of TSH and FSH secretion in rat and guinea pig. Effects of gonadectomy and goitrogens. *Endocrinology*, 78, 1230-1237.
- Das, L.N., Mishra, D.B. and Biswal, G. (1965): Comparative histological study of adrenal and thyroid glands of the bull and bullock. *Indian Vet. J.*, 42, 824-830.
- Finerty, J.C. and Cowdry, E.V. (1962): *Textbook of Histology*. 5th ed. pp. 296-309. Lea and Febiger. Philadelphia.
- Hamolsky, M.W., Stein, M. and Freedberg, A.S. (1957): The thyroid hormone plasma protein complex in man. II. A new *in vitro* method for the study of uptake of labelled hormonal components by human erythrocytes. *J. Clin. Endocr. and Metab.*, 17, 33-44.
- Kalinowska, C. (1977): Relationship of thyroid activity and growth rate of sheep. *Roczniki Nank Rolniczych*, 37-46.
- Lillie, R.D. (1965): *Histopathologic Technic and Practical Histochemistry*. 3rd ed. P. 57. McGraw Hill Book Co. New York.
- Mathur, M.L. (1971): Microscopic study of the thyroid gland of the Asiatic water buffalo (*Bubalus bubalis*). *Am. J. Vet. Res.*, 32, 363-366.
- Moon, R.C. and Turner, C.M. (1960): Effects of ovariectomy and replacement therapy upon thyroxine secretion rate of rat. *Proc. Soc. Exp. Biol. Med.*, 103, 66-68.
- Ohida, S. (1954): Histological studies of the thyroid gland of the mouse after castration. *Folia anat. Jap.*, 26, 347-370.
- Prakash, P. and Sharma, D. (1975): Seasonal variation in thyroidal <sup>131</sup>I uptake and thyroxine secretion rate in buffalo (*Bubalus bubalis*). *Acta Veterinaria Hung. Budapest.*, 23, 369-375.
- Prakash, P. and Sharma, D. (1978): Structural changes in the thyroid gland of buffalo following administration of thiouracil. *Anat. Anz. Jena.*, 143, 271-276.
- Snedecor, G.W. and Cochran, W.G. (1967): *Statistical Methods*. 6th ed. pp. 258-260. Iowa State University Press. Ames, Iowa.
- Starr, P. and Burner, R.C. (1935): Effect of castration on thyroid in female guinea pig. *Proc. Soc. Exp. Biol. Med.*, 33, 465-468.
- Tomonari, T. (1959): Histological studies of mammalian thyroid glands. *Arch. Histol. Jap.*, 17, 497-523.

## Explanation of Figures

- Fig. (1): Section of the thyroid gland of male buffalo (control) showing high cuboidal follicular cells. (Hematoxylin and Eosin stain. OC.10 X Ob. 40).
- Fig. (2): Section of the thyroid gland of male buffalo (Caudectomy) showing high cuboidal follicular cells. (Hematoxylin and Eosin stain. OC.10 X Ob.40).
- Fig. (3): Section of the thyroid gland of male buffalo (open method) showing flattened and low cuboidal follicular cells. (Hematoxylin and Eosin stain. OC.10 X Ob.40).

Table (1): Mean values  $\pm$  S.E. of different parameters of the thyroid gland of buffalo.

Parameters	Control	Castrated	
		Open Method	Caudectomy method
Thyroidal $^{131}\text{I}$ uptake (%) dose	32.07 $\pm$ 1.88	23.83 $\pm$ 1.32	31.2 $\pm$ 1.83
Erythrocyte uptake of $^{131}\text{I}$ (%)	21.3 $\pm$ 4.8	15.2 $\pm$ 2.7	20.1 $\pm$ 5.02
Number of blood vessels per mm <sup>2</sup>	211 $\pm$ 9.03	169 $\pm$ 11.41	205 $\pm$ 6.32
Percent follicular cell type:			
a) upto 3.2 $\mu\text{m}$	2.70 $\pm$ 0.25	15.66 $\pm$ 0.51	2.99 $\pm$ 0.27
b) 3.3 - 6.4 $\mu\text{m}$	23.33 $\pm$ 1.14	56.08 $\pm$ 1.63	29.11 $\pm$ 1.43
c) 6.5 - 10.5 $\mu\text{m}$	48.44 $\pm$ 1.64	27.36 $\pm$ 1.72	46.56 $\pm$ 1.91
d) 10.6 $\mu\text{m}$ - above	25.53 $\pm$ 1.94	0.90 $\pm$ 0.39	23.34 $\pm$ 2.11
Follicular cell height ( $\mu\text{m}$ )	9.20 $\pm$ 0.13	5.99 $\pm$ 0.12	9.35 $\pm$ 0.15
Size of follicles ( $\mu\text{m}$ ):			
a) short diameter	43.92 $\pm$ 1.57	68.71 $\pm$ 2.62	46.75 $\pm$ 1.53
b) long diameter	156.35 $\pm$ 5.54	210.01 $\pm$ 5.1	160.20 $\pm$ 7.12



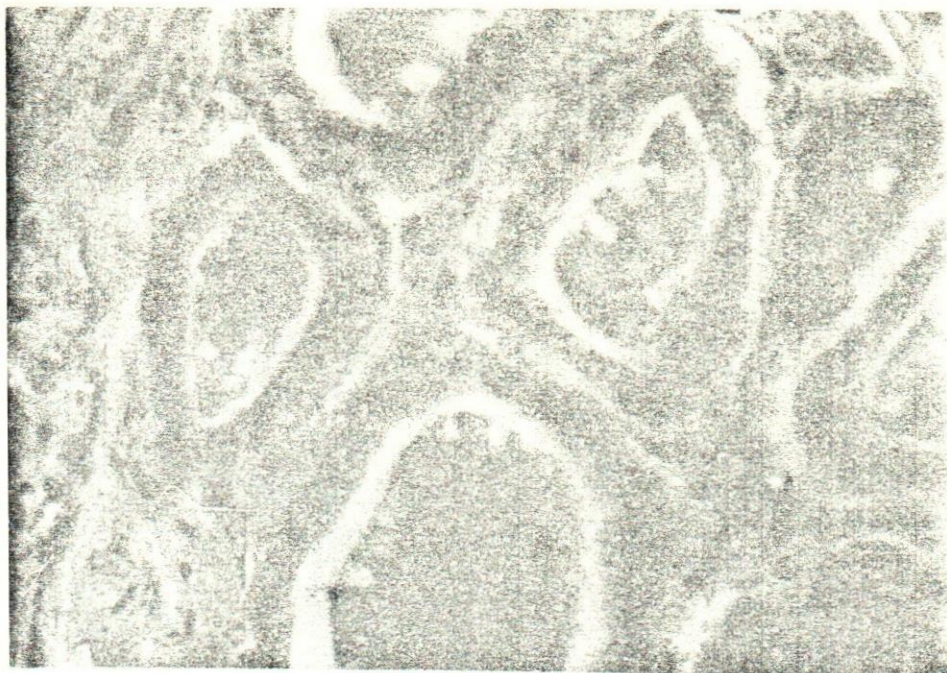


Fig.(1)

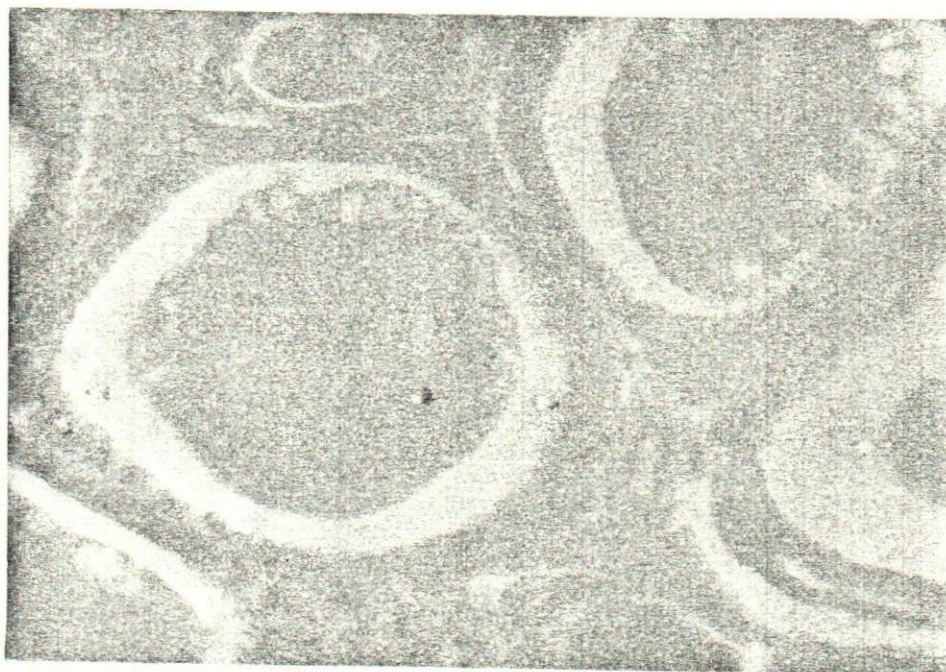

Fig.(2)

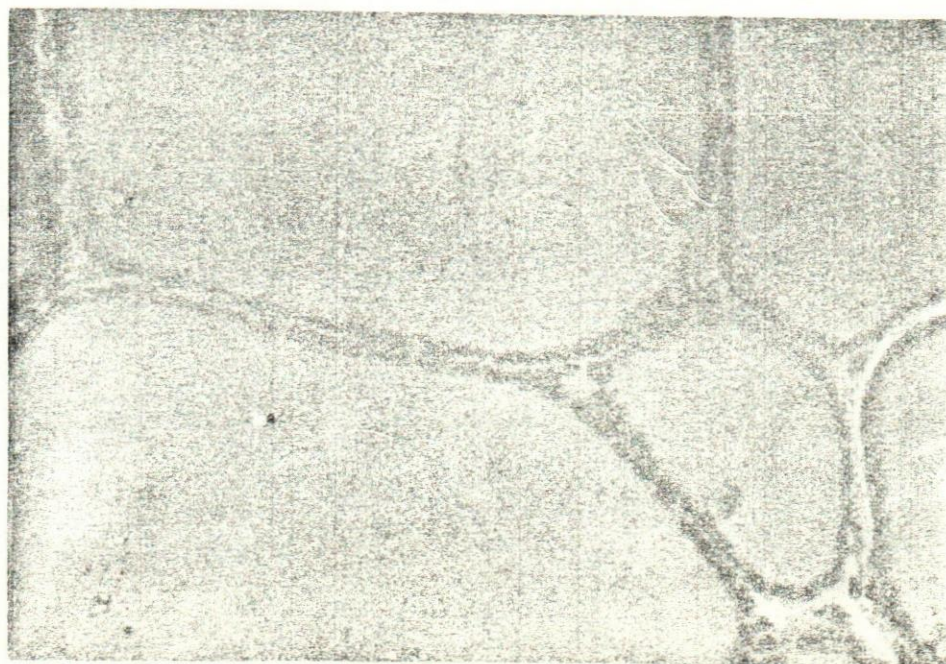

Fig. (3)



