

قسم : التشريح والهستولوجى - كلية الطب البيطرى - جامعة أسيوط .  
رئيس القسم : أ د / عبدالله حفى طه .

### الابهـر الصدري فى الجمل وحيد السنـام

عبدالله حفى ، أحمد قنارى ، محمد عطية

تم فى هذا البحث دراسة مسار الابهـر الصدري والذي يجتاز الفرجة الابهـرية مغيرا اسمه الى الابهـر البطنى . كما تم دراسة الشرايين بين الضلعية الظهرية ويبلغ عددها احد عشر زوجا ينشا الزوج الأول منها من الشريان العنقى الفائر والثانى من الشريان الضلعى العنقى اما باقى الشرايين فانهاتخرج من الابهـر الصدري . وقد وجد أن كل شريان بين ضلعى يعطى الفرع الظهرى ، الذى يخرج منه الفرع الشوكى وفرعين لعضلات الظهر وكذلك فروعا تنتظم فى صفوف يتراوح عددها بين ستة وسبعة لتغذية الجلد فى منطقة الصدر . كما أمكن معرفة العدد الشريانى المغذى للسـم فى الجمل . هذا وقد وجد أن الابهـرى الصدري يعطى كذلك الشريان الحجابى الأمامى لتغذية ساقى الحجاب الحاجز .

Handwritten text at the top of the page, possibly a header or title.

Handwritten text line below the header.

Handwritten text line in the upper middle section.

Main body of handwritten text, consisting of several lines of cursive script.

Dept. of Anatomy and Histology,  
Faculty of Vet. Med., Assiut University,  
Head of Dept. Dr. A. Hifny.

AORTA THORACICA OF THE ONE-HUMPED CAMEL  
(*Camelus dromedarius*)  
(With One Figure)

By

A. HIFNY, A.K. AHMED and M. ATTIA  
(Received at 16/11/1981)

SUMMARY

The course and branches of the thoracic Aorta were completely examined. In addition the origin and branches of the dorsal intercostal arteries in camel were carefully described.

INTRODUCTION

A complete description about the thoracic aorta and the distribution of the dorsal intercostal arteries in the one humped camel is not available. The vascularization of the characteristic Hump of the camel is also included in the present study, in addition to, the branches of the thoracic aorta.

MATERIAL and METHODS

The present study was carried out on 7 adult and 2 full term fetuses of the one-humped camel (*Camelus dromedarius*) of both sexes and different ages.

The animals were bled and injected at first with 10% formalin solution and after 48 hours with red coloured Latex.

The Nomenclature used is that adopted by NOMINA ANATOMICA VETERINARIA (1973).

RESULTS

The thoracic aorta (1/4) forms the direct continuation of the aortic arch (1/1) opposite to the fifth thoracic vertebra. It extends till the caudal border of the second lumbar vertebra where it enters the abdominal cavity through Hiatus aorticus to continue as abdominal aorta.

At its initial part, it lies to the left of the median plane then passes caudally between the two pleural sacs along the ventral aspect of the bodies of the thoracic vertebrae.

During its course, the thoracic aorta gives off Aa. intercostales dorsales III-XI, A. costoabdominalis dorsalis, Aa. Lumbales I et II and A. phrenica cranialis.

Aa. intercostales dorsales:

The dorsal intercostal arteries (1/5) in camel are eleven pairs. The first pair is detached from the deep cervical arteries and the second one originates from the costocervical trunks. Both of the right and left dorsal intercostal arteries III-XI originate separately from the dorsal aspect of the thoracic aorta.

The first two dorsal intercostal arteries pass ventrally while the third and fourth ones are directed craniodorsally and the rest of them run in a caudodorsal direction lateral to the bodies of the corresponding vertebrae. Each dorsal intercostal artery then descends between the intercostal muscles to continue its course subpleurally along the caudal border of the respective rib.

The second to the seventh dorsal intercostal arteries terminate by joining the postcostal branches of A. thoracica interna and A. musculophrenica. The rest of the dorsal intercostal arteries cross the costal arch and pierce the costal part of the diaphragm and M. transversus abdominis to terminate in M. rectus abdominis.



*A. HIFNY, et al.*

Each of the aortic dorsal intercostal arteries detaches a R. dorsalis and Rr. cutanei. In addition, the Left third dorsal intercostal artery gives off a R. bronchialis which crosses the lateral aspect of Aorta thoracica and divides at the tracheal bifurcation into a right and a left branch for the corresponding lung.

R. dorsalis:

The dorsal branch (1/6) is given off just caudoventral to the transverse process of the corresponding vertebra. It passes through the proximal end of its intercostal space detaching a R. spinalis, R. interspinosus and continues its course as R. muscularis.

The spinal branch (1/7) enters the vertebral canal via the intervertebral foramen to join the ventral spinal artery while the interspinous branch (1/8) detaches a twig to the respective costovertebral articulation then ascends on the interspinous ligament medial to M. multifidus. It supplies the above mentioned muscle in addition to M. spinalis et semispinalis thoracis and ends in M. longissimus thoracis.

Rr. cutanei laterales:

The lateral cutaneous branches (1/10) which are detached from the second to eleventh dorsal intercostal arteries are arranged in six rows. The branches of the first row originate from Aa. intercostales dorsales except the third and fourth ones arise from the respective dorsal branches. They appear between Mm. longissimus thoracis and iliocostalis thoracis. They directed dorsomedially to supply the above mentioned muscles, trapezius thoracis and the area of the skin which is vascularized normally by Rr. cutanei mediales in the other domestic animals. The hump is well vascularized through considerable branches from the eighth to eleventh lateral cutaneous branches of the same row.

Rr. cutanei laterales of the second row appear just at the ventral border of M. iliocostalis thoracis. This row supplies together with the third and fourth rows Mm. serratus ventralis thoracis cranially and serratus dorsalis caudally. The cutaneous branches of the second to the fifth rows of Aa. intercostales dorsales II-V are purely muscular while those of the other dorsal intercostal arteries terminate in the skin of the lateral body wall.

Rr. cutanei laterales of the fifth and sixth rows supply Mm. latissimus dorsi, obliquus externus abdominis and the skin of the region.

Rr. cutanei laterales of the seventh row are detached caudally from the last four dorsal intercostal arteries while cranially are given off Rr. postcostales of Rr. intercostales ventrales of A. thoracica interna and A. musculophrenica. They vascularize M. obliquus externus abdominis and the skin of the area.

A. costoabdominalis dorsalis:

The dorsal costoabdominal artery (1/11) arises from Aorta thoracica at a level with the last thoracic vertebra. It runs laterally between the body of the vertebra and Mm. psoas minor and major. It continues its course then along the caudal border of the last rib to end in M. transversus abdominis. It has similar distribution as the last dorsal intercostal artery.

A. phrenica cranialis:

The cranial phrenic artery (1/12) is given off Aorta thoracica at a level with the caudal border of the last thoracic vertebra.

It passes in a cranioventral direction on the lateral part of the right crus of the diaphragm. At the caudal end of the last thoracic vertebra, it divides into a cranial and a caudal branch. They ramify in the right crus, in addition, the cranial branch supplies the caudal mediastinal lymph nodes.

## DISCUSSION

The origin of A. intercostalis I from A. cervicalis profunda in camel is similar to that described by LESBRE (1903) in the same animal and WILKENS and MUNSTER (1976) in dog and horse. SUZUKI (1961) stated that the first dorsal intercostal artery in dog arises either from the deep cervical artery or the costocervical trunk. However, GHOSHAL (1975) mentioned that Aa. intercostales dorsales I et II in ruminants are given off A. intercostalis suprema.



# THORACIC AORTA IN CAMEL

The second dorsal intercostal artery originates in camel from the costocervical trunk, while LESBRE (1903) stated that this vessel is detached from the subcostal branch of the dorsal scapular artery in the same animal. - WILKENS and MUNSTER (1976) mentioned that this vessel arises in all domesticated animals other than dog from the supreme intercostal artery and in dog from A. vertebralis thoracica. The last mentioned authors stated that the first and second dorsal intercostal arteries in and are absent. GHOSHAL (1975) described these two vessel in pig as atypical, the first arises from A. vertebralis on the right side and A. cervicalis profunda on the left side and the second one from A. scapularis dorsalis on both sides.

The joining between Aa. intercostales dorsales II-VII and Rr. postcostales in camel simulates that found by SEIDLER (1966) between Aa. intercostales dorsales I - X and Rr. intercostales ventrales caudales in cattle.

The cranial phrenic artery is not described in other domestic animals other than horse as mentioned by KOCH (1970) and WILKENS and MUNSTER (1976).

## REFERENCES

- GHOSHAL, N.G. (1975): Heart and arteries in: S. SISSON and J.D. GROSSMAN: Anatomy of the domestic animals. Vol. I, II; 5th ed., 607-618, 993-1002, 1336-1342, 1640-1651, W.B. Saunders Comp., Philadelphia-London.
- Koch, T. (1970): Lehrbuch der Anatomie, Bd. III, VBE, Verlag Gustav Fischer, Jena.
- Lesbre, M.F.X. (1903): Recherches Anat. sur les Camelides (Tome VIII), Arch. Mus. D'Hist. Nat. Lyon. Lib. de Fac. Med. et de Fac. Droit.
- Nomina Anatomica Veterinaria (1973): Published by the International Committee on Vet. Anatomical Nomenclature, Vienna.
- Seidler, D. (1966): Arterien und Venen der Körperwand des Rindes. Diss. Med. Vet., Tierarztl. Hochschule, Hannover.
- Suzuki, T. (1961): The Vascular system of the thoracic wall of the dog. The intercostal arteries and the lateral thoracic artery. Acta Anat. N.P. 36, 72-82.
- Wilkins, H. and W. Munster (1976): Arterien und Venen in: R. Nickel, A. Schummer und E. Seifried; Lehrbuch der Anatomie der Haustiere, Bd. III, 143-190. Verlag P. Parey, Berlin - Hamburg.

## LEGENDS

Fig. (1): Diagram showing the course and branches of the thoracic aorta in camel. Left side.

- |                              |                                |                            |
|------------------------------|--------------------------------|----------------------------|
| A) second thoracic vertebra, | B) third rib,                  | C) last rib                |
| 1- Arcus aortae,             | 2- Truncus brachiocephalicus,  | 3- A. subclavia sinistra,  |
| 4- Aorta thoracica,          | 5- Aa. intercostales dorsales, | 6- R. dorsalis,            |
| 7- R. spinalis,              | 8- R. interspinosus,           | 9- R. muscularis,          |
| 10- R. cutanei lateralis,    | 11- A. costoabdominalis,       | 12- A. phrenica cranialis. |

THE HISTORY OF THE

REIGN OF CHARLES THE FIRST  
IN THE YEAR 1649  
BY JOHN HENRY  
OF THE MIDDLE TEMPLE  
ESQ.

LONDON  
Printed by J. Sturges, at the Angel in St. Dunstons Church  
1754

TO THE

READERS OF THIS HISTORY  
THE AUTHOR SAYS  
THAT HE HAS BEEN  
OBLIGED TO

REVISIT THE  
ORIGINAL MANUSCRIPTS  
AND TO CORRECT  
THE PRESS

AND TO ADD  
SOME NEW  
NOTES  
AND

TO THE  
END OF  
THE  
HISTORY

AND TO  
THE  
END OF  
THE  
HISTORY

AND TO  
THE  
END OF  
THE  
HISTORY

AND TO  
THE  
END OF  
THE  
HISTORY

AND TO  
THE  
END OF  
THE  
HISTORY

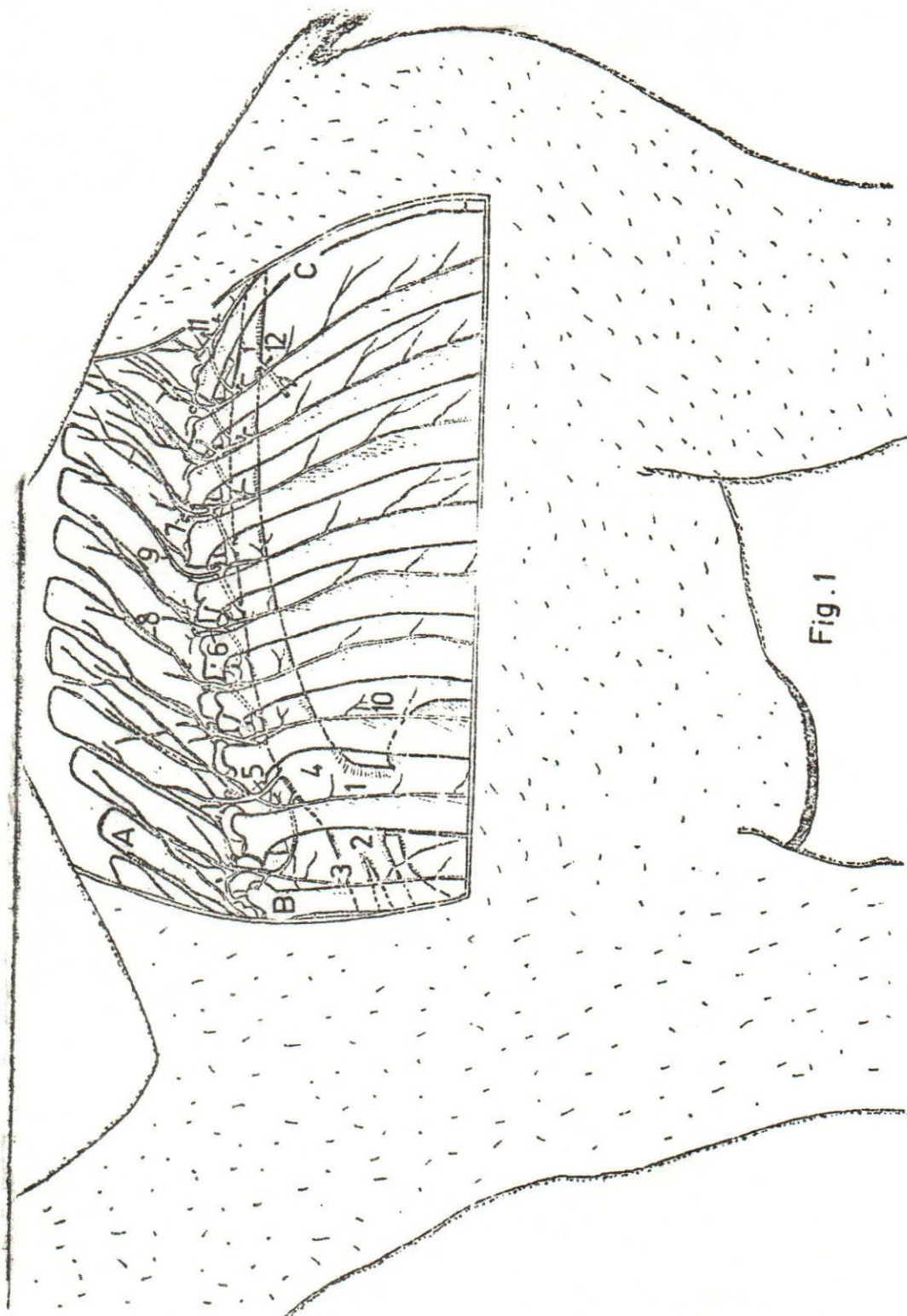


Fig. 1



