

Dept. of Surgery & Theriogenology,
Faculty of Vet. Med., Alexandria University,
Head of Dept. Prof. Dr. M.Y. Abboud.

SOME SURGICAL AFFECTIONS OF THE TEETH IN LARGE RUMINANTS (With 1 Table & 7 Figs.)

By
M.M. KASSEM; A.A. KENAWY and S.R. NOUH
(Received at 14/4/1991)

بعض الاصابات الجراحية للأسنان في المجترات
الكبيرة

مصطفى قاسم ، أحمد قناوي ، سمير ———

أجري البحث علي ٢٩ (تسعة وعشرون) حيوان من المجترات الكبيرة واتضح من الدراسة أن الأغلبية العظمى من الإصابات الجراحية للأسنان تنحصر في : - الأسنان البنية اللون - المسافات البينية بين الأسنان - تسوس مينا الأسنان - ترسيب الأملاح الجيرية علي الأسنان - إلتواء الأسنان الأمامية - الأسنان ذو الزوائد الحادة - الزيادة في عدد الأسنان - الفك الخنزيري . ومن النتائج السابقة يتضح أن بعض اصابات الاسنان لا تؤثر تأثيراً مباشراً علي صحة الحيوان ، ووجد البعض الآخر له مخاطر كبيرة علي صحة الحيوان ويستوجب التدخل الجراحي بالطرق المعتادة لعلاج مثل هذه الحالات خوفاً من المضاعفات .

SUMMARY

In the present work, the most common dental affections were recorded in large ruminants in twenty nine cases, including brown teeth, diastasis dentium, rotation of the rostral teeth, dental calculus, sharp enamel points, enamel flecks, false polyodontia and prognathism.

Many dental affections in ruminants had no bad effect on the animal. Other produce severe pain to the patient animal and subsequently lead to complications. The later affections could be treated surgically in routine procedures.

INTRODUCTION

Some dental affections were recorded in donkeys and horses. These affections were classified according to their incidence into: dental caries sharp enamel points, projection of the upper cheek teeth, dental tarter, diastasis dentium, fracture of the teeth and polyodontia (AMIN and KASSEM, 1987).

Many congenital, developmental and acquired affections of the teeth were recorded in donkeys and horses. Congenital affections are brachygnathism, prognathism, diastasis dentium, polyodontia and oligodontia. The developmental affections include, sharp enamel points, step formed mouth, smooth masticatory surface, projection (hooking) of one tooth and exuprantia dentis. Dental diseases mentioned in the available literatures as, dental caries dental tarter, alveolar periostitis and dental fistula (MISK and HIFNY, 1982).

On the other hand, developmental abnormalities of the teeth in ruminants were discussed by HARVEY (1985) who stated that hypodontia or partial anodontia, in which a few teeth are absent is due to absence or failure of development of one or more tooth buds. Additional teeth (polyodontia) occurs much less frequently than partial anodontia. Diastasis dentium allows the introduction and impaction (entrapment) of food material, theraby causing gingivitis and in some cases resulting in a breakdown of the periodontal membrane.

Enamel flecks were described as small opaque spots in the enamel on the labial surface in both the temporary and the permanent dentition occur in one or more rostral teeth. The spots were white to yellow-brown or black, and they darken with age. When these flecks reach the occluded surface they are rapidly worn away, resulting in the formation of a notch. The eroded underlying areas are prone to caries formation (HARVEY, 1985).

Dental caries is caused by bacterial acid production. The caries contains bacteria and food debris and give off a characteristic odour. Enamel hypoplasia can be recognized by enamel defect in the form of points, spots and circumscribed areas, the exposed dentine has a rough surface and is yellowish brown. Plaque and tarter often develop at these places but caries is rare (EISENMENGER and ZETNER, 1985).

Dental calculus is commonly seen in the premolars as a hard deposit of calcium salts and organic material. The tarter is brown to black but may also contain forage pigments particularly the necks of the incisors are affected. Tarter does not cause any clinical sign, unless it involve the gingival border which cause gingivitis and seperation between the gum and tooth (OEHME and PRIER, 1976 and O'CONNOR, 1965).

Brachygnathism is a congenital deformity in which the upper jaw is longer than the lower one. This type of affection leads to elongation of the lower incisors and may cause injuries to the soft tissue above. On the other hand prognathism is characterized by elongation of the lower jaw than the upper one and inferior incisors extend beyond the superior. The condition occurs most commonly in the dog, but is seen occasionally in the horse (FRANK, 1964).

AFFECTIONS OF THE TEATH

MATERIAL and METHODS

In the present work 29 cases of large ruminants were submitted to the Vet. Clinic suffering from teeth affections. Some of them suffered from systemic disorders besides teeth affections. Before clinical examination, each affected animal recieved neuroplegic drug as Rompun in a dose rate of, 2 mg/kg body weight injected intramuscularly. All patient animals were thoroughly examined with special interest to the oral mucous membrane. The recorded cases of teeth affections were tabulated as show in table (1).

RESULTS

In the present study, there are different types of dental affections recorded in 29 cases of large ruminants (Table 1). Brown teeth (Porphyria) is one of the dental affections in cows. This type of affection is acquired and observed in the temporary and permanents incisors as grayish brown or grayish yellow deposit in labial or/and lingual surface (Fig. 1).

Diastasis dentium was recorded in incisors. The affection is characterized by a narrow space between two neighbour incisors. This space was filled with small pieces of food materials, which subsequently lead to fermentation of food deposit and produce some dental complications as gingivitis and dental caries (Fig. 2).

Rotation of the rostral teeth was observed in rare cases in cows and mainly affect the corner incisor of permanent teeth. The degree of rotation was about 90° in their alveoli (Fig. 3).

Enamel flecks were observed very rare in large ruminants. In the present study, one case was recorded in a cow. This affection was characterized by dark spot located on the labial surface of the left fourth (corner) incisors. The black discouring spots have some food debris and offensive odour, but their was no evidence of pain (Fig. 4).

Dental calculus is one of the most common acquired affection of the teeth. In this work it was found in the first (central) incisors in cows, mainly situated on the labial surface as a hard ring. The deposits were white to yellow-brown or black and they darken with age. The calculus is mostly located at the base of the crown encircling the neck of the tooth (Fig. 2).

Sharp enamel points is one of the developmental acquired affection of the teeth. It was observed in camels and cattle. The sharpeness is more evident in camels at the medial border of the lower cheek teeth. The food materials were collected between

the affected teeth and buccal mucous membrane. In some cases this affection was accompanied with injuries of the oral mucous membrane (Fig. 5).

In the present study some congenital abnormalities were recorded in the mouth of large ruminants. False polyodontia was observed in cows and it was characterized by presence of accessory tooth or teeth in addition to the normal number of the teeth (Fig. 6). In one cow there was one extra incisor situated in front of the deciduous teeth of the lower jaw (Fig. 6). The second case was characterized by two accessory teeth in a cow. They were erupted in front of the first incisors. The supranumerary teeth erupted from the labial surface of the gum, which showed slight hypergrowth of the gum around the accessory teeth. This type of dental abnormalities was accompanied with diastasis dentium.

Lastly elongation of the mandible (Prognathism) occurred in newly born calves. The characteristic symptoms were clear when the animal closed the oral commissure. The dental pad of the upper jaw was not resting over the lower incisors and may be accompanied with injuries (Fig. 7).

DISCUSSION

In the present study, the prevalent dental affections were recorded in cattle such as brown teeth (porphyria). This condition was characterized by discolouration of the teeth which may be greyish brown or greyish yellow deposit present on the labial or lingual surface of temporary or permanent incisors. The cause may be due to the distribution of pigmentation in dental layers of the teeth. This affection does not cause any clinical sign unless it becomes more extensive and involves the gingival border which leads to gingivitis and separation between the gum and the teeth, these results are in agreement with that obtained by (OEHME and PRIER, 1976 and HARVEY, 1985).

In the present investigation, diastasis dentium was observed as a space between incisor teeth in cattle. This condition was recorded in two forms. The first one was diastasis dentium with a wide space does not produce any clinical symptoms or complications to the teeth or gum. The second form was diastasis dentium with a narrow space which allows the entrapment of the food materials, thereby causing gingivitis and in some cases resulting in a breakdown of the periodontal membrane, these results are similar to that discussed by (AMIN and KASSEM, 1987) in horse and donkey and (MISK and HIFNY, 1982) in donkeys. Diastasis dentium which was observed here mainly affect the rostral teeth in cattle. While HARVEY (1985) stated that this type of dental affection is usually present as a space between the cheek teeth. The cause of diastasis dentium is not only due to congenital abnormalities or absence of one or more than

AFFECTIONS OF THE TEATH

one tooth, but it may be also due to rotation of the rostral teeth as the result of trauma or torsion during embryonic life.

In this work, rotation of the rostral teeth may be the first cause of diastasis dentium with a narrow interdental space in cattle. The degree of rotation was about 90-180° in the alveoli. This condition leads to impaction of the food materials or foreign bodies in the interdental space which cause gingivitis and alveolar periostitis (O'CONNOR, 1965). The problem appears to be a developmental anomaly in that there is usually no over-crowding, and it affects both members of the pair (HARVEY, 1985).

Enamel flecks were recorded in little cases of large ruminants. This affection is acquired and is characterized by presence of dark spots on the labial surface of the incisors. The affected animals have no inflammatory signs or pain (EISENMERGER and ZETNER, 1985). It has been suggested that the cause is a lack of the interprismatic layer or hypocalcification. This affection usually leads to dental caries (HARVEY, 1985).

Dental calculus (odontolithiasis) was found on the labial surface of the incisors in cows. It was characterized by a hard ring present at the base of the crown, encircling the neck of the tooth. The deposit was white to yellow brown and contain a hard deposit of calcium salts or organic materials. The deposit does not produce any inflammatory signs unless it involve the gum and alveoli which leads to gingivitis and seperation of the teeth (O'CONNOR, 1965). Meanwhile OEHME and PRIER (1976) recorded this disease affecting the premolar cheek teeth with the same characters.

Sharp enamel points were observed with little extent in large ruminants. The sharpness is more evident in camels at the medial border of the lower cheek teeth. These results were in agreement with that discussed by AMIN and KASSEM (1987) in horse and donkey and MISK and HIFNY (1982) in donkeys.

Developmental abnormalities of the teeth were recorded in rare cases such as false polyodontia. This congenital condition was temporary present in young aged animals, subsequently disappeared after shedding the deciduous incisors, (HARVEY, 1985).

Developmental abnormalities of the mandible were observed mainly in calves as mandibular prognathism (pig mouth). The condition is considered a serios defect in all ruminants because it may affect the apposition of the upper and lower cheek teeth or the contact of the rostral teeth with the dental pad impairing the ability to graze and masticate, (HARVEY, 1985).

REFERENCES

- Amin, M.E. and Kassem, M.M. (1987): Topographical anatomical studies on the teeth with special reference to some surgical affections in donkey and horse. *Assiut Vet. Med. J.*, Vol. 18, No. 35, 212-222.

Assiut Vet.Med.J., Vol. 26, No. 51, October 1991.

- Eisenmenger, E. and Zetner, K. (1985): Veterinary Dentistry, 1st Ed. Lea & Febiger, Philadelphia, USA.
- Frank, E.R. (1964): Veterinary Surgery 7th Ed. Burgess publishing company USA.
- Harvey, C.E. (1985): Veterinary Dentistry, 1st Ed. WB saunders company, Philadelphia, USA.
- Misk, N.A. and Hifny, A. (1982): Surgical affections of the teeth in donkeys of South Egypt. 14 Congress proceeding European Society. Surgery Istanbul - Turkey, 7-9 Sep., 165-187.
- O'Connor, J.J. (1965): Dollar's Veterinary Surgery 4th Ed. Bailliere, Tindall and Cox.
- Oehme, F.W. and Prier, J.E. (1976): Large Animal Surgery, 1st Ed. The Williams and Wilkins Com., Baltimore.

Table (1)

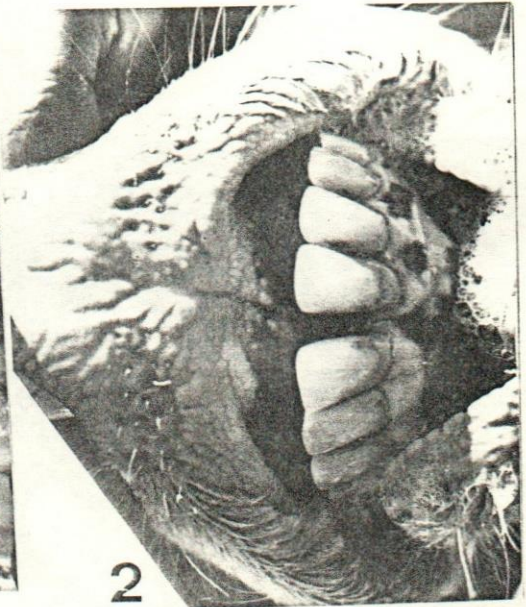
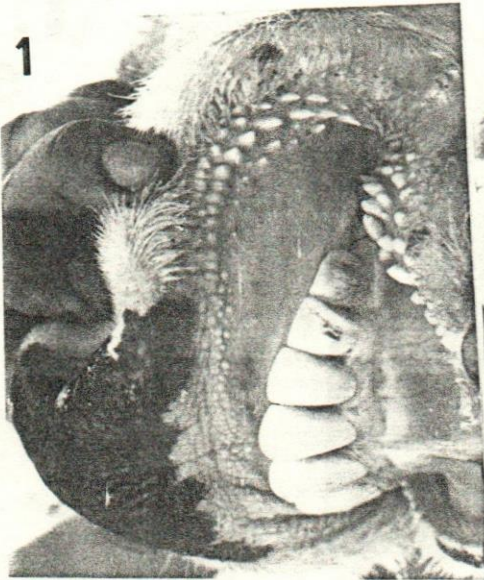Shows the number of cases suffering from
dental affections in large ruminants

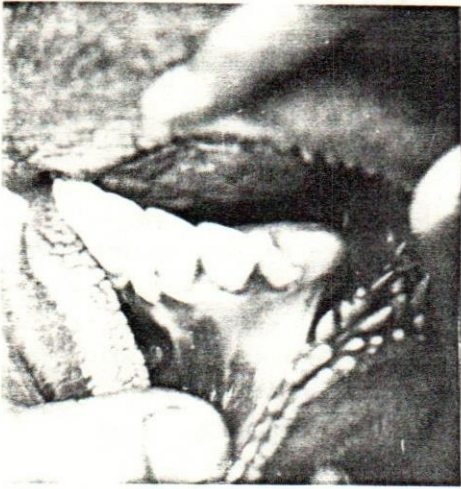Dental Affections	No. of Patient animals
Brown teeth (Porphyria)	8 cows
Diastasis dentium	6 cows
Rotation of the rostral teeth	5 cows
Enamel flecks	1 cow
Dental calculus	1 cow
Sharp enamel points	3 camels
False polyodontia	2 cows
Mandibular prognathism	3 calves
Total	29 animal

AFFECTIONS OF THE TEATH


LEGENDS TO ILLUSTRATIONS

- Fig. 1:** Brown teeth- presence of a patchy pigmentation of the labial surface of the 3rd and 4th rostral teeth.
- Fig. 2:** Diastasis dentium between central incisors. Dental calculus as a ring at the base of the crown in the rostral teeth.
- Fig. 3:** 90° rotation of the fourth temporal rostral tooth in one year old cow.
- Fig. 4:** Enamel flecks, small opaque spots in the enamel on the labial surface of the fourth rostral tooth.
- Fig. 5:** Sharp enamel points of the cheek teeth in camel.
- Fig. 6:** False polyodontia due to retained deciduous of second rostral tooth which leads to eruption of the perminant one infront of it, in a two years old cow.
- Fig. 7:** Mandibular prognathis in young calf. lower jaw is longer than upper one.

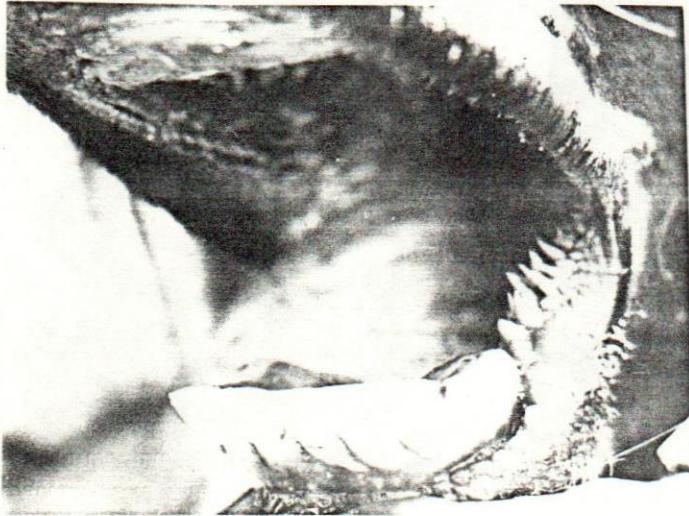



3



5



4

AFFECTIONS OF THE TEATH

