

Dept. of Zoology,
 Fac. of Science, Assiut University
 Head of Dept. Prof. Dr. E.G Youakim.

EFFECT OF HYPERVITAMINOSIS D ON SOME ORGANS OF THE ALBINO RAT

IV- THYROID AND PARATHYROID GLANDS

(With 35 Figures)

By

M.K. EL-NAFFAR; I.M. ANWAR; M.S. EL-HAWARY;

A.B. MAHMOUD and AMNA M. MOSTAFA

(Received at 28/10/1990)

تأثير زيادة فيتامين (د) على بعض أعضاء الفأر الأبيض
 ١- الغدة الدرقية وجار الدرقية

محمد النفار ، ابراهيم أنور ، مصباح الهواري ، عبدالله محمود ، آمنه مصطفى

تناول هذا البحث دراسة التأثيرات الهستولوجية والهستوكيميائية للجرعات المرتفعة من فيتامين (د) على الغدة الدرقية وجار الدرقية في الفئران البيضاء . وأظهرت الغدة الدرقية بعض التغيرات نتيجة الجرعات العالية من فيتامين (د) كالآتي: ظهرت الحويصلات الدرقية منتفخة وتغلطحت خلاياها الطلائية المبطنة وتحللت بعض الحويصلات وفقدت حدودها الخارجية . فقدت بعض الحويصلات شكلها المميز وضمت الخلايا الحويصلية وتحللت أنويتها . كما اتسعت بعض الأوعية الدموية ونقصت كمية الألياف الغروانية . بالإضافة إلى أن كمية المواد الكربوهيدراتية لم تتأثر في الغدة الدرقية المعاملة بينما ازداد المستوى البروتيني بها في الأطوار غير الناضجة وانخفض في الأطوار الناضجة . لم تظهر الغدة جار الدرقية في الأطوار غير الناضجة أي تغيرات هستولوجية أما الأطوار الناضجة فقد أوضحت عدة تغيرات منها : انكماش بعض الخلايا الرئيسية وضوم أنويتها وتحلل البعض الآخر مع فقدان شكلها المميز . كما ازدادت كمية الألياف الغروانية . ولم تظهر كمية الكربوهيدرات أي تغيير يذكر ، بينما ارتفع المحتوى البروتيني في هذه الغدة لعمر ١٤ يوما والأطوار الناضجة .

SUMMARY

The present work is concerned with the histological and histochemical effects of hypervitaminosis D on thyroid and parathyroid glands of the albino rats. The thyroid gland exhibits some variations due to hypervitaminosis D as follow: The follicles appeared swollen and their epithelial lining become flattened. Some follicles showed some degeneration in which the cells lost their boundaries. Some follicles lost their characteristic shape and the follicular cells are hypertrophied showing pyknotic nuclei. The blood vessels become wider. The quantity of collagenous fibers is decreased than the control. The amount of carbohydrates is not changed, but the protein level is increased in immature stages where it is decreased in adult ones.

With respect to the parathyroid gland of treated rats, the following results had been occurred: No changes could be observed in immature stages of

14-21, and 28-days. In adult rats of 97- and 111-days old, the following changes had been occurred: The chief cells are shrunk with deeply stained pyknotic nuclei. Some chief cells are degenerated and lost their characteristic pattern. The connective tissue septa separating the nests of chief cells are increased, and the amount of collagenous fibers is increased. The carbohydrate level is not affected, but the proteinic content is elevated in 14-days old and adult stages than normal.

INTRODUCTION

ISONO et al. (1977) studied the postnatal development of the parathyroid gland of mouse, while EMURA et al. (1984) studied the ultrastructure of parathyroid gland of golden hamster, and found some microscopical changes which related to age. ZABEL et al. (1987) studied the thyroid parafollicular cells in postnatal development of rats using an immunocytochemical methods.

KELLNER (1933) and POTVLIEGE (1962) pointed out that vitamin D decreases the volume of parathyroid glands in the fetus and mother rat. CHERTOW et al. (1975); GOLDEN et al. (1979) and VOIGTS et al. (1983) reported that parathyroid hormone level was decreased during calcitriol therapy in bovine parathyroid glands. However, OLDHAM et al. (1978) found a rise in PTH level after injection of calcitriol into vitamin D deficient dogs. The interaction between hypervitaminosis D and sterility of animals has been investigated by HAUCH (1934).

Few histochemical data were recorded on the effect of hypervitaminosis D on the organs. CHANG and HEGSTED (1964) and ARMBRECHT and WASSERMAN (1976) observed that the lactose (carbohydrates) elevates the passive absorption of calcium in the intestine. VOIGTS et al. (1983) stated that no data showing improvement in glucose metabolism with calcitriol therapy (vitamin D).

WASSERMAN and CORRADINO (1973) reported that the protein synthetic event was required for vitamin D action. The same authors added that the synthesis of rat intestinal protein is affected by vitamin D. UENG et al. (1979) found that the level of CaBP in the rat intestine is unaffected by treatment with vitamin D in pups one day postpartum.

The aim of the present work is to study the effect of hypervitaminosis D on the thyroid and parathyroid glands of postnatal rats.

MATERIAL and METHODS

Experiment 1:

Fifty-four immature rats of postnatal life were divided into six groups, each with 9 rats. Three groups of these animals which constitute the treated animals were daily injected intraperitoneally with vitamin D (Devarol-S) dissolved in sesame

VIT. D and THYROID & PARATHYROID

oil at a dosage of 0.2 ml (12,000 i.u.). This dose was administered for seven successive days to the rats of 7-, 14-, and 21-days old. The other three groups served as control. They were received the same dose of sesame oil only by a similar manner.

Experiment 2:

Thirty-six mature adult rats of 90-days old were divided into four groups, each of 9 rats. The first two groups were daily injected intraperitoneally with the vitamin D which dissolved in sesame oil at a dosage of 1 ml (60,000 i.u.). The doses were used for 7 successive days to one group and 21 successive days to the second group. The other two groups that served as the control groups were received the sesame oil only for 7 days and 21 days.

All the experimental and control rats were anaesthetized and dissected one day after the last injection. The thyroid and parathyroid glands were removed and immediately immersed in appropriate fixatives (Bouin's, formol-alcohol and 10% formalin) for histological and histochemical studies. All specimens were dehydrated in alcohols, then cleared in xylene, embedded in paraffin wax and sectioned at 5 μ m. thickness.

Some sections were stained with Harris' haematoxylin & eosin and Masson's trichrome stain (DRURY and WALLINGTON, 1980). Others were stained with PAS-reaction for carbohydrates (HOTCHKISS, 1948), while others were stained with bromophenol blue for general proteins (PEARSE, 1980).

RESULTS

A) Histological Changes :

Thyroid Glands Of Normal Rats :

1- Stage of 14-days old:

The thyroid gland consists of two lobes (Fig. 1). It is formed of thyroid follicles and interfollicular cells of different sizes and shapes, and covered by a thin connective tissue capsule. The gland is divided by fibrous septa into lobules. Each lobule consists of several follicles separated from each other by a thin layer of loose connective tissue. The follicles are the dominant structure of the gland. The thyroid follicle is rounded or oval in shape. Its wall consists of a single layer of epithelial cells. The lumen of the follicle is filled with colloid (Figs. 2 & 3). The colloid is amphoteric, staining with both acidic and basic dyes because it contains thyroglobulin (glycoprotein). The cells lining the follicle are of two kinds; the typical follicular epithelial cells and parafollicular cells. The follicular cells constitute the majority of the cells lining the follicle, and situated peripherally. They are low cuboidal, but when the follicle is filled with colloid, the follicular cells are flattened. The parafollicular cells are the minority, but are larger and paler than the follicular cells. They are vary in shape and have large pale nuclei. The nucleoli are prominent in some cells and not prominent in others. These cells have no colloid droplets. The parafollicular

cells are squeezed between the basement membrane and the follicular cells, but do not reach the lumen of the follicle. The interfollicular cells are masses of cells present inbetween the follicles. They are of the same size of follicular cells (Fig. 3). Moderate collagenous fibers are shown surrounding the follicles. The colloid material is deeply stained with Masson's trichrome stain (Fig. 2).

2- Stages of 21-and 28-days old:

The capsule is thicker. The follicles, follicular cells and interfollicular cells become more prominent (Figs. 4 & 5).

3- Stages of 97-and 111-days old (adult):

The thyroid glands of these stages are more developed representing the anatomical features of the adult stages (Fig. 6). It consists mainly of the previously described structure which includes capsule, thyroid follicles (follicular cells and para-follicular cells), interfollicular cells, connective tissue and blood vessels. The follicles are increased in size if compared to the previously described stages. The follicular cells are cuboidal in shape with clear rounded nuclei that having prominent deeply stained nucleoli. Some follicular cells are darkly stained and others are moderately stained. The para-follicular cells are faintly stained and slightly larger than the follicular cells with paler cytoplasm (Fig. 6). The quantity of collagenous fibers is concentrated around the thyroid follicles and blood vessels. The amount of colloid present in the follicular lumen is decreased than that of the previous stages. The amount of collagen content is relatively decreased than that of the previous stages (Fig. 7).

Thyroid Glands Of Treated Rats :

1- Stages of 14-and 21-days old:

The thyroid gland of the treated rats exhibits signs of inactivation. The follicles appeared dilated and the follicular cells become flattened. Some follicles showed some degeneration in which the cells lost their boundaries (Fig. 8). The collagenous fibers are unaffected.

2- Stage of 28-days old:

A slight histological changes are shown in the follicles. Wide spaces are seen in the intercellular connective tissue. Some follicles lost their characteristic shape and some follicular cells showed pyknotic nuclei (Fig. 9). The blood vessels are seen more wider and numerous (Fig. 10). The quantity of cellagenous fibers is decreased than that of the control group.

3- Stage of 97-days old:

The thyroid follicles showed certain degeneration and lost their characteristic pattern. The follicles have irregular follicular cells, containing pyknotic nuclei. Other

VIT. D and THYROID & PARATHYROID

follicles are swollen containing darkly stained clotted acidophilic material. Some follicular cells are hypertrophied (Fig. 11). The quantity of collagenous fibers in the connective tissue is lesser than that of the control but it is relatively high in the capsule (Fig. 12).

4- Stage of 111-days old:

The fully mature rats of 90-days old were injected as the previously treated stage, but for about 21 successive days until rats reaching the age of 111-days. The thyroid gland showed that the follicles are greatly swollen containing much colloid (Figs. 13 & 14). The follicular cells are degenerated. The parafollicular cells are increased in number, and cells lost their characteristic shape.

Parathyroid Glands Of Normal Rats :

1- Stage of 14-days old:

The parathyroid glands are embedded in the substance of the thyroid gland; one in each lobe (Fig. 1). The parathyroid gland is surrounded by a thin connective tissue capsule separating from the thyroid tissue (Fig. 2). It is composed entirely of closely packed sheets of undifferentiated chief cells as well as little fibrous stroma (Fig. 15). The cells of parathyroid gland are polyhedral, prismatic or cuboidal in shape, and the boundaries are ill-defined. The nuclei are not prominent. The cytoplasm is slightly eosinophilic and contains few vacuoles. Few darkly stained chief cells may be seen beside numerous lightly stained chief cells. Delicate septa of loose connective tissue fibers support the cellular parenchyma and contains few blood vessels (Fig. 15).

2- Stages of 21-and 28-days old:

The general structure of parathyroid gland of the present stages is nearly similar to the previously described stage of 14-days old, but here the gland is enlarged in size about two times, and the capsule is thicker. The glandular chief cells are arranged in cords separated by thin connective tissue septa (Figs. 4 & 16). Generally, the nuclear structure is delicately reticular, with a number of coarse chromatin particles (Fig. 16). Some blood vessels are situated near the capsule and connective tissue septa (Fig. 17). The quantity of collagenous fibers in the capsule is clearly increased. Also, there is a slight increase in the quantity of collagenous fibers between the glandular chief cells (Fig. 17).

3- Stages of 97-and 111-days old (adult):

These stages represent the fully mature adult where the parathyroid gland is enlarged in size and its cells are obviously differentiated (Fig. 7). The chief cells are arranged in clearly visible clumps or nests or irregular cords separated by connective tissue septa. These septa contain large blood vessels. The chief cells showed variation of stainability. Some of which is pale, however other cells stained darker.

The cell boundaries are more distinct. Their nuclei have peripheral chromatin material attached to the nuclear membrane (Fig. 18). The content of the collagenous fibers is decreased than that of the previous stages.

Parathyroid Glands Of Treated Rats :

1- Stages of 14-and 21-days old:

After 7 days from injection, the histological changes of 14 and 21-days old rats revealed that the capsule is slightly thicker but nothing more could be detected other than normal (Fig. 19).

2- Stage of 28-days old:

The present stage revealed that no histological changes could be seen.

3- Stage of 97-days old:

The parathyroid gland of the present stage revealed some changes where the cytoplasm of the chief cells is deeply stained. Some cells are shrunk with deeply stained pyknotic nuclei. The nests of chief cells become irregularly distributed (Fig. 20). The amount of collagenous fibers is slightly increased (Fig. 12).

4- Stage of 111-days old:

Atrophic changes could be observed due to functional depression of the parathyroid gland as a result of elevated blood calcium. Also, the histological changes that previously described in stage of 97-days old are observed in this stage. In addition, some cells showed degeneration and lost their characteristic pattern. The nuclei are pyknotic. The connective tissue septa that separating the nests of cells are increased. The capsule becomes thicker (Fig. 21 & 14). The quantity of the collagenous fibers is increased.

B) Histochemical Changes :

I- Carbohydrates :

Carbohydrates have been studied with the application of periodic acid-Schiff's reaction (PAS). The carbohydrate substances are stained in a red or magenta colour.

The Thyroid Gland :

The capsule of the thyroid gland; the boundaries of the thyroid follicles and the colloid material of stages 14,21- and 28-days old control rats are rich in carbohydrate content (Fig. 22). The constituents of the thyroid glands of stages 97-and 111-days old control rats contain less amount of carbohydrates than that described of the previous stages (Fig. 23).

After treatment with hypervitaminosis D, the thyroid gland constituents showed that the amount of carbohydrates is not changed than the control groups.

VIT. D and THYROID & PARATHYROID

The Parathyroid gland :

The capsule of parathyroid gland of all stages of control rats is rich in carbohydrate content. The connective tissue septa of 14-, 21-and 28-days old showed large amount of carbohydrates (Fig. 24). The cytoplasm of chief cells of 14-days old showed moderate amount of carbohydrates (Fig. 24). In 97-and 111-days old, the chief cells are faintly stained containing slight amount of carbohydrate (Fig. 25).

After treatment with large doses of vitamin D, all stages of rats showed that the carbohydrate content is similar to the control group and not affected by hypervitaminosis D.

II- General Proteins :

General proteins have been studied with the application of the bromophenol blue stain. The proteinic structures are stained in a bluish-green colour.

The Thyroid Gland :

The follicles of the control thyroid gland of 14-days old rat showed that the capsule and the colloid material contain moderate amount of protein but the follicular cells contain small amount of protein. The interfollicular cells and the interfollicular connective tissue showed no protein substances (Fig. 26). Stages of 21-and 28-days old showed a slight increase in the proteinic content in the all constituent of the thyroid gland (Fig. 27). In mature stages of 97-and 111-days old, the amount of protein is similar to that described in stages 21-and 28-days old.

After treatment with a high dose of vitamin-D, the interfollicular cells, the capsule, the follicular cells and the colloid of 14-days old showed a marked increase in the proteinic content (Fig. 28). The interfollicular cells revealed the presence of a slight amount of protein and are slightly similar to normal. The stages of 21-and 28-days old showed that the proteinic content is decreased than that of the control one (Fig.29). However, in adult stages of 97-and 111-days old, the level of protein is increased, similar to present in (Fig. 27).

Thus, as the result of hypervitaminosis D, the amount of proteins is increased in 14-d, decreased in 21-days old and increased in adult stages.

The Parathyroid Gland :

In 14-days old rats, the capsule contains a moderate amount of protein which is much larger than found in the chief cells that stained faintly. The connective tissue septa contain slight amount of protein (Fig. 30). In 21-and 28-days old, the proteinic content is slightly increased (Fig. 31). In mature stages of 97-and 111-days old, the proteinic substance of the connective tissue septa is increased, but the other constituents exhibit no changes other than that observed in 28-days old (Fig. 32).

After treatment with hypervitaminosis D, the proteinic contents in the capsule, connective tissue septa and the chief cells are increased in the stage of 14-days old.

The nuclear chromatins showed moderate amount of protein (Fig. 33). Stages of 21- and 28-days old showed no change in the proteinic content (Fig. 34). However, in adult stages the level of protein is markedly increased in the capsule, chief cells, and connective tissue septa (Fig. 35).

DISCUSSION

Hypervitaminosis D on the thyroid gland of rats showed some histological changes. The follicles are dilated while the follicular cells became flattened, and some of which are degenerated. STOLTENBERG (1929) found hypofunction of the thyroid gland in ricketic rabbit, with high cylindrical epithelium and a small quantity of colloid in the follicles. Excessive doses of vitamin D in the thyroid gland of adult stages result in appearance of degenerative features and hypertrophy of some follicular cells. This finding agrees with the result of SOROUR (1923) who described hypertrophy in the thyroid gland of rat in experimental rickets.

KAMEDA (1986) stated that, the thyroid gland of guinea pig contains small number of C-cell follicles in one month old, then increased gradually with age (29-months old). It is associated with a proliferative abnormality of intrafollicular C-cells, while the luminal colloid is PAS-positive. The present study showed a PAS-positive substance in the lumina of follicles, while the epithelial follicular cells are moderately stained and increased in size and number with age.

GAMSTEDT et al. (1986) studied the effects of B-methasone on serum thyroid hormone-binding proteins in Grave's disease. They found that, thyroxine-binding globulin is decreased, while thyroxine-binding prealbumin is increased in patients. In the present study, hypervitaminosis D revealed the increase of follicular colloid-containing protein in the experimental rats.

On treatment with hypervitaminosis D, the capsule of parathyroid gland of 14- and 21-days old as well as 111-days old became thicker, while parathyroid gland of 28-days old rats are not affected. The parathyroid gland may be affected in prolonged excess with vitamin D. The parathyroid glands of 97- and 111-days old rats revealed that some chief cells are shrunk with deeply stained pyknotic nuclei as well as the nests of chief cells became irregularly distributed. In young rats of 48- and 56-days old, DE ROBERTIS (1941) found that the cells of parathyroid glands are irregular in form and size. However, pyknotic nuclei were observed by ROTH (1962) in rats. In the parathyroid gland of 111-days old rats, the connective tissue septa separating the nests of cells and the amount of collagenous fibers are increased. This result is in agreement with the finding of DE ROBERTIS (1941) who reported that, the connective tissue strands seem to be thicker between the retracted trabeculae under the effect of parathyroid extract. In the present study, some cells showed degeneration. This result coincides with the finding of DE ROBERTIS (1941) who found degeneration involved the cytoplasm and nucleus.

KLEINER and ORTEN (1966) stated that administration of parathormone increases the phosphatase activity of the serum, which has an effect on carbohydrate metabolism in the tissues. Therefore, vitamin D has a good role on phosphate balance and on carbohydrate metabolism. Lactose exerts a rather striking favorable effect on the absorption of calcium in the rats. Lactose significantly increases calcium absorption when given orally. The parathyroid glands in the present study showed that the carbohydrate level is not affected.

INOUE and SETOGUTI (1986) and SHOUMURA et al. (1988) have observed large secretory granules in chief cells of parathyroid glands of mammals. These granules contain protein particles. SETOGUTI et al. (1981) have stated that, storage granules were released only as an emergency supply of parathyroid hormone. These granules indicate an increase in function of parathyroid gland. Our observations were in agreement with these results. ARPS et al. (1987) observed secretory proteinic granules (acidic glycoprotein) in bovine parathyroid glands. The present study showed little accumulation of protein in chief cells. It was suggested that, the protein is responsible for stabilization of parathyroid hormone within the secretory granules.

THANAKA et al. (1969) stated electron-microscopic studies on restitution of the rabbit parathyroid gland following vitamin D₂ administration. They found that, Golgi-complexes were significantly increased in number, and the cytoplasm has many secretory granules which indicates the release of parathyroid hormone. The present work showed little secretory granules of protein in the cytoplasm of chief cells in parathyroid gland of rats.

SILVER et al. (1986) stated that, 1,25-dihydroxychole-calciferol decreased the levels of parathyroid hormone-mRNA in the rats and came to the conclusion that, this vitamin D regulates parathyroid hormone gene transcription. The present work showed that vitamin D raised relatively the proteinic content and thus may represent the hormone picture. On the other hand, JAEGER et al. (1987) found that, the treatment of parathyroidectomized animals with parathormone caused hypercalcemia as well as increase of dihydroxyvitamin D in plasma.

REFERENCES

- Armbricht, H.J. and Wasserman, R.H. (1976): Enhancement of Ca⁺⁺ uptake by lactose in the rat small intestine. *J. Nutr.*, 106: 1265-1271.
- Arps, H.; Dietel, M.; Lauritzen, B.; Elting, J.J.; Niendorf, A. and Cohn, D.V. (1987): Co-localization of parathyroid hormone and secretory protein-1 in bovine parathyroid glands; A double immunocytochemical study at the electron microscopical level. *Bone Miner.*, 2(3): 175-184.
- Chang, Y.O. and Hegsted, D.M. (1964): Lactose and calcium transport in gut sacs. *J. Nutr.*, 82: 297-300.
- Chertow, B.S.; Baylink, D.J. and Wergedal, J.E. (1975): Decrease in serum immunoreactive parathyroid hormone secretion in vitro by 1,25-dihydroxycholecalciferol. *J. Clin. Invest.*, 56: 668-675.

VIT. D and THYROID & PARATHYROID

- De Robertis, E. (1941): The cytology of the parathyroid and thyroid glands of rats with experimental rickets. *Anat. Rec.*, 79(4): 417-433.
- Drury, R.A.B. and Wallington, E.A. (1980): CARLETON's Histological Technique. Oxford, University Press.
- Emura, S.; Shoumura, S. and Isono, H. (1984): Age-related changes in the ultrastructure of the parathyroid gland of the golden hamster. *Acta Sch. Med. Gifu*, 32: 636-662.
- Gamstedt, A.; Jarnerot, G.; Kagedal, B. and Tegler, L. (1986): Effects of beta-methasone on serum iodothyronines and thyroid hormone-binding proteins in Grave's disease. *Acta Med. (Scand.)*, 220(3): 237-240.
- Golden, D.; Maey, R. and Greenmalt, A. (1979): Vitamin-D: A direct effect on the parathyroid gland. *Min. Elec. Metab.*, 2: 721-723.
- Hauch, J.T. (1934): Viosterol toxicity. *J. Nutr.*, 8: 163.
- Hotchkiss, R.D. (1948): A microchemical reaction resulting in the staining of polysaccharide structures in fixed tissue preparations. *Arch. Bioch.*, 16(1): 131-142.
- Inoue, Y. and Setoguti, T. (1986): Immunocytochemical localization of parathormone in the mammalian parathyroid gland using the protein A gold technique. *Cell Tissue Res.*, 243: 3-7.
- Isono, H.; Miyake, K.; Shoumura, S. and Barnett, R.J. (1977): Electron-microscopic study on the postnatal development of the mouse parathyroid gland. *Arch. Histol. (Jap.)*, 40: 367-380.
- Jaeger, P.; Jones, W.; Kashgarian, M.; Baron, R.; Clemens, T.L.; Segre, G.V. and Hayslett, J.P. (1987): Animal model of primary hyperparathyroidism. *Am. J. Physiol.*, 252 (6 part 1): E 790- E 798.
- Kameda, Y. (1986): Age associated increase of C-cell follicles in guinea pig thyroid glands. *Anat. Rec.*, 216(2): 175-180.
- Kellner, B. (1933): Die Veränderung Weisser Ratten bei ver- W giftung mit bestrahltem frogsterin. *Virchows Arch. Path. Anat.*, 288: 491.
- Kleiner, I.S. and Orten, J.M. (1966): BIOCHEMISTRY, Seventh Edition. pp. 629-634, 777 & 801. The C.V. Mosby Company, Saint Louis.
- Oldham, S.B.; Smith, R. and Hartenbower, D.L. (1978): Effect of 1,25-dihydroxycholecalciferol on serum calcium, phosphate, and immunoreactive parathyroid hormone in dogs. *Adv. Exp. Med. Biol.* 103: 509-516.
- Pearse, A.G. (1980): Histochemistry; Theoretical and Applied. London, Churchill.
- Potvliege, P.R. (1962): Hypervitaminosis-D₂ in gravid rats. *Arch. Pathol.*, 73(5): 371-382.
- Roth, S.I. (1962): Pathology of parathyroids in hyperparathyroidism. *Arch. Pathol.*, 73: 75-88.
- Setoguti, T.; Inoue, Y. and Kato, K. (1981): Electron-microscopic studies on the relationship between the frequency of parathyroid storage granules and serum calcium levels in therat. *Cell Tissue Res.*, 219: 457-467.
- Shoumura, S.; Ishizaki, N.; Emura, S.; Iwasaki, Y.; Yamahira, T. and Isono, H. (1988): Immunocytochemical localization of parathyroid hormone in rabbit parathyroid glands. *Histol. Histopathol.*, 3: 93-95.
- Silver, J.; Naveh-Manny, T.; Mayer, H.; Schmeizer, H.J. and Popvtzer, M.M. (1986): Regulation by vitamin-D metabolites of parathyroid hormone gene transcription in vivo in the rat. *J. Clin. Invest.*, 78(5): 1296-1301.

- Sorour, M.F. (1923): Versuche über Einfluss von Nahrung Licht and bewegung auf Knochenentwicklung und endokrine Drüse Yunger Ratten mit besonder Berücksichtigung der Rachitis Beitrz. Path. Anat., 71: 407-481.
- Stoltenberg, L. (1929): Innersekretorische Drüsen bei Rachitis und spasmophilic Norsk. Mag. F. Laegeviden skapem. 90: 729-744.
- Tanaka, S.; Nakamura, K.; Chin, A. and Senga. I. (1969): Electron microscopic studies on restitution of the rabbit parathyroid gland following calcium and vitamin-D₂. Folia Endocrinol. (Jap.), 45: 566-567, 666-671.
- Ueng, T.H.; Colub, E.E. and Bronner, F. (1979): The effect of age and 1,25-dihydroxy-vitamin-D treatment on the intestinal calcium-binding protein of suckling rats. Arch. Biochem. Biophys., 196: 624-630.
- Voigts, A.L.; Felsenfeld, A.J. and Francisco, L. (1983): The effect of calciferol and its metabolites on patient with chronic renal failure. Arch. Intern. Med., 143: 1205-1211.
- Wasserman, R.H. and Corradino, R.A. (1973): Vitamins and Hormones. Academic Press, New York and London.
- Zabel, M.; Surdyk, J. and Biela-Jacek, I. (1987): Immunocytochemical studies on thyroid parafollicular cells in postnatal development of the rat. Acta Anat., 130(3): 251-256.

EXPLANATION OF FIGURES

BV= Blood Vessel, Ca= Capsule, CC= Chief Cell, Cd= Colloid, Fc= Follicular Cell, FI= Follicle, FS= Fibrous Stroma, IC= Interfollicular Cell, PC= Parafollicular Cell, PG= Parathyroid Gland, TG= Thyroid Gland, Tr= Trachea.

(Figures 1-35, photomicrographs of transverse sections of thyroid and parathyroid glands).

Figs. 1 & 2 & 3: Thyroid gland of 14-days old normal albino rats.

- 1- Stained with Hx & E., (X 125).
- 2- Stained with Masson's trichrome, (X 200).
- 3- An enlarged portion, stained with Hx & E. (X 800).

Fig. (4): Thyroid and parathyroid glands of 21-and 28-days old normal rats, stained with Hx & E. (X 125).

Fig. (5): An enlarged portion of thyroid gland of 21-days old normal rats, stained with Hx & E. (X 800).

Fig. (6): High-power magnification of thyroid follicles of adult stages (97- & 111-days old), stained with Hx & E. (X 800).

Fig. (7): Thyroid and parathyroid glands of adult normal rats (97- & 111-days old) stained with Masson's trichrome (X 200).

Figs. 8 & 9: Thyroid glands of treated rats, stained with Hx & E. (X 800).

- 8- Stages of 14-and 21-days old.
- 9- Stage of 28-days old.

VIT. D and THYROID & PARATHYROID

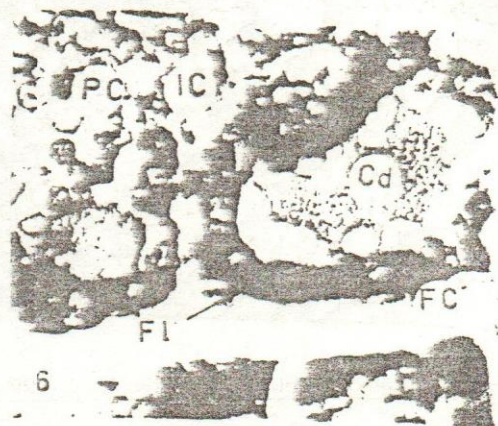
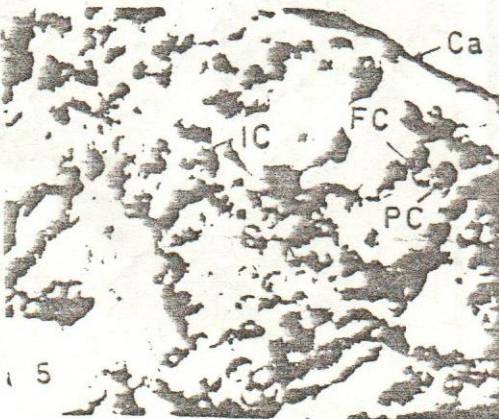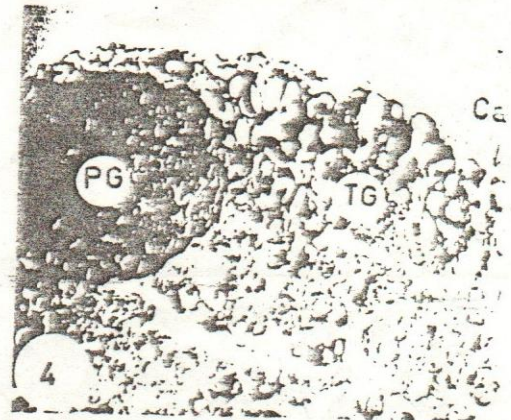
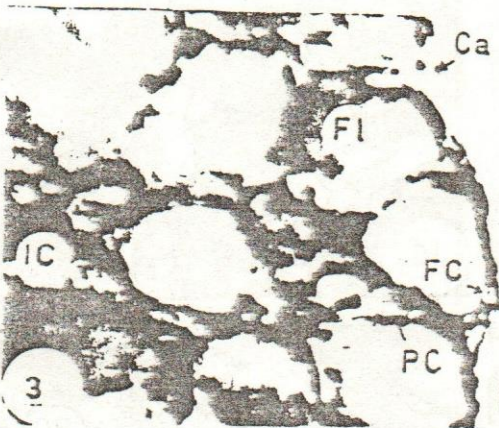

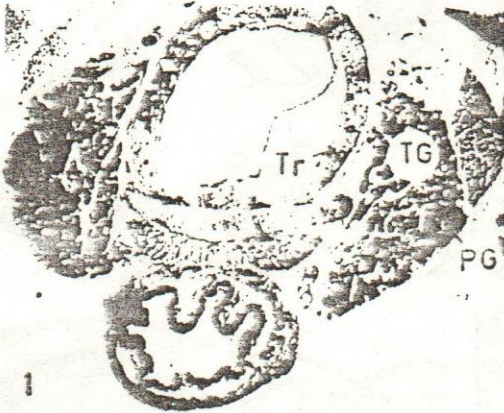- Fig. (10): Thyroid and parathyroid glands of treated rats (28-days old), stained with Masson's trichrome (X 200).
- Fig. (11): An enlarged portion of thyroid follicles of treated adult rats (97-days old), stained with Hx & E. (X 800).
- Fig. (12): Thyroid and parathyroid glands of treated adult rats (97-days old), stained with Masson's trichrome (X 200).
- Fig. (13): An enlarged portion of thyroid follicles of treated adult rats (111-days old), stained with Hx & E. (X 800).
- Fig. (14): Thyroid and parathyroid glands of treated adult rats (111-days old), stained with Masson's trichrome (X 200).
- Figs. 15 & 16: Parathyroid glands of normal rats, stained with Hx & E. (X 800).
 15- Stage of 14-days old.
 16- Stages of 21-and 28-days old.
- Fig. (17): Thyroid and parathyroid glands of normal rats (21- & 28-days old) stained with Masson's trichrome (X 200).
- Fig. (18): Parathyroid gland of normal adult rats (97- & 111-days old) stained with Hx & E. (X 800).
- Figs. 19 - 21: Parathyroid glands of treated rats, stained with Hx & E. (X 800).
 19- Stages of 14- & 21-days old.
 20- Stage of 97-days old.
 21- Stage of 111-days old.
- Figs. 22 & 23: Thyroid glands of normal rats, stained with PAS- reaction (X 640).
 22- Stages of 14- & 21- and 28-days old.
 23- Stages of 97- & 111-days old.
- Figs. 24 & 25: Parathyroid glands of normal rats, stained with PAS-reaction (X 640).
 24- Stages of 14- & 21- and 28-days old.
 25- Stages of 97- & 111-days old.
- Figs. 26 & 27: Thyroid glands of normal rats, stained with bromophenol blue (X 640).
 26- Stage of 14-days old.
 27- Stages of 21- & 28-days old.
- Fig. 28 & 29: Thyroid glands of treated rats, stained with bromophenol blue (X 640).
 28- Stage of 14-days old.
 29- Stages of 21- & 28-days old.
- Figs. 30-32: Parathyroid glands of normal rats, stained with bromophenol blue (X 640).
 30- Stage of 14-days old.
 31- Stages of 21- & 28-days old.
 32- Stages of 97- & 111-days old.

Figs. 33-35: Parathyroid glands of treated rats, stained with bromophenol blue (X 640).

33- Stage of 14-days old.

34- Stages of 21- & 28-days old.

35- Stages of 97- & 111-days old.



VIT. D and THYROID & PARATHYROID

