

Dept. of Theriogenology,
Faculty of Vet. Med., Assiut University,
Head of Dept. Prof. Dr. M. Abdel-Raouf.

THE CLINICAL PICTURE OF MYCOTIC ABORTION IN BUFFALO-COWS (With 4 Figs.)

By
A.H. ZAGHLOUL and S.H. SHEHATA
(Received at 21/3/1991)

الصورة الاكلينيكية للاجهاض الفطري في الجاموس
أحمد زغلول ، شحاتة حسن

شمل البحث دراسة الصورة الاكلينيكية للاجهاض نتيجة الاصابة المشتركة بكل من فطر الاسبرجيلس فيوميجيتس والكربتوكوكسي نيوفورمنس في قطيع مكون من ٥٥ عجلة جاموس عشار. وقد تبين وجود الأعطاب الجلدية المميزة (التهاب الجلد الفطري) في عدد ثلاثة من بين عدد ٧ أجنة مجهزة (٢٨,٥٧%) تم فحصها، كما لوحظ وجود التهاب واضح بالشيمة في كل الحالات التي تم فحصها. كما أمكن توضيح كل من الفطرين المذكورين في السحات المصبوغة والتي تم عملها من كلا من محتويات معدة الأجنة المجهزة وكذا السحات الشيمية وأمكن أيضا عزل كلا من الفطرين بعمل مزارع من محتويات معدة الأجنة المجهزة والرشتين والكبد الخاصة بتلك الأجنة. كما إسر الفحص الهستوباثولوجي للانسجة الجنينية عن وجود تجمعات من فطر الكربتوكوكسي نيوفورمنس داخل الجيوب الدموية للكبد. هذا بالإضافة الى أن كلا من الفحص البكتريولوجي والفحص السيولوجي للعينات التي تم فحصها من تلك الحالات لم يسفرا عن وجود أية مسببات للاجهاض غير هذين الفطرين.

SUMMARY

The clinical picture of abortion due to a combined infection by *Aspergillus fumigatus* and *Cryptococcus neoformans* among a herd of 55 pregnant buffalo-heifers was investigated. Characteristic skin lesions (mycotic dermatitis) were detected on 2 out of 7 (28.57%) examined aborted fetuses. Mycotic placentitis was observed in all collected placentae. Both fungi were detected in stained smears from foetal stomach contents (F.S.C) of aborted fetuses, as well as placental smears. Both fungi were also recovered on culture from F.S.C., foetal lungs and foetal liver. Histopathological examination of aborted foetal tissues revealed the presence of clumps of *Cryptococcus neoformans* fungus in the sinusoids of foetal livers. Bacteriological and serological examinations failed to demonstrate other causes of abortion among those animals.

INTRODUCTION

The most important and economically significant mycotic syndromes recognized among food animals, primarily bovine abortion and mastitis, can be caused by a variety of fungal agents (BIBERSTEIN, 1986). He added that while less than 40% of all abortions in cattle can be associated with an infectious agents, fungal agents are blamed for 2 to 30% of this total. WILLIAMS, *et al.* (1977) recorded that fungal infection was accounted for 13.4 to 24.9% of all abortions investigated annually in a large area of southern England between 1959 and 1966. AINSWORTH and AUSTWICK (1973); WILLIAMS, *et al.* (1977); WATSON (1979); HIGGINS, *et al.* (1981); PEPIN (1983); KROGH (1985) and BIBERSTEIN (1986) revealed that a wide variety of fungal species have been implicated in cases of mycotic abortion. *Aspergillus fumigatus* accounts for about two thirds or more of these abortions. It is followed in frequency by the zygomycotic fungi, including *Mucor*, *Rhizopus*, *Mortierella* and *Absidia*. They added that a low percentage of abortions were due to yeast - like fungi. WATSON (1979) and BIBERSTEIN (1986) reported that in the majority of cases of mycotic abortion, no general illness is present in the aborting cow, although mycotic pneumonia associating abortion is not uncommon. They added that the aborted foetus may be grossly normal, but a variable percentage (2 to 26%) have ring worm-like skin lesions, which are most frequently seen in the head and neck region, back and sides. AINSWORTH and AUSTWICK (1973); STUKER, *et al.* (1979); GALVITS, *et al.* (1982); KIRKBRIDGE (1985) and BIBERSTEIN (1986) described the characteristic gross and histological foetal and placental lesions, in cases of mycotic abortion.

The present work was carried out for the investigation of an abortion outbreak among a herd of pregnant buffalo-heifers kept at one of the dairy farms belonging to Assiut Governorate.

MATERIAL and METHODS

The investigated herd included 55 pregnant buffalo-heifers that were kept apart from the rest of the mother dairy herd, however, all animals of the herd were receiving the same ration and the same management. Over the course of 2 months period (April and May 1990), 25 animals aborted at different stages of pregnancy ranging from 4th to the 10th Month. Seven aborted fetuses together with their placentae, were collected directly after abortion and subjected to the following examinations:

1 - Aborted fetuses:

Each aborted foetus was examined for the presence of any gross post mortem lesions as skin lesions, oedema, emphysema, meconium- staining and was then necrops-

MYCOTIC ABORTION IN BUFFALOES

ied. The gross picture of both the thoracic and the abdominal viscera was recorded. Foetal stomach contents (F.S.C) were collected aseptically into sterile screw-capped bottle and few drops were examined microscopically for the presence of any motile microorganisms or fungal hyphae. Smears were also made from F.S.C., allowed to dry in air, fixed by heat and stained by Gram's and Modified Ziehl-Neelsen stains for demonstration of any specific abortifacient microorganisms. Parts from foetal liver, lungs and spleen were collected with maximum aseptic precautions and taken to the laboratory, where cultures were made from them together with F.S.C. onto blood agar and Sabouraud's glucose peptone agar plates. Incubation of these plates was carried out at 37°C for 72 hours both aerobically and at microaerophilic atmosphere. Isolates were identified both morphologically and biochemically.

II- Placentae:

Each collected placenta was examined grossly for the presence of necrosis, thickening and/or any characteristic lesions. Placental smears were made, dried, fixed, stained and examined microscopically for the presence of any specific microorganisms or fungal hyphae.

Moreover, small pieces from foetal liver, lungs, spleen and placenta were collected in jars containing 10% buffered formalin. In the laboratory, specimens were processed for paraffin embedding. Sections were cut and stained with H&E and PAS- reaction for detection of any changes in these organs according to the techniques of DRURY and WALLINGTON (1980).

III- Blood:

Blood samples were collected from all aborted animals two weeks after abortion. In the laboratory, serum was separated, clarified and subjected to serological examination using the Rose Bengal plate agglutination test (RBPT) for detection of specific antibodies against *Brucella abortus*, following the techniques of MORGAN, et al. (1978).

RESULTS

I - Aborted foetuses:

The gross post mortem examination of the aborted foetuses revealed the presence of the characteristic skin lesions of mycotic infection (mycotic dermatitis) on two foetuses of them (Photograph 1). Those two foetuses were aborted at about the 7th month of gestation. Blood-tinged fluid was observed, in large amounts, in both the thoracic and the abdominal cavities of these foetuses. Moreover, the heart was flabby, the liver was friable and the kidney was remarkably soft.

The microscopic examination of the stained smears made from F.S.C. revealed the presence of yeast-like fungi *Cryptococcus neoformans* (photomicrograph 2) together with some hyphae of *Aspergillus* species, which were furtherly identified as *Aspergillus fumigatus*.

The two types of fungi were recovered in the cultured Sabouraud's agar plates from F.S.C., foetal lungs and foetal liver. The isolated fungi were identified both morphologically and biochemically according to the techniques described by RIPPON (1988). On the other hand, no growth was observed on the inoculated blood agar plates incubated either aerobically or at microaerophilic atmosphere.

II- Placentae:

The examined placentae of aborting animals showed the Characteristic gross lesions of mycotic infection including thickened, brown and leathery allantochorion, together with swollen, necrotic cotyledons having a grey necrotic centre and red prephary (Photograph 3). Moreover, the microscopic examination of the stained placental smears, revealed the presence of both fungi demonstrated in F.S.C. On the other hand, the histological examination of the stained sections of foetal tissues, resulted in the detection of the yeast-like fungus as clumps in the sinusoides of foetal liver (Photomicrograph 4).

III- Blood:

The serological examination of the blood samples of the aborting buffalo cows showed that they were negative to *Brucella abortus* antibodies.

DISCUSSION

Abortions in cattle are frequently the results of an event that occurred weeks or months earlier and the cause, if it was ever present in the conceptus, is often difficult to detect by the time of abortion (GOODWIN, 1986). In the present work, the observed gross Post mortem skin lesions on two of the seven (28.57%) collected fetuses are similar to those previously recorded by WATSON (1979) and BIBERSTEIN (1986) who stated that a variable percentage (2 to 25%) of aborted fetuses, due to mycotic causes, have these characteristic lesions. Moreover, the detection of both of yeast-like fungi (*Cryptococcus neoformans*) and *Aspergillus fumigatus* in stained smears of F.S.C. and their recovery on culture from F.S.C., foetal lungs and foetal liver, together with the observed characteristic Post mortem lesions, can be considered as a confirmation for the involvement of these fungi in the induction of abortion among those pregnant buffalo-heifers. The failure of recovery of any other microorganisms on blood agar cultured plates from the same material is a further support

MYCOTIC ABORTION IN BUFFALOES

to the above mentioned conclusion. These findings are in agreement with those previously observed by AINSWORTH and AUSTWICK (1973); WILLIAMS, et al. (1977); WATSON (1979); PEPIN (1983); PAL, et al. (1985); SHERIDAN, et al. (1985) and BIBERSTEIN (1986) who revealed that *Aspergillus* species is responsible for about two thirds of mycotic abortions and that a low percentage of these abortions are due to yeast-like fungi. BIBERSTEIN (1986) added that *Cryptococcus neoformans* fungus is ordinarily has a saprophytic existence in the soil and its growth being enhanced by bird faeces, especially pigeon. He also revealed that multiple infections with *Aspergillus* combined with yeast-like fungi or *Zygomycetes* have been repeatedly observed. Meanwhile, RYAN and WYAND (1981) recorded that *Cryptococcus* species was detected as the main cause of abortion in two pregnant mares. The observed placental lesions of the examined placentae are identical to those previously described by STUKER, et al. (1979) WATSON (1979); GALVITS, et al. (1982) KIRKBRIDGE (1985); BIBERSTEIN (1986) and ACLAND (1988).

Moreover, the presence of the yeast-like fungus as clumps in the sinusoids of foetal liver is an indication of the occurrence of systemic mycosis and the incrimination of these fungi in the foetal deaths and abortions. On the other hand, the absence of specific antibodies against *Brucella abortus* in the sera of the aborting animals confirmed that this organism was not involved in the induction of abortion among those buffalo-heifers. Finally, it can be concluded that observed clinical picture, including the gross skin lesions on aborted foetuses, gross placental lesions, the direct demonstration of both fungi in F.S.C. and their recovery from cultured materials, together with the failure of isolation of other microorganisms and absence of specific antibodies from the sera of those animals, gave a good deal for the attribution of abortion among those buffalo-heifers to both detected fungi.

ACKNOWLEDGEMENT

The kind and sincere help of Professor A. Nafady of Department of Veterinary Pathology, Assiut University, is highly appreciated.

REFERENCES

- Acland, Helen M. (1988): Female reproductive system. pp. 623-648 in "Special Veterinary Pathology. Edited by Thomson, R.G.; B.C. Decker Inc., Toronto and Philadelphia.
- Ainsworth, G.C. and Austwick, P.K.C. (1973): Fungal Diseases of Animals. 2nd Ed., Farnham, Royal: CAB.

- Biberstein, E.L. (1986): Systemic mycosis. In "Current Veterinary Therapy" p. 611-619, 1st Ed. Edited by J.L. Howard, Saunders Comp. Philadelphia.
- Drury, R.A.B. and Wallington, E.A. (1980): Carleton's Histological Technique. 5th Ed. Oxford Univ. Press, Oxford.
- Galvits, R.; Rady, M. and Bucsek, M.J. (1982): Morphological studies on the immune system of Cattle 11. Histological changes in fetuses from cases of abortion caused by chlamydia, *Corynebacterium* and fungi. Magyar Allatorvosok Lapja 37 (10): 669-674. (Vet. Bull. 1983, Abst. 2684).
- Goodwin, D.E. (1986): Abortion: An approach to diagnosis, p. 729-797. In "Current Veterinary Therapy", 1st Ed. Edited by J.L. Howard, Saunders Comp., Philadelphia.
- Higgins, R.; Hoquet, F.; Marsolais, G.; Montpetit, C.; El-Azhary, Y.; Morin, M.; Bois, J.M. and Ethiers, R. (1981): Diagnosis of infectious abortions in dairy cattle. Canad. J. Comp. Med., 45 (2): 159-166.
- Kirkbridge, C.A. (1985): Mycotic abortion. p. 147-161, in "Laboratory Diagnosis of Abortion. In food Animals "Edited by C.A. Kirkbride, Madison, Wisconsin, U.S.A. 1st Ed.
- Krogh, H.V. (1985): Bovine mycotic abortion in Denmark. Nordisk Vet. Med., 37 (1): 27-33.
- Morgan, W.J.B.; Mackinnon, D.J.; Gill, K.P.W.; Gower, S.G.M. and Norris, P.L.W. (1978): Brucellosis Diagnosis: Standard laboratory techniques. 2nd Ed. Published by MAFF, London.
- Pal, M.; Mehrotra, B.S. and Dahiya, S.M. (1985): Studies on mycotic abortion caused by *Aspergillus fumigatus* fresenius. Ind. J. Anim. Reprod., 6 (1): 43-48.
- Pepin, G.A. (1983): Bovine mycotic abortion. Vet. Annual 23: 79-90.
- Rippon, J.W. (1988): Medical Mycology. 3rd Ed. p. 599-609. Saunders comp., Philadelphia.
- Ryan, M.J. and Wyand, D.S. (1981): *Cryptococcus* as a cause of neonatal pneumonia and abortion in two horses. Vet. Pathology, 18 (2): 270-272.
- Sheridan, J.J.; White, D.S.C. and McGarvie, G.D. (1985): The occurrence of and organisms concerned with bovine mycotic abortion in some countries of Ireland. Vet. Res. Commun. 9 (3): 221-226.
- Stuker, G.; Ehrensperger, F.; Pohlenz, J. and Troll, C. (1979): Significance and diagnosis of mycotic abortion in cattle (in Switzerland). Zentralblatt für Vet. Med., 268 (3): 184-194.
- Watson, W.A. (1979): Other infectious diseases. pp. 199-244, in "Fertility and Infertility In domestic Animals", 3rd Ed. by J.A. Laing, Bailliere Tindall, London.
- Williams, B.M.; Shreeve, B.J.; Herbesrt, C.N. and Swire, P.W. (1977): Bovine mycotic abortion: Some epidemiological aspects. Vet. Rec., 100: 382-385.

MYCOTIC ABORTION IN BUFFALOES

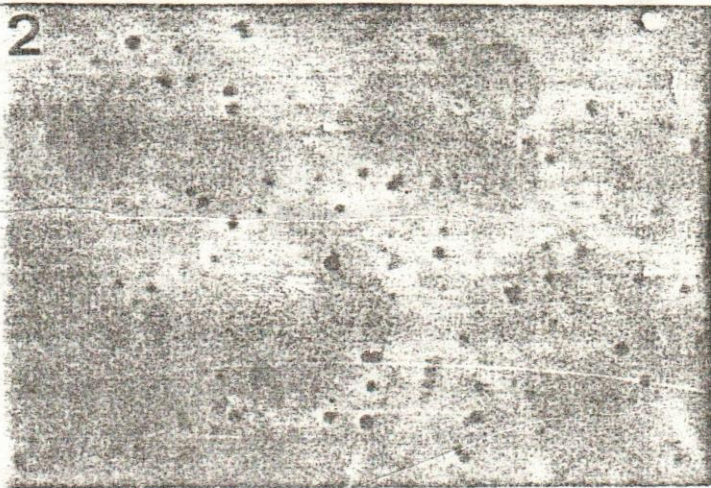



Fig. (1): Mycotic dermatitis on face and side of aborted buffalo-foetus.

Fig. (2): Yeast-like fungus (*Cryptococcus neoformans*) as budding spherical cells in stained smears of F.S.C. (X 500).

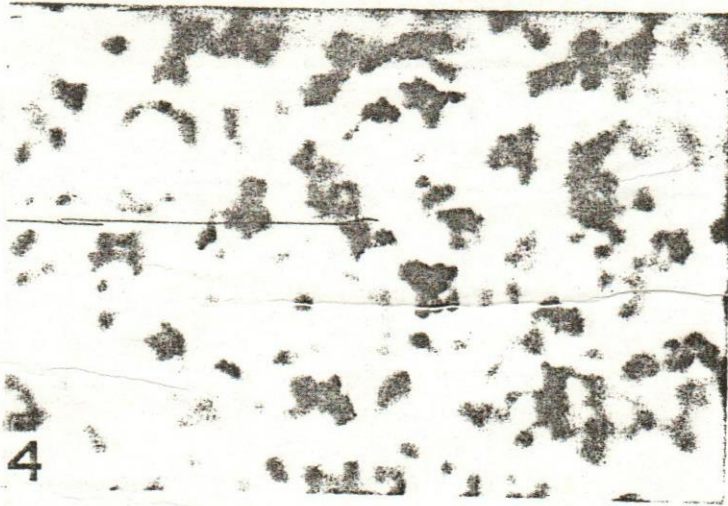



Fig. (3): Placental cotyledon showing characteristic mycotic placentitis with grey centre and red prephary.

Fig. (4): Clumps of *Cryptococcus neoformans* fungus in sinusoids of foetal liver (X500).