

Dept. of Animal Medicine,
Faculty of Vet. Med., Assiut University,
Head of Dept. Prof. Dr. M.F. Raghib.

ANGIOGRAPHIC AND RADIOGRAPHIC PICTURE OF MANUS AND PES IN GOATS II FLUOROSIS (With 5 Figs.)

By

A.SH. SEDDEK; M.A. ALI* and M.A. ALAM EL-DIN**

(Received at 28/10/1990)

صور أشعة الأوعية الدموية في أرجل الساعين
٢- التسم المزمن بالفلورين

عبد اللطيف شاكر ، محمد عادل ، محمد علم الدين

أُجرى هذا البحث على ثلاثين ماعز متفاوتة الأعمار بين ٢ - ٣ شهور و ٢ - ٤ سنوات والتي ترمى بمنطقة التلوث بالفلورين. وتم فحص الحيوانات اكلينيكيًا ومعلبيًا واشعاعيًا للتأكد من تسمها بالفلورين. ولقد حقنت شرايين الأرجل الأمامية والخلفية بالصبغة للتعرف على التغيرات التي تحدث في الأوعية الدموية والمصاحبة لتسم الفلورين. وقد أشارت النتائج الى تباين التأثير على الأوعية الدموية من حيث كثرتها في بعض الأحوال أو ضيقها أو وجودها معًا مما يدل على أن هناك ارتباط وثيق بين تأثير الفلورين على الأوعية الدموية وآفات العظام فتظهر على هيئة بروتات عظمية أو تآكل العظام وذوبانها فيظهر في صورة ضمور للعظم ووجود خويصلات داخل النسيج العظمي.

SUMMARY

This work was carried out on 30 goats aged between 2-3 months and 3-4 years rearing on an endemic fluorosed area. The clinical, laboratory examination were done to ensure that the animals were fluorosed. The radiological examination was carried out to declare the effect of fluorosis on the angiographic picture of the limbs in these animals. The angiographic examination was made by injection of the contrast media through the median and femoral arteries. The affected limbs showed hypervascularization which represented by dilatation of the blood vessels as in the A.digitalis communis III, newly formed as those which appear in the exostotic bones as well as tortuous blood vessels as shown in the A.digitalis plantaris communis II and or sclerotic changes in the blood vessels which observed in the A.metatarsa dorsalis III, A.Digitalis communis II and V. cephalica. The bony changes were represented as bony exostosis, sclerosis and osteoporosis with cyst formation.

* Dept. of Surgery, Faculty of Vet. Medicine, Assiut University.

** Dept. of Anatomy, Faculty of Vet. Medicine, Assiut University.

A.SH. SEDDEK, et al.

INTRODUCTION

Endemic fluorosis is a chronic fluorine intoxication had been found in certain parts of the world. The main important clinical changes of fluorosis were recorded in teeth and skeleton by ROHOLM (1937), SHUPE, et al. (1963), RAMBERG and OLSSON (1970) and SEDDEK (1988).

The radiographic changes of bone accompanying fluorosis in cattle appears as an increase in bone density, abnormal porosity, thickening of endosteum and periosteum and mineralisation of attachments of tendons to bones (SHUPE, et al. 1963). The distribution of fluorine in body fluids and soft tissues such as blood plasma, heart, liver, kidney, spleen, thyroid and aorta is reviewed by ARMSTRONG and SINGER (1962).

The fluoride present in a calcified plaques in blood vessels is like that of skeletal tissues and urinary calculi (HERMAN, et al. 1958). SMITH, et al. (1960) found that the fluoride content of the aorta is higher than that of other soft tissues and accompanied by a degree of arteriosclerosis and calcifications.

The angiography of the foot of horse was described by COLLES, et al. (1979) who mentioned that, how some aspects of the vascular anatomy may predispose to pathological condition.

The lack of available literature concerning the angiographic changes on the limbs of goat in cases of fluorosis, encouraged us to study the effect of endemic fluorosis on the blood vessels of the limbs in goats.

MATERIAL and METHODS

In the present study thirty native breed goats varying in ages between 2-3 months and 3-4 years old were selected from an endemic fluorosed area about 1/2 km south of a superphosphate factory at Manquabad, Assiut province. All investigated animals showed a bad health condition and were suffering from dental lesions as well as palpable bony exostosis in the thoracic and pelvic limbs.

Blood samples were obtained from the external jugular vein and spontaneous urine samples, were collected for estimation of fluorine level which were determined according to FRY and TAVES (1970).

All angiographs were performed while the animals were anaesthetized with I.M. injection of xylazine hydrochloride 2% (Bayer) in a dose of 0.5 mg/kg b.wt. The seats of canulation in median and femoral arteries were shaved and disinfected for aseptic surgical exposure. The arteries were canulated with a sterile braunula

ANGIOGRAPHIC CHANGES IN FLUOROSIS

18 G (Art. No. 420753/0 luer, Braun Nelsungen AG, West Germany). The Urografin 58% (Fa. Schering, Berlin) in a dose of 10-15 ml was used as a contrast media, administered through an record syringe into the artery. The radiographs were taken just after the end of injection. The values used were 55 Kv, 5 mAs at a 90 cm focal film distance by a mobile x-ray unit. After withdrawal of the canula, haemorrhage was arrested by digital pressure and the skin was sutured with silk No. 1 in a simple interrupted manner.

The nomenclature of the blood vessels described in the present work was that adopted by N.A.V. (1983).

RESULTS

Clinical examination:

16 goats, 3-4 years old, showed dental changes such as pitting, staining, wearing and chalky teeth. The exostotic projections in the mandible, long bones and in sporadic ribs were observed. The young examined 14 animals (2-3 months old) showed neither dental nor skeletal changes except one showed mandibular irregularity.

Serum analysis for fluoride contents revealed 0.941 ± 0.40 ppm in old animals and the level reached 0.631 ± 0.141 ppm in young ones.

Urine analysis of these animals revealed 46.56 ± 9.13 ppm in old animals and in young ones the values reached 10.68 ± 2.50 ppm.

Radiological findings:

In adult animals the radiographs revealed that there were two types of bony changes related to fluorosis, the first represented as increased density and thickening of the compact bone with narrowing of the medullary cavity. The second type of bony changes were represented as osteoporosis, bone resorption and cystic lesions inside the compact bones. The bony exostosis appeared in radius and ulna, large metacarpal, tibia and large metatarsal, as well as in phalanges.

The judgment of the angiographic changes was based upon the comparison with normal angiographic picture described by ALI and ABDEL MONIEM (1990). The main changes associating fluorosis were confined in hypervascularity and sclerosis. The hypervascularity was represented in angiographic picture as a dilatation of some blood vessels such as A.digitalis communis III (Fig. 1), newly formed blood vessels supplying the bony exostosis (Fig. 1 & 2) and tortious appearance of the vessels as the A.digitalis plantaris communis II (Fig. 2 & 3 A). The sclerosed vessels appeared faint such as A.metatarsae dorsalis III, A.digitalis plantaris communis II and V. cephalica (Fig. 2-5). In these cases the injection was faced by a resistance which gave a

false impression that the vessels are completely filled with the contrast media. Meanwhile the angiographic picture revealed that the substance did not reach in sufficient amount to the distal parts of the limbs.

The sclerosis of the blood vessels may lead to the decrease in blood supply of the digit. This may result in deformity of the digits (Fig. 4 A & B).

In young animals nothing was observed in the radiographs either in the bones or in the blood vessels of the limbs.

DISCUSSION

The blood and urine analysis for fluorides revealed a recent exposure of an endemic fluorosis. The levels reached more than 0.5 ppm in blood indicating a chronic exposure to high concentration of fluorides (GREENWOOD, *et al.* 1964). The analysis of urine revealed also a recent exposure to fluorides where the levels were more than 8 ppm (SPENCER, 1917).

The effect of fluorine on the skeletal system of both humans and animals was illustrated by FRANK (1979) as four distinct pathological conditions namely, osteosclerosis in humans, Osteomalacia in humans and animals, secondary parathyroidism in humans and sheep and osteoporosis in rats. The results in this study agree with the aforementioned findings. The effect of fluorides in high doses was recorded as a cause of osteomalacia and porosis in growing animals with great demand for calcium whereas in low levels lead to osteosclerosis (ROHOLM, 1937). The exostotic foci refers to the stimulation of osteoblast cells by low doses. This induce a new bone formation especially at the periostium, where fibrous bone later becomes lamellar bone (SEDDEK, 1988).

The skeletal changes were restricted in adult animals while the young ones showed no considerable observable changes. The recorded lesions were identical to that observed by GRÜNDER (1972) CORREA, *et al.* (1986) and SEDDEK (1988). The hypervascularisation of blood vessels could be referred to the direct effect of fluorine on the intima of blood vessels. This leading to its hyperactivity firstly and by long duration the endothelium may be deteriorated followed by atrophic changes in the walls of blood vessels permitting the osteosclerotic changes to be included (CARLSON and SUTTIE, 1967). HAYTHORN and TAYLOR (1936) showed that the concentration of calcium in human aorta increases in a regular linear fashion with increasing age. It might be expected that the association of fluorides with calcification could be attributed recurrently to age (FRANK, *et al.* 1960).

ANGIOGRAPHIC CHANGES IN FLUOROSIS

The problems of fluoride transport to different areas of bones have received considerable attention. It has been suggested that the preferential uptake of a bone-seeking element at tissue surfaces is due to a better blood supply relative to that of the interior. However WALLACE-DURBIN (1954) supposed that the large uptake in actively calcifying areas could be explained by the relatively high vascularity of newly forming tissues.

The bone lesions exhibits an indirect effect on blood vascularity. It causes compression of arteries which lead to bad nourishment. A compensatory mechanism in the form of newly formed collateral branches resulting in a stimulation of the hypervascular areas to form a new bone particles. The compressed arterial area showed in the same time dystrophic changes such as malacia and porosis and cystic formations. This series of ill nourishment and compensatory hypervascularity explain the independent predilection seats of osteosis in a given bone segment previously concluded by SEDDEK (1988).

The sclerotic changes found in the blood vessels could be referred to the increased Ca^{++} precipitation on the atrophic areas of the vasculature aided by the action of calcitonin produced from the hypertrophic parafollicular cells of the thyroid (SEDDEK, 1988). The sclerotic changes in blood vessels could be also attributed to the disturbance in lipid metabolism (BATENBURG and BEIGH, 1972).

REFERENCES

- Ali, M.A. and Abdel Moniem (1990): Angiographic picture of manus and pes in goats. I-Normal. Assiut Vet. Med. J., In press.
- Armstrong, W.D. and Singer, L. (1962): Distribution in body-fluids and soft tissues in fluorides and human health. WHO pp. 94-104 (1970). Contributors Adler, P.; Armstrong, W.D. and Murrell, E. Bell.
- Batenburg, J.J. and Beigh, S.G. (1972): The mechanism of inhibition by fluoride of mitochondrial fatty acid oxidation. Biochem. and Biophys. Acta, 280: 495-505.
- Carlson, J.R. and Suttie, J.W. (1967): Effect of sodium fluoride on Hela cells. II Metabolic alterations associated with inhibition. Experimental Cell Research, 45: 423-432.
- Colles, C.M.; Garner, H.E. and Coffman, J.R. (1979): The blood supply of the horse's foot. Proc. 25th Ann. Conv. Am. Ass. Equine Pract. 385-389.
- Correa, R.F.; Oliveira, J.A.; Mendez, M.C. and Schild, A.L. (1986): Fluoride intoxication in cattle due to industrial pollution caused by processing rockphosphate. Fluoride, 19 (2): 61-64.
- Frank, J. (1979): A new concept of the effect of fluorides on bone. Fluoride, Vol. 21, No. 4: 195-208.

ASH. SEDDEK, et al.

- Fry, B.W. and Taves, D.R. (1970): Serum fluoride analysis with the fluoride electrodes. *J. Lab. & Clinic Med.*, 75: 1020-1025.
- Greenwood, D.A.; Shupe, J.L.; Stoddard, G.E.; Harris, L.E.; Nielsen, H.M. and Olsen, L.E. (1964): Fluorosis in cattle. *Agric. Expt. Sta. Utah state. Uni. Special report.*
- Gründer, H.D. (1972): Fluorimissions wirkungen auf Rinder. *Zbl. Vet. Med.*, 19: 229-309.
- Haythorn, S.R. and Taylor, F.A. (1936): The calcium content of arteriosclerotic aortas. *Am. J. Path.*, 12: 303-313.
- Herman, J.R.; Mason, B. and Light, I. (1958): Cited by Armstrong and Singer (1962).
- Nomina Anatomica Veterinaria (1963): 3rd ed. published by the international committee on Vet. Gross. Anatomical nomenclature under the financial responsibility of the World Association of Vet. Anatomists. Ithaca New York.
- Ramberg, C.F. and Olsson, S.E. (1970): Fluoride effects on bone morphology and calcium kinetics. *Fluoride* (3): 175-181.
- Roholm, K. (1937): Fluoride intoxication: A clinical hygienic study with review of the literature and some experimental investigations. H.K. Lewis & Co. Ltd., London.
- Seddek, A.Sh. (1988): Clinicotoxicological study of enviromental pollution of sulphur and fluorine in Goats. Ph.D. Thesis, Assiut University.
- Shupe, J.L.; Miner, M.L.; Greenwood, D.A.; Harris, L.E. and Stoddard, G.E. (1963): The effect of fluorine in dairy cattle. II clinical and pathologic effects. *Am. J. Vet. Res.*, 24 (102): 964-979.
- Singh, A.; Dass, R.; Hayreh, S.S. and Jolly, S.S. (1962): Skeletal changes in endemic fluorosis. *The journal of bone and joint surgery*, Vol. 44 B, No. 4: 806-815.
- Smith, F.A.; Gardner, D.E.; Leone, N.C. and Hodge, H.C. (1960): The effects of the absorption of fluoride V. The chemical determination of fluoride in human soft tissues following prolonged ingestion of fluorides at various levels. *A.M.A. Archives fo industrial health* Vol. 21. Apr. 38/330-40/332.
- Spencer, G.R.; Fawzil, El-Sayed; Kroening, G.H.; Pell, K.L.; Norman, S.; Adams, D.F.; Melvin, F. and Alexander, J.E. (1971): Effect of fluoride, calcium, and phosphorus on porcine bone. *Am. J. Vet. Res.*, Vol. 32, No. 11: 1751-1771.
- Wallac-Durbin, P. (1954): ^{18}F incorporation into various hard tissues of the fully grown rat. *J. dent. Res.*, 33: 789-800.

ANGIOGRAPHIC CHANGES IN FLUOROSIS

LEGENDS

- Fig. (1):** Dorsopalmar angiographic picture of the thoracic limb showing a dilation of the A.digitalis communis III (6) and newly formed blood vessels (3). A.mediana (1). V.cephalica (2). A.digilatis palmaris communis II (4). A.digitalis palmaris communis IV (5). Aa.digitalis propria III, IV abaxialis (7 & 8). Aa.digitalis propria III, IV axisialis (9 & 10).
- Fig. (2):** Dorsopalmar angiographic picture of the pelvic limb showing newly formed blood vessels (5). Tortious appearance of the A.digitalis plantaris communis II (6). Sclerosis of the A.metatarsea dorsalis III (3). Incomplete filling of the A.digitalis plantaris communis II (7). A.cranialis tibialis (1). Ramus caudalis of V.suphana lateralis (2). Exostotic and porosis of the large metatarsal bone (4).
- Fig. (3):** Mediolateral (A) and dorsopalmar (B) angiographic picture of the radius showing sclerosis of the V.cephalica (2). A.mediana (1). Compansatory newly formed blood vessels in a tortious appearance (3). The bone showed sclerosis and osteoporotic change.
- Fig. (4):** Dorsopalmar and mediolateral angiographic picture of the thoracic limb showing a network of newly formed blood vessels (small arrows). Exostotic focci (3) and deformity of the phalanges. A.mediana (1-4). V.cephalica (2).
- Fig. (5):** Dorsoplantar angiographic picture of the pelvic limb showing sclerosis of the A.metatarsalis dorsalis III (2-4) and bone cyst (black arrows). Bone exostosis (3). Tuber calcis (1).




Fig. (1)

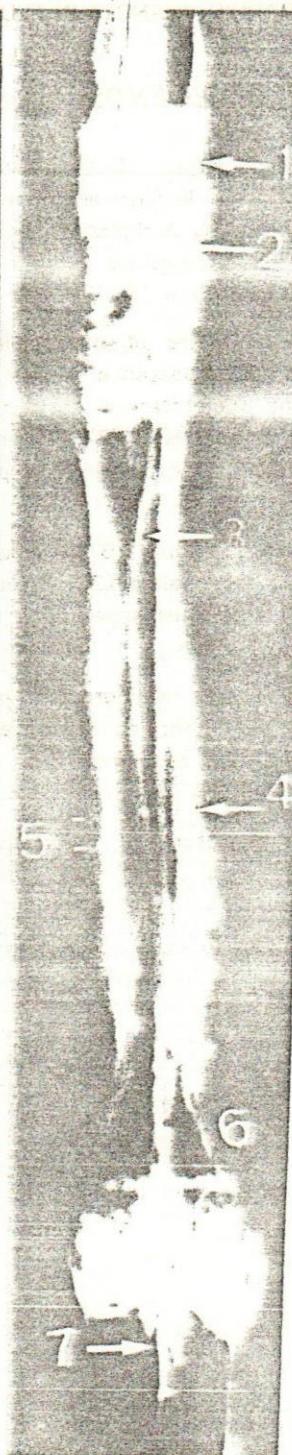


Fig. (2)




Fig. (3)




Fig. (4 a)




Fig. (4 b)

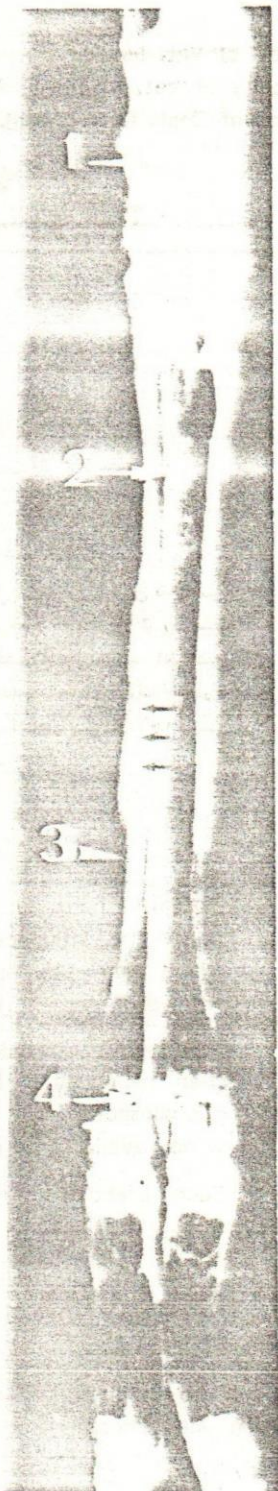


Fig. (5)