

Dept. of Anatomy and Histology,
Fac. of Vet. Med., Assiut University,
Head. of Dept. Prof. Dr. A. Hefny.

**THE TONGUE OF FOUR EUROPEAN WILD RUMINANT SPECIES
-MORPHOLOGY AND EXTRINSIC MUSCLES-
(With 1 Table and 1 Plate & 5 Figures)**

By

A.S. SABER

(Received at 6/11/1990)

اللسان في أربعة أنواع من المجترات الأوروبية البرية
- مورفولوجي والعضلات الخارجية -

أشرف صبحي صابر

نوقش في هذا البحث شكل وتركيب وقياسات اللسان ، كذلك عضلات اللسان الخارجية في أربعة أنواع من المجترات الأوروبية البرية ، صغيرة ومتوسطة الحجم وتتبع مختلف طرق الغذاء . كما قسمها هوفمان (١٩٧٦) . وتشمل العينات كل من غزال الرو، الغزال الأحمر ، ايل آدم، والخروف البري . هذا وقد قورنت النتائج المتحصل عليها بالحيوانات المستأنسة الأخرى كما أبرزت أهم خصائص كل نوع ووضحت النتائج في لوحتين وجدول وشكل واحد . وقد انتهت الدراسة على أن الخصائص المورفولوجية العامة للسان في الحيوانات محل الدراسة تشبه بعضها البعض ، كذلك تشبه الأنواع المستأنسة . ومع ذلك لوحظت اختلافات مميزة في الأنواع المختلفة خاصة فيما يتعلق بتوزيع حلمات اللسان .

SUMMARY

The form, structure and measurements of the tongue as well as the extrinsic lingual muscles of 4 small and medium-sized wild European ruminant species of different feeding types as classified by HOFMANN (1976) were fully described. These representatives include the roe deer, red deer, fallow deer, and mouflon. The results were compared with other domestic species, the most characteristic species differences were shown and the results were expressed in 2 plates, 1 table and 1 figure.

The common morphological features of the tongue is found to be similar in all species studied and conform the other domestic species. However, distinct species variations, specially in the distribution of the lingual papillae, were observed.

INTRODUCTION

The tongue of ruminants play an important role not only to get hold of food plants but also in pulling or selecting these food plants. The present study was carried out on the tongue of European representatives of wild ruminants of all three categories of feeding types as classified by HOFMANN and STEWART (1972). The roe deer represents the concentrate selectors, the red deer and fallow deer as mixed feeders (intermediate type) and the mouflon as grass and roughage eaters.

A.S. SABER

MATERIAL and METHODS

The present study was carried out on 4 European ruminant species using a total of 22 specimens. Of those 5 came from roe deer (*Capreolus capreolus*) as concentrate selector; 9 from red deer (*Cervus elaphus*) and 4 from fallow deer (*Cervus dama*) as mixed feeders, and 4 from mouflon (*Ovis ammon musimon*) being grass and roughage eaters. The species belonged to both sexes and different adult age groups.

Anatomical differences of the tongue and extrinsic lingual muscles were studied by macroscopic dissection. The results were illustrated by drawings (5 figs.) and were discussed with other domestic species. The nomenclature used is in accord with the *Nomina Anatomica Veterinaria* (1983).

RESULTS

Results are expressed in (Table 1 and Plate 1 & 5 Figures).

DISCUSSION**1) Morphological Features :**

The tongue of four ruminant species studied (roe deer, red deer, fallow deer and mouflon) is a very mobile and versatile organ. It fills the oral cavity and is situated on the floor of the mouth between the bodies of mandible. It is supported caudally by the hyoid bone. In the red deer it is somewhat firm.

The *dorsum linguae* is related to the hard palate, and its free rostral portion is the apex. The tongue presents in its caudal part an elliptical prominence, *torus linguae*, rostral to which is the deep *fossa linguae*.

The measurements and the morphological features of the tongue of the species studied were presented in plate I and table 1.

MAY (1970) and NICKEL *et al.* (1973) agreed that the apex *linguae* is pointed in the ox and is slightly pointed in the sheep. In the camel the apex is flattened dorsoventrally and possesses a longitudinal furrow on the *dorsum* (AL-BAGDADI, 1966; HEGAZI, 1945 and IBRAHIM, 1983) and this resembles the fallow deer and red deer of this study.

The *torus linguae* is described in the tongue of ox (McLEOD, 1958), in ox and sheep (HABEL, 1967; MAY, 1970 and NICKEL *et al.*, 1973), in buffalo (SENGAR and SINGH, 1970) and in camel (HEGAZI, 1945; AL-BAGDADI, 1966; ARNAUTOVIC & ABDEL-MAGID, 1974 and IBRAHIM, 1983).

MAY (1970) stated that the root and body of the tongue in the ox are wider than in the horse, while in the sheep the tongue is narrower in middle of the body.

TONGUE OF FOUR WILD RUMINANT

Table (1): The most characteristic features of the tongue in the roe deer, red deer, fallow deer and mouflon.

C E R V I D S					GOVIDS
TONGUE	CONCENTRATE SELECTOR	MIXED FEEDER (INTERMEDIATE TYPE)		GRASS/ROUGHAGE EATERS	
	ROE DEER	RED DEER	FALLOW DEER	Mouflon	
Apex	- rounded and thick	- rounded, wide and thick	- notched and thin	- rounded and thick	
Corpus	- slightly elevated median ridge rostral to the torus which fades out rostrally.	- slight median ridge which is continued rostrally by a median groove which ends before the tip.	- slight median elevation caudally and a groove which notch the tip rostrally.	- slight median elevation rostral to the torus.	
Torus	- presents a smooth median ridge. - along its length, it has the same width.	- is comparatively small.	- is narrower at both the rostral and caudal ends.	- is pointed rostrally.	
Fossa	- deep and didn't reach the borders of the tongue. C.S. in the apex C.S. in the corpus	- deep and didn't reach the tongue borders. - elongated and oval in shape. - triangular.	- deep, wide and extends to near the lateral borders. - triangular in outline. - triangular.	- short and shallow. - oval to rounded in shape. - triangular.	

Plate I: The measurements of **A.S. SABER**
the tongue and torus linguae in the
roe deer fallow deer, mouflon and
red deer respectively.

Plate II:

Figs. (1-4): Tongue of the roe deer, fallow deer, mouflon and red deer. Dorsal view. A Tongue B Cross section in the apex of A.

a apex; b body; b' median groove;
c root; d torus linguae; d' fossa linguae;
1 filiform, conical and lenticular papillae;
2 fungiform papillae;
3 vallate papillae.

Fig. (1): Lingual muscles of the fallow deer.

1 stylohyoid; 2 thyrohyoid; 3 kera-
tohyoid; 4,4' the two parts of M.
styloglossus; 5 M. genioglossus; 6
M. styloglossus; 7 tongue; 8 A. maxillaris
externa; 9 N. hypoglossus; 10 N.
lingualis.

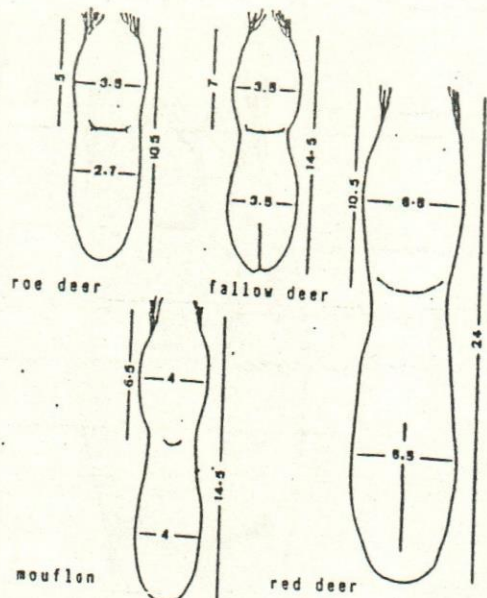
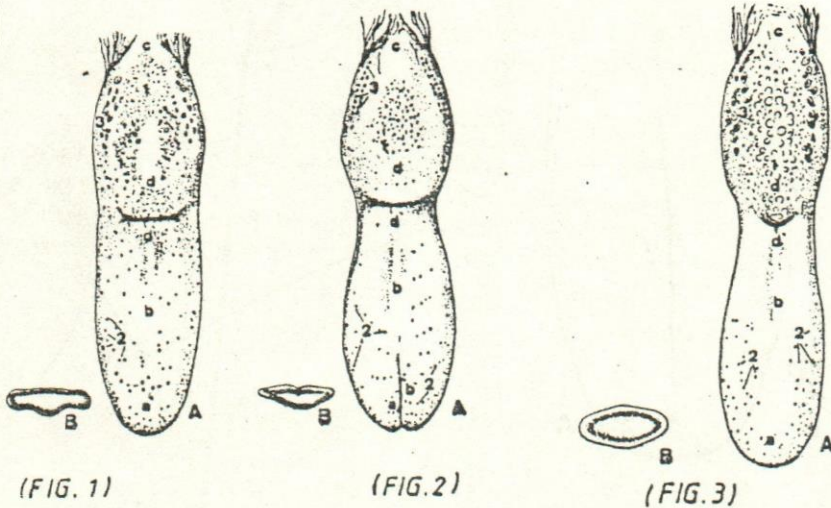
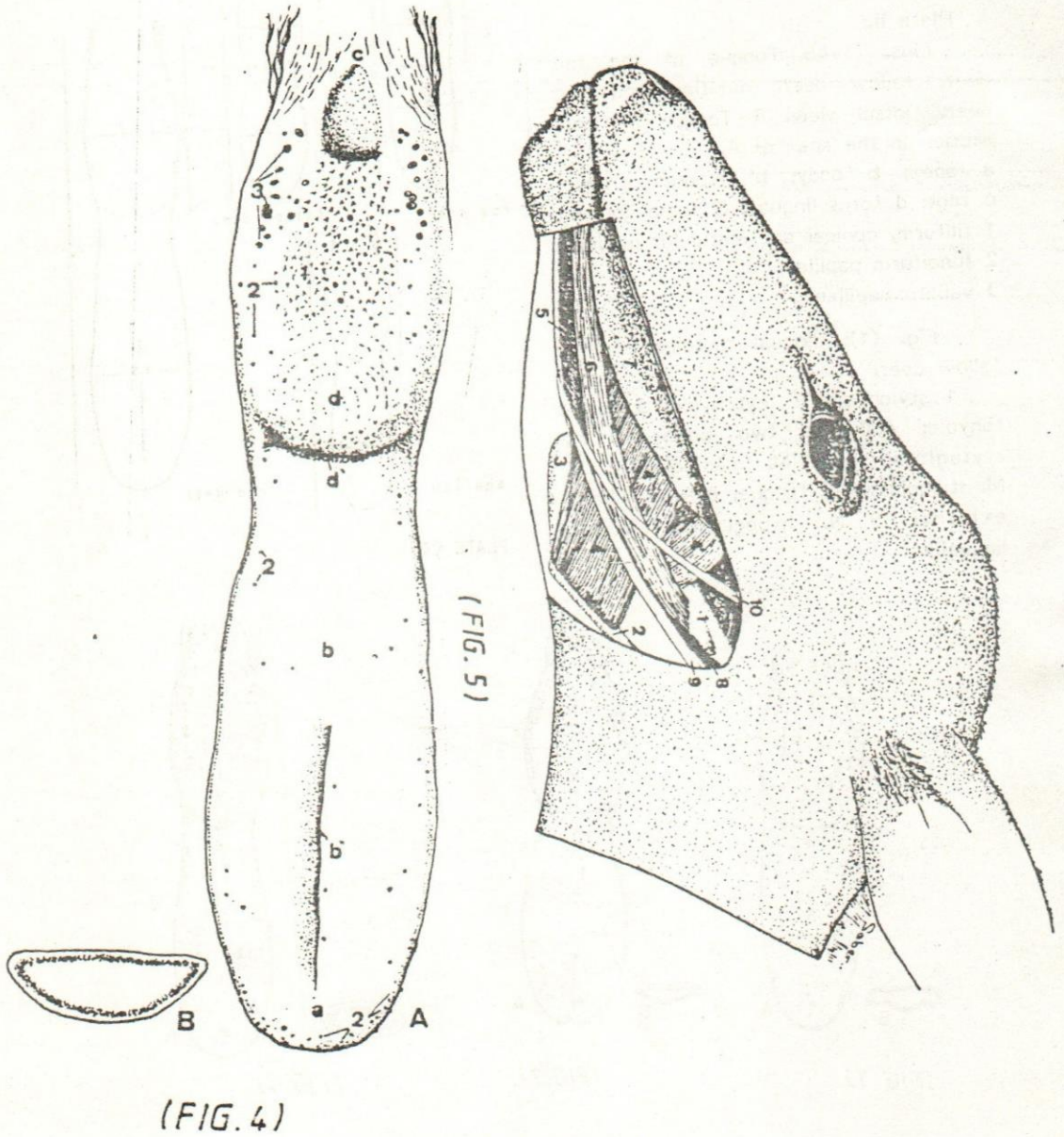


PLATE (I)



TONGUE OF FOUR WILD RUMINANT



He agreed with HABEL (1975) that the torus in the sheep as in ox but not as well marked.

The tongue has a thin and delicate mucous membrane covering its ventral and lateral surfaces. On the dorsum, however, the mucosa is thick and tough due to the cornification of its epithelium. The mucous membrane presents many papillae classified as mechanical (filiform, conical and lenticular) and gustatory (fungiform and vallate).

The filiform papillae are soft, horny threads and direct caudally. They are found along the dorsum linguae, the dorsal parts of the lateral surfaces as well as on the torus linguae where they are larger and coarser. In the red deer the papillae at the fossa linguae are tongue-shaped and reach 1.5 cm long.

In the ox the filiform papillae are found on the dorsum linguae in front of the fossa linguae (NICKEL *et al.*, 1973) and are cornified and sharp, especially on the apex (HABEL, 1975). In the small ruminants the papillae extend also onto the torus and ventral surface of the apex, where they are more prominent (MAY, 1970). They are larger and more flattened than in the ox (NICKEL *et al.*, 1973). In the camel the papillae are lightly cornified and cover the dorsum and borders of the tongue (IBRAHIM, 1983 and SMUTS & BEZUIDENHOUT, 1987).

The conical papillae in the roe deer are found at the rostral part of the torus linguae and are directed rostrally. In the red deer and fallow deer those found at the rostral part of the torus direct rostralwards and those found on the sides point caudally and towards the median plane. In the mouflon the conical papillae are fewer than in the other three species and are found on the lateral sides of the torus linguae, lateral to the lentiform papillae.

The lentiform papillae are also found on the torus linguae. They are flat and of varying size. In the roe deer they are found around the smooth median ridge. The papillae are larger in the middle and become smaller laterally and caudally. In the red deer and fallow deer the papillae are relatively very few and are scattered mainly over the rostral part of the torus linguae and among the conical papillae. In the mouflon, they are typical lentile-shaped and their diameter ranges between 1-3.5 mm. They are found along the smooth median ridge extending from the rostral part of the torus to the root of the tongue. They are large at the rostral part of the torus and towards the median plane and becomes smaller laterally and caudally. Some of the lenticular papillae are modified into broad flattened oval-shaped ones.

In the ox the conical papillae are blunt and the lenticular are round and flat and they decrease in number towards the root of the tongue (NICKEL *et al.*, 1973). However, the same papillae rostral to the lingual fossa were described as sharp and pointed while become blunt and hard caudal to the lingual fossa (McLEOD, 1960). In the sheep the lenticular papillae are either blunt or pointed (McLEOD, 1960),

TONGUE OF FOUR WILD RUMINANT

while both types of papillae in the small ruminants resemble those of the large ruminants (NICKEL *et al.*, 1973). In the camel the conical papillae are the continuation of the lenticular ones and completely cover the root of the tongue and scattered also on the glossoepiglottic fold, base of epiglottis and the lateral walls of the oropharynx (IBRAHIM, 1983).

The fungiform papillae are less numerous and are distributed over the dorsum linguae, especially along its borders, the lateral and ventral surfaces of the tongue. The papillae are usually pale in colour with rounded free borders which project slightly above the surface of the tongue. The fungiform papillae are scattered among the filiform papillae, and on the torus among the conical and lenticular ones. In the red deer they are relatively few in number over the dorsum linguae while they aggregate on both surfaces of the apex. In the mouflon the fungiform papillae are scattered on the lateral parts of the dorsum linguae and the ventral surface of the apex.

In the ox McLEOD (1960) and in the small and large ruminants NICKEL *et al.* (1973) agreed that the fungiform papillae are numerous especially along the edges of apex, but are also found in smaller number on the dorsum and along the lateral surface. HABEL (1975) stressed that these papillae are more numerous in the sheep and goat than in the ox. In addition, MAY (1970) mentioned that the papillae in the sheep become more numerous towards the transverse groove. In the camel IBRAHIM (1983) mentioned that the fungiform papillae are crowded on the ventral surface of the apex linguae forming a horse-shoe like shape and this is reiterated by HEGAZI (1945) and AL-BAGDADI (1966) in the same animal.

The vallate papillae are located on the dorsum, just rostral to the root of the tongue. They are larger than the fungiform and are surrounded by a circular cleft and do not project above the surface of the tongue. In the roe deer their number is 9-12, arranged in two rows along the lateral sides of the torus linguae. In the red deer they are 16-20, arranged in one irregular row. The vallate papillae in the fallow deer are about 18-20, arranged in two rows. In the mouflon they range between 16-18 and are arranged laterally along the caudal half of the torus linguae.

In the ox the vallate papillae are 8-17 (McLEOD, 1960 and NICKEL *et al.*, 1973) and may reach to 24-30 with a diameter of 1.5-4.5 mm (DAVIS *et al.*, 1979). In the sheep the papillae may reach 18-20-24 (MAY, 1970 and NICKEL *et al.*, 1973) while in the goat they are only 12-18 (NICKEL *et al.*, 1973 and HABEL, 1975). They form an irregular double row on each side of the caudal part of the dorsum. In the camel, the vallate papillae are 3-6 large (up to 200 mm) and 2-3 smaller and medially situated (SMUTS and BEZUIDENHOUT, 1987). The number of papillae may be doubled and encircled with one root.

The foliate papillae could not be detected in any of the examined species. However, NICKEL *et al.* (1973) mentioned rudimentary papillae in the ox and CHAUVEAU (1891) described them in the camel.

II) Extrinsic Muscles of the Tongue :

The extrinsic muscles of the tongue are M. genioglossus, M. hyoglossus and M. styloglossus (Fig. 1).

M. Genioglossus :

The most medial of the extrinsic muscles of the tongue. It is a semipennate, flat muscle with ventral faint tendinous margin. It measures about 85, 160, 120, 98 mm in width in the roe deer, red deer, fallow deer and mouflon respectively. The muscle originates rostrally at the medial surface of the incisive part of the mandible and extends caudally to the hyoid bone. Its muscle fibers run in a fan-shaped fashion rostralwards and caudalward towards the tip, body and root of the tongue respectively. The insertion is in the intrinsic muscles of the tongue. The genioglossus muscle is related medially to that of the other side while is separated from it by the thin septum linguae. The lateral surface of the muscle is related to Gl. sublingualis monostomatica rostrally and M. styloglossus caudally. It is crossed also by N. lingualis, N. hypoglossus and V. sublingualis.

M. Hyoglossus :

The muscle lies ventrolateral to the root of the tongue. It is nearly rectangular in shape and lies between M. genioglossus medially and M. styloglossus laterally. The muscle could be divided according to its origin into a caudodorsal small part and a rostroventral larger part. The length of both parts is about 24,35; 37,63; 33,45; 30,40 mm and the width is about 9,19; 20,30; 10,20; 10,20 mm in the roe deer, red deer, fallow deer and mouflon respectively.

The caudodorsal part originates from both the lateral and medial surfaces of the rostral end of the stylohyoid, undercovered by the origin of M. styloglossus. In the mouflon it originates, in addition, from the caudal border of the caudal extremity of the epihyoid. The rostroventral part is larger and takes its origin from the basihyoid and the rostral part of the thyrohyoid. In the mouflon it takes its origin also from the processus lingualis which is missed in the other three species (SABER and HOFMANN, 1985). The fibers of both portions of the hyoglossus muscle run dorsolaterally to insert in the root of the tongue. The most caudal fibers of the rostroventral part of the muscle direct caudally to intermingle with that of the caudodorsal part. The muscle is related medially to the rostral part of the stylohyoid, the keratohyoid, the epihyoid, as well as to N. hypoglossus and A. lingualis.

M. Styloglossus :

Is the most lateral of the extrinsic muscles of the tongue. It is long, strip-like and measures about 110, 200, 133, 125 mm in length and about 10,15,14,15 mm in width in the roe deer, red deer, fallow deer and mouflon respectively. The muscle

TONGUE OF FOUR WILD RUMINANT

takes its origin from the lateral surface of the expanded ventral extremity of the stylohyoid. It extends rostrally until about 20-40 mm apart from the apex linguae to join that of the other side and to insert in the intrinsic muscles of the tongue. The rostral three fourths of the lateral surface of the muscle is covered by Gl. sublingualis (polystomatica and monostomatica) and the caudal part is crossed by N. lingualis which continues its course rostrally at the ventral border of the muscle. In the roe deer the polystomatic part of the buccal glands is related to the caudo-dorsal part of the muscle, and overlies its lateral surface nearly at its middle. The Gl. buccalis monostomatica covers the lateral surface of the gland caudally and becomes related to its ventral margin few millimeters before the rostral end of the muscle. On the medial side, the styloglossus lies on M. hyoglossus caudally and on M. genioglossus rostrally. It is related also to A. and V. lingualis as well as N. hypoglossus.

In all species examined, a band of muscle fibers of a considerable width is noticed medial to M. hyoglossus at its insertion. It runs between the root of the tongue and end by blending with the medial surface of M. styloglossus.

The muscles of the tongue of the 4 ruminant species of this study resemble basically those of other domestic ruminants in origin, insertion and action (McLEOD, 1960; MAY, 1970; NICKEL *et al.*, 1973; HABEL, 1975; IBRAHIM, 1983 and SMUTH and BEZUIDENHOUT, 1987), although some species variations still present.

Conclusion :

The tongue of four wild European ruminant species in this study shows common morphological features, however sufficient variation to differentiate the species are quite clear. The conical papillae are generally fewer in the grass eating feeders (mouflon), while the lenticular ones are fewer in the mixed feeders (red deer and fallow deer). The fungiform papillae (gustatory) are relatively fewer in the mixed feeders (red deer) than in the concentrate selectors and grass and roughage eaters. However, the vallate papillae were fewer in the concentrate feeders (roe deer). These findings seem to adapt the nature of feeding in the concentrate and mixed feeders type because the gustatory papillae contain taste buds which characterise the tongue as organ help in taste and selection of food.

On the other hand the tongue of mouflon as well as of the other cervides examined is not used in the prehension of food as that of ox. Therefore the development of papillae, especially on the apex of the tongue is not great. This opinion is supported by MAY (1970).

In general, it can be concluded that the tongue shows, more or less, some adaptation related to feeding behaviour as expressed in the morpho-physiological classification into feeding types (HOFMANN and STEWART, 1972) and which had been confirmed by STOCKMANN (1979) for morphological features of the mandible.

ACKNOWLEDGMENT

I wish to express my deepest thanks to Prof. R.R. Hofmann, Institute of Veterinary Anatomy, Histology and Embryology, J.L. University, Giessen, Germany for supplying the materials of this work. My thanks were also extended to Prof. H. Badawi, Prof. of anatomy, Assiut University, Egypt for his kind revision of the manuscript.

REFERENCES

- Al-Bagdadi, F.A. (1966): The tongue of the camel (*Camelus dromedarius* and *Camelus bactrianus*). Nord. Vet. Med. 18: 337-346.
- Arnautovic, I. and A.M. Abdel-Magid (1974): Anatomy mechanism of distension of the dulla of the one-humped camel. Acta Anat. 88: 115-124.
- Chauveau, A.S. (1891): Cited by HEGAZI (1945).
- Davis, R.O.; M.R. Kare and R.H. Cagan (1979): Distribution of taste buds on fungiform and circumvallate papillae of bovine tongue. Anat. Rec. 195: 443-446.
- Habel, R.E. (1975): Ruminant digestive system; in Sisson and Grossman's: The anatomy of the domestic animals. Edited by R. Getty 5th ed., 861-915. W.B. Saunders Company, Philadelphia.
- Hegazi, M.A.H. (1945): The anatomy of the digestive system of the camel. M.S. Thesis, Cairo University.
- Hofmann, R.R. (1976): Zur adaptiven Differenzierung der Wiederkauer: Unter suchungsergebnisse auf der Basis der vergleichenden funktionellen Anatomie des Verdauungstrakts. Prakt. Tierarzt. Hannover 57/6: 351-358.
- Hofmann, R.R. and D.R.M. Stewart (1972): Grazer or browser: a classification based on the stomach structure and feeding habits of East African ruminants. MAMMALIA, Paris 36/2: 226-240.
- Ibrahim, I.A. (1983): Some anatomical studies on systema digestorium of the *Camelus dromedarius*. Ph.D. Thesis, Assiut University.
- MAY, N.D.S. (1970): The anatomy of the sheep, a dissection manual. 3rd ed. University of Queensland Press.
- McLeod, W.M. (1960): Bovine anatomy. 2nd ed. Burgess Publishing Company.
- Nomina Anatomica Veterinaria (1983): Published by the international comitte on Veterinary Gross Anatomists. 3rd ed. Ithaca, N.Y.
- Nickel, R.; A. Schumer and E. Seiferle (1973): Lehrbuch der Anatomie der Haustiere. Band I, II. P. Parey, Berlin, Hamburg.
- Saber, A.S. and R.R. Hofmann (1985): A comparative study of the hyoid bone (*Os hyoides*) of 6 ruminant species (*Ruminantia* Scopoli, 1777). Anat. Anz. Jena 158: 43-50.
- Smuts, M.M. and A.J. Bezuidenhout (1987): Anatomy of the dromedary. Clarendon Press, Oxford.
- Stöckmann, W. (1979): Formunterschiede der Mandibel afrikanischer Bovidae (Mammalia) und ihre Beziehungen zur Zusammensetzung der Nahrung. Zool. Jb. Syst. Jena. 106: 344-373.