

Dept. of Surgery,  
 Fac. of Vet. Med., Assiut University,  
 Head of Dept. Prof. Dr. M.T. Nassef.

# **NORMAL PNEUMO-TENDOGRAMS AND PNEUMO-DESMOGRAMS AT THE METACARPAL AND METATARSAL REGIONS OF THE DONKEY LIMBS** (With 2 Figs. and 2 Tables).

By

**M.A. SELEIM**

(Received at 11/12/1990)

تصوير أوتار الشط الأمامي والخلفي وأغلفتها في الحمر بالأشعة  
 بعد الحقن بالهواء

مجدي سليم

تم تصوير الأوتار القابضة والوتر الباسط العام وأغلفتها في الشط الأمامي والخلفي في عشرة حمير بالأشعة السينية بعد حقنهما تحت الجلد بالهواء وذلك لدراسة إمكانية ظهور الأوتار والأربطة في هذه الأماكن وفي هذه الصور من الممكن قياس سمك الأوتار وفحصها وخاصة الأوتار السطحية والفاخرة القابضة وهذه الطريقة يمكن تطبيقها عمليا في تشخيص بعض أمراض الأوتار والأربطة فضلا عن أنها طريقة سهلة ومريحة ورخيصة.

## **SUMMARY**

In 10 experimental donkeys, pneumo-tendograms and pneumo-desmograms at the metacarpal and metatarsal regions were performed to study the anatomic and radiographic values of this technique. On pneumographs the thickness of soft tissue can be measured especially the superficial and deep digital flexor tendons. The technique can be easily applied clinically for diagnosis of some affections of tendons and ligaments, as well as, it is rapid and inexpensive.

## **INTRODUCTION**

Tendinitis, desmitis and rupture of the tendons and ligaments of the metacarpal and metatarsal regions are common problems in equine (ADAMS, 1974; DIETZ, 1982; PERSONETT *et al.*, 1983; GERRING and WEBBON, 1984 and VERSCHOOTEN and PICAVET, 1986). DIETZ (1982) enumerate the tendons and ligaments in the metacarpus and metatarsus which may usually be affected as follow: The superficial digital flexor tendon (with possible involvement of its check ligaments); the deep digital flexor tendon (with its check ligament); the suspensory ligament (superior sesamoidean ligament) and the extensor tendon (tendon of the long digital extensor or common digital extensor), which is rarely affected.

Survey radiographs are practically useless because they do not contribute any additional information to simple palpation. In acute tendinitis, the exact clinical localization of the lesion may be difficult when severe oedema is present, yet-exact anatomical diagnosis can be impossible in the distal third of the third metacarpal or metatarsal bone (VERSCHOOTEN and De MOOR, 1978).



M.A. SELEIM

The thermography and  $^{133}\text{Xe}$  (STROMBERG, 1973) and recently ultrasonography (SPAULDING, 1984) clearance studies have been employed, but the expensive apparatuses are not readily available in each clinic and certainly not to the practitioner. VERSCHOOTEN and De MOOR (1978) and VERSCHOOTEN and PICAVET (1986) described the radiological diagnosis of tendinitis and desmitis in horse by means of air-tendograms.

This study was done to demonstrate radiographically the accurate anatomical appearance of the normal tendons and ligaments in the metacarpal and metatarsal regions of the donkey by means of air contrast filling.

### **MATERIAL and METHODS**

The donkeys were sedated with an intravenous injection of chlorpromazine. The tendograms were done with the donkeys in a standing or recumbent position. The site of injection was shaved and disinfected. A rubber tourniquet was applied distal to the carpal or hock joint.

The air was injected through a three-way stopcock in 20 legs (thoracic or pelvic). A local infiltration analgesia was applied subcutaneously at the site of air injection using 2 ml of 2% xylocaine HCl. The air was injected subcutaneously and between the flexor tendons and the suspensory ligament at the middle third of the palmar or plantar aspect of the metacarpal or metatarsal regions. The needle was directed distally in an oblique manner (Fig. 1).

The air was injected in ascending doses from 20-100 ml. The air was also injected at the dorsal aspect subcutaneously proximal to the level of fetlock joint (Fig. 1). Just after air introduction lateral radiographs were taken in extended and flexed positions.

The thickness of the superficial digital flexor (SDF) and deep digital flexor (DDF) tendons were measured on specimens of normal donkeys as well as on the tendograms at different distances distal to the distal end of the accessory carpal bone. The radiographs were carefully examined for recognition of the different structures.

### **RESULTS**

Pneumo-radiograms of good quality were obtained after injection of 60 to 80 ml air into the flexor aspect and of 20 to 30 ml into the extensor aspect of the metacarpal or metatarsal region according to the size of the animal.

On specimens of normal donkeys the values of flexor tendon thickness were recorded in table (1). The measurements were made at different levels distal to the distal end of the accessory carpal bone. It was observed that the superficial digital flexor tendon (SDF) decreased sharply in thickness from 5.2 mm proximally till 2.6 mm distally. But, the deep digital flexor tendons (DDF) have nearly the same thickness along its whole length (5.8 mm proximally and 5.5 mm distally) including the inferior check



## PNEUMO-TENDOGRAMS &amp; DESMOGRAMS

ligament.

The recognition of these variations in thickness are seen in the normal tendogram, in which the different structures are sharply delineated (Fig. 2). The radiographic thickness of the tendons are also measured and compared. The normal values are recorded in table (2). It was also observed that the thickness of the SDF decrease from 6.0 mm proximally at the level of the distal end of the accessory carpal bone to become 2.7 mm distally near the level of the proximal sesamoid bone. But, the DDF has nearly the same thickness along its length (6.2 mm proximally and 5.6 mm distally).

In addition to SDF and DDF the following structures are seen (Fig. 2): the inferior check ligament; the caudal border of the stay apparatus; the caudal edge of the straight sesamoidean ligament; the vincula of the DDF and fibrocartilage caudal to the fetlock joint in which the sesamoid bones are embedded. In some radiograms the proximal and distal ends of the common digital tendon sheath are clearly outlined. These structures are seen equally in both extended and flexed positions.

After injection of 20-30 ml air subcutaneously at the dorsal aspect of metacarpus or metatarsus 5-8 cm proximal to the fetlock joint, the dorsal skin and extensor tendon are separated and sharply outlined.

The insufflation of the ordinary air subcutaneously and between the tendons never induced any irritation to the animal or infection. All the air disappears clinically within 24 hours after injection.

## DISCUSSION

The present study revealed a satisfactory technical quality of pneumography of the metacarpal and metatarsal regions of the donkey limbs. The outlines of the different structures nicely and clearly appeared in the normal pneumograms. The pneumo-tendograms and pneumo-desmograms are useful in the diagnosis of many affections of the tendons and ligaments in these regions in horse (VERSCHOOTEN and De MOOR, 1978; DIETZ, 1982 and VERSCHOOTEN & PICAVET, 1986).

The procedures are easy, rapid and inexpensive as well as has no complications. The dorso-palmar radiographs has no value due to the superimposition of the bone and soft tissues.

When a tourniquet or pressure bandage are applied distal to the carpal or hock joint increasing the intra-tendovaginal pressure to facilitate tendon separation and preventing the escaping of the air proximally.

Not all different structures are always possible to be seen in either extended or flexed positions of the fetlock joint. The reason, when the two radiographic positions are combined, most of the structures can be recognized (VERSCHOOTEN and De MOOR, 1978). In the present study, the flexed position, actually do not contribute any additional information to the extended one.

The quality of tendograms is more improved when the procedures are performed in recumbent position, where the technique is more carefully applied, so, the total amount of information are increased.

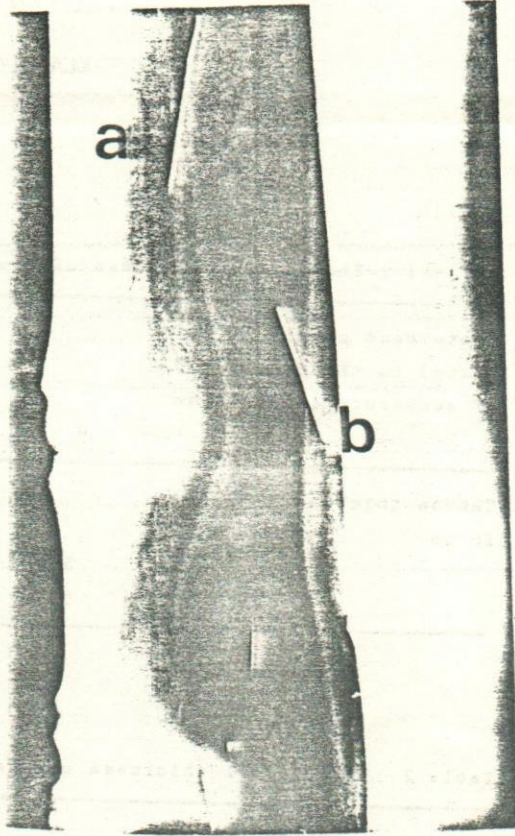
In conclusion, the pneumo-tendogram and pneumo-desmogram proved to give accurate and useful informations in normal animals using an easy, rapid, and inexpensive technique. This technique can be used for diagnosis of some tendon and ligament affections in donkeys.

## REFERENCES

- Adams, O.R. (1974): Lameness in Horses. 3rd Ed Lea & Feiger, Philadelphia.
- Dietz, O. (1982): Diseases of the Horse. A Handbook for Science and Practice. Ekkehard Wiesner, Berlin part 2/II, 1st Ed.
- Gerring, E.L. and Webbon, P.M. (1984): Fetlock annular ligament desmotomy: A report of 24 cases. equine Vet. J., 16 (2): 113-116.
- Personetti, L.A.; McAllister, E.S. and Mansmann, R.A. (1983): Proximal suspensory Desmitis. Mod. Vet. Pract. Vol. 64(7): 541-545.
- Stromberg, B. (1973): Morphologic, Thermographic and <sup>133</sup>Xe Clearance Studies on Normal and Diseased Superficial Digital Flexor Tendons in Race Horses. Equine Vet. J. Vol. 5: No. 4, 156. Cited by Verschooten, F. and De Moor, A. (1978).
- Spaulding, K. (1984): Ultrasonic anatomy of the tendons and ligaments in the distal metatarsal region of the equine limb. Vet. Radiol. 25, 155-166.
- Verschooten, F. and De Moor, A. (1978): Tendinitis in the horse: Its radiographic diagnosis with air tendograms. J. Am. Vet. Radiol. Soc. 19: 23-30.
- Verschooten, F. and Picavet, T.M. (1986): Desmitis of the fetlock annular ligament in the horse. Equine Vet. J. 18(2): 138-142.



**Fig. (1):** Showing the needle at the site of air injection (a-for flexor & b- for extensor tendons).



**Fig. (2):** A normal pneumograms of the metacarpal & phalangeal regions showing: (1) SDF; (2) DDF; (3) extensor tendon; (4) palmar skin; (5) dorsal skin; (6) suspensory ligament; (7) loose C.T.; (8) inferior check ligament; (9) annular ligament and (10) distal distension of digital tendon sheath.

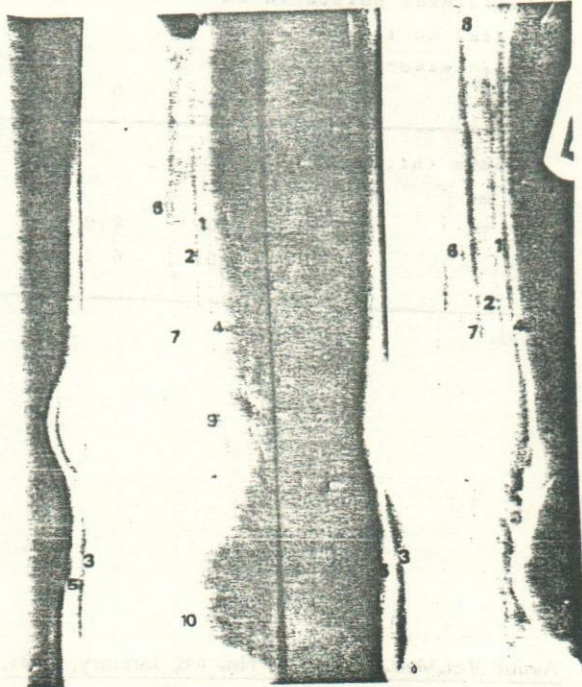


Table 1 : The normal thickness of the tendons of specimens.

Measurement points in cm distal to the distal end of accessory carpal bone		0	5	10	15
Tendon thickness in mm					
	SDF	5.2	3.8	3.2	2.6
	DDF	5.8	5.2	5.6	5.5

Table 2 : The normal thickness of the tendons on tendograms

Measurement points in cm distal to the distal end of accessory carpal bone		0	5	10	15
Tendon thickness in mm					
	SDF	6.0	4.2	3.8	2.7
	DDF	6.2	6.6	6.3	5.6