

Comparing Shaping Ability of Fanta, One Curve, and Pro Taper Next Ni-Ti Rotary File Systems

Soliman N. Mansour¹, Maram Obeid², Tariq Yehia³

Abstract:

Objective: To compare the shaping ability of Fanta, One Curve, and Pro Taper Next Ni-Ti rotary file systems. **Materials and Methods:** Sixty Mandibular molars with mesiobuccal canals with curvatures ranging between 20° and 40° were divided into three groups of 20 teeth each. a group for each system as follows: group 1 was prepared by Fanta file system, group 2 was prepared by Pro Taper Next file system, and group 3 was prepared by One Curve file system. The measuring of canal curvatures was determined by Schneider's method using standardized periapical radiographs and the Image J software. Pre and post-CBCT scans were done on all samples. Measurements of Pre and Post CBCT scans were compared to assess transportation and centering ability. Data were analyzed using the Minitab 19 program one-way analysis of variance (ANOVA) and Tukey Honestly Significant Difference (HSD) test. **Results:** There was no significant difference between the 3 tested groups regarding transportation or centering ratio, but the coronal third showed higher values of transportation with Fanta group ($p \leq 0.05$), and Pro Taper next group ($p \leq 0.05$). **Conclusions:** All instruments were safe to use. The three instruments showed no significant difference regarding shaping ability.

Introduction:

Endodontics is a branch of dentistry devoted to dealing with the complicated structure within the teeth. Endodontic is a Greek word that literally means “inside the tooth”. The endodontic treatment goal is to maintain natural tooth structure as much as possible.^{1,2} Shaping root canals is one of the most important steps in root canal treatment. It is critical for proper treatment of root canal as it affects all following procedures, including chemical disinfection and filling of the root canal.^{3,4} Many Nickel-titanium (Ni-Ti) files are introduced in the market with variable shapes. Fanta AF blue S one file (Shanghai Fanta dental materials Co., Ltd. China) is an AF-H heat-treated Ni-Ti file with S- shape cross-section from the middle of the file upward, and an almost oval cross-section at the tip. The manufacturer claims that Fanta files have great cutting efficiency and flexibility as it has minimum radial contact. Moreover, the variable S-cross-section of the Fanta file increases the volume of upward debris elimination. One curve file (MICRO ,MEG, Besancon, France) is a heat-treated Ni-Ti file with a variable cross-section .The manufacturer claims that One Curve files have high flexibility and cutting efficiency that respects the original anatomy of the tooth. The manufacturer also claims that the variable cross-section of the file enhances the centering ability of the file in the apical Third, and debris removal coronally. Pro Taper Next (DENTSPLY, Tusla ,United States) is an M-wire file that gives flexibility and cyclic fatigue resistance as claimed by the manufacturer.

and the asymmetric rotation enhances the shaping efficiency as the rotation of the file differs from the center of mass resulting in only two points of the rectangular cross-section touching the canal wall at a time Therefore, comparing the shaping, and cleaning abilities of Fanta rotary file and one curve rotary file using Pro Taper Next file as a control group was thought to be of value.

Materials and Methods:

Samples selection and preparation:

Sixty extracted permanent mandibular first molars were collected. Only teeth with fully developed sound root apices with mesiobuccal root canals of (20°–40°) angle of curvature that permit size 10 or size 15 K-files (Mani, Tochijo, Japan) insertion to the major foramen were included. Standard periapical radiographs were taken for the teeth. Schneider's method⁵ was used to calculate the angle of mesiobuccal canal curvature. Teeth were decoronated at the cement-enamel junction using a diamond disc (Mani, Tochijo, Japan). Mesial roots were smoothed to get an equivalent 12 mm length for all Mesiobuccal canals creating a reference point that is flat, and reliable. Working length was determined by subtracting 1 mm short of the length at which the K file 10 reaches the apical foramen. Selected samples were scanned by the GENDEX DP-800 device (Kavo dental, Charlotte, United States) at 90 kV, 6.3 mA, voxel size 85µm (0.085mm), and Field of view of 5 cm height. After the acquisition, data were exported and transferred in DICOM format and downloaded via a Compact Disk (CD) to a personal computer for analysis using In Vivo Dental viewer. M1 and D1 measurements were obtained from pre-instrumentation imaging at 3, 5, and 7 mm levels from the apical end in the mesiodistal direction. M1: was the shortest distance from the mesial edge of the root to the mesial edge of the un-instrumented canal. D1: was the shortest distance from the distal edge of the root to the

¹Postgraduate student, Department of Endodontics, Faculty of Dentistry, Ain Shams University, Cairo, Egypt.
soli89dentist@gmail.com

²Associate professor, Department of Endodontics, Faculty of Dentistry, Ain Shams University, Cairo, Egypt.

³Lecturer, Department of Endodontics, Faculty of Dentistry, Ain Shams University, Cairo, Egypt

DOI: 10.21608/mjd.2022.149688.1059

distal edge of the un-instrumented canal (Figure 1). Preparation was performed following the manufacturer's recommendations for each system.

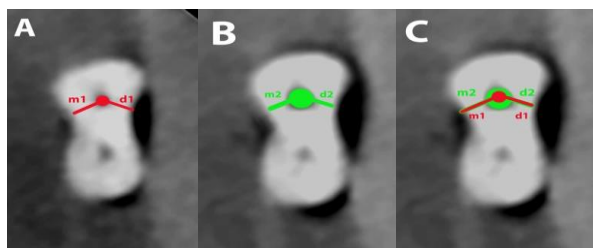


Figure 1: Measurements for cross section used in Gambil's Equation: (A) Measurements before instrumentation, (B) measurements after instrumentation, (C) the difference between the two measurements

All root canal preparations were completed by one operator. An electric torque control motor with a gear reduction handpiece (16:1) was used. Each canal was prepared to a final apical size of 25 in a crown-down sequence in each group. Irrigation was done using 2 ml 2.5% sodium hypochlorite (NaOCL) with a 30 Gauge needle after each instrumentation. Patency was maintained using a #10 K file. Each instrument was discarded after 3 canals preparation. Group 1 (n=20) was prepared by Fanta AF blue S one in a rotation movement with crown-down technique to working length at speed 400 rpm and torque 2.6 N.cm according to the manufacturer's recommendation using Fanta orifice opener (#17/12) then Fanta file (#25/06). Group 2 (n=20) was Prepared by ProTaper Next in a rotation movement with crown-down technique to working length at speed 300 rpm and torque 2 N.cm according to the manufacturer's recommendation using X1 file (#17/04) then X2 file (#25/06). Group 3 (n=20) was prepared by One Curve in a rotation movement with crown-down technique to working length at speed 300 rpm and torque 2.5 N.cm according to the manufacturer's recommendation using One Flare orifice opener (#25/09) then One Curve file (#25/06). After instrumentation, the samples were scanned again in the same way as described for the pre-instrumentation scan. The following measurements were carried out: M2: was the shortest distance from the mesial edge of the root to the mesial edge of the instrumented canal, and D2: was the shortest distance from the distal edge of the root to the distal edge of the instrumented canal.

Evaluation of canal transportation was calculated using the formula of Gambill et al.⁶, $(M1 - M2) - (D1 - D2)$ (Figure 1). According to this formula, a result other than 0 indicated that transportation has occurred in the canal. Evaluation of canal centering for each section was done using the following ratio:

$$\frac{M1 - M2}{D1 - D2} \quad \text{or} \quad \frac{D1 - D2}{M1 - M2}$$

The highest value while using this formula has to be the denominator, and the smallest has to be the numerator. A value of (1) indicates perfect centering⁷.

The measurements were stored for later statistical analysis.

Statistical evaluation:

Data were presented in terms of mean \pm SD Using the Minitab 19 program (Minitab Ltd. Coventry, UNITED KINGDOM) one-way analysis of variance (ANOVA) and Tukey Honestly Significant Difference (HSD) test was calculated to determine any statistical difference amongst groups. In the present study, ($P \leq 0.05$) was considered the level of significance.

Results:

The results revealed that there was no statistically significant difference between the 3 tested file systems at each third of the root canal ($P > .05$), (Table 1 and Table 2). During instrumentation, none of the instruments fractured. There was no significant difference between the 3 tested groups regarding transportation or centering ratio, but the coronal third showed higher values of transportation with Fanta group ($p \leq 0.05$), and Pro Taper next group ($p \leq 0.05$).

Discussion:

Promising root canal treatment relies on adequate shaping and debridement of the root canal system with maintaining the original shape of the canals producing tapered conical canal from apical to coronal with no ledges, zipping, elbowing, and other procedural errors^{8,9}. Root canal instrumentation goal is to get a continuously tapered shape with the smallest diameter at the apical foramen and the largest at the orifice to allow effective irrigation and filling according to Schilder.¹⁰

Rotary systems with single files were introduced to practice to increase operator quality with less operation time required. AF blue S one is a single Ni-Ti rotary file system. According to the manufacturer, the file is made of AF-H heat-treated wire claiming this gives the file more flexibility and a variable S-shaped cross-section at the whole length of the file except its tip as it is almost oval at the tip. This cross-section is claimed to give better debris removal, centering ability, and cutting efficiency with minimum radial contact. One Curve is a single Ni-Ti rotary file system. According to the manufacturer, the file is made of heat-treated C-wire with controlled memory and the ability to be pre-bent with a varying cross-section. This cross-section suggests excellent debris removal and better centering ability in the apical third. ProTaper Next files have different off-centered rectangular cross-sections and asymmetric rotation, which is supposed to increase its strength as claimed by the manufacturer. In most studies¹¹⁻¹⁸ post-operative changes in root canal morphology have been performed on mesial root canals of lower adult molars because in most cases these teeth possess at least curvature in the mesiodistal plane.

In this study, mesial roots of extracted mandibular adult first molars with an angle of curvature ranging from 20° to 40° were included because these roots contain canals that are often tight and curved making instrumentation more tricky and difficult.^{12,19}

Table 1: Effect of file type on canal transportation

	Fanta AF blue S one	Pro Taper Next	One Curve	P-Value
Coronal	0.1244 ±0.0814 ^a	0.1253 ±0.0876 ^a	0.1064 ±0.0727 ^a	0.778
Middle	0.0631 ±0.0590 ^a	0.0573 ±0.0435 ^a	0.0464 ±0.0422 ^a	0.638
Apical	0.0531 ±0.0375 ^a	0.0544 ±0.0518 ^a	0.0587 ±0.0836 ^a	0.964

Table 1: Effect of file Type on centering ratio

	Fanta AF blue S one	Pro Taper Next	One Curve	P-Value
Coronal	0.4847 ±0.2765 ^a	0.5040 ±0.2770 ^a	0.4383 ±0.2284 ^a	0.782
Middle	0.5259 ±0.3222 ^a	0.6454 ±0.2526 ^a	0.5843 ±0.2245 ^a	0.445
Apical	0.4658 ±0.2535 ^a	0.6603 ±0.3082 ^a	0.5474 ±0.1991 ^a	0.103

Means that do not share same letter are significantly different $t \leq 0.05$.

Root canal thirds were represented by 3 levels from the apex as follows: apical third 3 mm from the apex, middle third 5 mm from the apex, and coronal third 7 mm from the apex. These 3 levels show curvatures with high susceptibility to iatrogenic mishaps^{20,21}. Pre-operative determination of the canal curvature was done by Schneider's method⁵. This method has been used by many authors as it is proven that it is accurate and reliable.²²

CBCT scanning (Figure 2) was performed because it affords a meticulous, repeatable, 3-dimensional assessment of dentin thickness changes before and

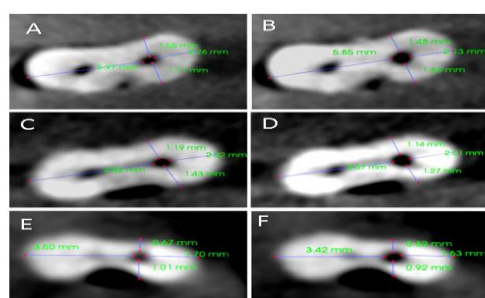


Figure 2: CBCT measurements; pre-instrumentation A: coronal, C: middle, E: apical and post-instrumentation B: coronal, D: middle, F: apical.

after preparation without the destruction of samples as reported by many investigators^{11,12,19}. In the present study, the three groups showed no significant difference in centering ratio or transportation. This could be attributed to several similarities between the three systems where they work in crown down technique, rotation motion, a similar degree of taper of each system, and terminated preparation with the same file tip diameter. This result is in agreement with Hussien et al.¹⁵ who found no significant difference between 2Shape, Neoniti, and PTN systems as they also work with the same parameters as the files in the present study, and with Katia E. et al.²³ who found no significant difference between Fanta file and azure file. Also, the results came in agreement with Tufenkci P et al.²⁴ who found that OC and PTN showed similar shaping abilities. Apical transportation values that are more than 0.3 mm can endanger the outcome of treatment due to a noticeable decrease in the sealing

ability of the Obturation material^{25,26}. None of the transportation values measured in this study surpassed this limit.

Conclusion:

All tested systems showed no statistically significant difference regarding canal transportation, and centering ability at each level of the canals (apical, middle, and coronal thirds) while the coronal thirds showed the highest value of transportation among the 3 systems.

References:

1. Tang W, Wu Y, Smales R. Identifying and reducing risks for potential fractures in endodontically treated teeth. *J Endod.* 2010;36(4):609–617.
2. Chethan M, K R, Natesan R, M R, M S, S Nair V. Preserved for endurance: Minimal invasive endodontics. *IP Indian J Conserv Endod.* 2021;6(2):88–91.
3. Talati A, Moradi S, Forghani M, Monajemzadeh A. Shaping ability of nickel-titanium rotary instruments in curved root canals. *Iran Endod J.* 2013;8(2):55–58.
4. Nayak A, Jain P, Kankar P, Jain N. On comprehensive analysis of root canal shaping ability of three endodontic files of different kinematics. *Proc Inst Mech Eng Part H, J Eng Med.* 2021;235(8):947–957.
5. Schneider S. A comparison of canal preparations in straight and curved root canals. *Oral Surg Oral Med Oral Pathol.* 1971;32(2):271–275.
6. Gambill J, Alder M, del Rio C. Comparison of nickel-titanium and stainless steel hand-file instrumentation using computed tomography. *J Endod.* 1996;22(7):369–375.
7. Rejula F, Christalin R, Ahmed W, Dinakaran S, Gopinathan A, Babu A. Measure and compare the degree of root canal transportation and canal-centering ability of twisted, protaper, and conventional stainless steel k files using spiral computed tomography: An in vitro study. *J Contemp Dent Pract.* 2017;18(6):463–469.
8. Hülsmann M, Rummelin C, Schäfers F. Root canal cleanliness after preparation with different

- endodontic handpieces and hand instruments: a comparative SEM investigation. *J Endod.* 1997;23(5):301–306.
9. Thompson S, Dummer P. Shaping ability of Hero 642 rotary nickel-titanium instruments in simulated root canals: Part 2. *Int Endod J.* 2000;33(3):255–261.
 10. Schilder H. Cleaning and shaping the root canal. *Dent Clin North Am.* 1974;18(2):269–296.
 11. El Batouty K, Elmallah W. Comparison of canal transportation and changes in canal curvature of two nickel-titanium rotary instruments. *J Endod.* 2011;37(9):1290–1292.
 12. Hashem A, Ghoneim A, Lutfy R, Foda M, Omar G. Geometric analysis of root canals prepared by four rotary NiTi shaping systems. *J Endod.* 2012;38(7):996–1000.
 13. Capar I, Ertas H, Ok E, Arslan H, Ertas E. Comparative study of different novel nickel-titanium rotary systems for root canal preparation in severely curved root canals. *J Endod.* 2014;40(6):852–856.
 14. Altunbas D, Kutuk B, Kustarci A. Shaping ability of reciprocating single-file and full-sequence rotary instrumentation systems in simulated curved canals. *Eur J Dent.* 2015;9(3):346–351.
 15. Hussien Y, Nabil Roshdy N, Galal Ghoniem A. Assessment of the Shaping Abilities of 2Shape, Neolix and Pro Taper Next Rotary Systems: A Comparative In vitro study. *Acta Sci Dent Sciencs.* 2020;4(4):71–78.
 16. Alrahabi M, Alkady A. Comparison of root canal apical transportation associated with Wave One, ProTaper Next, TF, and OneShape nickel–titanium instruments in curved canals of extracted teeth: A radiographic evaluation. *Saudi J Dent Res.* 2017;8(1–2):1–4.
 17. Sajad M, Ahmed A, Sagar M. Comparative evaluation of the shaping ability of single file system versus multiple file system in root canals of mandibular molars: An in-vitro study. *IJADS* 2018; 4(1): 17-20.
 18. Saberi E, Mollashahi N, Farahi F. Canal transportation caused by one single-file and two multiple-file rotary systems: A comparative study using cone-beam computed tomography. *G Ital Endod.* 2018;32(2):57–62.
 19. Fayyad D, Elgendy A. Cutting efficiency of twisted versus machined nickel-titanium endodontic files. *J Endod.* 2011;37(8):1143–1146.
 20. Elnaghy M, Elsaka S. Evaluation of root canal transportation, centering ratio, and remaining dentin thickness associated with ProTaper next instruments with and without glide path. *J Endod.* 2014;40(12):2053–2056.
 21. Hartmann M, Barletta F, Fontanella V, Vanni J. Canal Transportation after Root Canal Instrumentation: A Comparative Study with Computed Tomography. *J Endod.* 2007;33:962–965.
 22. Weine F, Kelly R, Lio P. The effect of preparation procedures on original canal shape and on apical foramen shape. *J Endod.* 1975;1(8):255–262.
 23. Kataia E, Nagy M, Kataia M, Khalil H. Shaping ability of two heat treated rotary NiTi instruments using different kinematics/in vitro study. *Bull Natl Res Cent.* 2021;45(1): 1-6.
 24. Tufenkci P, Orhan K, Celikten B, Bilecenoglu B, Gur G, Sevimay S. Micro-computed tomographic assessment of the shaping ability of the One Curve, One Shape, and ProTaper Next nickel-titanium rotary systems. *Restor Dent Endod.* 2020;45(3):1–11.
 25. Zanesco C, Só M, Schmidt S, Fontanella V, Grazziotin-Soares R, Barletta F. Apical Transportation, Centering Ratio, and Volume Increase after Manual, Rotary, and Reciprocating Instrumentation in Curved Root Canals: Analysis by Micro-computed Tomographic and Digital Subtraction Radiography. *J Endod.* 2017;43(3):486–490.
 26. García M, Duran-Sindreu F, Mercadé M, Bueno R, Roig M. A comparison of apical transportation between ProFile and RaCe rotary instruments. *J Endod.* 2012;38(7):990–992.