

## **The use of Nano graft combined with leukocyte-platelet rich fibrin in ridge preservation (A Randomized controlled Clinical and Histological study)**

*Mazen Mostafa Sayed\*, Prof. Dr. Ahmed Youssef Gamal \*\* and Dr. Waleed Mohamed Abbas \*\*\**

### **Abstract**

**Purpose:** The aim of the present study is to evaluate ridge preservation using Nano graft combined with leukocyte-platelet rich fibrin : Primary objective:

- Histomorphometrical analysis of bone quality. Secondary objective:
- Clinical measurements of dimensional changes before and after extraction.
- Cone beam computed tomography (CBCT) for assessment of dimensional changes before and after extraction.

### **Materials and method:**

Thirty six patients were selected from the outpatient clinic of Oral Medicine and Periodontology department, faculty of Dentistry, Ain Shams University.

**Result:** In the present study, it was found that the mean bone height decreased with a higher percent in (control group) than (nano graft combined with L-prf group and L-prf group) with a significant difference between control group and other two groups while there was no significant difference between nano graft combined with L-prf group and L-prf group. By histomorphometric analysis a higher mean surface area of newly formed bone was detected in L-prf group than nano graft combined

\* Student of Master Degree

\*\* Professor Of Oral Medicine, Periodontology, And Oral Diagnosis, Faculty Of Dentistry, Ain Shams University.

\*\*\* Lecturer Of Oral Medicine, Periodontology, And Oral Diagnosis, Faculty Of Dentistry, Ain Shams University

with L-prf group than control group with a significant difference between all groups.

Radiographically, CBCT revealed that a greater percent decrease in bone height was denoted in (control group) than ( nano graft combined with L-prf group and L-prf group) with a significant difference between control group and other two groups while there was no significant difference between nano graft combined with L-prf group and L-prf group.

Accordingly bone width showed a higher decrease in (nano graft combined with L-prf group) than (L-Prf group) than (control group) with a significant difference between all groups.

**Conclusion:** Extraction sockets grafted with nanocrystalline hydroxyapatite (nano graft) combined with L-prf group showed less bone resorption in horizontal direction than L-prf group than control group both clinically and radiographically. Extraction sockets grafted with nano graft combined with L-prf group and L-prf group showed less bone resorption in vertical direction compared to control group with no significant difference between nano graft combined with L-prf group and L-prf group both clinically and radiographically. L-prf group showed higher mean surface area of newly formed bone than nano graft combined with L-prf group than control group with a significant difference between all groups. A complete prevention of remodeling is not achievable, irrespective of the technique used.

**Keywords:** Nano graft combined - leukocyte-platelet.

## Introduction

Tooth extraction is one of the most widely performed procedures in dentistry. It has been historically well documented that this may induce significant dimensional changes

of the alveolar ridge <sup>(4)</sup>.

Horizontal buccal bone resorption has been shown to reach as much as 56%, lingual bone resorption has been reported to be up to 30%, and the overall reduction in width of the horizontal ridge has been reported to reach up to 50%. With this horizontal ridge resorption, the alveolar housing assumes a more lingual/palatal position, with possible negative effects on esthetics, phonetics, and function <sup>(10, 1)</sup>.

Although the bone resorption continues over time, the most statistically significant loss of tissue contour occurs during the first month after tooth extraction and can average up to 3 to 5 mm in width by 6 months <sup>(9)</sup>. Absorption is affected by multiple factors, like depth of the extraction socket, mucosa thickness, metabolic factors, and functional loading.

## Material and methods:

Group I (control group): Included 12 patients with single tooth extraction for each patient.

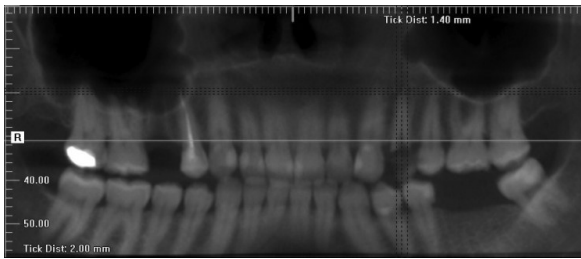
Group II (L-PRF alone): Included 12 patients undergoing single tooth extraction for each patient followed by socket fill with L-PRF.

Group III (Nano graft combined with L-PRF): Included 12 patients with single tooth extraction for each patient followed by socket fill with L-PRF combined with Nanocrystalline hydroxyapatite (nano graft).

## Surgical procedure:

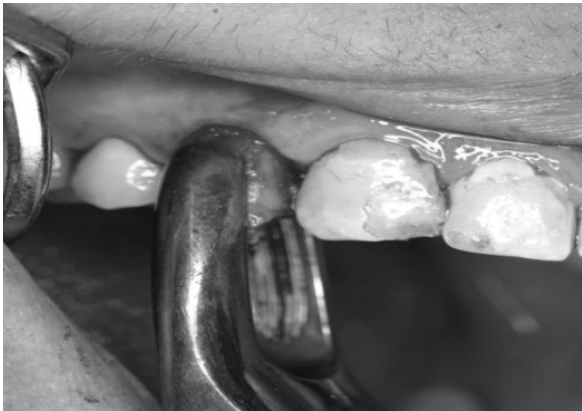### Extraction and Socket Augmentation Procedure:

1- Baseline cone beam computed tomography (CBCT) was done at day of extraction **figure (1)**.



**Figure (1): Panoramic view of CBCT showing badly decayed upper first premolar indicated for extraction.**

2- After administration of local anesthesia, atraumatic extraction was performed using periotome for severing the periodontal ligament with minimal trauma to the surrounding alveolar bone to facilitate removal of the involved tooth, to preserve bone and soft tissue then using extraction forceps for tooth extraction **figures (2).**



**Figure (2): Tooth removal after luxation.**

3- Socket curettage was done using bone curettes .

4- Clinical measurements were performed which included: (Crestal Bone height - Bone width).

#### **Preparation of L- PRF:**

A venipuncture will be performed, prior of performing any treatment. Blood will be drawn into sterile, plastic 10-mL tubes without anticoagulant. L-PRF clots and membranes will be prepared as described by Choukroun et al. (2001). The tubes will be immediately centrifuged at 2700 rpm for 12 min. using a table centrifuge . After centrifugation, each L-PRF clot will

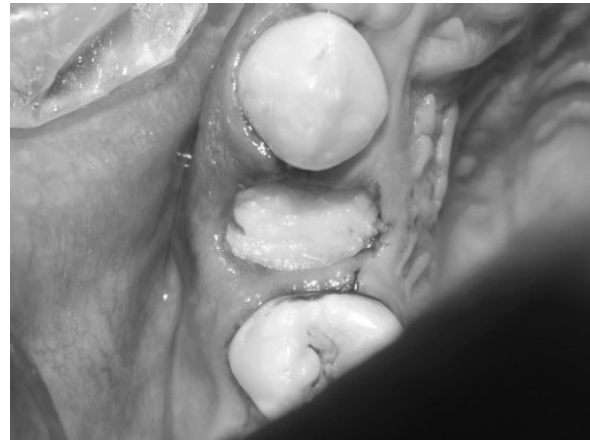be removed from the tube and separated from the red element phase at the base with pliers. L-PRF clots will be squeezed between a sterile glass plate and a metal box to obtain L-PRF membranes, equal in size and thickness figures (3).



**Figure (3): L-PRF box showing L-PRF**

5- For group (I) socket left without placing any grafting materials.

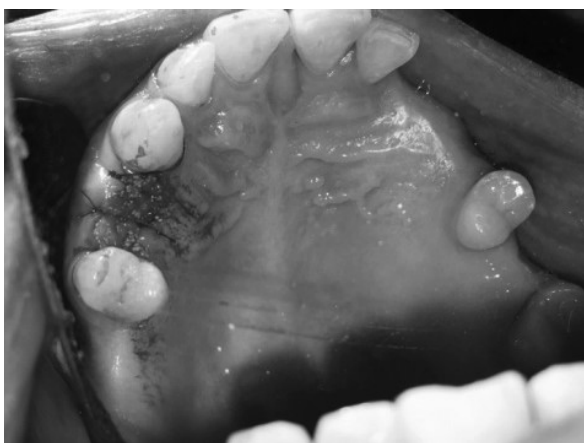6- For group (II) socket was filled by L-PRF figure (4).



**Figure 4: socket filled by L-PRF.**

7- For group (III) socket was filled by Nano graft mixed with L-PRF **figure (5).**

8- papilla approximation using 5/0 reverse cutting 3/8th polypropylene suture **figure (5).**



**Figure 5: socket filled by Nano graft mixed with L-PRF.**

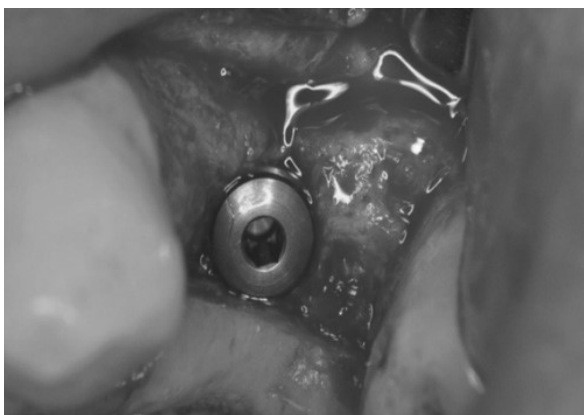9-Post-extraction instructions were given to the patient and medications were prescribed (Amoxicillin 500 mg, Metronidazole 500 mg twice/day and antiseptic chlorhexidine mouth wash for 1 week ) (Silvio et al., 2017).

#### **Implant placement and core biopsy procedure:**

1- After 3 months, another CBCT was done .

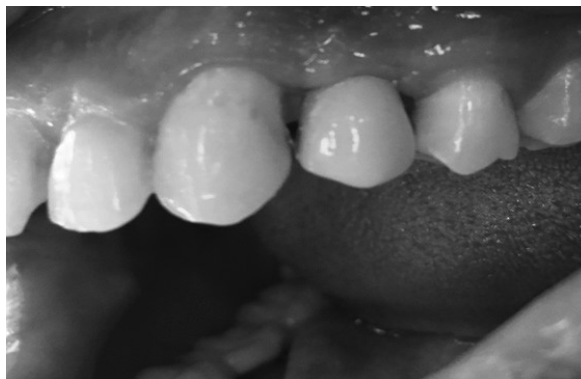2- Clinical measurements were repeated for the alveolar ridge bone height and width before implant placement.

3- An open flap reflection was done for core biopsy using trephine bur of 2.3mm diameter and 7mm length and placement of implant , and then flaps were closed (Silvio et al., 2017) figures (6).



**Figure (6): Implant in place and placement of cover screw.**

4- Three months later patients received the prosthetic part of implant restoration figures (7).



**Figure (7): Final restoration three months later after implant placement.**

## **Result :**

### **I-Histological assessment**

Histomorphometry: The highest mean value was recorded in L-PRF group ( $60.49 \pm 3.55$ ), followed by nano graft combined with L-prf group ( $41.68 \pm 2.08$ ), while the least value was in control group ( $28.95 \pm 2.28$ ). ANOVA test revealed that the difference between groups was statistically significant ( $p=0.00$ ). Tukey's post hoc test revealed a significant difference between each 2 groups.

### **II- clinical assessment**

#### **1-Bone height level:**

At baseline, the highest mean value was recorded in control group ( $5.75 \pm 1.56$ ), followed by nano graft combined with L-prf group ( $5.35 \pm 1.03$ ), while the least value was in L-PRF group ( $5.11 \pm 0.93$ ). ANOVA test revealed that the difference between groups was not statistically significant ( $p=0.541$ ).

After three months, the highest mean value was recorded in control group ( $8.75 \pm 0.77$ ), followed by L-prf group ( $7.42 \pm 1.00$ ) while the least value was in nano graft combined with L-PRF group ( $7.01 \pm 0.99$ ).

ANOVA test revealed that the difference between groups was statistically significant ( $p=0.0007$ ). Tukey's post hoc test revealed that L-PRF group was not significantly different from nano graft combined with L-PRF group, while both groups were statistically significant from control group.

Bone height level in nano graft combined with L-prf group mean value ( $-1.66 \pm 0.25$ ) significantly decreased after three months ( $P=0.00$ ), L-prf mean value ( $-2.31 \pm 0.57$ ) significantly decreased after three months ( $P=0.00$ ) and the control group mean value ( $-3.00 \pm 0.13$ ) significantly decreased after three months ( $P=0.00$ ).

The greatest percentage of change value was recorded in control group (54.53 %), followed by L-prf group (46.90 %) while the least percentage of change was in nano graft combined with L-PRF group (32.61 %). Kruskal Wallis test revealed that the difference between groups was statistically significant ( $p=0.006$ ). Post hoc test revealed that L-PRF group was not significantly different from each of the other 2 groups, while nano graft combined with L-prf group was statistically significant from control group.

## 2- Clinical bone width

At Baseline, the highest mean value was recorded in nano graft combined with L-PRF group ( $10.04 \pm 1.18$ ), followed by L-prf group ( $8.66 \pm 1.94$ ) while the least value was in control group ( $8.61 \pm 1.89$ ). ANOVA test revealed that the difference between groups was not statistically significant ( $p=0.094$ ).

After 3 months, the highest mean value was recorded in nano graft combined with L-PRF group ( $8.50 \pm 1.03$ ), followed by L-prf group ( $6.23 \pm 0.66$ ) while the least value was in control group ( $4.94 \pm 0.56$ ). ANOVA test revealed that the difference between groups was statistically significant ( $p=0.00$ ). Tukey's post hoc test revealed a significant

difference between each 2 groups.

Clinical bone width of nano graft combined with L-prf group mean value ( $1.54 \pm 0.47$ ) significantly decreased after three months ( $P=0.00$ ), L-prf mean value ( $2.42 \pm 0.53$ ) significantly decreased after three months ( $P=0.00$ ) and the control group mean value ( $3.68 \pm 0.67$ ) significantly decreased after three months ( $P=0.00$ ).

The greatest percentage of change value was recorded in control group (-42.50%), followed by L-prf group (-27.85%), while the least percentage of change was in nano graft combined with L-PRF group (-15.26 %). Kruskal Wallis test revealed that the difference between groups was statistically significant ( $p=0.000$ ). Post hoc test revealed a significant difference between each groups.

## III- Radiographic assessment (cbct )

### 1-Bone height:

At baseline, the highest mean value was recorded in control group ( $13.65 \pm 0.86$ ), followed by L-prf group ( $13.61 \pm 1.37$ ), while the least value was in nano graft combined with L-PRF group ( $12.46 \pm 1.18$ ). ANOVA test revealed that the difference between groups was not statistically significant ( $p=0.061$ ).

After three months, the highest mean value was recorded in L-PRF group ( $11.62 \pm 1.26$ ), followed by nano graft combined with L-prf ( $11.27 \pm 1.17$ ), while the least value was in control group ( $9.94 \pm 1.20$ ). ANOVA test revealed that the difference between groups was statistically significant ( $p=0.022$ ). Tukey's post hoc test revealed that L-PRF group was not significantly different from nano graft combined with L-PRF group, while both groups were statistically significant from control group.

Radiographic bone height of nano graft combined with L-prf group mean value

( $1.19 \pm 0.20$ ) significantly decreased after three months ( $P=0.00$ ), L-prf mean value ( $1.99 \pm 0.28$ ) significantly decreased after three months ( $P=0.00$ ) and the control group mean value ( $3.71 \pm 0.56$ ) significantly decreased after three months ( $P=0.00$ ).

The greatest percentage of change value was recorded in control group (-27.37%), followed by L-prf group (-14.66%), while the least percent decrease was in nano graft combined with L-PRF group (-9.61%). Kruskal Wallis test revealed that the difference between groups was statistically significant ( $p=0.000$ ). Post hoc test revealed a significant difference between each 2 groups.

## **2- Bone width:**

At baseline, the highest mean value was recorded in nano graft combined with L-prf group ( $9.14 \pm 1.96$ ), followed by L-prf group ( $7.62 \pm 1.85$ ), while the least value was in control group ( $7.48 \pm 1.83$ ). ANOVA test revealed that the difference between groups was not statistically significant ( $p=0.110$ ).

After three months, the highest mean value was recorded in nano graft combined with L-PRF group ( $8.10 \pm 0.92$ ), followed by L-prf group ( $5.69 \pm 0.71$ ), while the least value was in control group ( $4.36 \pm 0.63$ ). ANOVA test revealed that the difference between groups was statistically significant ( $p=0.00$ ). Tukey's post hoc test revealed a significant difference between each 2 groups.

Radiographic bone width of nano graft combined with L-prf group mean value ( $1.04 \pm 0.36$ ) significantly decreased after three months ( $P=0.00$ ), L-prf mean value ( $1.93 \pm 0.37$ ) significantly decreased after three months ( $P=0.00$ ) and the control group mean value ( $3.11 \pm 0.56$ ) significantly decreased after three months ( $P=0.00$ ).

The greatest percentage of change value was recorded in control group (-41.59%),

followed by L-prf group (-25.38%), while the least percentage of change was in nano graft combined with L-PRF group (-11.37%). Kruskal Wallis test revealed that the difference between groups was statistically significant ( $p=0.000$ ). Post hoc test revealed a significant difference between each 2 groups.

## **Discussion**

The fresh extraction socket in the alveolar ridge represents a special challenge in every day clinical practice. Regardless of the subsequent treatment, maintenance of the ridge contour will frequently facilitate all further steps of therapy. This is particularly true for treatments involving the placement of dental implants. It has been demonstrated in numerous animal and clinical studies that following tooth extraction, undisturbed wound healing will lead to loss of ridge volume and change in ridge shape <sup>(3)</sup>.

Alveolar bone and soft tissue remodeling is a normal physiological response following tooth extraction. These tissue changes have been recorded 40–60% decrease in the height and the width of the residual alveolar ridge <sup>(2)</sup>.

Literature has provided evidence in support to the fact that ridge preservation procedures reduce the bone dimensional changes compared with extraction without ridge preservation procedures <sup>(5)</sup>. However, systematic review demonstrates, in spite of employing evidence based ridge preservation techniques, a complete prevention of vertical and horizontal bone resorption is an unpredictable event <sup>(11)</sup>.

The adoption of alveolar ridge preservation (ARP) has been proposed as a method to significantly improve the aesthetic outcome of single-tooth implants, particularly in the anterior maxilla as it has been reported that they may help to retain sufficient bone at dental implant sites to

allow fixture placement <sup>(7)</sup>.

Moreover, Vignoletti et al. demonstrated a significantly smaller reduction in vertical and horizontal dimensions in ARP. However clinicians' choice of ARP technique often relies on personal preference rather than evidence of efficacy <sup>(12)</sup>.

The present study was conducted on thirty six patients, selected from the outpatient clinic of Ain Shams University. Patients were divided into three groups: nano graft combined with L-Prf group included twelve patients underwent ridge preservation, L-PRF group included twelve patients underwent ridge preservation and control group included twelve patients without any grafting materials. Strict inclusion and exclusion criteria were used during patient selection, to minimize the variables that may effect on the result.

All patients in our study were medically free in order to minimize the variables and to avoid any factors that may affect healing and liability to infection. <sup>(8)</sup>.

All patients in our study were nonsmokers since smoking is significant risk factor in alveolar ridge procedures and it is associated with poor treatment outcomes. Moreover, smoking is associated with increased loss of bone according to many studies.

According to the protocol for presurgical preparation, upper and lower impressions were taken to obtain a working model. Acrylic stents were made on the working model including at least one tooth adjacent to the tooth to be extracted to serve as a fixed reference guide for bone height level done using a standardized periodontal probe and a standardized bone caliper for bone width measurements; the measurements were done with the base of the stent as reference. The measurements were done immediately after extraction, and after three months <sup>(6)</sup>.

## Reference:

1. Botticelli D, Berglundh T, Lindhe J (2004): Hard-tissue alterations following immediate implant placement in extraction sites. *J Clin Periodontol*; 31:820-8.
2. Farmer M & Darby I (2014): Ridge dimensional changes following single-tooth extraction in the aesthetic zone. *Clinical Oral Implants Research* 25: 272–277.
3. Hammerle CH, Araujo MG and Simion M, Osteology Consensus Group 2011 (2012): Evidence based knowledge on the biology and treatment of extraction sockets. *Clinical Oral Implants Research* 23(5): 80–82.
4. Horowitz R, Holtzclaw D, Rosen PS (2012): A review on alveolar ridge preservation following tooth extraction. *J Evid Based Dent Pract* 12: 149-160.
5. Iasella JM, Greenwell H, Miller RL, Hill M, Drisko C, Bohra AA and Scheetz JP (2003): Ridge preservation with freeze-dried bone allograft and a collagen membrane compared to extraction alone for implant site development: A clinical and histologic study in humans. *J Periodontol*; 74(7): 990-999.
6. Mardas N, Trullenque-Eriksson A, MacBeth N, Petrie A & Donos N (2015): Does ridge preservation following tooth extraction improve implant treatment outcomes: a systematic review. *Clinical Oral Implant Research*. 1–12.
7. Madhan S, Govindaswamy G, Madhumati S, Singh T (2017): Comparison of Ability of Platelet-rich Fibrin vs CollaPlug in maintaining the Buccal Bone Height of Sockets following Extractions in 20 Patients *Journal of Health Sciences & Research*, January-June 2017;8(1):1-6.
8. Mombelli, A., & Cionca, N. (2006). Systemic diseases affecting osseointegration therapy. *Clinical oral implants research*, 17(S2), 97-103.

9. Nevins M, Camelo M, De Paoli S, Friedland B, Schenk RK, Parma-Benfenati S. et al. (2006): A 14. study of the fate of the buccal wall of extraction sockets of teeth with prominent roots. *Int J Period Restor Dent*; 26:19-29.

10. Schropp L, Wenzel A, Kostopoulos L, Karring T (2003): Bone healing and soft tissue contour changes following single-tooth extraction: a clinical and radiographic 12-month prospective study. *Int J Period Restor Dent*; 23: 313-23.

11. Ten Heggeler JM, Slot DE, van der Weijden GA (2011): Effect of socket preservation therapies following tooth extraction in non-molar regions in humans: A systematic review. *Clin. Oral Implants Res*, 22: 779–788.

12. Vignoletti F, Matesanz P, Rodrigo D, Figuero E, Martin C, Sanz M (2012): Surgical protocols for ridge preservation after tooth extraction. A systematic review. *Clinical Oral Implants Research*; 23 Suppl 5:22–38.