

COMPARATIVE STUDY OF THE EFFECTS OF NATURAL HONEY AND ANTACID (ALUMINIUM PHOSPHATE) ON THE ANTI-INFLAMMATORY AND ULCEROGENIC ACTIVITY OF INDOMETHACIN

By

A. M. Gaballah*, S. E. Zeid*, T.M. Ibrahiem, N. M. Gameil and
A. Abd El-Hamed.

From

*Depts. Pharmacology * & Pathology, Faculty of Medicine
and Dept. Pharmacology, Faculty of Pharmacy,
Mansoura University*

Received for Publication : 27 / 2 / 1989.

ABSTRACT

The effects of concurrent administration of either honey or aluminium phosphate with indomethacin on the anti-inflammatory activity, ulcerogenic activity and plasma level of indomethacin in rats were investigated in this study. Natural honey (3 gm/kg orally) caused a significant decrease of ulcerogenic activity of indomethacin (30 mg/kg orally) as indicated by the gross lesion score and histopathological examination. This effect induced by honey is comparable to that produced by colloidal aluminium phosphate (3 gm/kg orally). Also honey caused a

marked decrease of indomethacin-induced gastric acid secretion that was not significantly different from that produced by aluminium phosphate.

Both indomethacin-honey and indomethacin-aluminium phosphate combinations caused a decrease of anti-inflammatory activity and plasma level of indomethacin but the reduction produced by the first combination was found to be significantly less than that produced by the second combination. These data may justify the use of honey concurrently with indomethacin to suppress its deleterious effect

on the gastric mucosa with less disturbance of its plasma level and anti-inflammatory activity than its concomitant use with antacid.

INTRODUCTION

Natural honey is prepared by bees from the nectars of various plants. It has occupied a prominent place in medicine throughout the world history. The revelation in Holy Koran (sura XV, Al-Nahl, Verses 68 & 69) clearly described the effectiveness of honey in various diseases (Amir Ali, 1974). It is noteworthy that the first report on the use of honey in the treatment of gastrointestinal disorders was documented in Bukhari collection of Hadith (Khan, 1977). However, systematic scientific studies of its medical attributes are lacking.

There are some scattered reports in the literature regarding the effectiveness of honey in gastrointestinal disorders (Salem, 1981 and Haffejee & Moosa, 1985), wound healing (Cavanagh et al., 1970 and Bergman et al., 1983) and as an antimicrobial agent (Ibrahim, 1981 and

Obaselliebor et al., 1983).

The aim of the present study was to investigate the effect of honey on the gastric lesions and excessive gastric secretion induced by indomethacin in rats. Also, to study its effect on the anti-inflammatory activity and plasma level of indomethacin.

MATERIAL AND METHODS

- * Natural honey was obtained from the plant protection department, Faculty of Agriculture, Mansoura University, Egypt.
- * Indomethacin (Indocid, 25 mg/capsule, Merck).
- * Colloidal aluminium phosphate (Phosphalugel packet, 11 gm/packet, Biotherax).
- * Male albino rats, approximately of the same age, weighing 150-200 gm were housed under similar conditions and fed similar diet of bread and milk with free access to water. Rats were starved for 48 hours before experiment, but

water was allowed. Animals were randomly coded into groups of 18 rats, which were then subjected to the planned treatments outlined below:

- * **Group (I)**) Received 1 ml saline orally (control group).
- * **Group (ii)**) Received indomethacin 30 mg/kg orally as an aqueous suspension (Cho et al., 1985).
- * **Group (iii)**) Received honey 3 gm/kg (Ali et al., 1990) and indomethacin 30 mg/kg orally.
- * **Group (iv)**) Received colloidal aluminium phosphate 3 gm/kg and indomethacin 30 mg/kg orally. The dose of aluminium phosphate was equivalent to the average human therapeutic dose as calculated according to Paget and Barnes(1964).

In all groups the final volume of fluid administered to each rat was equal to 1 ml.

Evaluation of Gastric Lesions :

Six rats out of each groups were sacrificed 5 hours after receiving various treatments. The stomachs were gently dissected out, opened along the greater curvature, washed with saline and randomized so that the examiner had no knowledge of treatment given. They were examined with X 6.4 binocular magnifier. The mucosal lesions per stomach were counted and the mean was calculated for each group (Kolbasa et al., 1988). The percent protection with honey or aluminium phosphate was determined by comparison with the group which received indomethacin alone. After scoring the gross lesions, the stomachs were preserved in 10% buffered formaline. Blocks were prepared from pieces of the stomachs. Tissue sections were stained with haematoxylin and eosin for histopathological examination in a blind fashion.

Determination of Gastric Acidity:

Five hours after administration of various treatments, 6 rats from each group were anaesthetized with I. P. injection of urethan 1.8 gm/kg and prepared for measurement of gastric acid output according to the method described by Punrunen and Karpanen (1975). Briefly, the trachea was cannulated and rat was allowed to breathe spontaneously. A polyethylene cannula was introduced into the stomach through an incision in the duodenum and ligated about 0.5 cm away from the pylorus, the stomach was then irrigated with 5 ml normal saline at 37°C, left for 20 minutes and 4 ml. of the recovered solution was titrated against 0.1 N sodium hydroxide to pH 7.

Assessment of Anti-inflammatory Activity and Determination of Plasma Level of Indomethacin :

One hour after administration of various treatments, 6 rats from each group were injected with 0.05 ml. carrageenin solution (1%) subcutaneously into the planter surface of the left hind paw. The right paw was injected

with 0.05 ml. of normal saline. Three hours after administration of various treatments, which coincide with peak plasma level of indomethacin according to Woodburg and Fingl (1975), blood samples were taken from retro-orbital sinus under light ether anaesthesia, plasma was separated for determination of indomethacin level using the spectrofluorophotometric method (Huncker et al., 1966).

Twenty four hours after carrageenin, the thickness of the hind feet were measured by paw oedemameter. The difference between the thickness of the left and right paws represents the amount of inflammatory oedema induced by carrageenin. The mean percent difference was calculated for the control and treated groups. The percent reduction of oedema was calculated and taken as a measure of anti-inflammatory activity (Winter et al., 1962).

In order to investigate the effect of natural honey orally administered on the plasma level of intraperitoneally injected indomethacin, two additional

groups of rats were added each of 6 rats. One group received indomethacin 30 mg/kg I. P. and the second group received natural honey 3gm/kg orally and indomethacin 30 mg/kg I.P. After one hour, plasma samples were collected from both groups and indomethacin plasma level was determined as mentioned before.

RESULTS

1- Evaluation of Gastric Lesions :

A) Macroscopic Findings :

There was no macroscopic evidence of mucosal injury in any of the specimens from the control group receiving saline. Administration of indomethacin resulted in production of gastric mucosal damage mainly in the corpus of the stomach in 100% of animals. The lesions occurred in a linear fashion on the mucosal ridges and had the appearance of mucosal thickening, oedema, erosions and haemorrhages. Administrations of honey or aluminium phosphate concurrently with indomethacin significantly reduced the gastric lesions produced by indomethacin. There were 73% and 75% protection against indomethacin

induced gastric damage with honey and aluminium phosphate respectively. There was no statistically significant difference between the effect of honey or aluminium phosphate ($P>0.05$) as illustrated in table (1).

B- Microscopic Findings :

- * Control Group: The mucosa of the stomach appeared more or less normal (Fig. 1).
- * In indomethacin exposed group, the stomach is severely affected in the form of acute erosive gastritis which showed extensive hyperaemia, infiltration of superficial mucosa by lymphocytes, macrophages and neutrophils. There was areas of eroded mucosa. Other parts showed acute ulceration, where the mucosa is completely destroyed with extensive infiltration of submucosa by acute inflammatory cells (Fig. 2).
- * In contrast, when indomethacin was administered concurrently with honey or aluminium phosphate, there was complete

absence of congestion, haemorrhage and no inflammatory cell in the superficial mucosa. Only occasional localized erosions with mild inflammatory infiltrate (Figs. 3,4) .

II- Effect of Honey and Aluminium Phosphate on Indomethacin Induced Gastric Acid Secretion :

Table (II) shows that indomethacin alone caused significant increase of gastric acid concentration. The concomitant administration of indomethacin with honey resulted in increase in gastric acid concentration which was significantly, less than that produced by indomethacin alone and was not significantly different from the control. Combination of indomethacin with aluminium phosphate produced a significant increase of gastric acid concentration compared with control but was significantly less than the acid secretion produced by indomethacin alone. On the other hand there was no significant difference in the concentration of gastric acid between the group treated with indomethacin and honey and that

treated with indomethacin and aluminium phosphate ($P > 0.05$).

III- Anti-inflammatory Activity of Indomethacin Alone or in Combination with Honey or Aluminium Phosphate in Rat Paw Oedema Test:

Table (III) shows that administration of indomethacin alone or in combination with honey or aluminium phosphate have a significant anti-inflammatory activity as compared to the control group. However, the anti-inflammatory activities of these combinations were significantly less than that of indomethacin alone. The anti-inflammatory activity of indomethacin-honey combination was significantly higher than indomethacin-aluminium phosphate combination.

IV- Effect of Concomitant Administration of Indomethacin With Either Honey or Aluminium Phosphate on Plasma Level of Indomethacin :

Honey and aluminium phosphate caused significant reduction of indomethacin plasma level. However,

aluminium phosphate produced more reduction of indomethacin plasma level than that produced after addition of honey (Table IV).

Also, it was noticed that there was no significant difference in the plasma indomethacin level after I.P. injection of indomethacin alone or in combination with oral honey ($P > 0.05$, Table V).

DISCUSSION

Indomethacin has been widely used to induce experimental gastric lesions in animals (Kolbasa et al., 1988 and Cho et al., 1985). It blocks prostaglandin synthesis, and this was accepted as a major factor in the pathogenesis of the gastrointestinal lesions caused by indomethacin (Lippman, 1974; Van Kolfaschoten et al., 1983 and Inaven et al., 1988). In addition to blocking gastric acid secretion, prostaglandins at a concentration that do not block acid secretion appear to be capable of protecting the gastric mucosa from the ulcerogenic effects of indomethacin (Vapaatalo and Ylikorhola, 1984).

In the present study honey produced a significant protection against indomethacin induced gastric damage. This finding is in agreement with that reported by Ali et al. (1990), who stated that honey had a dose dependent protective effect against gastric damage caused by indomethacin. The gastric cytoprotective effect of honey was found to be comparable statistically to the effect produced by the antacid colloidal aluminium phosphate.

The second important finding in the present study which may explain the gastric cytoprotective effect of honey was the significant reduction of gastric acid concentration by concurrent administration of honey with indomethacin. The effect of honey on gastric acid concentration may be attributed to several factors viz : the hypertonic nature of honey may play an important role in inhibition of gastric acid output , as it was found that the introduction of hypertonic solutions into the duodenum of man and dogs inhibited gastric acid secretion (Kaulbersz and Konturck, 1962). Honey due to its colloidal nature may adsorb HCl in the stomach

(Radwan et al., 1989). Acidification of the antral mucosa was found to suppress tonic release of gastrin and honey is known to be acidic in nature pH 3.6 (Anderson & Oble, 1964). They also suggested that acidification of antral mucosa may represent a negative feed - back, which inhibits gastrin production and hence decreases gastric acid secretion. Moreover, Thompson (1966) postulated that when an acid gets in contact with the pyloric mucosa a special inhibitory factor called gastrone is released from antral mucosa and inhibits gastric acid secretion.

The gastroprotective effect of honey may be attributed to this observed inhibition of gastric acid concentration through decreasing the acid erosive effect on the mucosa and changing the optimal pH for pepsin activity (Radwan et al., 1989). However, other possible mechanisms for the protective effect of honey against indomethacin-induced mucosal damage may be suggested although they were not investigated in the present study. It may be argued that the protective

effect of honey may be due to high carbohydrate content (Hegazy et al., 1981). However, Ali et al. (1990) reported that a mixture containing the same proportions of carbohydrates as found in natural honey failed to offer any protection. This indicates that additional or other factors are involved. Relevant to this is the report that as many as 181 substances are contained in honey (White, 1975), some of which may be involved in mediating its antiulcerogenic action. It is also possible that the demulcent and hygroscopic effects of honey may aid in forming a protective coating as well as in causing a reduction of oedema as evidenced by its ability to promote healing when applied topically to corneal ulcers (Ioyrisb, 1977) or to wounds (Bose, 1982 and Bergman et al., 1983).

Honey was reported to suppress gastric pepsin secretion and/or activity (Radwan et al., 1989), this antipeptic effect of honey may be significant to its gastroprotective activity. Furthermore, the reduction of indomethacin plasma level and counteraction of

indomethacin -induced inhibition of prostaglandins synthesis (Robinson, 1983) may be involved in the mechanism of gastroprotective effect of honey against indomethacin induced gastric damage. In support to this assumption, the gastric damage which was not mainly due to reduction in prostaglandins like that produced by ethanol was less antagonised by honey (Ali et al., 1990).

The concurrent oral administration of honey with indomethacin to rats reduced significantly the plasma indomethacin level; an effect which can be attributed to the decrease of intestinal absorption of indomethacin. Such postulation is supported by our finding that concurrent administration of natural honey orally and indomethacin intraperitoneally did not produce any significant change of indomethacin plasma level. The reduction of the plasma indomethacin level produced by the concurrent administration of colloidal aluminium phosphate was significantly more than that produced by concurrent administration of honey and it is mostly due to decreased

indomethacin absorption (Galeazzi, 1977 and Garnham, 1977).

An important point investigated in this work was the effect of either honey or aluminium phosphate on the antiinflammatory activity of indomethacin. Both were found to reduce its anti-inflammatory activity. However, the suppressive action of aluminium phosphate on the anti-inflammatory activity of indomethacin was much pronounced. Again, this may be attributed to the decreased plasma indomethacin level and /or counteracting indomethacin-induced inhibition of prostaglandins synthesis (Robinson, 1983).

Although honey produced statistically more or less an equal effect to aluminium phosphate in protecting against indomethacin-induced gastric damage and gastric acid secretion, yet, honey has the advantage that it produced reduction of indomethacin plasma level and indomethacin anti-inflammatory activity less than that produced by aluminium phosphate. These results may suggest that honey may be more preferable than antacids

to be used clinically in combination with potentially ulcerogenic non - steroidal anti - inflammatory drugs like indomethacin to prevent or reduce the occurrence of gastric lesions without much reduction of their anti-inflammatory action. However, further work is required to explore the Possible mechanism (s) of these observations and to evaluate their clinical applications.

Table (1) : Effects of Honey and Aluminium Phosphate on Indomethacin - induced Gastric Lesions In Rats.

Group No.	Treatment	Gross Lesion score	% Protection
I	Saline orally (4 ml / rat) .	0	-
II	Indomethacin orally (30 mg / kg)	1206 \pm 1.01	-
III	Indomethacin (30 mg / kg) + Honey (3 gm / kg) orally	3.4 \pm 0.23*	73
IV	Indomethacin (30 mg / kg) + Aluminium phosphate (3 gm / kg) orally	3.1+0.21*@	75

- Values are expressed as the mean of six animals \pm the standard error of this mean and compared using student's t - test.

- % Protection indicates the % reduction of gastric lesions.

* Significant difference from Indomethacin group at ($P < 0.05$) .

@ Non - significant difference from Indomethacin - honey group ($P > 0.05$) .

Table (2) : Effect of Honey or Antacid on Indomethacin induced Gastric Acid Secretion in Rats

Treatment	Mean concentration of gastric acid (mEq / L / h \pm S. E.)	% Change of acid conc.	% decrease in indomethacin gastric acid concentration
Control.	20 . 47 + 1. 85	-	-
Indomethacin (30 mg / kg) orally.	36 . 86 + 2.92*	80	-
Indomethacin (30 mg / kg) + Honey (3 gm / kg) orally.	24.84+2.18 @	21	32.6
Indomethacin (30 mg / kg) + Aluminium phosphate (3 mg / kg) orally .	28.3 + 2.65* @	38	23

* Significant difference from control at (P < 0.05) .

@ Significant difference from indomethacin alone at (P < 0.05) .

Table(III) : Anti - inflammatory Activity of Indomethacin Alone or in Combination with either Honey or Antacid in Rat Paw Oedema Test

Treatment	Mean % Change in thickness of rat paw \pm S. E.	% Reduction of inflammation.
Control.	92.25 \pm 6.3	-
Indomethacin (30 mg / kg) orally.	30.30 \pm 1.25*	67.2
Indomethacin (30 mg / kg) + Honey (3 gm / kg) orally.	40.20+2.95*	56.4
Indomethacin (30 mg / kg) + Aluminium phosphate (3 mg / kg) orally .	51.60+3.29* @	44.4

* Singnificantly less than control at P < 0.05

- Significantly higher than indomethacin alone at P < 0.05 .

@ Significantly higher than indomethacin - honey combination at P < 0.05

Table (IV) : Effect of Concomitant Oral Administration of Indomethacin with either Honey or Antacid on Plasma Level of Indomethacin in Rats.

Treatment	Mean Plasma level of Indomethacin ug / dl + S. E.
Indomethacin (30 mg / kg) orally.	7.3+0.34
Indomethacin (30 mg / kg) + Honey (3 gm / kg) orally.	6.2 + 0.32
Indomethacin (30 mg / kg) + Aluminium phosphate (3 mg / kg) orally .	5.1 + 0.29 ^o

* Singnificantly less than indomethacin alone at $P < 0.05$.

o Significantly less than indomethacin + honey at $P < 0.05$.

Table (V) : Effect of Concomitant Oral Administration of Indomethacin (I. P.) and Honey (Orally) on Plasma level of Indomethacin in Rats.

Treatment	Mean Plasma level of Indomethacin ug / dl + S. E.
I. P. Indomethacin (30 mg / kg)	9. 2 \pm 0. 52
I. P. Indomethacin (30 mg / kg) Oral Honey (3 gm / Kg)	8. 89 \pm 0.65 *

* Non - Significant difference from indomethacin group ($P > 0.05$)




Fig. 1: Stomach of control rat X 100 with no significant pathological lesions.

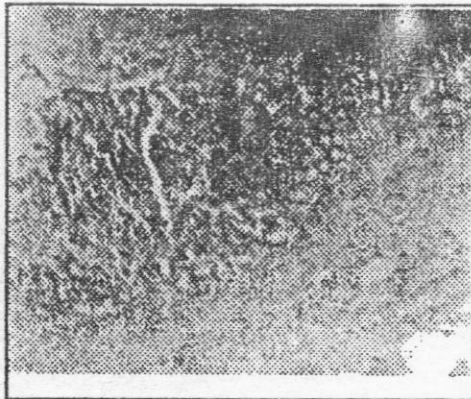


Fig. 3 : Stomach of rat received indomethacin. It shows margin of gastric ulceration X 100.

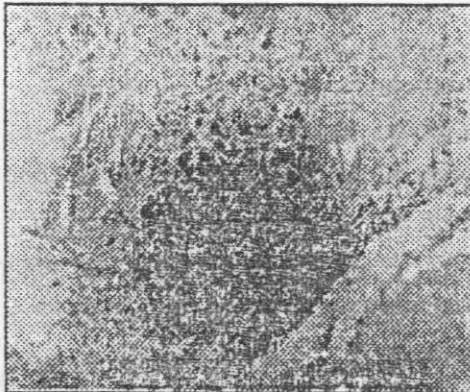


Fig. 2 : Stomach of rat received indomethacin x 100 . It shows extensive erosion & inflammatory infiltrate in the mucosa & submucosa.




Fig. 4: Stomach of rat received honey and indomethacin X 100 It shows marked decrease in inflammatory cells & very mild superficial erosion.

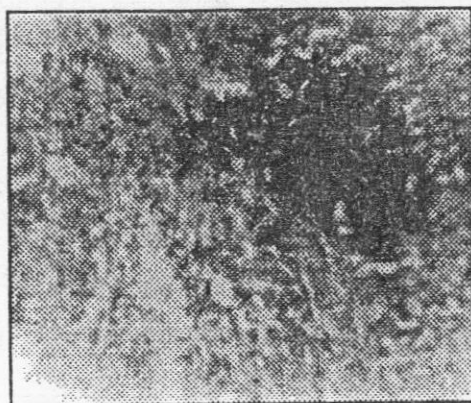


Fig. 5 : Stomach of rats received antacid & indomethacin X 100. It shows little inflammatory cells in the mucosa & submucosa.

REFERENCES

- All, A. M.; Al-Humayyd, M. S. and Madan, B. R. (1990) :** Saudi Med. J., 11 (4) : 775 - 279.
- Amir - Ali, H. (1974) :** The message of the koran 1st ed. Tokyo; Charles E. Tuttle Co. 395 - 453.
- Anderson, S. and Oble, L. (1964) :** Acta Physiol. Scand., 61 : 55.
- Bergman, A.; Yanai, T. and Weiss, J. (1983) :** Am. J. Surg., 145 : 374.
- Bose, B. (1982) :** Lancet, 22 : 963.
- Cavanagh, D.; Beazley, T. and Ostapowicz, F. (1970) :** J. Obstet. Gynecol. Br. Common, 77 : 1037.
- Cho, C. H.; Ogle, C. W. and Wong, S. H. (1985) :** Digestion, 32 : 288.
- Galeazzi, R. L. (1977) :** Eur. J. Clin. Pharmacol., 12 : 65.
- Garnham, J. C. (1977) :** Postgrad. Med. J., 53 : 126.

- Haffejee, I. E. and Moosa, A. (1985) : Kaulbersz, J. and Konturck, S. J.
Br. Med. J., 290 : 1886. (1962) : Gastroenterology, 43:
457.
- Hegazy, M.R. ; El-Zayat, A.F. and Ibrahim, M. (1981) : Proc. Khan, M. M. (1977) : The translation
conference of pharmacol. of meaning of Sahih Al-
and Drug Evaluation, Cairo, Bukhari Vol. VII 1st ed. Al-
Abstract, P.26. Madina Al-Munawara : Is-
lamic University, 395 : 453.
- Huncker, H. B.; Zacchel, A. G.; Cox, S. V.; Brodie, D. A. and Kolbasa, K. P. ; Lancaster, C. and
Cantwell, N. H. R. (1966) : Olafsson, A. (1988) : Gas-
J. Pharm. Exp. Ther., 153 : troenterology, 95 : 932.
237.
- Ibrahim, A. S. (1981) : Proceedings of Lippman, W. (1974) : Prostaglandins,
the first international confer- 7 : 1 (1974) .
ence on Islamic Medicine, Obaseiki-Ebor, E. and Afonya, T.
Kuwait Bulletin of Islamic (1983) : J. Pharma. Pharma-
Medicine, 1 : 363. col, 35 : 748.
- Inaven, W.; Wyss, P. A. and Kayser, Paget, G. E. and Barnes, J. M.
S. (1988) : Gastroenterolo- (1964) : Evaluation of drug
gy, 95 : 636. activities, Pharmacometric,
laurence, D. R. and Bacha-
rach, A. L. (eds). Vol.1,
Chap.6, P.135, Academic
Press London and New
York.
- Ioyrisb, N. (1977) : Bees and People
2nd ed. Mir, Publications,
Mosco, U.S.S.R.

- Punrunen, J. and Karpanen, H.** (1975) : Life Sci., 16 : 1513.
- Radwan, A. G. ; Kandil, M.S. and Hassan, G. M.** (1989) : J. Egypt. Soc. Pharmacol. Exp. Ther., 8 (1) : 145.
- Robison, D. R.** (1983) : Am. J. Med., Suppl. 13 : 26.
- Salem, S. N.** (1981) : Proceedings of the first international conference of Islamic Medicine. Kuwait Bulletin of Islamic Medicine, 1 : 358.
- Thompson, J.C.** (1966) : In Gastrin, 193. M.I. Grossman (ed.) Barkeley and Los Angeles : University of California.
- Van Kolfshoten, A.; Hagelen, F. and Hillen, E.X.** (1983) : Dig. Dis. Sci., 28 : 1127.
- Vapaatalo, H. and Ylikorhata, O.** (1984). Ann. Clin. Res., 16 : 225.
- White, I.W. Jr.** (1975) : Composition of honey, In : Carne E. ed. Honey, a comprehensive Survey, London, Heinemann, 157, 206.
- Winter, C.A.; Ristey, E.A. and Nuss, G.W.** (1962) : Proc. Soc. Exp. Biol. Med., 111 : 544.
- Woodburg, D.M. and Fingl, E.** (1975) : In "The Pharmacological Basis of Therapeutics, 5th ed. by L.S. Goodman, & A. Gilman, Macmillan Publishing Co., Inc. New York, P. 342.

مقارنه تأثير عسل النحل الطبيعى ومضاد الحموضه (الومنيوم فوسفات) على النشاط التقرحى والمضاد للالتهابات للاندوميثاسين

د / على محمد جاب الله د / صبرى زيد د / طارق إبراهيم

د / ناريمان جميل د / عزمى عبد الحميد (باثولوجى)

من اقسام الفارماكولوجى - والباثولوجى بطب المنصوره - قسم الفارماكولوجى بصيدلة المنصوره

فى هذا البحث تم دراسة تأثير اعطاء عسل النحل الطبيعى أو مضاد الحموضه (الومنيوم فوسفات) عن طريق الفم (٣ جم / كج) على النشاط التقرحى والمضاد للالتهابات للاندوميثاسين وعلى مستوى الاندوميثاسين فى بلازما الجرذان البيضاء .

وجد أن إعطاء عسل النحل يقلل من نشاط الاندوميثاسين التقرحى فى المعدة قليلا ذو دلالة احصائية هامه مماثله الى حد كبير لتأثير الالومنيوم فوسفات وايضا يسبب انخفاض ملحوظ لتركيز الافراز الحمضى للمعدة الناتجه عن اعطاء الاندوميثاسين لا يختلف كثيرا عن نسبة هذا الانخفاض الذى يسببه الالومنيوم فوسفات .

اعطاء كل من الاندوميثاسين وعسل النحل معا أو الاندوميثاسين والالومنيوم فوسفات معا يقلل من النشاط ضد الالتهاى ونسبة الاندوميثاسين فى البلازما ولكن الانخفاض الذى يسببه عسل النحل اقل احصائيا من الذى يسببه الالومنيوم فوسفات .

وعلى ضوء هذه النتائج يمكن تفضيل اعطاء عسل النحل الطبيعى مع الاندوميثاسين لحماية المعدة من التأثير المقترح للاندوميثاسين . ذلك لان عسل النحل الطبيعى يعطى حماية للمعدة مماثله لتلك التى يعطيها مضاد الحموضه (الومنيوم فوسفات) ولكن عسل النحل لا يقلل نشاط الاندوميثاسين المضاد للالتهابات بنفس الدرجة التى يسببها استخدام الالومنيوم فوسفات .

My dear Mr. Gladstone, I have the pleasure to acknowledge the receipt of your letter of the 10th inst. and in reply to inform you that the same has been forwarded to the proper authorities for their consideration.

I am, Sir, very truly, Sir, your obedient servant,
 Wm. E. Gladstone

I have the honor to acknowledge the receipt of your letter of the 10th inst. and in reply to inform you that the same has been forwarded to the proper authorities for their consideration.

I have the honor to acknowledge the receipt of your letter of the 10th inst. and in reply to inform you that the same has been forwarded to the proper authorities for their consideration.

I have the honor to acknowledge the receipt of your letter of the 10th inst. and in reply to inform you that the same has been forwarded to the proper authorities for their consideration.

I have the honor to acknowledge the receipt of your letter of the 10th inst. and in reply to inform you that the same has been forwarded to the proper authorities for their consideration.

I have the honor to acknowledge the receipt of your letter of the 10th inst. and in reply to inform you that the same has been forwarded to the proper authorities for their consideration.