

# EVALUATION OF SPIRONOLACTONE TREATMENT IN ACNE VULGARIS IN FEMALES

*By*

**Abdel-Naby S. E.; Eid M. M. and Abo-Hashem, E. M.**

*From*

*Department of Dermatology and Venereology and  
Clinical Pathology Mansoura University*

*Received for Publication : 25/11/1989*

## INTRODUCTION

Spironolactone is an aldosterone antagonist and an anti-androgen. Its anti-androgenic properties have been shown to be beneficial in the treatment of acne vulgaris (Boisselle and Tremblay, 1978).

Spironolactone was shown to reduce sebum excretion rates and the clinical effect was found to be dose independent (Goodfellow et al., 1984). The ways by which spironolactone exerts its anti-androgenic effects are not fully understood. It appears to inhibit testosterone biosynthesis by blocking cytochrome p 450 enzymes in the adrenal gland and testis (Menard and Stripp, 1974) and may also affect ovarian androgen synthesis

(Muhlemann et al., 1986). Spironolactone also act peripherally by inhibiting the binding of dihydrotestosterone (DHT) to nuclear and cytosolic receptors in target tissues such as the skin and prostate (Corvol et al., 1975).

Sebaceous gland activity is regulated by androgens (Strauss and Pochi, 1974) and is affected consequently by spironolactone or its chief metabolite potassium canrenoate, blocking the effects of DHT on sebaceous gland androgen receptors (Muhlemann et al., 1986).

In our study we would like evaluate the efficacy of spironolactone (100 mg daily) for female patients with acne and monitored its effect on their

androgen status.

## MATERIALS AND METHODS

Twenty women with moderate to severe acne attending the out-patient clinic of Mansoura University Hospital entered the trial. In addition ten carefully selected, normal matched females taken as a control. No antibiotics were administered during the month that preceded the trial and no topical treatment was allowed during the study.

The patients were advised to avoid pregnancy and oral contraceptives during the study. All the patients were subjected for pelvic and abdominal ultrasound for diagnosis of ovarian masses and superarenal tumours.

Blood samples were taken from each patient before and 3 months after spironolactone treatment for assay of plasma testosterone and sex hormone binding globulin (SHBG).

Radioimmunoassay of testosterone was done by the method of Collins et al., (1972), SHBG by the method of

Iqbal and Johnson (1977), free testosterone index Wd5 obtained by the following equation,  $\frac{\text{total testosterone}}{\text{SHBG}} \times 100$  et al., 1983).

All patients received spironolactone 100 mg/day after breakfast starting from the 4th day of the cycle until the 22 nd day for patients with regular cycles. These with irregular cycles received the drug for 20 days followed by a 7 days drug-free period. The clinical response was evaluated by subjective, objective and photographic assessments according to Goodfellow et al., (1984). Then, our patients were categorised into, those with moderate to marked response (a score of more than 65 degree) and those with mild response ( a score of 65 or less degree).

Statistical analysis used were, mean value standard deviation (Burn et al., 1952) and student "T" test (Petrie, 1978) .

## RESULTS

Of the original twenty patients, 14 completed the trial. Two patients

withdrew due to occurrence of pregnancy during therapy and four failed to return after the initial interview. The age of the patients ranged from 18-35 years (mean age 23.y years). The results were tabulated and statistically analysed according to the student "T" test and these results can be summarised as follows :

#### **Radiological Findings (Table I) :**

50% of acne patients had polycystic ovarian changes, while no abnormalities of suprarenal gland could be detected.

#### **Initial Hormonal Levels :**

On comparing hormonal values of T, SHBG and FTI in all patients before treatment with the control group. Statistical analysis revealed significant increase of T and FTI, while SHBG showed insignificant difference as shown in table (2) and illustrated in figure (1).

We have found also that patients with polycystic ovary had higher total testosterone "T" levels than those without polycystic ovary and patients

above 70 kg had higher levels of FTI and lower SHBG than those below 70 kg.

#### **Hormonal Levels and Clinical Response Findings After Treatment:**

Hormonal values in the patients before and after spironolactone treatment were tabulated in table (3) and illustrated in fig. (2). The results showed significant decrease of (T) level after treatment while the changes in both SHBG and FTI levels were insignificant. Results revealed that the percent decrease of T was higher in patients with polycystic ovary than those without polycystic ovary and the percent decrease of T level was higher in patients with moderate acne than those with severe acne.

#### **Side Effects :**

The most frequently reported side effect is headache (3 patients) and drowsiness (3 patients) followed by oligomenorrhea in patients and polymenorrhea in 2 patients and one patient suffered from initial exacerbation of acne.

## DISCUSSION

There is now considerable data to suggest that androgens are important in the pathogenesis of acne (Lawrence et al., 1981) especially in the more severe forms (Marynick et al., 1982). This idea is supported by the present study which revealed significant increase of T and FTI in acne patients than the control group ( $P < 0.05$ ), this is in agreement with the results of Odland et al., (1982).

Antiandrogens offer promise in the treatment of acne vulgaris. Oral cyproterone acetate has been used in several studies (Hammerstein et al., 1975), but side effects may limit its use (Braendle et al., 1974). Topically applied antiandrogens have also been used (Fryolle, 1975), but results have not been impressive (Goodfellow et al., 1984).

Spironolactone is a widely used drug in the treatment of hypertension and fluid retention states. Well-known side-effects include gynaecomastia in men and menstrual disturbance in women, reflecting a series of

endocrine changes related to inhibition of androgen binding to receptors, as well as increased oestrogen secretion (Tidd et al., 1978). In our study, the drug was well tolerated at 100 mg daily, only headache and some menstrual disturbances being noted by some patients.

Sex hormone binding globulin (SHBG) in all of our patients were insignificantly lower than the control values. Similar results were noticed by Ekoe et al., (1980). However, Odland et al., (1982) and Darley et al., (1984) observed a significant decrease of SHBG levels in acne patients than controls, Pittaway and Wnetz (1982) explained this by the elevated T level which decreases hepatic SHBG synthesis in such patients.

After spironolactone therapy it was observed that mean serum T level of the 14 patients who completed the trial significantly decreased, while SHBG and FTI were insignificantly changed after treatment. These results were in agreement with Givens (1985), Evans and Burke (1986) and



Ylostalo et al., (1987).

The clinical response was observed in all patients but with different degrees according to the combination of subjective, objective and photographic data.

Patients with moderate to marked clinical response, were compared to those with mild response as regards hormonal levels before and after therapy. There was insignificant difference in the initial hormone level between the two groups, this is in agreement with the observation of Muhlemann et al., (1986).

The persistence of acne after treatment in some patients after lowering of androgen was probably related to the fact that acne vulgaris is influenced by multiple factors, including sebum production, sebaceous gland bacterial infections and possibly faulty follicular keratinization (Hay and Hodgins, 1974).

There was insignificant difference as regards initial hormone values in

patients with regular and irregular menstrual cycles, this is in agreement with Darly et al., (1984). However, the percent decrease of T was more in those with irregular cycles than the other group but the degree of clinical response to therapy was insignificantly different.

Spironolactone therapy was found to be beneficial in the correction of other associated manifestations of hyperandrogenism, such as hirsutism, a finding which was previously noted by Koksai et al., (1987). It also has an effect in correcting androgenic alopecia as previously observed by Burke and Cunliffe (1985).

It is a point of interest to mention that 5 out of 7 patients with premenstrual tension syndrome spontaneously showed alleviation of symptoms during spironolactone therapy. This was previously observed by O'Brien et al., (1979) and Ylostalo et al., (1987). Five of our patients complained of aggravation of acne after stoppage of spironolactone, so extended maintenance therapy is needed for these patients,

the same observation previously noted by Ylostalo et al., (1987).

The present study showed that the regimen used was acceptable to the patients, therapeutically effective and side effects were mild, transient and reversible.

### SUMMARY

Acne vulgaris is a very common multifactorial disorder involving the pilosebaceous follicles occurring mainly in pubertal and postpubertal period. Until now it represents a clinical problem in its treatment inspite of recent and different modalities of therapy. Twenty females with acne vulgaris were treated with 100 mg spironolactone per day. Estimation of total

serum testosterone (T) and sex hormone binding globulin (SHBG) was done by radioimmunoassay before and after 3 months of spironolactone.

Ovarian ultrasound showed polycystic ovaries in 50% of cases. 14 patients (70%) were showed mild to marked response while 6 patients only showed no response to spironolactone treatment. After spironolactone therapy it was observed that mean serum T level of 14 patients significantly decreased while SHBG and free testosterone index were insignificantly changed after treatment. It is concluded that this form of therapy for acne vulgaris, up to the dose used is safe, reliable, and accepted by the patient.

**Table (1) :** Ovarian ultrasound findings in the selected acne patients in this study.

Ultrasound findings	Patient no	%
* Polycystic ovary.	10	50 %
* Single ovarian cyst.	3	15 %
* Slightly enlarged ovaries.	2	10 %
* Normal ovarian findings.	5	25 %

No + ve findings were detected in plain x ray skull for the sella turcica that is to say no pituitary tumours were detected in both patients and control groups.

**Table (2) :** Hormone levels in patients with acne as compared to control group.

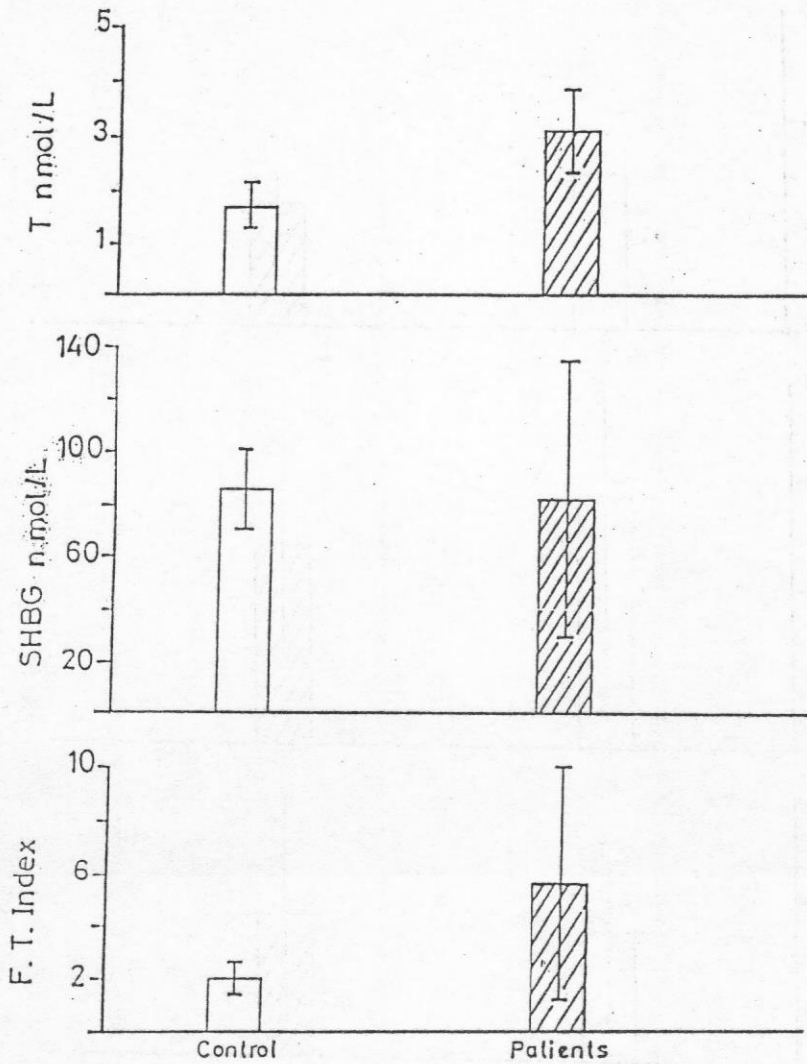
Group		Total testosterone (T) n mol / l	Sex hormone binding globulin (SHBG) n mol / l	Free testosterone index (FTI)
Control	No	10	10	10
	Mean	1.67	84.96	1.99
	S. D	0.41	15.73	0.46
All Patients	No	19	20	19
	Mean	3.07	82.77	5.66
	S. D	0.78	50.84	4.34
t		5.21*	0.13	2.57*

\* t significant,  $P \leq 0.05$

**Table (3) :** Hormonal levels in the patients before and after treatment.

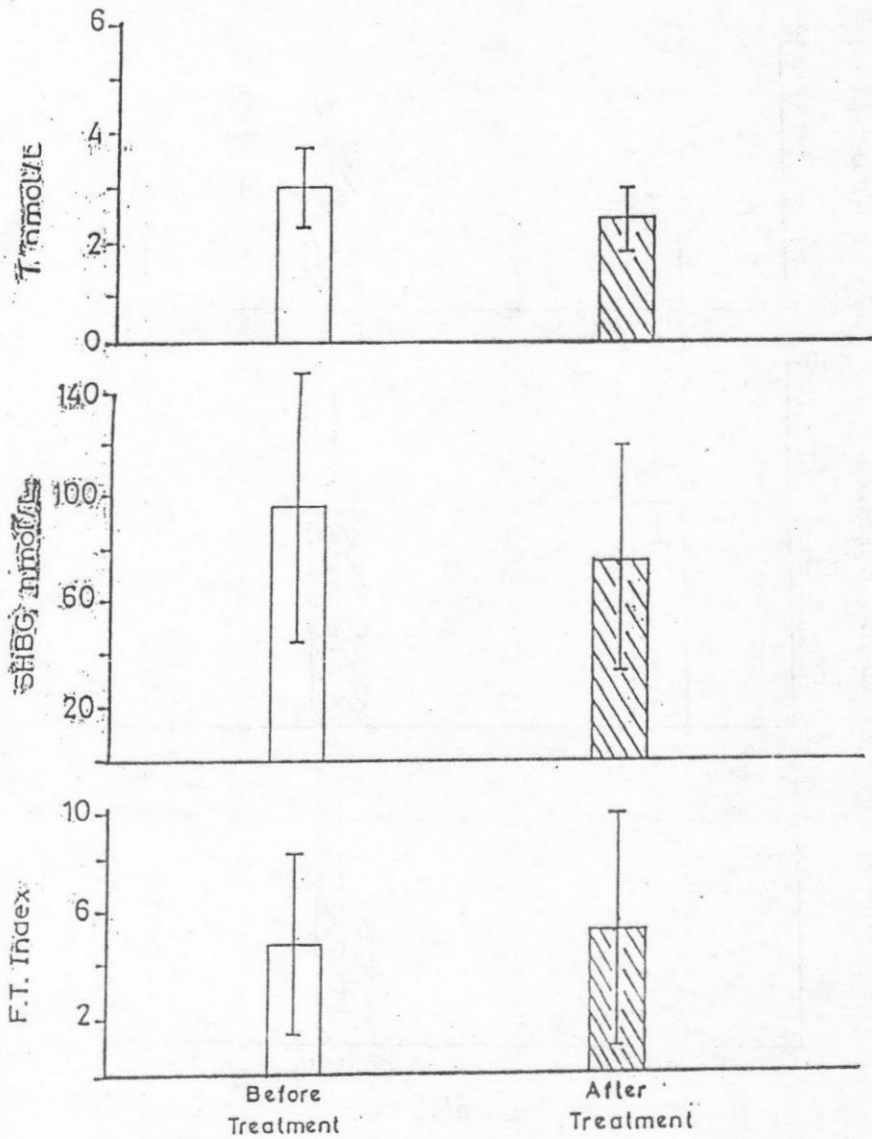
Group		Total testosterone (T) n mol / l	Sex hormone binding globulin (SHBG) n mol / l	Free testosterone index (FTI)
Control treatment	No	14	14	14
	Mean	2.94	94.87	4.67
	S. D	0.72	50.51	3.5
Control treatment	No	14	14	14
	Mean	2.29	75.24	5.09
	S. D	0.55	42.85	4.51
t		2.6	1.07	0.27





Figure(1)

Hormone levels in patients with acne as compared to control group.



Figure(2)

Hormonal levels in the patients before and after treatment.

## REFERENCES

- Boisselle, A. and Tremblay, R. R.** (1987) : Clinical usefulness of spironolactone in the treatment of acne and hirsutism. *Clinical Research*, 26 : 6.
- Braendle, W.; Boess, H.; Breckwoldt et al., (1974)** : Effects and side effects of cyproterone acetate treatment. *Arch. Fur Gyn*, 216 : 335.
- Burke, B. M. and Cunliffe, W. J.** (1985) : Oral spironolactone therapy for female patients with acne, hirsutism or androgenic alopecia. *Br. J. Dermat.*, 112 : 124.
- Burn, J.; Finney, D. J. and Goodwine P. G. (1952)** : Biological standardisation. 2nd ed., university press, Oxford, pp. 32.
- Carter, G. D.; Holland, S. M. Alagband-Zadeh, J. A. et al., (1983)** : Investigations of Hirsutism : Testosterone is not enough. *Ann. Clin. Bioch.*, 20 : 262.
- Collins, W. P., Mansfield, M. D.; Aladina, S. et al., (1972)** : Radioimmunoassay of plasma testosterone. *J. Ster. Bioch.* 3 : 333.
- Corvol, P.; Michaud, A.; Menard, J. et al., (1975)** : Antiandrogenic effect of spironolactone : Mechanism of action. *Endocrinology*, 97 : 52.
- Darley, C. R.; Moore, J. W. and Besser, G. H. (1984)** : Androgen status in women with persistent acne vulgaris. *Clin. Exp. Dermat.*, 9 : 28.
- Ekoe, J. M.; Burchardt, P. and Ruedl, B. (1980)** : Treatment of hirsutism, acne, alopecia with cyproterone acetate. *Dermatologica*, 160 : 398.
- Evans, D. J. and Burke, C. W. (1986)**

- : Spironolactone in the treatment of idiopathic hirsutism and the polycystic ovary syndrome. *J. Roy. Soc. Med.* 79: 451.
- Fayolle, J. (1975) :** La progesterone percutanee dans Le traitement de l'acne et des etats seborrheiques de la peau et du cuir chevelu. *Lyon Medica*, 233 : 1303.
- Givens, J. R. (1985) :** Treatment of hirsutism with spironolactone. *Fert. Sterl.*, 43 : 841.
- Goodfellow, A.; Alagband-Zadeh, J. Carter, G. et al., (1984) :** Oral spironolactone improve acne vulgaris and reduces sebum excretion. *Brit. J. Dermat.*, 111 : 209.
- Hammerstein, J.; meckies, J. and Leo-Rossberg, I. (1975) :** Use of cyproterone acetate in the treatment of acne, hirsutism and virilism. *J. Ster. Bioch.*, 6 : 827.
- Hay, J. B. and Hodgins, M. B. (1974):** Metabolism of androgens by human skin in acne. *Brit. J. Dermat.*, 91 : 123.
- Koksai, A.; Pobuccu, P. and Akyurek, C. (1987) :** Spironolactone in the treatment of hirsutism. *Arch. Gyna.*, 240 : 95.
- Lawrence, D. M., Katz, M. and Robinson, I. W. E. (1981) :** Reduced sex hormone binding globulin and derived free testosterone levels in women with severe acne. *Clin. Endocr.*, 15 : 87.
- Marynick, S. P., Charkmakjian, Z. H., McCaffree, D. L. et al., (1982) :** Androgen excess in cystic acne. *New. Eng. J. Med.*, 308 : 981.
- Menard, R. H.; Stripp, B. and Gillette, J. R. (1974) :** Spironolactone and testicular cytochrome P-450 : de-

creased testosterone formation in several species and changes in hepatic drug metabolism. *Endocrinology*, 94 : 1628.

**Muhlemann, M. F.; Carter, G. D., Cream, J. J. et al., (1986) :** Oral spironolactone : an effective treatment for acne vulgaris in women. *Brit. J. Dermat.*, 115 : 227.

**O'Brien, P. M. S., Craven, D., Selby, C. et al., (1979) :** Treatment of premenstrual syndrome by spironolactone. *Brit. J. obst. Gyna.*, 86 : 142.

**Odland, V.; Carlstrom, K. and Michaelsson, G. (1982) :** Plasma androgenic activity in women with acne vulgaris and in healthy girls before, during and after puberty. *Clin. Endocrinol.*, 16 : 243.

**Petrie, A. (1978) :** Lecture notes on

medical statistics. Blackwell Scientific Publication, Oxford, London, Edinburgh, pp : 72.

**Pittaway, D. E. and Wentz, A. C. (1982) :** Therapeutic alternatives for the hirsute patient. *Drug therapy*, pp : 97.

**Strauss, J. S. and Pochi, P. E. (1974) :** Endocrinologic control of the development and activity of the human sebaceous gland. *J. Invest. Dermatol.*, 26 : 191.

**Tidd, M. J.; Horth, P. E.; Ramsay, P. E. et al. (1978) :** Endocrine effects of spironolactone in man. *Clin. Endocrin.*, 9 : 389.

**Ylostalo, P.; heikkinen, J.; kaupplia, A. et al. (1987) :** Low dose spironolactone in the treatment of female hirsutism. *Int. J. Fert.*, 32 : 41.



## تقييم دواء اسبيرونولاكتون فى علاج حب الشباب فى الاناث

حب الشباب مرض شائع وقد وجد أن السبب الرئيسى فى حدوثه هو زيادة افراز الغدد الدهنية نتيجة لزيادة نسبة هرمون الذكوره عن الاناث عن طريق افراز المبيض أو الغده فوق الكلوية.

يتناول هذا البحث تقييم دواء الاسبيرونولاكتون فى علاج حب الشباب وقد تم اختيار ٢٠ حالة من الاناث وتتراوح أعمارهن بين ١٨-٣٥ سنة وقد تم فحص الحالات طبياً والفحص بالأشعة التشخيصية والموجات الصوتية والفحوص المعملية لتحديد مستوى كل من هرمون التستوستيرون، الجلوبيولين المتحد بالهرمون الذكري قبل وبعد العلاج لمدة ثلاثة شهور.

قد دلت النتائج المستخلصة كالآتى :-

- ١- نتائج الأشعة التشخيصية وجد أن ٥٠٪ من الحالات بها المبيض متعدد الحويصلات.
- ٢- نتائج الهرمونات قبل العلاج ارتفاع فى مستوى هرمون التستوستيرون عن الطبيعى وخاصة فى حالات ذوى المبيض متعدد الحويصلات.
- ٣- هبوط فى نسبة التستوستيرون الكلى بعد العلاج مع تحسن حب الشباب وزيادة الافراز الدهنى بالبشرة.