

# ENDOSTATIN AND VEGF xxx b ARE POTENTIAL DIAGNOSTIC MARKERS FOR IDIOPATHIC PULMONARY FIBROSIS

*By*

Nadia A. Hasaneen MD, Ph.D\*  
and Ibrahim M. El-Dosoky, PhD\*\*

*From*

*Departments of Thoracic Medicine\* and Pathology\*\*,  
Mansoura Faculty of Medicine, Mansoura, Egypt*

## ABSTRACT

**Background :** Vascular remodeling in idiopathic pulmonary fibrosis (IPF) is regulated by an imbalance between angiogenic and angiostatic factors. The identification of biomarkers for IPF could aid in the classification of disease subtypes, and provide a means to define therapeutic response. Endostatin is an anti-angiogenic peptide with known effects on endothelial cells. VEGF xxxb is a new family of VEGF isoform stimulates a unique pattern of VEGF-R2 receptor with anti-angiogenic activity and play important role in lung injury and repair. The present study examined weather the expression of endostatin and VEGF xxxb differed among the histologic subgroups of IPF, usual

interstitial pneumonia (UIP) which is steroid unresponsive type and non-specific interstitial pneumonia (NSIP) which is steroid responsive type.

**Methods :** The present study was conducted retrospectively using lung biopsies collected via vidoscopic thoracoscopy from 10 patients diagnosed as UIP and 10 patients diagnosed as NSIP pathologically. The control lung tissues from 6 patients were obtained from histologically normal areas of lung lobe removed for isolated benign tumors. The expression of endostatin and VEGF xxxb in lung tissues was assessed using immunohistochemistry studies.

**Results :** VEGF xxxb was localized mainly to the hyperplastic alveolar epithelial cells in the lung tissue of

UIP mainly on the cell surfaces of alveolar macrophages and epithelial cells. However lung biopsy from patients with fibrotic type of NSIP showed positive VEGF xxxb staining in the regenerative epithelial cells when compared to cellular type of NSIP which immunostained weakly for VEGFxxx b. Endostatin was up-regulated in UIP lesions compared with NSIP. Endostatin staining was strongly positive in alveolar tissue and inflammatory cells. The expression of endostatin on epithelial cells was increased significantly in UIP-like lesions compared with fibrotic NSIP lesions and in fibrotic NSIP-like lesions compared cellular NSIP and normal lung tissues.

*In Conclusions :* These results confirm that inhibition of angiogenesis with endostatin and VEGF xxxb contributed much more to UIP lesions than to NSIP. These results may indicate that these two diseases have a different pathophysiology. Endostatin and VEGFxxx b may be a useful marker to distinguish both diseases.

*Key word :* Angiogenesis, angiostatic, VEGF-xxx b, endostatin, IPF, UIP, NSIP, vascular remodeling.

## INTRODUCTION

The idiopathic interstitial pneumonias (IIPs) comprise a group of diffuse parenchymal lung diseases of unknown etiology with varying degrees of inflammation and fibrosis [1]. The American Thoracic Society/ European Respiratory Society (ATS/ERS) 2002 consensus classification statement divide IIPs into the following clinic-pathological entities: Usual interstitial (UIP), nonspecific interstitial pneumonia (NSIP), cryptogenic organizing pneumonia (COP), respiratory bronchiolitis-associated interstitial lung disease, and desquamate, acute, and lymphocytic interstitial pneumonias [2]. Usual interstitial pneumonia (UIP) and nonspecific interstitial pneumonia (NSIP) are the most clinically important and frequently occurring [2] forms of idiopathic pulmonary fibrosis (IPF). UIP and NSIP closely mimic each other clinically but NSIP has a far better outcome [3]. It is critical to differentiate between UIP and NSIP pathologically, because of differences in survival and response to corticosteroid.

UIP is a progressive and usually fatal disease with median survival

endothelial growth factor (VEGF) has been recognized as a major regulator of normal and pathological angiogenesis and as an enhancer of vascular permeability [9]. Several studies demonstrated that VEGF levels in bronchoalveolar lavage (BAL) fluids are significantly decreased in patients with IPF [10, 11], whereas the plasma levels of VEGF in IPF patients were reported to be comparable to those in healthy volunteers [12]. There is no proper explanation of this paradoxical phenomenon. The recognition of the VEGF xxxb isoform family led to another potential explanation for these observations. This family of VEGF isoforms is formed by splicing from exon 7 into the previously assumed 3'-untranslated region (exon 8b) of the VEGF mRNA. This new family of VEGF isoforms (VEGF xxxb) consists of peptides of the same length as other forms, but with a different COOH-terminal six amino acids, SLTRKD rather than CDKPRR [13]. VEGF xxxb isoform stimulates a unique pattern of VEGF-R2 receptor [14] with anti-angiogenic activity and play important role in lung injury and repair [14, 15].

Vascular remodeling in idiopathic pulmonary fibrosis (IPF) is regulated by an imbalance between angiogenic and angiostatic factors which has been demonstrated in both animal models and tissue specimens from patients with IPF [6-8]. Vascular en-

time approximately 2.9 years from the time of diagnosis [4]. UIP is histologically characterized by heterogeneous pattern of ongoing lung injury leading to formation of fibroblastic foci (small aggregates of actively proliferating fibroblasts or myofibroblasts) adjacent to established alveolar fibrosis which result in an irreversible distortion of the lung's architecture. Histological feature of UIP is hardly indicative of new capillary formation in the alveolar wall but limited proliferation of microvessels has been observed adjacent to fibroblastic foci [5]. In contrast to NSIP lesion generally show homogeneous changes of predominantly inflammatory changes reaction (cellular NSIP) or mostly fibrotic changes (fibrotic NSIP) in alveolar structures. In cellular NSIP, alveolar capillaries are often intermingled with inflammatory cells whereas NSIP in fibrotic type appear to contain few capillaries.

represent the activation of tissue fibroblasts in the lung, leading to collagen deposition, and endostatin may participate in the fibrosing process in the lung [22]. Endostatin may play a role in aberrant epithelial repair in IPF [23]. Furthermore, endostatin level was reported to be elevated in the BAL fluid and plasma of patients with IPF compared with normal controls. Elevated BAL Fluid endostatin levels correlated with a number of elevated cytokines, MMP3 and lung function in IPF.

The aim of the present study was to study the expression of anti-angiogenesis factors; endostatin and VEGF xxxb using immunohistochemistry among the 2 histologic subgroups of IPF namely usual interstitial pneumonia (UIP) which is steroid unresponsive type and nonspecific interstitial pneumonia (NSIP) which is steroid responsive type. The overall goal of the present study is to examine if both endostatin and VEGF xxxb can be used as a marker to differentiate UIP (steroid unresponsive type of IPF) from NSIP (steroid responsive type of IPF).

Endostatin is an angiogenesis inhibitor that is an endogenously produced as proteolytic fragment of type XVIII collagen. Endostatin has been implicated in the microvascular damage found in pre-eclampsia and can be used to suppress tumor angiogenesis in mice [16]. Serum levels of endostatin have been studied extensively in patients with cancers originating from the kidney, head and neck, and lung [17-19]. Higher serum endostatin level was reported in patients with both lung cancer and interstitial pneumonia compared to those without interstitial pneumonia [19]. Very recently, two study groups reported the serum levels of endostatin in patients with systemic sclerosis [20, 21]. One of these study groups demonstrated elevated serum levels of endostatin in such patients, especially those who presented with pulmonary fibrosis, and they speculated that detected the endostatin was released by tissue-activated fibroblasts [20]. Elevated serum levels of endostatin were also observed in patients with connective disease associated pulmonary fibrosis and patients with IPF. Elevated serum levels of endostatin in such patients may

## PATIENTS AND METHODS

### A) Patient population

Archival normal and IPF lung tissue sections and paraffin blocks were utilized in this study.

The present study was performed retrospectively on lung specimens from 20 patients with IPF (10 patients with UIP and 10 patients with NSIP) in the period between July 2009 and May 2010. Samples were obtained by video thoroscopic lung biopsy. The diagnosis of IPF was based on strict criteria (ie, clinical history, physical examination, roentgenographic findings, laboratory tests, pulmonary function tests, histologic findings, and the exclusion of other known causes of interstitial lung disease), according to the latest American Thoracic Society/European Respiratory Society criteria [2]. The histological diagnosis in all specimens was compatible with that of UIP in 10 patient and NSIP in 10 patients. None of the patients were under systemic steroid or immunosuppressive therapy prior to lung biopsy. The control lung tissues were obtained from histological normal areas of lung lobe removed for isolated benign tumors via thoracotomy. Pa-

tients in the control group had no other underlying lung pathology.

*B) Tissue Preparation and histological Evaluation of lung sections using light microscopy* Lung biopsies were fixed immediately in 10% neutral formalin, dehydrated, and embedded in paraffin block. Sections (4\_μm thick) was cut and stained with H&E. Two additional coated slides were cut for VEGF and endostatin staining examined using immunohistochemistry study.

*C) Immunohistochemistry (IHC) studies* : IHC staining was performed with the avidin biotin complex method using ABC kits (Vector Laboratories Inc, Burlingame CA, U.S.A). Tissue sections of lung biopsies were deparaffinized through serial baths of xylene, alcohol and water. To reactivate the antigen, sections were pretreated in 10 mM citrate buffer, pH6.0 in a microwave oven for 10 min at boiling condition. The sections were then washed three times with phosphate buffered solution (PBS) for 5 min. Then, the sections were soaked in 0.3% hydrogen peroxide for 30 min at room

temperature to remove endogenous peroxidase activity. To inhibit nonspecific binding, sections were treated with 10% horse serum for 20 min and incubated with mouse anti-human VEGFxxx b monoclonal antibody (R&D Systems, USA, cat # MAB3045) and endostatin monoclonal antibodies (Chemicon International, Temecula, CA) at 1:200 dilutions for overnight at 4°C. After being washed with PBS, the slides were subsequently incubated with biotinconjugated goat antimouse Ig G antibody for 1 hour. After the section washed with PBS, the sections were then treated with avidin-biotin peroxidase complex (Vector Laboratories, CA) for 1h and washed once more with PBS. The sections were finally incubated with DAB (3, 3'- diaminobenidine hydrochloride containing 0.1% hydrogen peroxidase) for 5-8 min. Sections were then counterstained with hematoxylin and mounted. Nonimmune mouse IgG was used as a negative control. No significant immunohistochemical reaction occurred in the control sections. In independent tis-

sue evaluation by pathologists graded semiquantatively the degree of staining that was present, as follows: grade 0, no staining present; grade 1, < 10% of the cells are positive; grade 2, > 10% but < 50% of the cells are positive; and grade 3, > 50% of cells are positive.

#### *D) Grading of Fibrosis*

The grade of fibrosis in each field was also assessed by using previously described criteria with slight modifications [4, 24] from grade 0 to 5 (0, normal lung; 1, minimal fibrous thickening of alveolar or bronchiolar walls; 2, moderate thickening of walls without obvious damage to lung architecture; 3, increased fibrosis with definite damage to lung structure and formation of fibrous bands or small fibrous masses; 4, severe distortion of structure and large fibrous areas "honeycomb lung" is placed in this category; and 5, total fibrous obliteration throughout the field). The evaluation of immunoreactivity and the grade of fibrosis in each field were determined at the same time by pathologist who is blinded to clinical



cal diagnosis.

#### E) Statistical Analysis

The percentage of IPF patients and control subjects with positive immunohistochemical signals were compared using the  $X^2$  test (Microsoft Excel 2000; Microsoft Corp; Bellevue, WA). A p value of  $< 0.05$  was considered to be significant.

## RESULTS

### 1) *The histological features of usual interstitial pneumonia (UIP) :*

The diagnostic keys for diagnosing UIP were the following: 1) a patchwork appearance resulting from alternating areas of scarred and normal lung; 2) architectural distortion; and 3) fibroblastic foci. As shown in Figure 1, at low magnification there was the abrupt alternating of scarred and normal lung (patchwork pattern: scar-normal-scar-normal) and the scarred areas showed obliterated the alveolar architecture (Figure 1A). The fibrosis was mostly seen at the periphery of the lobule in the subpleural paraseptal regions, with relative sparing of the centrilobule. This was a useful diagnostic clue, particularly in early cases (Figure 1B). Honeycomb consists of

enlarged airspaces lined by bronchiolar epithelium, frequently filled by mucus and surrounded by dense scars (Figure 1C). The architectural distortion and the abrupt transition with residual normal lung was one of the characteristic of UIP. A fibroblastic focus consisting of a dome-shaped proliferation of myofibroblasts immersed in a myxoid matrix. Fibroblastic foci were covered by bronchiolar epithelium or by hyperplastic pneumocytes (Figure 1D). Temporal heterogeneous appearance with alternating areas of normal lung structure, interstitial inflammation, and dense fibrosis was most characteristic feature of UIP as shown in Figure 3C.

### 2) *The histological features of non-specific interstitial pneumonia (NSIP) :*

Of 10 patients diagnosed with NSIP, 7 patients had cellular NSIP and 3 had fibrotic NSIP.

Histology of NSIP showed a uniform interstitial fibrosis with preservation of the alveolar architecture. At low magnification, the absence of patchwork and architectural distortion are the keys to differentiating NSIP

from usual interstitial pneumonia (Figure 2A). There was absence of honeycomb and fibroblastic foci (the fibrosis was all of the same age). Furthermore, in areas in which fibrosis was more marked; the alveolar framework was still recognizable (Figure 2B). The fibrosis sometimes is looser in NSIP, a feature rarely seen in usual interstitial pneumonia (Figure 2C). Enlarged airspaces surrounded by interstitial fibrosis and lined with bronchiolar or alveolar epithelium are quite frequent in fibrosing NSIP and differ from honeycomb in the finer character of the fibrosis, which respects the alveolar architecture (Figure 2D). In cellular pattern of NSIP, large number of mononuclear cells consistently occupied interstitial matrix of alveolar wall (Figure 3a). Fibrin rich exudates were occasionally found in air space and were often enclosed by extension of epithelial cells (organizing pneumonia). Most alveolar wall in cellular pattern of NSIP appeared quiet enlarged with edema and inflammatory cells (Figure 3A). In fibrotic pattern of NSIP, the alveolar walls were characterized by uniform collagen deposition without fibroblastic foci compared to UIP pattern

where fibroblastic foci developed adjacent to patchy fibrotic scars (Figure 3B, 3C respectively).

3) *VEGFxxx b is upregulated in hyperplastic epithelial cells of UIP.*

By immunohistochemistry, VEGFxxx b was localized mainly to the hyperplastic alveolar epithelial cells in the lung tissue of UIP mainly on the cell surfaces of alveolar macrophages and epithelial cells (Figure 4). These finding was observed in all 10 patients with UIP. On the other hand, in patients with nonspecific interstitial pneumonia of fibrotic type, VEGFxxx b staining was positive in the regenerative epithelial cells when compared to cellular type of NSIP which showed weak immune-staining of VEGFxxx b. Immunostaining for VEGFxxx b was observed in 3 out 10 in NSIP, most of VEGFxxx b staining was observed in lung biopsy from patients diagnosed with fibrotic NSIP. Control normal lung tissue (n= 6) showed no staining for VEGFxxx b (Figure 4).

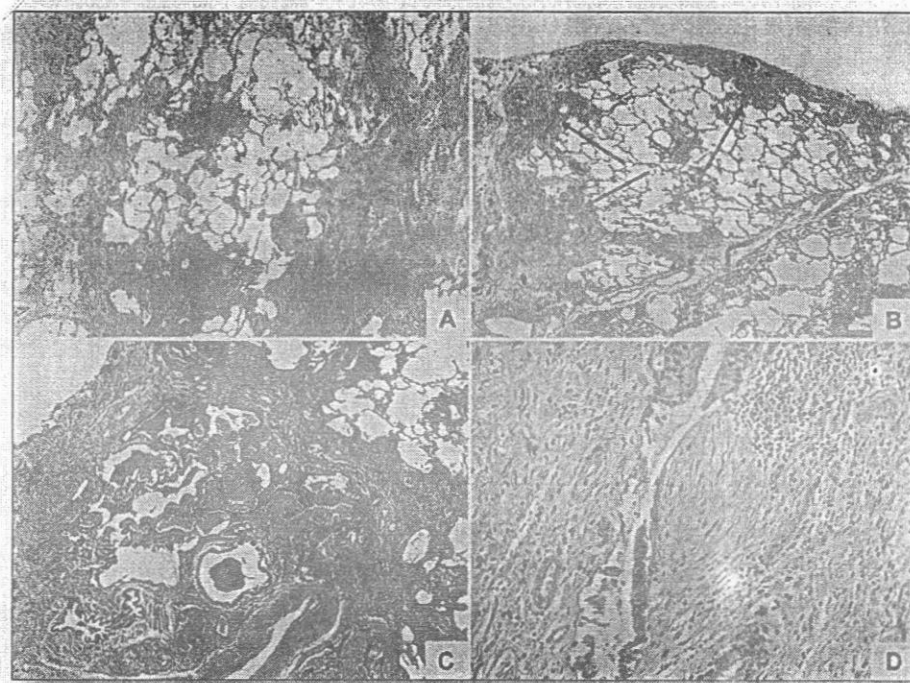
4) *Endostatin expression increased in UIP and its expression increased with grade of fibrosis.*

Positive signals for endostatin were

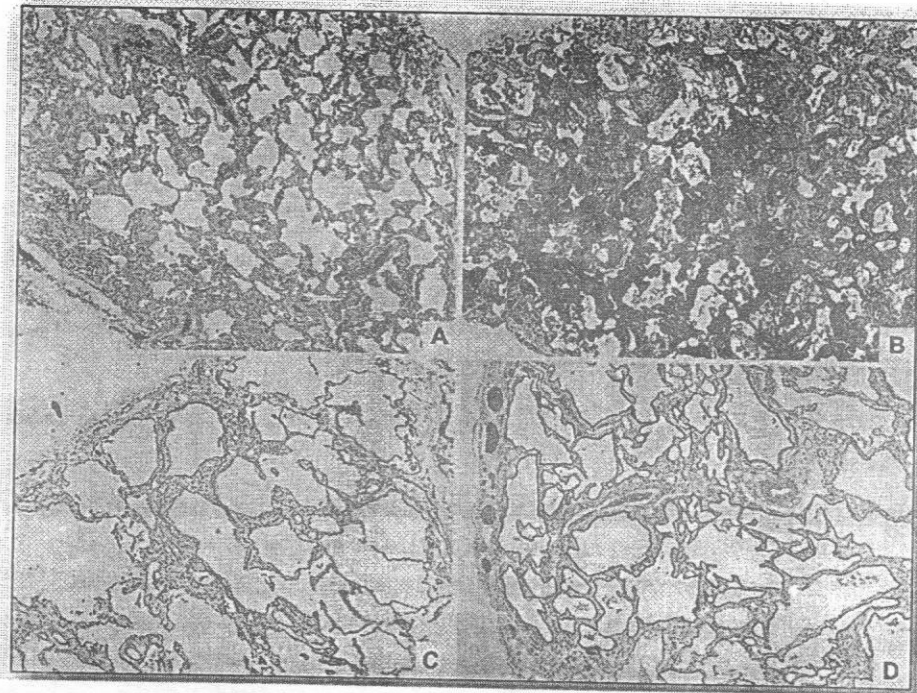


predominantly detected in the bronchiolar and alveolar epithelial cells in lung tissues from patients with UIP, especially in grade 3 lesions. In UIP, fNSIP, and cNSIP, there was a significant increase in the expression of the endostatin in grade 3 fibrosis compared with other grades ( $P < .05$ ). Endostatin expression in UIP-like lesions significantly increased compared with fNSIP-like

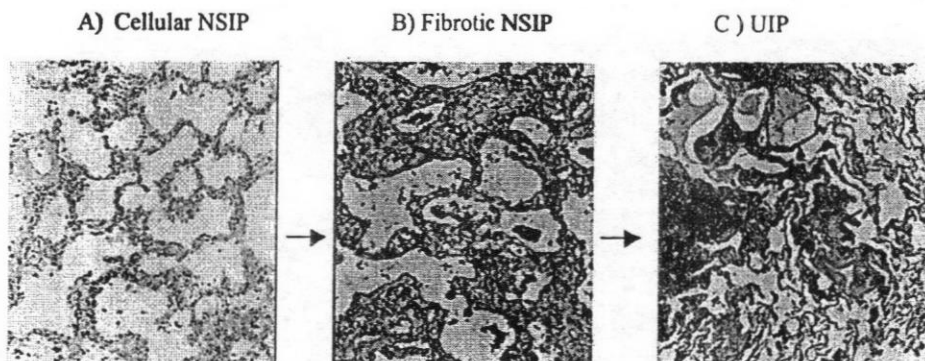
lesions ( $P < .01$ ) in grade 1,2 and 3 and also significantly increased compared with cNSIP-like lesions ( $P < .01$ ) in grade 1,2 and 3. There was a significant increase in the expression of endostatin in fNSIP-like lesions compared with cNSIP-like lesions ( $P < .05$ ) in grade 2 and grade 3 lesions (Figure 5A and B). IHC for endostatin was negative in all control subjects.



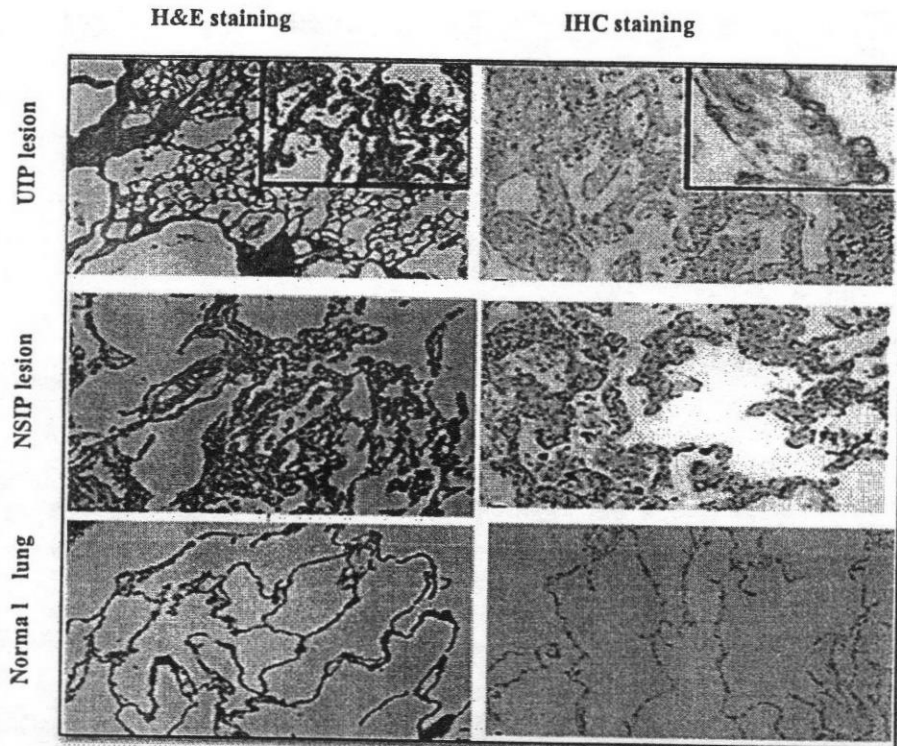
**Figure 1: Histology of usual interstitial pneumonia (UIP):** A) At low magnification there is abrupt alternation of scarred and normal lung (patchwork pattern: scar-normal-scar-normal). In the scarred areas the alveolar architecture is obliterated (H&E x 20). B) The fibrosis frequently prevails at the periphery of the lobule in the subpleural paraseptal regions (arrows), with relative sparing of the centrilobule (H&E x 20). C) Honeycomb consists of enlarged airspaces lined by bronchiolar epithelium, frequently filled by mucus and surrounded by dense scars. Note the architectural distortion and the abrupt transition with residual normal lung seen in the right upper corner (H&E x 20). D) A fibroblastic focus consisting of a dome-shaped proliferation of myofibroblasts like cells in a myxoid matrix. Fibroblastic foci is covered by bronchiolar epithelium (H&E x 100).



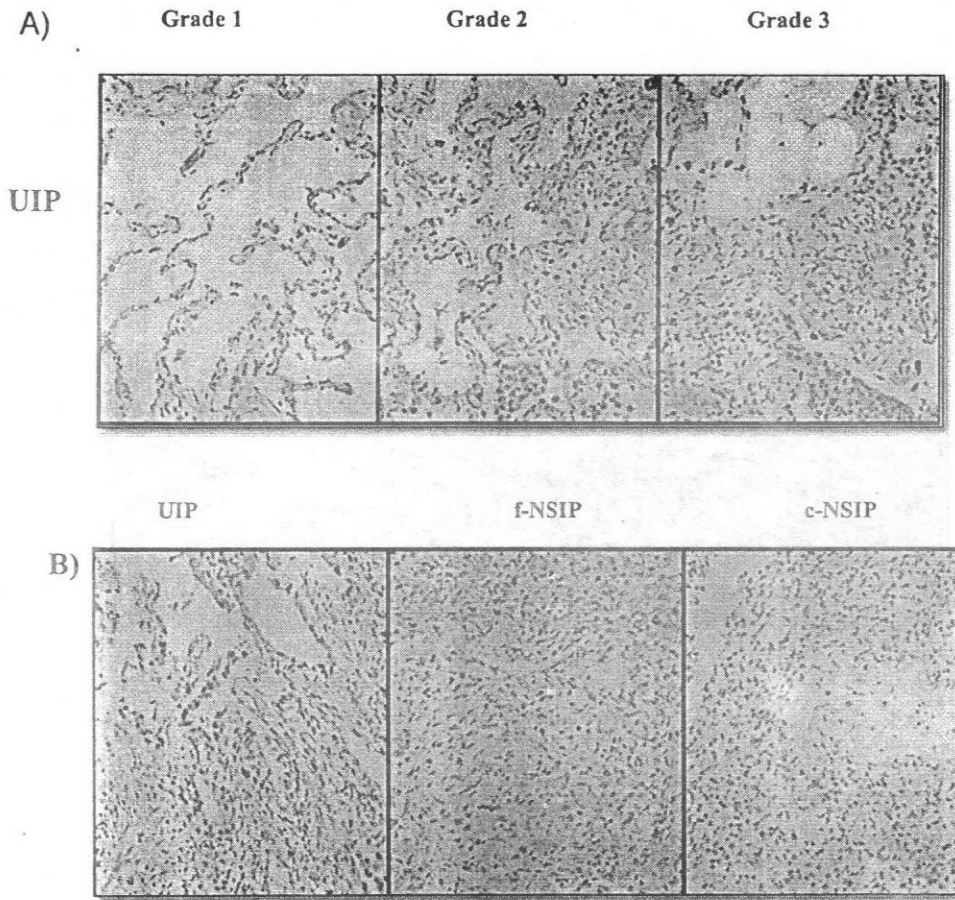
**Figure 2 :** Histology of non-specific interstitial pneumonia ((NSIP) : A)) Uniform interstitial fibrosis with preservation of the alveolar architecture, with no of honeycomb and fibroblastic foci (the fibrosis is all of the same age) (H&E x20. B)) Also in areas in which fibrosis is more marked, the alveolar framework is still recognizable ((H&Ex 20).C)) Another lung section showing loose fibrosis ((H&Ex40).D) Enlarged airspaces surrounded by interstitial fibrosis and lined with bronchiolar or alveolar epithelium with preservation of the alveolar architecture (H&Ex40).



**Figure 3:** Representative images of lung biopsy specimens: A) Cellular non specific interstitial pneumonia (cNSIP) lesions: Centrilobular accentuation of lymphocyte infiltration into the alveolar walls. B) Fibrotic non specific interstitial pneumonia (fNSIP): Loose fibrosis with moderate infiltration of lymphoid cells in the subpleural and centrilobular areas C) Usual interstitial pneumonia (UIP). Temporal heterogeneous appearance with alternating areas of normal lung structure, interstitial inflammation, and dense fibrosis (H&E \*40).



**Figure 4 :** Histology and immunohistochemistry for VEGFxxx: Top panel showed H&E staining and IHC staining of lung tissue from UIP patients showing septal inflammation and fibrosis. Note VEGFxxx immunostaining was intensely positive in the hyperplastic alveolar epithelial cells and alveolar macrophages. Middle panel showed H&E and IHC staining of lung section from NSIP. Note that VEGFxxx is positive in the regenerative epithelial cells of NSIP lesion. Lower panel, H&E and IHC for VEGFxxx in the control normal lung tissue. No positive immunostaining is observed in the sample.



**Figure 5 :** Endostatin expression increased in UIP lesion and its expression was increased with increasing the grade of fibrosis. A) representative image of immunohistochemical analysis of endostatin in UIP lesion with various grades of fibrosis: As shown, there was a significant increase in the expression of the endostatin in grade 3 fibrosis compared with other grade 1 and 2 fibrosis. B) Representative images of immunohistochemical analysis for endostatin in grade 3 lesions from UIP and NSIP lesions: As shown there was strong immunostaining for endostatin in UIP compared to fNSIP and cNSIP of the same grade of fibrosis (x 20).



## DISCUSSION

Angiogenesis, new vessel formation has been shown to play a role in the evolution of tissue repair and fibroplasia associated with acute lung injury and sarcoidosis [25, 26]. The contribution of angiogenesis to the pathogenesis of fibrosis in IPF has until recently been largely ignored. The existence of morphological neovascularization in IPF was originally identified by Turner-Warwick [27], who performed postmortem studies on the lungs of patients with widespread IPF and demonstrated neovascularization/vascular remodeling that was often associated with anastomoses between the systemic and pulmonary microvasculatures. Further evidence of neovascularization during the pathogenesis of pulmonary fibrosis has been seen in a rat model of pulmonary fibrosis [28]. Peao and associates perfused the vascular tree of rat lungs with methacrylate resin at a time of maximal pulmonary fibrosis [28]. Using scanning electron microscopy, these investigators demonstrated major vascular modifications that included neovascularization of an elaborate network of microvasculature located in the peribronchial re-

gions of the lungs and distortion of the architecture of the alveolar capillaries. The location of neovascularization was closely associated with regions of pulmonary fibrosis, similar to the findings for human lung [27], and this neovascularization appeared to lead to the formation of systemic-pulmonary anastomoses [28].

The development of new blood vessels (angiogenesis) is controlled by a discrete set of peptides, collectively referred to as angiogenesis factors and an imbalance in the levels of angiogenic factors, as compared with angiostatic factors that favors net angiogenesis has been demonstrated in both animal models and tissue specimens from patients with IPF [7, 8, 29]. These studies demonstrated that IL-8 and IP-10 are important factors that regulate angiogenic activity in IPF and that an imbalance exists in their expression, which favors net angiogenesis in this disease [6]. IL-8 level were greater from tissue specimens of IPF patients compared with those in control tissue [6]. In contrast, IP-10 levels were higher from tissue specimens obtained from control subjects compared with those from IPF pa-

tients [6]. These findings support the idea that IL-8 and IP-10 are important factors that regulate angiogenic activity in IPF [6].

The present study examined the angiostatic markers as endostatin and VEGFxxx b in lung biopsies from patients with IPF. In this study we compared the expression of endostatin and VEGFxxx b in most common type of IPF namely usual interstitial pneumonitis UIP which is steroid unresponsive and non specific interstitial pneumonitis (NSIP) which is steroid responsive type.

Our study demonstrated that the expression of both VEGF xxx b and endostatin, anti-angiogenesis markers were significantly increased in the bronchiolar and alveolar epithelial cells in UIP-like lesions compared with NSIP-like lesions in lung biopsy specimens by immunohistochemical studies. Furthermore the present study demonstrated the association between the severity of fibrosis and degree expression of anti-angiogenesis signals. Endostatin and VEGFxxx b expression were significantly increased in lesions with grade

3 of fibrosis when compared with grade 2 and 1 fibrosis.

VEGFxxx b isoform is new family of VEGF isoform formed by splicing from exon 7 into the previously assumed 3'-untranslated region (exon 8b) of the VEGF mRNA. VEGF xxx b isoform stimulates a unique pattern of VEGF-R2 receptor [14] with anti-angiogenic activity and play important role in lung injury and repair [14, 15]. VEGFxxx b is endogenously expressed in a variety of tissues. Its expression is down-regulated in the tumours and neovascularization-associated with diabetic retinopathy [30]. VEGFxxx b is also involved in physiological angiogenesis and it seems that they act as a brake on excess angiogenesis during conditions of controlled angiogenesis, such as mammary development during pregnancy [31] and lactation, and fertility control. VEGFxxx b expression is up-regulated in epithelial cells by growth factors such as IGF-1 (insulin-like growth factor 1) and TGF- $\beta$  (transforming growth factor  $\beta$ ). The mechanism through which TGF- $\beta$  upregulates VEGFxxx b appears to be through activation of p38MAPK [32,

33]. Upregulation of VEGFxxx by TGF- $\beta$  support our finding of increased VEGFxxx in hyperplastic foci where the expression of TGF- $\beta$  is prominent and though to play a role in the pathogenesis of hyperplastic foci in UIP.

Endostatin is an angiogenesis inhibitor that is an endogenously produced as proteolytic fragment of type XVIII collagen. Higher serum endostatin level was reported in patients with both lung cancer and interstitial pneumonia compared to those without interstitial pneumonia [19]. Very recently, two study groups reported elevated serum levels of endostatin in patients with systemic sclerosis [20] especially in those who presented with pulmonary fibrosis [20] and in patients with connective disease associated pulmonary fibrosis. Furthermore, endostatin level was reported to be elevated in the BAL fluid of patients with IPF compared with normal controls [23]. Endostatin has been shown to reduce migration, spreading and induce apoptosis on endothelial cells [34, 35]. Physiological doses of endostatin significantly reduced both alveolar epithelial types II cells wound

repair with inhibitory effects on cellular viability and increased apoptosis in epithelial cells. These actions on epithelial were partially mediated by FasL and caspase pathways [23]. Endostatin can interact with both integrins and VEGFR-2 which are known to be present on epithelial cells [36]. This is agreement with this study showing that both endostatin and VEGFxxx were more prominent at area of fibroblastic foci and epithelial cells.

In conclusion this study confirms that inhibition of angiogenesis with endostatin and VEGFxxx contribute much more to UIP lesions than to NSIP. Endostatin and VEGFxxx overexpression in UIP is a possible mechanism to injury to counteract angiogenesis and correlate to heterogeneous pattern of area of new vessels formation and angiogenesis in patients with UIP. This study also demonstrated the association of VEGFxxx and endostatin with fibrotic zones of UIP lesions and fibrotic NSIP rather than cellular NSIP. These results may indicate that these two diseases have different pathophysiology. Endostatin and VEGFxxx may be a useful

marker to distinguish these two diseases.

### **Acknowledgment**

The authors would like to acknowledge Dr. Sergey L. Lyubsky MD, department of anatomic and clinical pathology, Veteran Affairs Medical Center (VAMC) at Northport, New York, USA for providing us with tissue sections from patients with IPF and control groups.

### **REFERENCES**

1. Kim DS, Collard HR, King TE, Jr.: (2006) : Classification and natural history of the idiopathic interstitial pneumonias. *Proc Am Thorac Soc*, 3(4):285-292.
2. American Thoracic Society/ European Respiratory Society International Multidisciplinary Consensus Classification of the Idiopathic Interstitial Pneumonias. This joint statement of the American Thoracic Society (ATS), and the European Respiratory Society (ERS) was adopted by the ATS board of directors, June 2001 and by the ERS Executive Committee, June 2001. *Am J Respir Crit Care Med* 2002, 165(2):277-304.
3. Nagai S, Kitaichi M, Itoh H, Nishimura K, Izumi T, Colby TV (1998) : Idiopathic nonspecific interstitial pneumonia/fibrosis: comparison with idiopathic pulmonary fibrosis and BOOP. *Eur Respir J*, 12(5):1010-1019.
4. Ashcroft T, Simpson JM, Timbrell V (1988) : Simple method of estimating severity of pulmonary fibrosis on a numerical scale. *J Clin Pathol*, 41(4):467-470.
5. Ebina M, Shimizukawa M, Shibata N, Kimura Y, Suzuki T, Endo M, Sasano H, Kondo T, Nukiwa T (2004) : Heterogeneous increase in CD34-positive alveolar capillaries in idiopathic pulmonary fibrosis. *Am J Respir Crit Care Med*, 169(11):1203-1208.

6. Keane MP, Arenberg DA, Lynch JP, 3rd, Whyte RI, Iannettoni MD, Burdick MD, Wilke CA, Morris SB, Glass MC, DiGiovine B et al (1997) : The CXC chemokines, IL-8 and IP-10, regulate angiogenic activity in idiopathic pulmonary fibrosis. *J Immunol*, 159 (3):1437-1443.
7. Keane MP, Belperio JA, Arenberg DA, Burdick MD, Xu ZJ, Xue YY, Strieter RM (1999) : IFN-gamma-inducible protein-10 attenuates bleomycin-induced pulmonary fibrosis via inhibition of angiogenesis. *J Immunol*, 163 (10) : 5686-5692.
8. Nakayama S, Mukae H, Ishii H, Kakugawa T, Sugiyama K, Sakamoto N, Fujii T, Kadota J, Kohno S (2005) : Comparison of BALF concentrations of ENA-78 and IP10 in patients with idiopathic pulmonary fibrosis and nonspecific interstitial pneumonia. *Respir Med*, 99(9):1145-1151.
9. Yancopoulos GD, Davis S, Gale NW, Rudge JS, Wiegand SJ, Holash J (2000) : Vascular-specific growth factors and blood vessel formation. *Nature*, 407 (6801) : 242-248.
10. Koyama S, Sato E, Haniuda M, Numanami H, Nagai S, Izumi T (2002) : Decreased level of vascular endothelial growth factor in bronchoalveolar lavage fluid of normal smokers and patients with pulmonary fibrosis. *Am J Respir Crit Care Med*, 166(3):382-385.
11. Cosgrove GP, Brown KK, Schiemann WP, Serls AE, Parr JE, Geraci MW, Schwarz MI, Cool CD, Worthen GS (2004) : Pigment epithelium-derived factor in idiopathic pulmonary fibrosis: a role in aberrant angiogenesis. *Am J*

- Respir Crit Care Med, 170 (3):242-251.
12. Meyer KC, Cardoni A, Xiang ZZ : (2000) : Vascular endothelial growth factor in bronchoalveolar lavage from normal subjects and patients with diffuse parenchymal lung disease. J Lab Clin Med, 135(4):332-338.
  13. Bates DO, Cui TG, Doughty JM, Winkler M, Sugiono M, Shields JD, Peat D, Gillatt D, Harper SJ (2002) : VEGF165b, an inhibitory splice variant of vascular endothelial growth factor, is down-regulated in renal cell carcinoma. Cancer Res, 62 (14):4123-4131.
  14. Harper SJ, Bates DO (2008) : VEGF-A splicing: the key to anti-angiogenic therapeutics? Nat Rev Cancer, 8 (11):880-887.
  15. Guidi L, Costanzo M, Ciarniello M, De Vitis I, Pioli C, Gatta L, Pace L, Tricerri A, Bar-  
toloni C, Coppola L et al (2005) : Increased levels of NF-kappaB inhibitors (IkappaBalpha and IkappaBgamma) in the intestinal mucosa of Crohn's disease patients during infliximab treatment. Int J Immunopathol Pharmacol, 18(1):155-164.
  16. O'Reilly MS, Boehm T, Shing Y, Fukai N, Vasios G, Lane WS, Flynn E, Birkhead JR, Olsen BR, Folkman J (1997) : Endostatin: an endogenous inhibitor of angiogenesis and tumor growth. Cell, 88(2):277-285.
  17. Feldman AL, Tamarkin L, Paciotti GF, Simpson BW, Linehan WM, Yang JC, Fogler WE, Turner EM, Alexander HR, Jr., Libutti SK (2000) : Serum endostatin levels are elevated and correlate with serum vascular endothelial growth factor levels in patients with stage IV clear cell renal cancer. Clin Cancer Res, 6 (12):4628-4634.



18. Homer JJ, Greenman J, Stafford ND (2002) : Circulating angiogenic cytokines as tumour markers and prognostic factors in head and neck squamous cell carcinoma. Clin Otolaryngol Allied Sci, 27(1):32-37.
19. Suzuki M, Iizasa T, Ko E, Baba M, Saitoh Y, Shibuya K, Sekine Y, Yoshida S, Hiroshima K, Fujisawa T (2002) : Serum endostatin correlates with progression and prognosis of non-small cell lung cancer. Lung Cancer, 35(1):29-34.
20. Hebbbar M, Peyrat JP, Hornez L, Hatron PY, Hachulla E, Devulder B (2000) : Increased concentrations of the circulating angiogenesis inhibitor endostatin in patients with systemic sclerosis. Arthritis Rheum, 43 (4):889-893.
21. Distler O, Neidhart M, Gay RE, Gay S (2002) : The molecular control of angiogenesis. Int Rev Immunol, 21(1):33-49.
22. Sumi M, Satoh H, Kagohashi K, Ishikawa H, Sekizawa K (2005) : Increased serum levels of endostatin in patients with idiopathic pulmonary fibrosis. J Clin Lab Anal, 19(4):146-149.
23. Richter AG, McKeown S, Rathinam S, Harper L, Rajesh P, McAuley DF, Heljasvaara R, Thickett DR (2009) : Soluble endostatin is a novel inhibitor of epithelial repair in idiopathic pulmonary fibrosis. Thorax, 64(2):156-161.
24. Jinta T, Miyazaki Y, Kishi M, Akashi T, Takemura T, Inase N, Yoshizawa Y (2010) : The pathogenesis of chronic hypersensitivity pneumonitis in common with idiopathic pulmonary fibrosis : expression of apoptotic markers. Am J Clin Pathol, 134(4):613-620.

25. Henke C, Fiegel V, Peterson M, Wick M, Knighton D, McCarthy J, Bitterman P (1991) : Identification and partial characterization of angiogenesis, bioactivity in the lower respiratory tract after acute lung injury. *J Clin Invest*, 88(4):1386-1395.
26. Marinelli WA, Henke CA, Harmon KR, Hertz MI, Bitterman PB(1990) : Mechanisms of alveolar fibrosis after acute lung injury. *Clin Chest Med*, 11(4):657-672.
27. Turner-Warwick M (1963) : Precapillary Systemic-Pulmonary Anastomoses. *Thorax*, 18:225-237.
28. Peao MN, Aguas AP, de Sa CM, Grande NR (1994) : Neoformation of blood vessels in association with rat lung fibrosis induced by bleomycin. *Anat Rec*, 238(1):57-67.
29. Keane MP, Belperio JA, Burdick MD, Lynch JP, Fishbein MC, Strieter RM (2001) : ENA-78 is an important angiogenic factor in idiopathic pulmonary fibrosis. *Am J Respir Crit Care Med*, 164(12):2239-2242.
30. Perrin RM, Konopatskaya O, Qiu Y, Harper S, Bates DO, Churchill AJ (2005) : Diabetic retinopathy is associated with a switch in splicing from anti- to pro-angiogenic isoforms of vascular endothelial growth factor. *Diabetologia*, 48(11):2422-2427.
31. Bills VL, Varet J, Millar A, Harper SJ, Soothill PW, Bates DO (2009) : Failure to up-regulate VEGF165b in maternal plasma is a first trimester predictive marker for pre-eclampsia. *Clin Sci (Lond)*, 116(3):265-272.
32. Nowak DG, Amin EM, Rennel ES, Hoareau-Aveilla C, Gammons M, Damodoran G, Hagiwara M, Harper SJ,

- Woolard J, Ladomery MR et al (2010)** : Regulation of vascular endothelial growth factor (VEGF) splicing from pro-angiogenic to anti-angiogenic isoforms: a novel therapeutic strategy for angiogenesis. *J Biol Chem*, 285(8):5532-5540.
33. **Nowak DG, Woolard J, Amin EM, Konopatskaya O, Saleem MA, Churchill AJ, Ladomery MR, Harper SJ, Bates DO (2008)** : Expression of pro- and anti-angiogenic isoforms of VEGF is differentially regulated by splicing and growth factors. *J Cell Sci*, 121(Pt 20):3487-3495.
34. **Dixelius J, Larsson H, Sasaki T, Holmqvist K, Lu L, Engstrom A, Timpl R, Welsh M, Claesson-Welsh L (2000)** : Endostatin-induced tyrosine kinase signaling through the Shb adaptor protein regulates endothelial cell apoptosis. *Blood*, 95(11):3403-3411.
35. **Eriksson K, Magnusson P, Dixelius J, Claesson-Welsh L, Cross MJ (2003)** : Angiostatin and endostatin inhibit endothelial cell migration in response to FGF and VEGF without interfering with specific intracellular signal transduction pathways. *FEBS Lett*, 536(1-3):19-24.
36. **Wickstrom SA, Alitalo K, Keski-Oja J (2002)** : Endostatin associates with integrin  $\alpha 5\beta 1$  and caveolin-1, and activates Src via a tyrosyl phosphatase-dependent pathway in human endothelial cells. *Cancer Res*, 62 (19):5580-5589.

