

EFFECTS OF MELATONIN VERSUS OMEPRAZOLE ON REFLUX ESOPHAGITIS IN RATS

By

Amr M. Abbas*, Ahmed A. El Gendy*,
Hanaa G. El Serougy* and Ali Abd El-Wahab Ali**

From

Departments of Medical Physiology and Pathology**,
Faculty of Medicine, Mansoura University, Egypt*

ABSTRACT

Background and aim: We study the effects of melatonin and omeprazole on rats with experimentally induced reflux esophagitis.

Materials and methods: Sixty rats were divided into 12 sham operated rats and 48 rats with induced reflux esophagitis (RE), which were divided into either RE alone or pretreated by melatonin (MT), omeprazole or both, with or without inhibition of prostaglandin (PG) generation by indomethacin. Reflux esophagitis was induced in rats by ligating the pylorus and the junction between the forestomach and corpus. In all rats, gastric acid output, pH, nitric oxide (NO), melatonin, esophageal PGE₂, malondialdehyde (MDA) and reduced glutathione

(GSH) were measured. The esophageal injury was assessed by macroscopic damage score, lesion length and microscopic regenerative epithelial changes and leucocytic infiltration scores.

Results: Induction of RE increased gastric acid output, plasma NO, mucosal PGE₂, MDA, decreased pH, plasma MT, GSH and caused esophageal mucosal injury. Indomethacin administration to RE rats caused further increase in esophageal injury, acid output and decrease in pH and PGE₂. Pretreatment with omeprazole significantly increased pH, decreased acid output, and esophageal injury in comparison to MT pretreatment. In addition, MT pretreatment induced significant increase

in mucosal PGE_2 , plasma MT and NO as compared with omeprazole. No statistical significant change was found between action of MT or omeprazole on MDA, and GSH. The protective effects of MT but not omeprazole were attenuated by indomethacin. Combined MT and omeprazole decreased acid output, MDA, esophageal injury and increased pH, and GSH relative to the RE rats non-treated or those treated with omeprazole or MT. Moreover, combined MT and omeprazole significantly increased NO, mucosal PGE_2 , and plasma MT relative to the RE rats non-treated or those treated with omeprazole but not MT.

Conclusion : Omeprazole and MT have protective effects in rats with experimentally induced RE not only because of their inhibitory effect on gastric acid secretion but also due to their anti-oxidant action. Moreover, omeprazole is more effective than MT and combined treatment with MT and omeprazole is more effective than each of them alone.

Key words : Reflux esophagitis, melatonin, omeprazole, prostaglandin, esophageal mucosa, esophageal lesions.

INTRODUCTION

Reflux esophagitis is a common disease entity whereby gastric juice gains access to the esophagus due to transient lower esophageal sphincter (LES) relaxation, a low esophageal clearance speed, a lack of mucosal resistance, and is often associated with low LES pressure (1). The presence of refluxed materials induces different grades of oesophageal damage ranging from low to high grade oesophagitis (2). It is generally believed that reflux of gastric contents causes inflammation, erosions, ulceration, and destruction of the normal squamous epithelium of the oesophagus (3). If left untreated the erosion and ulceration of esophageal mucosa caused by gastric acid can induce several disease conditions, such as, chronic esophagitis, aspiration pneumonia, esophageal strictures, and Barrett's esophagus, the latter of which is a premalignant condition (4). However, the severity of reflux esophagitis cannot be accurately predicted based on acid exposure, which suggests that other damaging factors or possibly impaired mucosal resistance are also involved (5). Recent studies implicated oxygen derived free radicals in RE induced esophageal mucosal damage resulting in mucosal in-

flammation. Thus, control over free radical generation and modulation of inflammatory responses might offer better therapeutic effects to counteract the severity of RE (6).

Melatonin (N-acetyl -5- methoxy-tryptamine), an indole formed enzymatically from L-tryptophane, is the most versatile and ubiquitous hormonal molecule, produced not only in animals but also in some plants (7). Melatonin (MT) is generally believed to be secreted by the pineal gland in response to environmental light /dark cycles via suprachiasmatic nucleus, the master circadian oscillator in the brain, which regulates the circadian rhythms of several biological functions, especially circadian secretion of melatonin. (8). Melatonin has several important physiological functions in mammals including seasonal reproductive regulation, immune enhancement and regulation of light- dark signal transduction along with the capacity to influence possibly some aspects of aging. Additionally, it has been shown to have widespread antioxidant effects in variety of organ systems (9).

Melatonin is widely distributed in the human body. Besides pinealocy-

tes, the enteroendocrine cells (EE), especially in the GIT are considered to be a rich extrapineal source of melatonin. Some studies indicate that GIT is probably the most abundant extra pineal source of melatonin with mucosal concentrations recorded after protein meal exceeding by 100-400 times the blood plasma level (10). Although pineal melatonin acts prevalently in an endocrine capacity, extrapineal melatonin may act as an autocrine or a paracrine hormone (11), affecting the function of the gut epithelium, lymphatic tissues of the immune system and the smooth muscles of the gastrointestinal tract (8). Endogenous and exogenous melatonin is involved in the pre- and postprandial changes of intestinal motility (8). MT acts on target cells either directly or via G-protein coupled membrane MT receptors (MTR), mainly MTR1, MTR2 or MTR3 that modulate several intracellular messengers such as cAMP, cGMP and Ca^{+2} (12). Previous studies demonstrate that MT may be one of the most efficient protective factors preventing the development of acute gastric damage induced by topical strong irritants (as reactive oxygen species, ethanol, water - immersion restraint stress, ischemia and aspirin) and accelerating

healing of acute gastric ulcers (13).

The maintenance of integrity of epithelial barrier of the GIT against aggressive factors involve both neural and paracrine systems (14). Cyclooxygenase (COX)-PG and nitric oxide synthase (NOS)-NO systems are parts of this paracrine protection (15). However, the involvement of COX-PG and NOS-NO systems in the mechanism of esophageal integrity are still not completely understood. Particularly, little is known about the involvement of melatonin (MT), that is a potent antioxidant substance, with confirmed protective activity in the gastro-duodno-pancreatic region (16), in the acute esophageal mucosal injury and local esophageal microcirculation as well as in the paracrine protection including activation of COX-PG and NOS-NO systems.

Proton pump inhibitors such as omeprazole are extensively used for therapeutic control of acid-related disorders including gastroesophageal reflux disease and Zollinger-Ellison syndrome and for peptic-ulcer disease caused by stress (stress-related erosive syndrome), nonsteroidal antiinflammatory drugs, and Helicobacter pylori infection (17). Inhibition

of gastric acid secretion by these compounds is considered to be an important step to control the disorders (18).

The aim of this work was to study the effects of melatonin and omeprazole on the esophageal lesions in a rat model with experimentally-induced reflux esophagitis.

MATERIALS AND METHODS

Animals

Sixty Sprague-Dawley rats were purchased from Vaccine and Immunization Authority (Helwan, Cairo, Egypt) and housed (Animal House, Medical Physiology department, Faculty of Medicine, Mansoura University, Egypt) in standard cages in groups of four to six animals per cage under controlled conditions (temperature $25 \pm 1^\circ\text{C}$, and a 12:12 light/dark cycle), with free access to food and water for 1 week for acclimatization. The animals (250-270 g) were fasted for 24 h before the experiment. Drinking water was freely available to the animals up to 2 hr before the experiments. All experimental procedures were approved by Medical Research Ethical Committee of Mansoura University, Egypt.

Esophagitis induction

Under ether inhalation anesthesia, the abdomen was incised along the midline and then both the pylorus and the junction between the forestomach and corpus were simultaneously ligated according to the method described by Nakamura et al. (19). Consequently, the total capacity of the stomach to preserve the gastric juice was greatly diminished, resulting in reflux of gastric juice into the esophagus. A longitudinal cardiomyotomy of length ~1 cm was performed across the gastroesophageal junction to enhance reflux. The animals were fasted for 36 h after the operation but were allowed free access to drinking water. Then, after the end of the 36 hours, the animals were killed with an overdose of ether, and the esophagus and stomach were removed as a single unit.

Animal groups :

Sixty rats were divided into the following groups :

Group I (12 rats) : Included sham operated rats which were used as a control group. These rats were further subdivided into:

Ia (6 rats) : sham operated rats.

Ib (6 rats) : sham operated rats pretreated with indomethacin

(Sigma, USA) (5 mg/kg intraperitoneally) (13).

Group II (12 rats): Included rats in which reflux esophagitis was induced. These rats were further subdivided into:

Ila (6 rats): rats with reflux esophagitis alone.

Ilb (6 rats): in which reflux esophagitis was induced in indomethacin treated rats. Indomethacin (5 mg/kg intraperitoneally, i.p) was given 30 minutes before the start of ligation (13).

Group III (12 rats) : in which melatonin (Sigma, USA) was given to rats before induction of reflux esophagitis. These rats were further subdivided into:

IIla (6 rats) : in which melatonin (20 mg/kg, i.p) was given to rats 30 minutes before induction of reflux esophagitis (13).

IIlb (6 rats) : in which melatonin was given before induction of reflux esophagitis in indomethacin treated rats. Rats administered melatonin (20 mg/kg i.p) followed 30 minutes later by indomethacin (5 mg/kg intraperitoneally) & finally 30 minutes later by induction of reflux esophagitis.

Group IV (12 rats) : in which omeprazole (Sigma, USA) was given to rats before induction of reflux esophagitis. These rats were further subdivided into:

IVa (6 rats) : in which omeprazole (60 mg/kg, i.p) (20) was given to rats 30 minutes before induction of reflux esophagitis.

IVb (6 rats) : in which omeprazole was given before induction of reflux esophagitis in indomethacin treated rats. Rats administered omeprazole (60 mg/kg i.p) followed 30 minutes later by indomethacin (5 mg/kg intraperitoneally) & finally 30 minutes later by induction of reflux esophagitis.

Group V (12 rats) : in which both MT and omeprazole were given to rats before induction of reflux esophagitis. These rats were further subdivided into:

Va (6 rats) : in which both MT and omeprazole were given to rats before induction of reflux esophagitis. MT was given (20 mg/kg, i.p.) followed 30 minutes by omeprazole (60 mg/kg, i.p.) & finally 30 minutes later by induction of reflux esophagitis.

Vb (6 rats) : in which both MT

and omeprazole were given before induction of reflux esophagitis in indomethacin treated rats. Rats administered MT (20 mg/kg, i.p.) followed 30 minutes by omeprazole (60 mg/kg i.p), then 30 minutes later by indomethacin (5 mg/kg intraperitoneally) & finally 30 minutes later by induction of reflux esophagitis.

Quantification of gastric acid secretion :

Thirty six hours after pylorus ligation, rats were killed with an overdose of ether, and gastric contents were collected and centrifuged at 3,000 g for 10 min at 4°C. After centrifugation, the supernatant gastric juice volumes (ml/rat), pH values (pH meter, Cyber Scan 500) and acidities (mEq/l) were measured. Acidities were determined by titration of gastric juice vs. 0.1 N NaOH to pH 7.0. Acid outputs are expressed as mEq/hr (20).

Determination of plasma melatonin (MT) and nitric oxide (NO) levels:

A venous blood sample was withdrawn from rat tail vein into EDTA containing vials & used for determination of plasma melatonin by ELISA kit (Cat. No., RE54021, IBL International GmbH, Hamburg, Germany) in accor-

dance with manufacturer instructions (21). The concentration of nitric oxide (NO) was measured through the determination of nitrite and nitrate levels with the QuantiChrom™ Nitric Oxide Assay Kit (DINO-250) (BioAssay Systems, USA), which is designed to accurately measure NO production following reduction of nitrate to nitrite using improved Griess method (22).

Biochemical Assays of esophageal mucosa :

The oesophageal mucosa was stripped of the muscle layer, and stored frozen at -70°C for the following biochemical assays. When oxygen derived free radicals are generated in excess of the capability of the scavenging system, cells can be damaged by peroxidising lipids. Malondialdehyde (MDA), an index of lipid peroxidation, was determined in esophageal mucosa according to the method of Buege and Aust, (23) measuring spectrophotometrically the formation of thiobarbituric acid reactive substances. Reduced glutathione (GSH) levels, which reflect the cellular redox status, were colorimetrically measured with BioAssay Systems' QuantiChrom™ Glutathione Assay Kit (DIGT-250) (BioAssay Systems,

USA) according to the manufacturer's instructions (24). Esophageal mucosal PGE2 concentration was determined using immunoassay kit specific for PGE2 (R & D System, Inc, Mianneapolis MN, USA) (25).

Measurement of gross esophageal lesions

In all rats, the esophagi were resected up to the upper segment close to the hypopharynx. Then, they were cut along with the longitudinal axis. The lesion length (mm) that had developed in the esophagus was measured by ruler using hand lens. For examination of macroscopic changes, the esophageal lesion score system was used from 0 to 3 and photographed. According to this macroscopic scoring, esophagus had score 0 for normal shimmering mucosa, 1 for hyperemic or edematous mucosa with focal hemorrhagic spots, 2 for multiple erosions with haematin attached, 3 for ulcerations, dark necrotic spots (13).

Histopathological assessment

The dissected animal esophagi were opened longitudinally and 3 specimens were obtained; upper [approximately 5 mm below the cricopharyngeus], middle [midpoint between

the cricopharyngeus and the esophagogastric (EG) junction] and lower [approximately 0.5 mm above the EG junction] segments of the esophagus. Paraffin embedded formalin fixed blocks were obtained and 5- μ m sections were stained with hemotoxyline & eosin. According to Schindlbeck et al (26), the microscopic assessment of esophagitis includes; epithelial hyperplasia, Lamina propria changes and leucocytic infiltration. Epithelial hyperplasia is represented by expansion of basal zone (>15% of the total epithelial thickness) and elongation of lamina propria papillae (> two-thirds of the epithelial thickness). Lamina propria changes include dilatation and congestion of capillaries, forming vascular "lakes" or hemorrhages in the superficial papillae. Leucocytic infiltration includes intraepithelial eosinophils, neutrophils, lymphocytes (normally about 10 lymphocytes/HPF). Mucosal erosion and ulceration represent the extreme end of the GERD spectrum. Evaluation of the pathological changes followed the modified scoring system of Konturek et al (13). The sum of 3 specimens (upper, mid and lower oesophageal) of the same rat was calculated. The score includes; regenerative epithelial changes score: 0-none, 1- basal hyperpla-

sia, 2 mitosis, acanthosis, 3- parakeratosis; and score for Leucocytic infiltration: 0-none, 1- mild, 2- moderate, 3- severe.

Analysis of data

The statistical analysis was performed using the SPSS statistical Package version 10.0 (SPSS, Chicago, IL, USA). To compare the data, the recorded values were expressed as means \pm standard error of means (mean \pm SEM). A p value of < 0.05 was considered statistically significant (27).

RESULTS

Effects of melatonin, omeprazole & both on biochemical, macroscopic and microscopic parameters in rats with induced reflux esophagitis (Table 1) :

During the experiments of reflux esophagitis (RE), gastric acid output, plasma nitric oxide (NO), mucosal PGE2 and MDA increased while pH, plasma MT, GSH decreased significantly relative to sham operated rats. Rats with RE have a macroscopic damage score of 2.4 ± 0.07 and lesion length 40.2 ± 0.7 mm. Moreover, in these rats, significant increase occurs in regenerative epithelial changes and leucocyte infiltration scores rela-

tive to sham operated rats.

Omeprazole administration before induction of RE significantly decreased acid output, and MDA, increased pH and GSH while no significant effect was shown on MT, mucosal PGE₂ and plasma NO relative to the RE group. Moreover, it significantly decreased the macroscopic damage score, lesion length and regenerative epithelial changes and leucocyte infiltration scores relative to the RE group.

Melatonin administration before induction of RE significantly decreased acid output, and MDA and increased pH, plasma MT, NO, mucosal PGE₂ and GSH relative to the RE group. Moreover, it significantly decreased the macroscopic damage score, lesion length and the regenerative epithelial changes and leucocyte infiltration scores relative the RE group. The effect of MT in increasing pH and decreasing acid output, macroscopic damage score, lesion length, and regenerative epithelial changes and leucocyte infiltration scores is less whereas its effect in increasing mucosal PGE₂, plasma MT and NO is more significant than omeprazole. No significance was reported between

action of MT or omeprazole on MDA, and GSH.

Combined administration of both MT and omeprazole before induction of RE significantly decreased acid output and MDA and increased pH and GSH relative to the RE rats non-treated or those treated with omeprazole or MT. Moreover, it significantly increased NO, mucosal PGE₂ and plasma MT relative to the RE rats non-treated or those treated with omeprazole but not MT. On the other hand, it significantly decreased the macroscopic damage score, lesion length and regenerative epithelial changes and leucocyte infiltration scores relative to the RE rats non-treated or those treated with omeprazole and MT.

Effects of melatonin, omeprazole & both on biochemical, macroscopic and microscopic parameters in indomethacin administered rats with induced reflux esophagitis (Table 2):

During the experiments of reflux esophagitis (RE) in indomethacin administered rats, gastric acid output, and MDA increased while pH, plasma MT, NO, GSH and mucosal PGE₂ decreased significantly relative to sham

operated rats. Indomethacin administered rats with induced RE have a macroscopic damage score of 2.9 ± 0.07 and lesion length 47.2 ± 1.5 mm. Moreover, in these rats, significant increase occurs in regenerative epithelial changes and leucocyte infiltration scores relative to sham operated rats. These parameters were increased significantly relative to those in RE rats not administered indomethacin.

Omeprazole administration before induction of RE in indomethacin administered rats significantly decreased acid output, and MDA, and increased pH and GSH while no significant effect was shown on plasma NO, MT and mucosal PGE_2 relative to the RE group. Moreover, it significantly decreased the macroscopic damage score, lesion length and the microscopic epithelial thickness and leucocyte infiltration scores relative to the RE group.

Melatonin administration before induction of RE in indomethacin administered rats significantly decreased acid output, and MDA and increased pH, plasma MT, NO and GSH relative to the RE group. It tends to increase PGE_2 but non-significantly. Moreover,

it significantly decreased the macroscopic damage score, lesion length and the microscopic epithelial thickness and leucocyte infiltration scores relative to the RE group. While the effect of MT in increasing pH and decreasing acid output, damage score, lesion length and regenerative epithelial thickness and leucocyte infiltration scores is less significant than omeprazole, its effect in increasing plasma MT and NO is more significant. No significance was reported between action of MT or omeprazole on MDA, mucosal PGE_2 and GSH. Effects of MT on acid output, pH, mucosal PGE_2 , macroscopic damage score, lesion length and regenerative epithelial thickness and leucocyte infiltration scores were attenuated by administration of indomethacin relative to those in RE rats not administered indomethacin.

Combined administration of both MT and omeprazole before induction of RE in indomethacin administered rats significantly decreased acid output, and MDA and increased pH and GSH relative to the indomethacin administered RE induced rats either non-treated or those treated with omeprazole or MT. Moreover, it had no significant effect on mucosal

PGE₂, whereas it significantly increases plasma MT and NO relative to the indomethacin administered RE induced rats either non-treated or those treated with omeprazole but not MT. On the other hand, it significantly decreased the macroscopic damage

score, lesion length and the microscopic epithelial thickness and leucocyte infiltration scores relative to the indomethacin administered RE induced rats either non-treated or those treated with omeprazole and MT.

Table (1): Effects of melatonin (MT), omeprazole & both on biochemical, macroscopic and microscopic parameters in rats with induced reflux esophagitis (RE):

	Sham operated rats	RE	Omeprazole with RE	MT with RE	Combined with RE
Biochemical parameters:					
-Acid output(μ Eq/h)	21.1 \pm 2.1	213.5 \pm 7.2 ^a	85.9 \pm 9.1 ^b	151.5 \pm 6.6 ^{bc}	50.7 \pm 5.2 ^{bcd}
-pH	7.2 \pm 0.4	1.7 \pm 0.1 ^a	5.1 \pm 0.2 ^b	3.8 \pm 0.1 ^{bc}	6.9 \pm 0.1 ^{bcd}
-Plasma NO (μ mol/L)	28.8 \pm 3.1	37.4 \pm 1.9 ^a	38.3 \pm 2.1	45.8 \pm 1.2 ^{bc}	47.5 \pm 2.4 ^{bc}
-Mucosal PGE ₂ (ng/g tissue)	134 \pm 31	241 \pm 44 ^a	245 \pm 38	325 \pm 38 ^{bc}	328.8 \pm 35 ^{bc}
-Melatonin (pg/ml)	105 \pm 14	81 \pm 12 ^a	84 \pm 10	371 \pm 59 ^{bc}	367 \pm 53 ^{bc}
-MDA (uM/g tissue)	0.2 \pm 0.01	3.5 \pm 0.1 ^a	1.2 \pm 0.2 ^b	1.0 \pm 0.1 ^b	0.5 \pm 0.1 ^{bcd}
-GSH (uM/g tissue)	180 \pm 7	30 \pm 3 ^a	140 \pm 6 ^b	144 \pm 6 ^b	160 \pm 5 ^{bcd}
Macroscopic changes:					
- Damage score	-	2.4 \pm 0.07 ^a	0.5 \pm 0.01 ^b	0.8 \pm 0.02 ^{bc}	0.2 \pm 0.01 ^{bcd}
-Lesion length (mm)	-	40.2 \pm 1.7 ^a	19.1 \pm 1.1 ^b	27.6 \pm 1.5 ^{bc}	12.9 \pm 1.7 ^{bcd}
Histological changes:					
-Regenerative epithelial changes:	0.0 \pm 0.0	2.6 \pm 0.09 ^a	1.2 \pm 0.07 ^b	1.8 \pm 0.04 ^{bc}	0.6 \pm 0.01 ^{bcd}
-Leucocyte infiltration:	0.2 \pm 0.01	2.6 \pm 0.08 ^a	1.1 \pm 0.01 ^b	1.7 \pm 0.01 ^{bc}	0.5 \pm 0.01 ^{bcd}

Values are expressed as means \pm SEM (standard error of means).

NO: nitric oxide

PGE₂: prostaglandin E₂

MDA: malondialdehyde

GSH: reduced glutathione

a: significant relative to sham operated group. b: significant relative to RE group. c: significant relative to omeprazole administered group. d: significant relative to melatonin administered group.

Table (2): Effects of melatonin (MT), omeprazole & both on biochemical, macroscopic and microscopic parameters in induced reflux esophagitis (RE) of indomethacin administered rats:

	Sham operated rats pretreated with indomethacin	RE rats pretreated with indomethacin	Omeprazol in RE rats pretreated with indomethacin	MT in RE rats pretreated with indomethacin	Combined in RE rats pretreated with indomethacin
Biochemical parameters:					
-Acid output(μ Eq/L)	25.1 \pm 2.2	242.5 \pm 10.8 ^{a†}	96.1 \pm 11.3 ^b	172.9 \pm 6.3 ^{bc†}	71.9 \pm 6.7 ^{bcd†}
-pH	7.0 \pm 0.3	1.1 \pm 0.1 [†]	4.9 \pm 0.2 ^b	3.0 \pm 0.1 ^{bc†}	6.5 \pm 0.1 ^{bcd†}
-Plasma NO (μ mol/L)	28.6 \pm 3.1	20.2 \pm 1.9 ^a	21.3 \pm 2.8	29.2 \pm 2.3 ^{bc}	31.1 \pm 2.9 ^{bc}
-Mucosal PGE ₂ (ng/g tissue)	130 \pm 29	80 \pm 17 ^{a†}	85 \pm 16 [†]	91.8 \pm 10.7 [†]	93.9 \pm 12.7 [†]
-Melatonin (pg/ml)	105 \pm 14	78 \pm 8 ^a	80 \pm 9	380 \pm 45 ^{bc}	379 \pm 41 ^{bc}
-MDA (uM/g tissue)	0.2 \pm 0.01	3.6 \pm 0.2 ^a	0.9 \pm 0.2 ^b	0.8 \pm 0.2 ^b	0.4 \pm 0.1 ^{bcd}
-GSH (uM/g tissue)	180 \pm 7	33 \pm 5 ^a	137 \pm 8 ^b	140 \pm 8 ^b	163 \pm 7 ^{bcd}
Macroscopic changes:					
- Damage score	-	2.9 \pm 0.07 ^{a†}	0.6 \pm 0.1 ^b	1.6 \pm 0.1 ^{bc†}	0.4 \pm 0.01 ^{bcd}
-Lesion length (mm)	-	47.2 \pm 1.5 ^{a†}	20.6 \pm 1.3 ^b	35.9 \pm 1.9 ^{bc†}	14.7 \pm 3.8 ^{bcd}
Histological changes:					
-Regenerative epithelial changes:	0.3 \pm 0.01	2.9 \pm 0.07 ^{a†}	1.4 \pm 0.1 ^b	2.1 \pm 0.03 ^{bc†}	0.8 \pm 0.05 ^{bcd}
-Lecocyte infiltration:	0.2 \pm 0.02	2.9 \pm 0.07 ^{a†}	1.3 \pm 0.1 ^b	2.2 \pm 0.03 ^{bc†}	0.6 \pm 0.01 ^{bcd}

Values are expressed as means \pm SEM (standard error of means).

NO: nitric oxide

PGE₂: prostaglandin E₂

MDA: malondialdehyde

GSH: reduced glutathione

a: significant relative to sham operated group. b: significant relative to RE group. c: significant relative to omeprazole administered group. d: significant relative to melatonin administered group. †: significant relative to corresponding group not administered indomethacin.

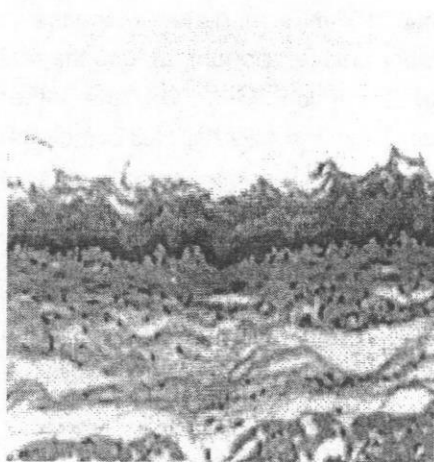


Fig (1) : Normal esophageal epithelium. Keratinization is a normal finding in rat esophagus (H&E stain, x100).

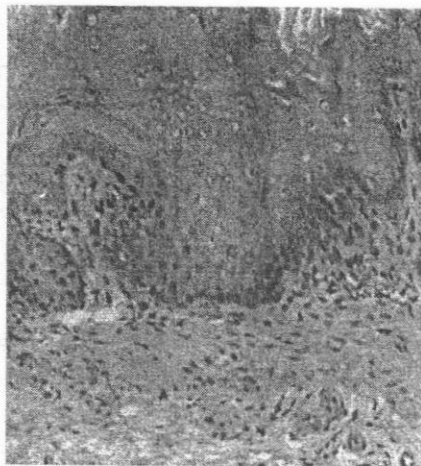

Fig (2): Marked epithelial hyperplasia with elongation of papilla (more than 1/3 of epithelium) and focal basal cells destruction (H&E stain, x400).

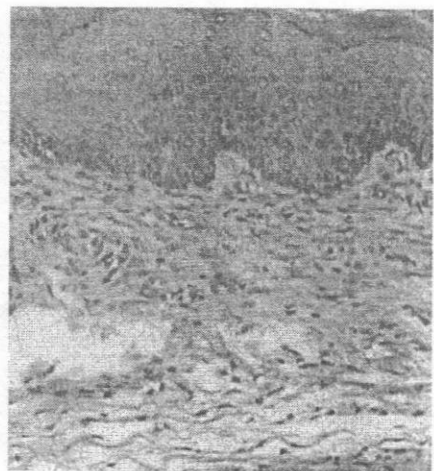


Fig (3): Focal basal cell hyperplasia more than 15% of epithelial thickening (H&E stain, x200).

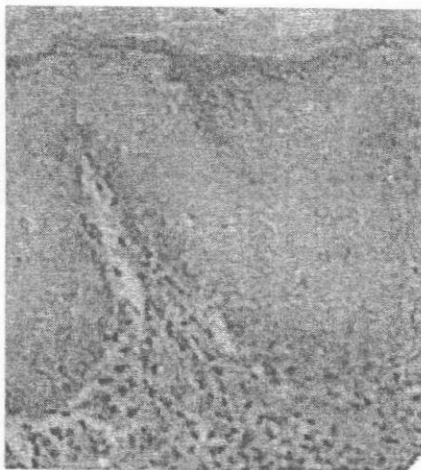


Fig (4) : Leukocytic infiltrate formed mainly of eosinophils in lamina propria (H&E stain, x400).

DISCUSSION

Esophageal lesion is likely to be multifactorial and the esophageal mucosa response to acid refluxate damage was associated with a failure in several mechanisms that include sensory nerves, and an endogenous NO release, an enhancement in the expression and release of cytokines, growth factor, adhesion molecules, and heat shock proteins and an increase in apoptosis (28). Small quantities of NO produced by calcium dependent nNOS play a physiological role in the gastrointestinal motility. Decreased nNOS function can result in motility disorders and lead to lower esophageal sphincter failure and GERD scenario, with relapse and chronicity of the disease (29). NO produced by eNOS dilates mucosal blood vessels and prevents leucocytes aggregation, and is therefore essential for the maintenance of esophageal mucosal blood flow. Absence of eNOS derived NO results in an increased susceptibility of GIT to injury (31). Pretreatment with NG-nitro-L-arginine (L-NNA), a non specific inhibitor of NOS, is accompanied by a decrease in plasma NO level, which results in reduction in esophageal blood flow (EBF) (13). This greatly augments the esophageal damage;

therefore it is reasonable to conclude that NOS/NO mediated response is important component of esophageal cytoprotection (13). On the other hand, oxygen free radicals are directly implicated in the pathogenesis of indomethacin induced mucosal damage (30). Furthermore, it has been shown that reflux esophagitis in rats is mediated by oxygen-derived free radicals, lipid peroxidation products or superoxide anions (31).

The present study evaluates the effects of the antiulcer drugs melatonin, omeprazole and the combination of both drugs in the reflux esophagitis with and without indomethacin administration.

An important endogenous substances involved in esophageal mucosal defense are prostaglandins (PG) (13). According to our results, RE caused significant increase in gastric acid output, decrease in pH and mucosal PGE2 generation. Furthermore, indomethacin, non selective blocker of cyclooxygenase-prostaglandin (COX/PG) system, caused a dramatic suppression of PG biosynthesis, significant increase in gastric acid output and decrease in pH resulting in significant aggravation

of esophageal injury. Moreover, the plasma level of NO in our study was significantly altered by GERD and further changed following pretreatment with indomethacin.

Our study showed that omeprazole administration before induction of RE, with or without indomethacin, significantly decreased acid output and increased pH relative to the RE group. Inhibition of gastric acid secretion by Proton pump inhibitors (PPI) as omeprazole is considered to be an important step to control the RE disorder (18). Proton pump inhibitors inhibit acid secretion by irreversibly interacting with the $H^+-K^+-ATPase$, the terminal proton pump of the parietal cell (32). In the acid space of the secreting parietal cell or in the vicinity of the enzyme, these compounds are converted to thiophilic sulfenamide or sulfenic acid, which reacts mainly with the Cys-813 residue in the catalytic subunit of the $H^+-K^+-ATPase$, which is critical for enzyme inactivation (33).

The modern approach of understanding the mechanism of the antiulcer effect of omeprazole should be directed toward exploring its plausible role in preventing oxidative damage and apoptosis as well as on the pro-

motion of healing process by cell proliferation. Although omeprazole blocks ulceration at a lower dose (2.5 mg/kg) without inhibiting acid secretion suggesting its independent antiulcer activity, at higher doses its additional antisecretory action definitely exerts beneficial effect by preventing aggravation of the wound, thereby helping the healing process by cell proliferation (34).

The present study showed that omeprazole administration, before induction of RE in rats with or without indomethacin, significantly decreased MDA and increased plasma GSH relative to the RE group. Thus, we can suggest that omeprazole has antioxidant and free radical scavenging activities. Suzuki et al (35) have demonstrated that omeprazole, *in vitro*, modulates neutrophil functions such as inhibition of oxygen derived free radical production and degradation of glucuronidase and lysozyme. PPIs such as omeprazole may affect inflammation regardless of their effect on inhibition of acid secretion. Omeprazole may thus prevent ulcer recurrence mainly by marked inhibition of acid secretion and its direct effect on neutrophil functions (36). Kobayashi et al., (37) reported that omeprazole

prevent RE and gastritis in rats by acting as an anti-inflammatory agent and by preventing neutrophil infiltration, and mucosal damage. Bandyopadhyay et al., (38) and Biswas et al., (34) found that omeprazole acts not only as proton pump inhibitor but also as an antioxidant and hydroxyl radical scavenger. Therefore, omeprazole is highly effective in blocking membrane lipid peroxidation and protein oxidation, which occur because of oxidative damage by reactive oxygen species (ROS) especially by OH (39). By blocking oxidative damage through lipid peroxidation and protein oxidation, omeprazole prevents loss of membrane permeability and dysfunction of the cellular proteins, leading to survival of the functionally active cells (34). Moreover, it offers an antiapoptotic effect by blocking DNA fragmentation during ulceration. Evidence has also been presented to show that omeprazole or lansoprazole blocks OH-induced oxidative damage of DNA by scavenging OH in vitro (34). This could be achieved if omeprazole or lansoprazole can directly scavenge the OH to form oxidation product. Omeprazole and lansoprazole undergo oxidation in cytochrome P-450 systems to produce hydroxyomeprazole or hydroxy-

lansoprazole and omeprazole sulfone or lansoprazole sulfone (40). Omeprazole has been shown to prevent compound 48/80 (mast cell degranulator)-induced gastric lesions (with no acid secretion) by acting as an anti-inflammatory agent and also by preventing neutrophil infiltration, activation, and associated mucosal damage (37). Thus, omeprazole may have multiple modes of action.

Also, the current study demonstrated that omeprazole has no significant effect on plasma MT, NO and mucosal PGE₂. Larsson et al (41) showed that omeprazole neither stimulates prostaglandin biosynthesis nor increases bicarbonate secretion to offer gastroprotection. Moreover, in our study, omeprazole significantly decreased the macroscopic damage score, lesion length, and the microscopic epithelial thickness and leucocyte infiltration scores relative to the RE group either non treated or those treated with melatonin. Thus, omeprazole has more prophylactic effect than melatonin in GERD. Since indomethacin pretreatment had no effect on the protective effect of omeprazole against reflux esophagitis, the participation of endogenous prostaglandins in the underlying mechanism could be

ruled out. These results were in agreement with Okabe et al (20).

Our study revealed that melatonin (MT) administration, before induction of RE in rats with or without indomethacin, significantly decreased acid output, and increased pH. These results are in agreement with Kato et al (42) and Lahiri et al (6) who reported that melatonin decreases gastric acid secretion. In the present study, we also found that the inhibitory effect of MT on gastric acid secretion is significantly lesser than the effect of omeprazole. Konturek et al (43) showed that the esophagoprotective activity of melatonin against GERD might be related to the inhibitory effect of this indole on gastric acid secretion and due to stimulation of gastrin release, which might attenuate the gastro-esophageal reflux by stimulation of the contractile activity of the lower esophageal sphincter. Reiter et al. (44) and Bandyopadhyay and Catapadhyay (45) concluded that MT functions in the gut seem to be protection of the mucosa from erosion and ulcer formation and to influence the movement of the gastrointestinal content through the digestive system. Bubenik et al. (46) demonstrated that 4-week administration of melatonin in

the diet significantly reduced the incidence of spontaneous (chronic) gastric ulcers in young pigs. It is of interest that the pigs with such ulcers exhibited lower contents of melatonin in the gastric mucosa and in the blood suggesting that these spontaneous ulcers originate from the local deficiency of this indole.

Moreover, the current study showed that MT significantly decreased esophageal lipid peroxidation products (MDA) that are aggravated by RE, whereas, the depleted levels of the anti-oxidant glutathione observed in RE were replenished by melatonin signifying its free radical scavenging properties and antioxidant effects resulting in the improvement of esophageal defense mechanism. These results were consistent with previous studies (6, 47, 48). Melatonin was found to protect the gastrointestinal mucosa from oxidative damage caused by reactive oxygen species (ROS) not only by scavenging OH radicals but also possibly by increasing the activities of two key gastric antioxidant enzymes, i.e gastric peroxidase (GPO) and superoxide dismutase (SOD) (38). Also, the mechanism of melatonin beneficial action has been attributed to its high

lipophilic properties allowing for the rapid entrance into the cells to protect their subcellular compartments (49). No significant difference was found between the effect of MT and omeprazole on MDA and GSH, therefore we can suggest that both have nearly the same anti-oxidant, free radical scavenging actions. Furthermore, MT administration increased plasma level of MT, and NO, and mucosal PGE2 content. In indomethacin administered rats with RE, MT tend to increase PGE2 generation but this increase was non significant. It is widely accepted that melatonin, a potent endogenous free radical scavenger, plays a pivotal role in NO mediated vasodilatation and enhances the generation of endogenous mucosal PGE2, derived from the COX activity (16), causing esophageal hyperemia, suggesting that these favorable effects of this indole were mediated through mucosal NOS/NO and COX/PG system (16,50,51). Therefore, the increased NO and PGE2 by MT administration, in the present study, resulted in vasodilating effect on esophageal microcirculation and increased EBF which prevented the formation of mucosal lesions, afforded protection against the damage of the mucosa exposed to acid refluxate and de-

creased the macroscopic damage score. These results were in accord with Koturek et al (13).

Moreover, our study showed that MT significantly decreased the macroscopic damage score, lesion length, and the microscopic regenerative epithelial changes and leucocyte infiltration scores in RE rats, with or without indomethacin administration, but these effects were less significant than those of omeprazole. Since these protective effects of MT, but not omeprazole, were significantly attenuated by pretreatment with COX inhibitor (indomethacin), we can propose that MT protects esophageal mucosa by increasing mucosal blood flow through the enhancement of PG release in the mucosa.

In addition, melatonin can exert its effect in the protection and treatment of GERD by several other mechanisms. The first is the involvement of melatonin in the stimulation of the mucosa -protective alkaline secretion by gastric mucosa (52). Reiter et al. (44) stated that melatonin influences bicarbonate secretion in the stomach and duodenum and has a role in preventing and repairing ulcers in them. They also reported that melatonin's

action in the control of bicarbonate secretion involves the central and peripheral sympathetic nervous systems and this action is receptor mediated. Kato et al. (53) found that melatonin plays a protective, anti-stress role in the gastric mucosa via a mechanism involving the central nervous system as melatonin may readily cross the blood brain barrier. They added that the inhibitory effect of peripherally administered melatonin may be mediated not only by peripheral receptors in the stomach but also by receptors in the central nervous system. Konturek et al (54) and Lahiri et al (6) reported that MT has strong anti-inflammatory effect as it inhibits the expression of the proinflammatory cytokine $TNF\alpha$.

Combined administration of both MT and omeprazole before induction of RE in untreated rats or those administered indomethacin significantly decreased acid output and MDA and increased pH and GSH relative to the RE rats or those pretreated with omeprazole and MT. Moreover, they significantly increases NO and plasma MT relative to the RE rats or those pretreated with omeprazole but not MT. Mucosal PGE₂, in RE rats not treated with inomethain, was significantly increased by the combined

MT and omeprazole relative to the RE rats or those pretreated with omeprazole but not MT. In addition, they significantly decreased the macroscopic damage score, lesion length and the microscopic regenerative epithelial changes and leucocyte infiltration scores relative to the RE rats or those pretreated with omeprazole and MT.

Rieter et al. (9) reported that melatonin when combined with other anti ulcer drugs like omeprazole has beneficial effects as it accelerates the healing effects of omeprazole and shortens the duration of treatment. Therefore melatonin reduces the side effects and increases the efficacy of omeprazole. Previously, Sener-Muratoglu et al. (56) compared the antiulcer and gastroduodenal protective mechanism of famotidine, omeprazole and melatonin and their results revealed that the three drugs have gastroduodenal protective action but famotidine and omeprazole have lowering effects on gastric acidity (antisecretory activity) whereas melatonin has no effect on this parameter but famotidine and omeprazole were not effecient as antioxidant as melatonin. In addition, Bandyopadhyay et al. (38) stated that melatonin prevented gas-

tric damage and when compared with already marketed anti-ulcer drugs such as ranitidine and omeprazole, melatonin was found to be more effective than ranitidine but less effective than omeprazole in preventing stress ulcer. They also demonstrated that co-treatment of GERD with melatonin at low dose synergistically increases the efficacy of omeprazole in preventing stress induced lesion. This may be important as giving omeprazole at lower doses would reduce the severity of their side effects.

CONCLUSION

- 1- Melatonin has a protective effect on GERD as it is anti-oxidant, and free radical scavenger. Moreover, it inhibits gastric acid secretion, and increases NO and PGE2 which in turn increase esophageal blood flow, thus decreasing the esophageal damage score. However, it is less effective than omeprazole.
- 2- Omeprazole has a protective effect on GERD not only because of its inhibitory effect on gastric acid secretion, but also because of its anti-oxidant, and free radical scavenging actions. Its action is

not affected by indomethacin.

- 3- Combination of melatonin and omeprazole is preferable as melatonin accelerates the healing effect of omeprazole and therefore shortens the duration of treatment and minimizes its side effects. Also, the combined treatment is more effective in anti-oxidant, and free radical scavenging actions as well as inhibition of gastric acid secretion than melatonin or omeprazole alone.

REFERENCES

1. Bell NJ, Burget D, Howden CW, Wilkinson J, and Hunt RH. (1992) : Appropriate acid suppression for the management of gastro-oesophageal reflux disease. *Digestion*; 51 (Suppl. 1): 59-67.
2. Aste H, Bonelli L, Ferraris R, Conio M, Lapertosa G. (1999) : Gastroesophageal reflux disease; Relationship between clinical and histological features. *Dig Dis Sci*; 44:2412-18.
3. Hirschowitz BI. (1991) : A critical analysis, with appropriate

- controls, of gastric and pepsin secretion in clinical esophagitis. *Gastroenterology*; 101:1149-58.
4. **Biancani P, Sohn UD, Rich HG, Harnett KM, and Behar J. (1997)** : Signal transduction pathways in esophageal and lower esophageal sphincter circular muscle. *Am J Med*; 103: 23S-28S.
5. **Min Y S, Lee S E, Hong S T, Kim H S, Choi B-C, Sim S S, Whang W K, and Sohn UD. (2009)** : The Inhibitory Effect of Quercetin-3-O- β -D-Gluc-uronopyranoside on Gastritis and Reflux Esophagitis in Rats. *Korean J Physiol Pharmacol.*; 13: 295-300.
6. **Lahiri S, Singh P, Singh S, Rasheed N, Palit G, and Pant KK. (2009)** : Melatonin protects against experimental reflux esophagitis. *J Pineal Res.*; 46(2):207-13.
7. **Hardeland R, Pandi-Perumal SR, and Cardinali DP. (2006)** : Melatonin. *Int J Bi*
- ochem Cell Biol*; 38:313-316.
8. **Bubenik GA. (2001)** : Localization, physiological significance and possible clinical implication of gastrointestinal melatonin. *Biol. Signals. Recept*; 10: 350-366.
9. **Reiter RJ, Tan DX, and Manchester LC (2002)** : Antioxidative capacity of melatonin. In : *Handbook of Antioxidants*, 2nd edn. Cadenas E, Packer L eds, Marcel Dekker, New York, pp. 565-613.
10. **Konturek SJ, Konturek PC, Brzozowski T, and Bubenik GA. (2007)** : Role of melatonin in upper gastrointestinal tract. *J Physiol Pharmacol.*; 58 Suppl 6: 32-52.
11. **Lee PN, Hong GX, and Pang SF. (1991)** : Melatonin in the gastrointestinal tract. In *Role of Melatonin and Pineal Peptides in Neuroimmunomodulation*, Fraschini F, Reiter RJ (eds). New York,

Plenum Press, pp. 1127-1136.

12. **Ekmekcioglu C. (2006)** : Melatonin receptors in humans: biological role and clinical relevance. *Biomed Pharmacother.* 60:97-108.
13. **Konturek SJ, Zayachkivska O, Havryluk XO, Brzozowski T, Sliwowski Z, Pawlik M, Konturek PC, Czesnikiewicz-Guzik M, Gzhegotsky MR, and Pawlik WW. (2007)** : Protective effect of melatonin against acute esophageal lesions involve prostaglandins, nitric oxide and sensory nerves. *J Physiol Pharmacol.* 58:361-377.
14. **Bhat YM, and Bielefeldt K. (2006)** : Capsaicin receptor (TRPV1) and non erosive reflux disease. *Eur J Gastroenterol Hepatol.* 18(3): 293-270.
15. **Patterson LM, Zheng H, Ward SM, and Berthoud HR. (2003)** : Vanilloid receptor (VR1) expression in vagal afferent neurons innervating the gastrointestinal tract. *Cell Tissue Res.*; 311:277-287.
16. **Konturek SJ, Konturek PC, and Brzozowski T. (2006)** : Melatonin in gastroprotection against stress-induced acute gastric lesions and healing of chronic gastroduodenal ulcers. *J Physiol Pharmacol.*; 57 (Suppl 5): 51-66.
17. **Horn, J. (2000)** : Proton pump inhibitors: similarities and differences. *Clin. Ther.* 22, 266-280.
18. **Sachs, G., Shin JM, Besancon M, and Prinz C. (1993)** : The continuing development of gastric acid pump inhibitors. *Aliment. Pharmacol. Ther.* 7 (Suppl. 1) 4-12.
19. **Nakamura K, Ozawa Y, Furuta Y, Miyazaki H. (1982)** : Effects of sodium polyacrylate (PANa) on acute esophagitis by gastric juice in rats. *Jpn J Pharmacol.*; 32: 445-456.

20. Okabe S, Takinami Y, Iwata K, and Yanagawa T. (1995) : Mucosal protective effect of leminoprazole on reflux esophagitis induced in rats. *Jpn J Pharmacol.*; 69: 317-323.
21. Middleton B. (2006) : Measurement of melatonin and 6 sulphatoxymelatonin: In wheeler MS, and Hutchinson JS eds, *Methods in molecular biology, Hormone assays in biological fluids*. Humana press, Surrey, UK.; pp:235-254.
22. Bulau, P, Zakrzewicz D, Kitowska K, Leiper J, Gunther A, Grimminger F and Eickelberg O. (2007) : Analysis of methylarginine metabolism in the cardiovascular system identifies the lung as a major source of ADMA. *Am J Physiol Lung Cell Mol Physiol.*; 292: L18-L24.
23. Buege JA, and Aust SD. (1972) : Microsomal lipid peroxidation. *Methods Enzymol.*; 52:302-10.
24. Blenn, C., Althaus FR, and Malanga M. (2006) : Poly (ADP-ribose) glycohydrolase silencing protects against H₂O₂-induced cell death. *Biochem J.*; 396 (3):419-29.
25. Konturek SJ, Konturek PC, and Brzozowski T. (2005) : Role of prostaglandins in ulcer healing. *J Physiol Pharmacol.*; 56 (Suppl 5): 33-56.
26. Schindlbeck NE, Wiebecke B, Klauser AG, Voderholzer WA, Müller-Lissner SA. (1996) : Diagnostic value of histology in non-erosive gastro-oesophageal reflux disease. *Gut*; 39:151-154.
27. Armitage P, and Berry G. (1994) : Statistical methods in medical research. 3rd ed. Blackwell Scientific. In: *Statistical Methods in Medical Research* (3rd Edition ed.), Blackwell Scientific Publications, London 1994; pp: 292-305.
28. Poplawski C, Sosnowski D,

- Szaflarska-Poplawska A, Sarosiek J, McCallum R, and Bartuzi Z. (2006) :** Role of bile acids, prostaglandins, and COX inhibitors in chronic esophagitis in a mouse model. *World, J. Gastroenterol.*; 12 (11): 1739-1742.
29. **Modlin IM, and Sachs G. (2005) :** Acid related diseases: biology and treatment. Philadelphia: Lippincott, Williams and Wilkins; pp: 259-362.
30. **Kvietys PR, Twohig B, Danzell J, and Specian RD. (1990) :** Ethanol-induced injury to the rat gastric mucosa. Role of neutrophils and xanthine oxidase-derived radicals. *Gastroenterology*; 98: 909-920.
31. **Wetscher GJ, Perdakis G, Kretchmar DH, Stinson RG, Bagchi D, Redmond EJ, Adrian TE, and Hinder RA. (1995) :** Esophagitis in Sprague-Dawley rats is mediated by free radicals. *Dig Dis Sci*; 40: 1297-1305.
32. **Sachs, G. (1997) :** Proton pump inhibitors and acid related diseases *Pharmacotherapy*; 17, 22-37.
33. **Wolfe M M, and Sachs G. (2000) :** optimizing therapy for gastroduodenal ulcer healing, gastroesophageal reflux disease, and stress-related erosive syndrome. *Gastroenterology*; 118, S9-S31
34. **Biswas K, Bandyopadhyay U, Chattopadhyay I, Varadaraj A, Ali E, and Banerjee RK. (2003) :** A novel antioxidant and antiapoptotic role of omeprazole to block gastric ulcer through scavenging of hydroxyl radical.; 28;278(13):10993-1001.
35. **Suzuki M, Mori M, Miura S, Sue-matsu M., Fukumura D., Kimura H., Ishii H. (1996) :** Omeprazole attenuates oxygen-derived free radical production from human neutrophils. *Free Radic Biol Med.*; 21:727-31.
36. **Watanabe T, Higuchi K, Tomi-**

- naga K, Fujiwara Y, and Arakawa T. (2001) : Acid regulates inflammatory response in a rat model of induction of gastric ulcer recurrence by interleukin 1 β . Gut; 48: 774-781.
37. Kobayashi T, Ohta Y, Inui K, Yoshino J, and Nakazawa S. (2002) : Protective effect of omeprazole against acute gastric mucosal lesions induced by compound 48/80, a mast cell degranulator, in rats. Pharmacol. Res.; 46(1):75-84.
38. Bandyopadhyay D, Bandyopadhyay A, Das PK, and Reiter RJ (2002) : Melatonin protects against gastric ulceration and increases the efficacy of ranitidine and omeprazole in reducing gastric damage. J Pineal Res.; 33(1):1-7.
39. Bhattacharjee M, Bhattacharjee S, Gupta A, Banerjee, RK (2002) : Critical role of an endogenous gastric peroxidase in controlling oxidative damage in H. pylori mediated and non mediated gastric ulcer. Free Radical Biol. Med.; 32, 731-743.
40. Kanazawa H, Okada A, Matsu-shima Y, Yokota H, Okubo S, Mashige F, and Naka-hara K. (2002) : Determination of omeprazole and its metabolites in human plasma by liquid chromatography-mass spectrometry. J. Chromatogr. A; 949: 1-9.
41. Larsson H, Mattson H, Sundell G, and Carlsson E. (1985) : Animal pharmacodynamics of omeprazole. A survey of its pharmacological properties in vivo. Scand. J.Gastroenterol.; 20, (Suppl. 108): 23-35.
42. Kato K, Murai I, Asai S, Takahashi Y, Matsuno Y, Komuro S, Kurosaka H, Iwasaki A, Ishikawa K, and Arakawa Y. (1998) : Central nervous system action of melatonin on gastric acid and pepsin secretion in pylorus-ligated rats. Neuroreport.; 9 (17): 3989-92.

43. Konturek SJ, Konturek PC, Brzozowska I, Pawlik M, Sliwowski Z, Czenikiewicz-Guzik M, Kwiecien S, Brzozowski T, Bubenik GA, and Pawlik WW. (2007) : Localization and biological activities of melatonin in intact and diseased gastrointestinal tract. *J physiol pharmacol.*; 58 (3):381-405.
44. Reiter RJ, Tan DX, Mayo JC, Sainz RM, Leon M. and Bandyopadhyay D. (2003) : Neurally-mediated and neurally-independent beneficial actions of melatonin in the gastrointestinal tract. *J Physiol Pharmacol.*; 54 (4):113-25.
45. Bandyopadhyay D, and Chattopadhyay A. (2006) : Reactive oxygen species-induced gastric ulceration: protection by melatonin. *Curr Med Chem.*; 13 (10):1187-202.
46. Bubenik GA, Ayles HL, Friendship RM, Brown GM, and Ball RO. (1998) : Relationship between melatonin levels in plasma and gastrointestinal tissues and the incidence and severity of gastric ulcers in pigs. *J Pineal Res.*; 24: 62-66.
47. Akbulut H, Akbulut KG, Gonul B. (1997) : Malodialdehyde and glutathione in rat gastric mucosa and effects of exogenous melatonin. *Dig Dis Sci.*; 42:1381-1388.
48. Cabeza J, Motilva V, and Alarcon de la Lastra CA. (2001) : Mechanism involved in the gastric protection of melatonin on ischemiareperfusion-induced oxidative damage in rats. *Life Sci.*; 68:1405-1415.
49. Emerit J, Edeas M, Bricaire F. (2004) : Neurodegenerative diseases and oxidative stress. *Biomed Pharmacother*; 58: 39-46.
50. Brzozowska I, Konturek PC, Brzozowski T, Konturek SJ, Kwiecien S, Pajdo R, Drozdowicz D, Pawlik M,

- Ptak A and Hahn, E.G. (2002) :** Role of prostaglandins, nitric oxide, sensory nerves and gastrin in acceleration of ulcer healing by melatonin and its precursor, L-tryptophan. *J Pineal Res.*; 32(3):149-162.
51. **Jaworek J, Brzozowski T, and Konturek SJ (2005) :** Melatonin as an organoprotector in the stomach and the pancreas. *J Pineal Res.*; 38(2):73-83.
52. **Sjoblom, M. and Flemstrom, G. (2001) :** Central nervous stimuli increase duodenal bicarbonate secretion by release of mucosal melatonin. *J Physiol Pharmacol.*; 52 (4 Pt 1):671-8.
53. **Kato K, Asai S, Murai I, Nagata T, Takahashi Y, Komuro S, Iwasaki A, Ishikawa K, and Arakawa Y. (2001) :** Melatonin's gastroprotective and antistress roles involve both central and peripheral effects. *J Gastroenterol.*; 36(2):91-5.
54. **Konturek PC, Burant G, Brzozowski T, Zopf Y, and Konturek SJ. (2008) :** Tryptophane free diet delays healing of chronic gastric ulcers in rats. *J. Physiol Pharmacol.*; 59 (suppl. 2): 53-65.
55. **Sener-Muratoglu G, Paskaloglu K, Arbak S, Hurdag C, and Ayanoglu-Dulger G. (2001) :** Protective effect of famotidine, omeprazole, and melatonin against acetylsalicylic acid-induced gastric damage in rats. *Dig Dis Sci.*; 46(2) :318-30.

الملخص العربي تأثير الميلاتونين والأوميبرازول في ارتجاع الحمض المعدى إلى المرئ في الفئران

بحث مقدم من:

د. عمرو مدحت عباس* ، د/ أحمد الجندي*

أ.د/ هناء جلال السروجي* ، د/ على عبد الوهاب على**

قسمى الفسيولوجيا الطبية* والباثولوجي**

كلية الطب - جامعة المنصورة

أجرى هذا البحث لدراسة دور الميلاتونين والأوميبرازول في ارتجاع الحمض المعدى إلى المرئ في الفئران وقد تم إجراء هذا البحث على ٦٠ فأرا تم تقسيمهم إلى خمسة مجموعات:

- المجموعة الأولى: وتشمل ١٢ فأرا منهم ٦ تم اعتبارهم sham و ٦ آخرين تم اعتبارهم sham و تم حقنهم بمادة indomethacin

- المجموعة الثانية: وتشمل ١٢ فأرا منهم ٦ تم إحداث ارتجاع في الحمض المعدى إلى المرئ لهم و ٦ آخرين تم حقنهم بمادة indomethacin ثم تم إحداث ارتجاع في الحمض المعدى إلى المرئ لهم

- المجموعة الثالثة: وتشمل ١٢ فأرا منهم ٦ تم حقنهم بالميلاتونين ثم تم إحداث ارتجاع في الحمض المعدى إلى المرئ لهم و ٦ آخرين تم حقنهم بالميلاتونين ثم بمادة indomethacin ثم تم إحداث ارتجاع في الحمض المعدى إلى المرئ لهم

- المجموعة الرابعة: وتشمل ١٢ فأرا منهم ٦ تم حقنهم بالأوميبرازول ثم تم إحداث ارتجاع في الحمض المعدى إلى المرئ لهم و ٦ آخرين تم حقنهم بالأوميبرازول ثم بمادة indomethacin ثم تم إحداث ارتجاع في الحمض المعدى إلى المرئ لهم.

- المجموعة الخامسة: وتشمل ١٢ فأرا منهم ٦ تم حقنهم بالميلاتونين والأوميبرازول ثم تم إحداث ارتجاع فى الحمض المعدى إلى المرئ لهم و ٦ آخرين تم حقنهم بالميلاتونين والأوميبرازول ثم بمادة indomethacin ثم تم إحداث ارتجاع فى الحمض المعدى إلى المرئ لهم.

وقد تم عمل الفحوصات الآتية لكل الفئران:

١- قياس حموضة المعدة والأس الهيدروجينى.

٢- قياس أكسيد النيتريك و الميلاتونين فى البلازما.

٣- قياس malondialdehyde و reduced glutathione و prostaglandin E2 فى الغشاء المخاطى المبطن للمرئ.

٤- الفحص الباثولوجى لعينات من المرئ.

وقد أظهر البحث أن الميلاتونين والأوميبرازول يقللوا الحموضة المعدية ويزيدوا الأس الهيدروجينى ويعتبروا مضادات للأكسدة ويحسنوا من الإصابة فى المرئ ولكن تأثير الأوميبرازول أفضل من الميلاتونين وقد أظهر هذا البحث أيضا أن تأثير الميلاتونين والأوميبرازول معا أفضل من تأثير كلا منهما بمفرده كما توضح هذه الدراسة أن مادة indomethacin تقلل من تأثير الميلاتونين بينما ليس لها تأثير على الأوميبرازول.

و نستخلص من هذا البحث أنه يمكن إعطاء الأوميبرازول و الميلاتونين أو كلاهما لعلاج ارتجاع الحمض المعدى إلى المرئ لأنهم يقللوا الحموضة المعدية ويعتبروا مضادات للأكسدة.

