

EVALUATION OF CERTAIN THERAPEUTIC MODALITIES IN TREATMENT OF SOLAR KERATOSIS AND SOLAR LENTIGINES: A COMPARATIVE STUDY

By

Shaymaa El-Mongy, Nora M Darwish,
Mohamed A Gab Allah

From

*Department of Dermatology & Venereology,
Faculty of Medicine, Mansoura University*

ABSTRACT

Many lines of treatment of solar keratosis and solar lentigines are present but still with some adverse effects. The present work aimed to compare three methods for treatment of solar keratosis (cryosurgery, dermabrasion and topical 5- fluorouracil) and of solar lentigines (topical tretinoin 0.05% cream, cryotherapy and dermabrasion) in order to determine the most preferable method. Thirty nine patients of either sex were subjected to careful history taking, pre, during and post treatment photographs.

The patients were randomly arranged in 5 groups: group I, II, III for

solar keratosis (21 patients), every 7 patients were treated with either topical 5-fluorouracil 5% cream, cryosurgery or dermabrasion respectively. Regarding, solar lentigines patients were randomly divided into 2 groups, group IV, (10 patients were treated with topical tretinoin 0.05%) and group V (8 patients were treated with cryotherapy of some lesions on the back of right hand and localized dermabrasion of some lesions on the back of left hand).

Cryosurgery is considered the most effective treatment modality for solar keratosis (with cure rate 100% and without recurrence of any treated lesion). It is well tolerated by the pa-

tient. Another good method of treatment is dermabrasion. It is safe, effective, inexpensive, and available. It has some complications which can be minimized. The cure rate was 85.7% and one case showed recurrence (14.3%).

Topical 5-FU 5% is considered as an effective treatment for solar keratosis. In the present study, cure rate of 85.7% was reported and no recurrence during the 6 months follow-up. Photosensitivity and hyperpigmentation with 5-FU can be avoided by good compliance of the patient and by clear instructions to avoid outdoor activity during the period of treatment.

On the other hand, topical tretinoin 0.05% cream, coupled with avoidance of the sun is an effective non destructive approach to improve solar lentigines. It makes only just improvement of solar lentigines. Adverse effects is little and tolerable.

Cryotherapy is preferable for treatment of solar lentigines. Localized dermabrasion is an efficacious therapeutic alternative. Complications with dermabrasion were more severe than

that of cryotherapy especially infection, serous crusts and erosions while cryotherapy is more painful but it is usually transient. Recurrence rate was the same with each procedure (50%).

INTRODUCTION

The present study included two dermatological disorders namely solar keratosis and solar lentigines. Solar keratosis is a hyperkeratotic lesion occurring in sun-exposed skin, which carries a low risk of progression to invasive squamous cell carcinoma⁽¹⁾. There are many effective treatments for solar keratosis such as cryosurgery, curettage, and topical 5-fluorouracil. Dermabrasion, chemical or cryosurgical peeling, and laser are considered less common however, effective treatments⁽²⁾. Solar keratosis has a wide range of clinical presentations, and each patient is unique.

Solar lentigo is circumscribed brown pigmented macule occurring singly or as multiple lesions, on sun-exposed skin, after acute or chronic sun exposure^(3,4). For solar lentigo there are many effective therapeutic modalities, e.g. topical tretinoin, cryotherapy, dermabrasion, and laser.

Aim of the Work :

The present work aims to compare different modalities of treatment of either solar keratosis or solar lentigines as regard their efficacy, side effects, and patient tolerability in order to determine the most preferable method of treatment for either solar keratosis or solar lentigines.

PATIENTS AND METHODS

This work was conducted on 39 patients of either sex (21 patients have solar keratosis on their face and 18 patients have solar lentigines on the back of their hands). The patients were selected randomly from those attending the outpatient clinic of Dermatology, Andrology and STDs department at Mansoura University Hospital. While, 66.7% of our patients were males (26 patients), 34.3% of them were females (13 patients). Solar keratosis patients were randomly arranged in three groups each 7 patients:

Group I : 7 patients were treated with topical 5-fluorouracil 5% cream applied twice daily for 4 weeks.

Group II : 7 patients were treated

with cryosurgery for one sitting for each patient using liquid nitrogen.

Group III : 7 patients were treated with dermabrasion, using diamond fraises, for one sitting for each patient.

Solar lentigines patients were randomly selected and divided into two groups:

Group IV : 10 patients were treated with topical tretinoin 0.05% cream applied once nightly for 6 months. Only 8 patients completed the study till its end.

Group V : 8 patients were treated with cryotherapy of some lesions on the back of right hand and localized dermabrasion of some lesions on the back of left hand for one sitting each.

The patients were subjected to careful history taking, general and dermatological examination, pre, during, and post treatment photographs. The patients were followed up for six

months after the end of the therapy.

Data were analyzed using EPI IWFO statistical package version 6.02. Categorical data was presented as number and percent. Fisher's exact test was used to compare between groups. Quantitative data was presented as mean + standard deviation. Student's t-test was used for comparison between two means and Anova (F) test was used for comparison between more than two means. $P < 0.05$ was considered to be statistically significant.

RESULTS

As regard patients of group I, the following side effects appeared at the sites of application of the treatment in the form of pruritus and burning sensation as shown in table (1):

All of the previously mentioned side effects disappeared within about one month after discontinuation of treatment. Photosensitivity with intense erythema and residual hyperpigmentation appeared in one patient (14.3%). Complete cure of treated lesions was reported in 85.7% of patients and failure of therapy was re-

ported in one patient (14.3% of treated patients).

During follow-up of the patients of group II, pain, oedema, and blisters formation appeared as frequent temporary complications for cryosurgery. Pain, oedema and blisters (bullae) appeared in 57.1%, 14.3% and 100% of patients respectively. All these complications disappeared in a duration ranged from 2 hours to one week. Bacterial infection of the wound appeared in 14.3% of patients and disappeared within one week after using oral broad spectrum antibiotic. Transient hypopigmentation appeared in 14.3% of treated patients and disappeared in one month while permanent hypopigmentation appeared in 28.6% of patients. Healing by bad atrophic scar appeared in only one patient (14.3%) by the end of the 1st month of follow-up. With cryosurgery, cure rate was 100% and no recurrences were reported (table 2).

In the group III, dermabrasion was done under anesthesia. However, one patient (14.3%) expressed mild pain and another one expressed moderate pain during the procedure.

Erosions and crustations appeared in all treated lesion and healing was completed within 3 weeks. Erythema appeared in 71.4% as a complication of dermabrasion but persisted in only one case and disappeared from the rest of treated patients. Cure rate without recurrences was 85.7% of treated patients and recurrence appeared in 14.3% of treated patients.

There was insignificant difference between the outcome of each group compared by the other two groups ($P>0.05$) (table 3).

Regarding group IV, there was statistically significant hypopigmentation of the treated solar lentigines by the end of 1st month of treatment with topical tretinoin 0.05% in 87.5% of treated patients. By the end of treatment period, there was obvious decreased pigmentation of solar lentigines in 87.5% of treated patients while there was no color change of treated lesions in 12.5%. Erythema appeared in 12.5% of treated patients and scaling appeared in 87.5% of patients. They improved when emollients were applied and the amount of

topical tretinoin was decreased (table 4,5).

Regarding group V, during the follow-up of treated patients, serous crusts and erosions were significantly more after localized dermabrasion while blisters formation were reported only with cryotherapy. As regard other side effects observed during the follow-up period, erythema and infection, were non significantly more after localized dermabrasion while swelling, pain, and brown crustation were non significantly more with cryotherapy. Healing by bad scar was reported in 12.5% of treated patients following either localized dermabrasion or cryotherapy (table 6,7).

Hyperpigmentation was considered as recurrence of treated lesions. Rate of complete cure was 50% and the rate of recurrence was 50% with each of the dermabrasion and the cryotherapy (table 7).

Recurrence started by the end of first month postoperatively and increased gradually till the end of follow up period i.e. 6 months.

Table (1) : Percentage of expected side effects of 5FU during weekly visits in group I.

Item	1 st week		2 nd week		3 rd week		4 th week	
	No	%	No	%	No	%	No	%
Pruritus	-	-	2	28.6	4	57.1	4	57.1
Burning sensation	-	-	-	-	1	14.3	2	28.6

Table (2): Complications of cryosurgery reported in group II.

Type of complication	Number	%
Frequent temporary		
-Pain	4	57.1
-Oedema	1	14.3
-Bulla formation	7	100
Infrequent temporary		
-Wound infection	1	14.3
-Temporary hypopigmentation	1	14.3
Permanent		
-Hypopigmentation	2	28.6
-Atrophic scar	1	14.3

Table (3): Outcome of the 3 groups of solar keratosis.

Outcome	Group I		Group II		Group III	
	No	%	No	%	No	%
Complete cure	6	85.7	7	100	6	85.7
Failure of therapy	1	14.3	-	-	-	-
Recurrence	-	-	-	-	1	14.3

Group I vs group II Fisher's exact $P > 0.05$ Group II vs group III Fisher's exact $P > 0.05$.

Table (4): Change in color during follow-up in group IV.

Follow up	Unchanged		Hypopigmentation		Significant test
	No	%	No	%	
2 weeks*	6	75	2	25	
1 month*	1	12.5	7	87.5	Fisher's $P \leq 0.05$
2 months*	5	62.5	3	37.5	Fisher's $P > 0.05$
3 months*	4	50	4	50	Fisher's $P > 0.05$
4 months*	3	37.5	5	62.5	Fisher's $P > 0.05$
5 months*	6	75	2	25	Fisher's $P > 0.05$
6 months*	3	37.5	5	62.5	Fisher's $P > 0.05$
Overall **	1	12.5	7	87.5	

* Compared to the previous visit.

Table (5): Complications during treatment in group IV.

Item	No	%
Erythema	1	12.5
Scaling	7	87.5
None	1	12.5

Table (6): Side effects present on postoperative days 1 and 8 in group V.

Side effect	Day 1				Day 8			
	Dermabrasion		Cryotherapy		Dermabrasion		Cryotherapy	
	No	%	No	%	No	%	No	%
Serous crusts	8 **	100	1	12.5	5	62.5	6	75
Erythema	8	100	4	50	8	100	5	62.5
Erosion	6 *	75	1	12.5	4	50	2	25
Blisters	- **	-	6	75	-	-	2	25
Swelling	2	25	3	37.5	-	-	-	-
Pain	-	-	-	-	-	-	1	12.5
Brown crusts	-	-	-	-	1	12.5	3	37.5
Infection	-	-	-	-	2	25	1	12.5

* $P \leq 0.05$ Fisher's exact test.** $P \leq 0.01$ Fisher's exact test.

Table (7): Side effects observed 1, 2, 3 and 6 months postoperatively in group V.

Side effect	1 month				2 months			
	Dermabrasion		Cryotherapy		Dermabrasion		Cryotherapy	
	No	%	No	%	No	%	No	%
Erythema	3	37.5	5	62.5	-	-	3	37.5
Hyperpigmentation	1	12.5	1	12.5	2	25	2	25
Scar	1	12.5	1	12.5	1	12.5	1	12.5
Side effect	3 months				6 months			
	Dermabrasion		Cryotherapy		Dermabrasion		Cryotherapy	
	No	%	No	%	No	%	No	%
Hyperpigmentation	3	37.5	2	25	4	50	4	50
Scar	1	12.5	1	12.5	1	12.5	1	12.5

Table (8): Outcome of the 3 groups of solar keratosis.

Outcome	Group I		Group II		Group III	
	No	%	No	%	No	%
Complete cure	6	85.7	7	100	6	85.7
Failure of therapy	1	14.3	-	-	-	-
Recurrence	-	-	-	-	1	14.3

Group I vs group II Fisher's exact $P > 0.05$ Group II vs group III Fisher's exact $P > 0.05$.

Fig (1) : Two Solar Keratoses over the Ear pinna (before treatment with 5-FU cream) .

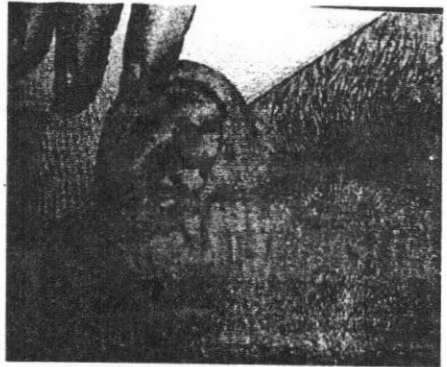


Fig (2) : Complete cure of solar keratoses (after treatment) .

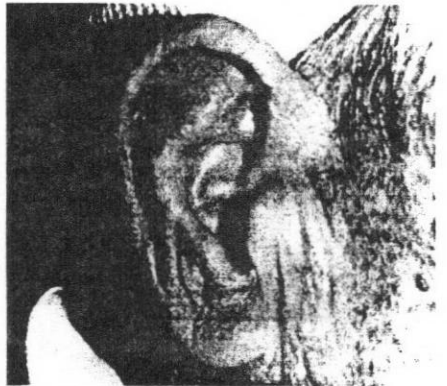

Fig (3) : Solar keratosis over the forehead (before treatment with dermabrasion) .




Fig (4) : Complete disappearance of solar Keratosis (After treatment by dermabrasion).

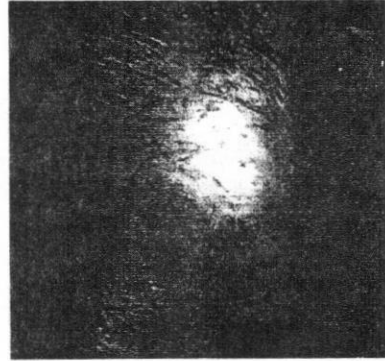
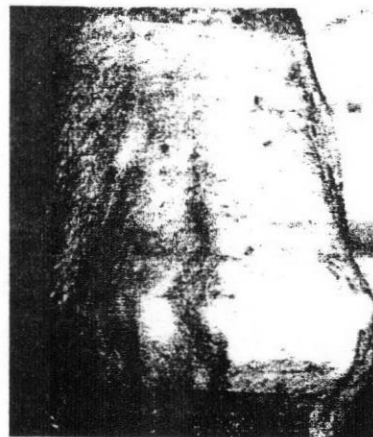


Fig (5) : Solar lentigines over back of the hand (before treatment with tretinoin 0.05% cream) .

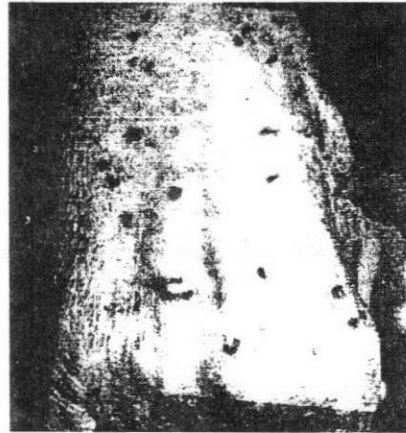

Fig (6) : Obvious hypopigmentation of solar lentigines over back of the hand (after treatment with tretinoin 0.05% cream) ..



DISCUSSION

Human skin exposed to solar radiation for a long time subsequently develops pigmented spots, which are named solar lentigines and solar keratosis⁽⁵⁾. Current treatments for actinic keratosis and solar lentigines are destructive and are often associated with significant adverse events⁽⁶⁾. The present study is a trial to present a comparative study of different methods that could be used in treatment of both conditions.

In the present study, male patients who had solar keratosis were more than female patients (85.7% of group I, 71.4% of group II, and 100% of group III were males).

In our work, the ages of the patients ranged from 15 to 83 (63.3 ± 22.2) years. Two cases only were 15 years old and the rest of the patients were older. These two cases of solar keratosis at this young age are explained by that they have xeroderma pigmentosa.

In the present study, patients used topical 5-fluorouracil (5-FU) 5% cream showed erythema at the sites

of application throughout the 4 weeks of treatment. Inflammation was not reported in the first week of the treatment but it developed in the following 3 weeks. Lastly, erosions were observed in 6 patients only at the 3rd and 4th weeks of treatment. These effects of 5-FU persisted for another 2 to 3 weeks after discontinuation of treatment and subsided completely one to two weeks later. These findings are more or less in agreement with Lawrence et al., (1995)⁽⁷⁾ who found the previously mentioned effects of 5-FU in all of their patients throughout the period of treatment (3 weeks) and persisted for another 2 to 3 weeks.

Pruritus and burning sensation appeared as expected effects of use of topical 5-FU 5%. This is in agreement with some authors^(7,2) One patient (14.3%), in the present study, showed photosensitivity and postinflammatory hyperpigmentation in the treated areas. This may be explained by that the patient exposed to direct sunlight after application of 5-FU cream.

Complete disappearance of treat-

ed solar keratoses was reported about one month after the end of treatment in 6 patients (85.7%) in our work with no recurrence of any of treated lesions till the end of the 6 months follow-up period. This is in agreement with the results of Lawrence et al., (1995)⁽⁷⁾. On the other hand, failure of therapy occurs in one patient. This can be explained by that this patient did not reach the stage of erosion during treatment due to non compliance. Dinehart (2000)⁽²⁾ stated that all patients undergoing successful treatment exhibit erythema, inflammation, and erosion and if the patient is not able to reach the end point of erosion, the cure rate drops dramatically.

Cryosurgery was the second modality used in the present study. Pain appeared in four patients. It was of mild or moderate intensity and disappeared within 2 to 10 hours after the procedure. Pain is due to ischemia and tissue damage caused by freezing^(8,9). Oedema appeared in one patient 8 hours after the procedure and disappeared in one week later. Small bullae appeared at the sites of the treated solar keratoses 24-48 hours

after cryosurgery in all patients.

This sequel of events after cryosurgery is well accepted according to the clinical-physical course of the skin cryosurgery described by some authors^(10,11,12).

We reported infection in only one patient of group II who treated with cryosurgery. It may occur due to improper timing of freezing duration which led to increased tissue destruction and necrosis that facilitated infection and also, improper care of the cryosurgical wound due to low compliance of the patient. The same patient who developed infection before had atrophic scar as a permanent complication in the same site. It could be assumed that infection left this scar after its subsidence.

Two patients (28.6%) developed permanent hypopigmentation after cryosurgery in our work. It is due to the fact that melanocytes are more susceptible to damage from freezing than keratinocytes⁽¹¹⁾. This is considered more or less in agreement with Chiarello (2000) and Gage and Meedagham^(14,15) (1979). On the other

hand, transient hypopigmentation was reported in one patient during our work. It appeared by the end of 1st month of follow-up and disappeared by the end of 2nd month. Repigmentation may be explained by migration of melanocytes from the margins or from undamaged melanocytes in hair follicles⁽¹⁶⁾. Complete disappearance of all solar keratoses treated with cryosurgery was observed by the end of 1st month of follow-up with no recurrence of any treated lesion till the end of 6 months follow-up period. This is supported by cure rate reported by Lubritz and Smolewski (1982)⁽¹⁷⁾ which was 98.8%.

Dermabrasion is a controlled removal of epidermis and the superficial dermal layers while preserving sufficient epidermal adnexa to allow for spontaneous re-epithelialization without scarring⁽¹⁸⁾. Actually, the sensation of patients during dermabrasion sittings varied from one patient to another. It was obvious that the pain sensation could be correlated to the duration of the sitting and hence the depth of abrasion and to the pain threshold of the treated patients. This

can be interpreted by the deeper levels reached by the application of dermabrasion for longer periods with the exposure of more nerve ending. Five patients of this group experienced no discomfort. However, one patient experienced mild pain and another one showed moderate pain inspite of usage of local anesthesia before the dermabrasion. This pain can be cleared by giving addition dosage of local anesthesia.

Crusts appeared over the dermabrasion induced erosions and they separated 2 weeks after the procedure. Healing was completed in 3 weeks and we used open dressing technique for the care of erosions occurred after dermabrasion. This is in agreement with Walker et al., (1998)⁽¹⁹⁾ who noticed that healing was usually completed within 3 weeks, particularly if the wound left open and dry. The only complication of dermabrasion reported in our study was erythema. It was temporary in 4 patients and persisted till the end of the study in one patient. This is in agreement with the experience of many authors^(20,21,22). Persisted erythema in our study was due to premature exposure

to sunlight due to non-compliance of the patient as he did not follow the instructions to avoid premature sun exposure. Erythema may disappear after 6 months. There was complete disappearance of the lesions from all patients after one month. Then by the 2nd months, one patient showed recurrence of a treated lesion and persist till the end of the study. This recurrence may be due to incomplete removal of the lesion as some diseased cells may persist which can not be detected by naked eye.

Solar lentigines: are benign lesions. Association with SCC and melanocytic malignant melanoma probably is coincidental in actinically damaged skin. Solar lentigo does not undergo malignant transformation, but they are cosmetically important for some patients who seek for treatment of these lesions^(23,24). Accordingly, a safe and effective method of treatment should be searched for. There was no controlled comparative study to compare these different modalities.

In the present study female patients were more than male patients.

This may be referred to that females are more interested in treating the solar lentigines than males as they always search for better cosmetic appearance. The ages of the patients in the present work ranged from 40 to 75 (56.6 ± 12.4) years.

While persons in rural areas exposed to sun more than those in urban areas and as the duration and intensity of solar exposure is directly related to the appearance of lentigines⁽³⁾, the number of patients from rural areas was expected to be more than the number of patients from urban area. However, we found that both number were equal in our study. This could be explained by that urban patients are more oriented by these lesions and are interesting in treatment of solar lentigines than rural patients due to the difference of social circumstances.

Six patients were of skin phototype III and ten patients were of type IV. This is more or less goes hand in hand with Mackie (1998b) and Hexsel et al. (2000)^(3,25) who mentioned that solar lentigines are more common in phototype II, III or IV.

Topical tretinoin is a potent inhibitor of new melanin production and it was suggested that topical tretinoin may decrease macular hyperpigmentation of solar lentigines⁽²⁶⁾. In the present study, topical tretinoin 0.05% cream was used for treatment of solar lentigines of the back of hands of the patients. There was clinically and statistically significant hypopigmentation of the macular hyperpigmentation of solar lentigines one month after the initiation of treatment. This hypopigmentation appeared in 87.5% of our patients but one patient (12.5%) showed failure of therapy with no change in color of the treated lesions. This is in agreement with Rafal et al., (1992)⁽²⁶⁾. This failure can be explained by noncompliance of the patient due to incorrect perception of mild scaling, that appeared in the first two weeks of therapy, as a side effect. Also, the relatively long duration of therapy and follow-up (about 6 months) may share in this noncompliance of the patient. This is in agreement with previous studies^(26,27,28).

In the present study, after application of topical tretinoin, scaling appeared in 87.5% of patients and ery-

thema appeared in 12.5% of patients. It should be noticed that one patient developed both scaling and erythema. One patient did not develop any reaction except mild scaling in first 2 weeks of treatment and this is the patient who showed failure of therapy. Erythema and scaling of skin appeared two weeks after start of treatment and they were most noticeable during first two months of treatment, after which there was a progressive decrease in their severity, frequency, and duration. This is in agreement with Glichrest (1992)⁽²⁸⁾ who suggested that presence of this cutaneous reaction may be useful to determine whether a patient was receiving topical tretinoin treatment or not. It should be noted that none of the patients in the present work had adverse reactions that were severe or permanent. This is supported by Weiss et al., (1988) and others^(26,27,29,30).

Cryotherapy and localized dermabrasion were used for treatment of solar lentigines in the present study. Both methods were conducted on the same patient, cryotherapy on solar lentigines on the back of right hand

and localized dermabrasion on the back of left hand. This was done to compare between both methods in a good and correct manner as each hand act as a control for the other.

In the present study, the time required to perform cryotherapy (1 - 2.5min) was significantly less than the time required to perform localized dermabrasion (2 - 5min) and the sensation during the procedure was more painful with cryotherapy. This goes hand in hand with Hexsel et al. (2000)⁽²⁵⁾ who reported the same result in their study.

Regarding side effects of both procedures serous crusts and erosions were significantly more with localized dermabrasion, however, blisters were significantly more with cryotherapy. These results goes hand in hand with that reported in a study carried out by Hezsel et al., (2000)⁽²⁵⁾.

Regarding the rest of complications, erythema was more with localized dermabrasion and persisted for one month. Erythema following cryotherapy while it was less than with localized dermabrasion, it persisted for

two months. This is in agreement with Hexsel et al., (2000)⁽²⁵⁾. The number of patients had swelling following each procedure used was nearly the same. Swelling appeared one day after the procedure and was not noticed by the 2nd visit of follow-up one week later. This result is supported by the experiences of some authors Orentreich and Orentreich (1998)⁽²²⁾ and Zouboulis (1998) ⁽¹⁰⁾.

In this study, pain appeared in one patient in only lesions treated with cryotherapy 8 days postoperatively. Then disappeared by the next follow-up visit one week later. Brown crust appeared more with cryotherapy 8 days postoperatively and disappeared one week later. These results are supported by results of the study of Hexsel et al., (2000)⁽²⁵⁾.

Bacterial skin infection appeared more with dermabrasion, in the present study (25% with dermabrasion and 12.5% with cryotherapy). It disappeared 2 weeks later in case of dermabrasion and one week later in case of cryotherapy. In the experience of Yarborough (1993) and Padilla (1994)^(31,32), bacterial infections

following cryotherapy. on the other hand Graham, (1999)⁽¹⁶⁾ suggested that the incidence of infection following freezing is very low, probably due to destruction of skin flora and maintenance of the basement membrane. This controversy may be explained by non-compliance of the patient to use topical antibiotic ointment after the procedures and bad hygiene and health morals of the patient.

Healing with bad scar was noticed in two lesions treated with localized dermabrasion and in one patient treated with cryotherapy in the present work. This agrees with Holt (1988) and Zouboulis (1998) and Koranda (1989)^(10,33,34) who reported scarring as a permanent complication of cryosurgery and disagrees with Hexsel et al., (2000)⁽²⁵⁾ who reported no scar in their study. The cause of scarring following cryotherapy or localized dermabrasion is unknown, but the patient's genetic background, the depth of dermabrasion, the depth of freezing, and the anatomic site, are possible causes.

In the present study, and in agreement with Hexsel et al., (2000)⁽²⁵⁾ hy-

perpigmentation of treated area was considered as recurrence. The recurrences were early (started by the end of first month postoperatively) and frequent (as they occurred in 50% of cases), and occurred in both procedures in the same percentages. They are probably related to continuous sun exposure without photoprotection.

CONCLUSION

For treatment of the solar keratosis, cryosurgery may be more favorable because it is considered the most effective treatment modality with cure rate 100%, absence of recurrence and most of its complications are tolerable and treatable. Also, dermabrasion proved that it can be a good alternative for cryosurgery with expert hands and when facilities are available. On the other hand, topical 5-FU is a good treatment for solar keratosis but it needs special type of patients who has multiple lesions, compliant and accepts relatively long term of treatment.

As regard treatment of solar lentigines, localized dermabrasion and cryotherapy carried better results

than topical tretinoin as they led to complete disappearance of the treated solar lentigines. Although, both are considered invasive methods and recurrence rate was the same with each procedure (50%), cryotherapy may be more preferable. Its technique is simple, needs little time, needs no anesthesia, outpatient procedure, and economic. It has little temporary side effects and permanent complications were similar to that of localized dermabrasion and both were not dangerous. However, cryotherapy is more painful but it is usually transient. Localized dermabrasion needs special preparation e.g. theater, operative suits, and relatively expensive devices. The complications of the procedure were more severe than that of cryotherapy especially infection, serous crusts and erosions while blisters were significantly more with cryotherapy.

Topical tretinoin 0.05% cream is a non-invasive method to induce just lightening of the treated solar lentigines in a safe and quite manner. It is preferable for patients who do not want to undergo invasive maneuvers and get satisfaction from just lighten-

ing of the treated solar lentigines. Both solar keratosis and lentigines treatment must be individualized to obtain optimal result.

REFERENCES

1. **Mackie, R.M. (1998a)** : Epidermal skin tumors. In: Rook Textbook of Dermatology. Eds. Champion, R.H.; Burton, J.L.; Burnser, D.A. and Breathnach, S.M. Blackwell scientific publ. London Boston Paris. Sixth edn. Vol 4, 1670-71.
2. **Dinehart, S.M. (2000)** : The treatment of actinic keratoses. J. Am. Acad. Dermatol., 42:1 Pt. 2, 25-8.
3. **Mackie, R.M. (1998b)** : Melanocytic naevi and malignant melanoma. In: Rook Textbook of Dermatology. Eds. Champion, R.H.; Burton, J.L.; Burnser, D.A. and Breathnach, S.M. Blackwell scientific publ. London Boston Paris. Sixth edn. Vol 4., 1719-20.

4. **Rhodes, A.R. (1999)** : Benign neoplasias and hyperplasias of melanocytes. In: *Dermatology in General Medicine*. Eds. Fitzpatrick, T.B.; Freedberg, I.M.; Eisen, A.Z.; Wolff, K.; Austen, K.F.; Goldsmith, L. A. and Katz, S.I. McGraw-Hill Book Company. New York, St. Louis, San Francisco. Fifth edn., Vol 1, 1047-1059.
5. **Naganumaa, M.; Yagi, E. and Fukuda, M. (2001)** : Delayed induction of pigmented spots on UVB-irradiated hairless mice. *J. Dermatol. Sci.*, 25 (1): 29-35.
6. **Rivers, J.K.; Arlette, J.; Shear, N; Guenther, L.; Care, W. and Poulin, Y. (2002)** : Topical treatment of actinic keratoses with 3.0% diclofenac in 2.5% hyaluronan gel. *Br. J. Dermatol.*, 146 (1) : 94-100.
7. **Lawrence, N.; Cox, S.E.; Cockrell, C.J.; Freeman, R.G. and Cruz, P.D. (1995)** : A Comparison of the efficacy and safety of Jessner's solution and 35% trichloroacetic acid vs 5% fluorouracil in the treatment of widespread facial actinic keratoses. *Arch. Dermatol.*, 131: 2, 176-81.
8. **Zacarian, S.A.; Stone, B. and Clater M. (1970)** : Effects of cryogenic temperatures on microcirculation in the golden hamster cheek pouch. *Cryobiology*, 7: 27-39.
9. **LeFebvre, J. and Folke, L. (1975)** : Effects of subzero temperatures on the microcirculation in oral mucous membrane. *Microvasc. Res.*, 10: 360-72.
10. **Zouboulis, C.C. (1998)** : Cryosurgery in dermatology. *Eur. J. Dermatol.*, 8: 7, 466-74.
11. **Ascensao, A.C. and Gancalves, J.C.A. (1986)** : Cryosurgery of basal cell carcinoma. *Skin Cancer*, 2: 125-36.

12. **Dawber, R.P.R.; Colver, G. and Jackson, A. (1994)** : Solar keratosis. In: Dawber, R.; Colver, G. and Jackson, A.; eds. Cutaneous cryosurgery. Principles and clinical practice. Reprint of first edn. Martin Duntiz Ltd., London, P. 82.
13. **Zacarian, S.A. (1985)** : Cryogenics: the cryolesion and the pathogenesis of cryonecrosis. In: Cryosurgery for skin cancer and cutaneous disorders. St. Louis: C.V. Mosby, 1-30.
14. **Chiarello, S.E. (2000)** : Cryopeeling (extensive cryosurgery) for treatment of actinic keratoses: an update and comparison. *Dermatol. Surg.*, 26: 8, 728-32.
15. **Gage, A.A. and Meenaghan, M. (1979)** : Sensitivity of pigmented mucosa and pigmented cells in skin due to freezing injury. *Cryobiology*, 16: 348-61.
16. **Graham, G.F. (1999)** : Cryosurgery. In: *Dermatology in General Medicine*. Eds. Fitzpatrick, T.B.; Freedberg, I.M.; Eisen, A.Z.; Wolff, K.; Austen, K.F.; Goldsmith, L.A. and Katz, S.I. McGraw-Hill Book Company. New York, St. Louis, San Francisco. Fifth edn., Vol 2, 2980-86.
17. **Lubritz, R.R. and Smolewski, S.A. (1982)** : Cryosurgery cure rate of actinic keratoses. *J. Am. Acad. Dermatol.*, 7: 631-2.
18. **Hugo (1978)** : Videotape discussion of dermabrasion procedure. In: *Symposium on surgery of the aging face*. Edited by D. Goulion and E.H. Courtiss. The C.V. Mosby Company, St. Louis, P. 190.
19. **Walker, N.P.J.; Lawrence, C.M. and Dawber, R.P.R. (1998)** : Dermatologic surgery. In: *Rook Textbook of Dermatology*. Eds. Champion, R.H.; Burton, J.L.; Burnser, D.A.

- and Breathnach, S.M. Blackwell scientific publ. London Boston Paris. Sixth edn. Vol. 8, p.3624.
20. Epstein, E. (1962) : Dermabrasion. In: Skin surgery 2nd edn., Henry Kimpton, London, P: 243.
21. Orentreich, D.S. and Orentreich, N. (1987) : Acne scar revision updated. J. Dermatol. Clin., 5: 359.
22. Orentreich, N, and Orentreich, D.S. (1998) : Dermabrasion. As a complement to dermatology. Clin. Plast. Surg., 25(1): 63-80.
23. Roewert, H.J. and Ackerman, A.B. (1992) : Large-cell acanthoma is a solar lentigo. Am. J. Dermatopathol., 14: 2, 122-32.
24. Todd, M.M.; Rollis. T.M.; Gervels, J.W. and Hata, T.R. (2000) : A comparison of 3 lasers and liquid nitrogen in the treatment of solar lentigines. Arch. Dermatol., 136: 7, 841-6.
25. Hexsel, D.M.; Mazzuco, R.; Bohn, J.; Borges, J. and Gabbato, D.O. (2000) : Clinical comparative study between cryotherapy and local dermabrasion for treatment of solar lentigo on the back of the hands. Dermatol. Surg, 26: 5; 457-62.
26. Rafal, E.S.; Griffiths, C.E.M.; Ditre, C.M.; Finkel, L.J.; Hamilton, T.A. and Ellis, C.N. (1992) : Topical tretinoin (retinoic acid) treatment for liver spots associated with photodamage. N. Engl. J. Med., 326: 368-74.
27. Kligman, L.H. and Kligman, A.M. (1981) : Lack of enhancement of experimental photo-carcinogenesis by topical retinoic acid. Arch. Dermatol. Res., 27: 453-462.
28. Gilchrest, B.A. (1992) : Reti-

- 356 EVALUATION OF CERTAIN THERAPEUTIC MODALITIES etc..
- noids and photodamage.
Br. J. Dermatol., 127,
Suppl. 41: 14-20.
29. Weiss, J.S.; Ellis, C.N. ; Headington, J.T.; Tincoff, T.; Hamilton, T.A. and Voorhees, J.J. (1988) : Topical tretinoin improves photo-damaged skin: a double-blind vehicle-controlled study. J.A.M.A., 259: 527-32.
30. Ellis, C.N.; Weiss, J.S.; Hamilton, T.A.; Headington, J.T.; Zelickson, A.S. and Voorhees, J.J. (1990) : Sustained improvement with prolonged topical tretinoin (retinoic acid) for photoaged skin. J. Am. Acad. Dermatol., 23: 629-37.
31. Yarborough, J.M. (1993) : Dermabrasion. In: Dermatology. Edited by S.L. Moschella and H. J. Hurley. 3rd edition, Vol. IV, WB Saunders Company, Philadelphia, London, Toronto, P. 2478.
32. Padilla, R.S. (1994) : Dermabrasion. In: Wheeland, R.G., ed. Cutaneous Surgery, Philadelphia, W.B. Saunders, 479-90.
33. Holt, P. (1988) : Cryotherapy for skin cancer: results over a 5-year period using liquid nitrogen spray cryotherapy. Br. J. Dermatol., 119: 231.
34. Koranda, F.C. (1989) : Dermabrasion. In: Facial scars incision, revision & camouflage. Edited by J.R. Thomas and G.R. Holt. The C.V. Mosby Company. St. Louis, P. 133.