

MORPHOLOGICAL FEATURES OF THE STAPEDIUS MUSCLE IN MAN

By

Thomas J Haberkamp, MD
and Alaa A. Abou-Bieh*, MD

From

Department of Otolaryngology, University of Illinois, Chicago,
Illinois and Department of Otolaryngology, Faculty of Medicine,
Mansoura University, Mansoura, Egypt*

ABSTRACT

Objectives : The aim of this study is to review the gross anatomy and variations of the stapedius muscle and its relations to the structures forming the retrotympenic area. In addition, this study will try to present a theory to explain the reason for these variations from a developmental point of view.

Subjects and Methods : Thirty-five temporal bones were dissected, and studied utilizing a microscope and otoendoscopes. The muscle gross anatomy and its relations were studied.

Results : Marked variations in the origin and size of the muscle, the

course of its bony canal and its relation to the facial nerve canal were detected. These were mainly influenced by the sinus tympani development. These variations affected the length of the tendon and the pyramidal eminence. The presence of ectopic muscle bundles was confirmed in one specimen.

Conclusion : The stapedius muscle anatomy can vary significantly from one temporal bone to another. In some situations, these variations can be of surgical importance worth enough to be recognized.

INTRODUCTION

Recent advances in otologic surgical procedures, particularly endosco-

py require the need for more detailed knowledge of the components of the posterior mesotympanum and retrotympanic areas. The stapedius muscle is one of the structures, which can be frequently encountered during many surgical procedures in this area.

In most literature, the stapedius muscle complex is described as formed of a fusiform body, which is a mixture of striated and nonstriated fibers that converge into a tendon. The muscle lies in a bony sulcus or canal adjacent to the facial canal in the posterior wall of the tympanic cavity. Its tendon emerges from the orifice of the pyramidal eminence into the tympanic cavity to attach variably to the head and / or posterior crus of the stapes ¹. Some authors have highlighted the gross anatomical variations of the stapedius muscle especially in its relation to the facial nerve canal ^{2, 3}.

This work aims to provide a more detailed study of the variations in the gross anatomical features of the stapedius muscle and its relations to the surrounding structures, specifically

the facial nerve canal and the various retrotympanic recesses. In addition, we will try to explain these variations from a developmental point of view.

METHODS

The gross anatomy and anatomical variations of posterior mesotympanum and retrotympanic areas including the stapedius muscle and facial nerve canal were studied in 35 Fresh frozen temporal bones. To best of our knowledge, all bones came from adult cadavers. There were 21 right temporal bones and 14 left. All bones were dissected by the same approach and all were studied utilizing an operating microscope and otoendoscopes with 0°, 30° and 70° angles and 2.7 and 3 mm diameters. The photos were processed digitally by Photoswit® digital computer photo-system (Photoswit, USA). Measurements were taken by the use of paparella Fenestrometer (Gyrus®, USA).

The muscle complex anatomy was studied on serial steps, to accurately and completely study the Stapedius muscle complex and to preserve the relations to surrounding structures as

much as possible. The first step was to observe and measure the gross structure including the tendon, the pyramidal eminence and the bony canal. Next, the site of the tendon insertion to the stapes was noted. Then, the relations of the muscle complex to the surrounding structures were observed, these including the facial nerve canal, the sinus tympani, the posterior tympanic sinus, the facial recess and the lateral tympanic sinus. Also, the various eminences and ridges crossing near the muscle complex were studied. In a following step, both bony canals around the stapedius muscle and facial nerve were removed partially to observe their contents and their relations to each other with direct measures of the muscle. Finally, the muscle shape, origin and full course were noted together with whether the muscle was separated from the nerve or not.

Results

In all of the 35 specimens the muscular complex consisted of 3 segments (from distal to proximal), the free tendon, the pyramidal portion (both muscle and tendon) and the muscular bony canal. It was only pos-

sible to see the muscle bony canal partially by using the operating microscope. It became possible to examine the whole bony canal length only by using the 30° otoendoscope. It was reexamined again after removal of the bony covering of the muscle canal.

The Length of each individual segment was taken. There were marked variations in lengths of each of the three parts. The longest tendon in all specimens was 5 mm and the shortest on was 1 mm with mean 3. the pyramidal eminence varied in length between 7 mm and 2 mm with mean 4.7. The bony canal length was between 11 mm and 2 mm with mean 4. When the retrotympanic area was well aerated the ratio of the 3 segments was generally preserved with a ratio of 1 for tendon to 1.5 for pyramidal eminence to 1.3 for the bony canal.

The tendon shape usually was uniform cylindrical with slight tapering toward the insertion in the stapes. Except for 2 bones, the tendon direction was straight with slight tilting from distal to proximal. For the other two

bones, one bone the tendon was remarkably tilted in the usual direction and the other bone the tendon reversed its tilting direction into the proximal to distal manner. This was mainly due to the fact that relatively large sinus tympani pushed the entire muscle complex superior and lateral. The pyramidal eminence varied in shape from cylindrical in bones with a well-developed and well-pneumatized retrotympenic area to pyramidal in less developed bones. Its direction, which depended mainly on the sinus tympani pneumatization, was usually pointing forward or forward and downward in bones with large sinuses tympani. The bony canal was fusiform in shape in most of bones. Only in two bones, the canal took a tube like shape. The canal was dehiscent externally in 2 specimens. This dehiscence was partial and towards the sinus tympani alone in 1 specimen and toward the sinus tympani and the middle ear cavity in the other specimen.

One must be careful to remove mucosal folds from the tendon when studying the attachments since they may obscure the anatomy. The actual

tendon attachment was to the stapes head alone in 25 specimens and to the stapes head and posterior crus in 4 specimens. The tendon was attached to stapes head and sent a small muscular twig to attach in the posterior crus, or there was a hole near its end, in 4 specimens. The tendon was attached to the posterior crus only in 1 specimen and it was attached to the stapes head and posterior crus as well as the long process of incus in another specimen.

The bony canal directions together with its relations to the surroundings are the mainstay this research work was based on. Grossly the canal directions were influenced by two main factors; its relation to the facial nerve canal and the size and development of the sinus tympani. In the temporal bones with well-developed and well-pneumatized retrotympenic area, the canal took one of two directions. First was a slightly curved direction with distal end pointing forward and parallel to the tympanic segment of the facial nerve and the proximal end pointing backward and downward and parallel to or approaching the medial aspect of the mastoid (vertical) seg-

ment of the facial nerve and just below its 2nd genu. In both directions, the canal occupied the superolateral aspect of the sinus tympani. On the other hand, in temporal bone specimens with less or poorly-developed and less or poorly-pneumatized retrotympanic area, the canal was in straight, parallel to the tympanic segment of the facial nerve and at right angles to mastoid segment. In these specimens, the canal was superior, anterior and lateral to the tympanic orifice of the sinus tympani, i.e. outside it or with limited posterior extension to come inside the superior part of the sinus tympani.

As usual, the various bony ridges that define the retrotympanic spaces crossed the posterior tympanic wall. Nevertheless, the relations between these ridges and the pyramidal eminence and bony canal parts of the stapedius muscle complex varied. These variations were influenced by the development and pneumatization of the retrotympanic area (mainly of the sinus tympani). Usually the ponticulus extends as a ridge from the medial aspect of the pyramidal eminence to the promontory immediately

below the oval window niche to separate the posterior tympanic sinus superiorly from the sinus tympani inferiorly. In 7 specimens the sinus tympani was very large, subsequently the ponticulus formed a true bridge rather than a ridge between the posterior tympanic sinus above and the sinus tympani below. As a result the muscle bony canal encroached the lateral aspect of most of the posterior tympanic sinus and the upper part of the sinus tympani. In all other specimens, the posterior tympanic sinus was superior and medial to the muscle which did not form any part of the wall of the sinus.

The facial recess relations to stapedius muscle differed when studied, first from within the middle ear cavity, then after partial removal of the posterior canal wall. From within the middle ear cavity, the facial recess appeared to be superior and lateral to the muscle. In all bones with large sinus tympani, the recess formed the superior boundaries of the pyramidal eminence and the muscle bony canal. The pyramidal crest should run as a ridge superiorly from the styloid eminence to the pyramidal eminence,

then to the lower edge of the facial recess and turn up to the superior edge of the recess to end there superior to the level of the chordal eminence. When the sinus tympani was very large it stopped at the level of pyramidal eminence and turned anterior to end just proximal to the tendon exit.

This relationship was not applicable to the lateral sinus, as it is shallow and non-pneumatized so its relations to other structures are more or less fixed. After partial removal of the posterior canal wall, the facial recess appeared also to extend posteriorly and slight medially to the proximal end of the muscle. These changes in the pneumatization and development of both facial recess and sinus tympani also influenced the last of the styloid complex eminences, the chordal eminence, and the chordal crest (or ridge) between it and the pyramidal eminence. In very well pneumatized specimens there was an anticlockwise rotation of all the lateral structures of the styloid complex to bring them medial while bringing the medial structures to a more lateral position. Thus the chordal eminence became in more inferior position. The chordal

crest was shorted and ridging from lateral and inferior to medial and superior to join the pyramidal eminence.

For more data collection, both bony canals around the stapedius muscle and facial nerve were removed partially. There was no bony separation between the body of the muscle and the facial nerve (i.e. lying together in one bony canal) in 2 specimens. Then the origin of the muscle was observed to come directly from the walls of the bony canal in all specimens. In 9 bones the muscle was only attached to the anterior and lateral walls of the canal (the walls not related to facial nerve). In the 2 bones with deficient separation from the facial nerve, there was thick connecting tissue between the muscle and nerve. The exact place where the muscle fibers were converted (grossly) into tendon was the distal (anterior) end (summit) of the pyramidal eminence in all specimens. The muscle itself inside the canal was fusiform in shape in all specimens.

It is also worth noting the muscle course and length inside the bony canal. In 11 of the bones, especially

those bones with good development, the muscle course and length inside the bony canal significantly differed than what observed before opening the bony canal. In 7 bones, the muscle occupied only the distal two thirds of the bony canal and the proximal third was filled by thick fibrous tissue in 4 bones and was obliterated by bone in the other 3 specimens. In these bones, the muscle length was shorter 1- 2 mm than what it was externally apparent. In another 4 bones, the body of the muscle exceeded the bony canal cavity by 1 - 2 mm from the proximal side, either to come into direct contact with the facial nerve canal in 1 specimen or to lie inside an air cell of the retrofacial mastoid air cells. In all specimens, the muscle course was straight inside the canal, it did not take a curved course in any bone.

The relations between the facial nerve and the muscle could be classified into five categories: 1) the muscle

was completely anterior to the facial nerve (2 bones), 2) the muscle was anterior and extended laterally to the facial nerve (2 bones), 3) the muscle was anterior and extended medially to the facial nerve (13 bones), 4) the muscle was anterior, extended laterally and then posterior to the facial nerve (1 bone), 5) the muscle was anterior, extended medially and then posterior to the facial nerve (17 bones). In all the specimens with muscle extension posterior to the facial nerve, the muscle was laying directly anterior to the posterior semicircular canal and inferior to the lateral semicircular canal (wedged between the nerve and the canals).

In one specimen, when the muscle extended medially and posterior to the facial nerve, a small muscle condensation (1 mm x 2 mm) could be seen away from the posterior end and completely isolated inside bone. We thought this to be ectopic muscle tissue and this proved histologically to be muscle tissue.

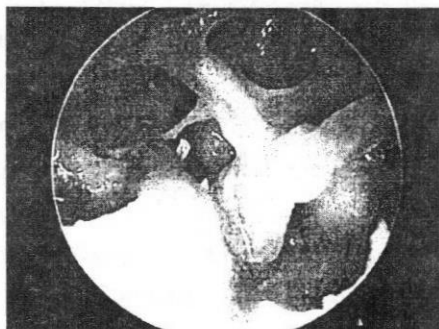


Fig 1: Left ear (70 degree otoendoscope) showing the relation of Stapedius muscle to the Sinus Tympani.

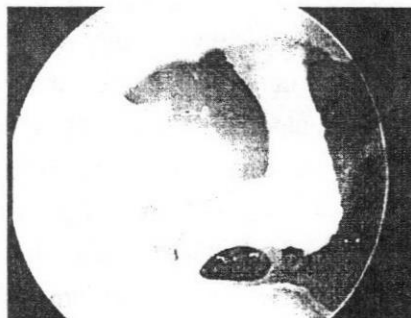

Fig 2 : Right ear (30 degree otoendoscope) showing the relation of Stapedius muscle to the Tympanic segment of the Facial nerve canal.

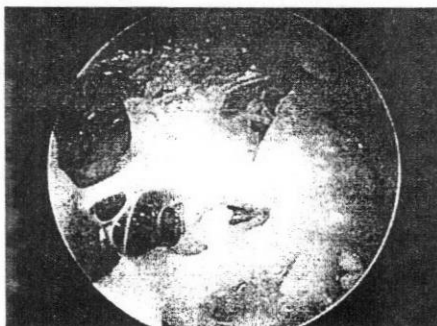


Fig 3: Left ear (30 degree otoendoscope) showing the relation of Stapedius muscle to the Mastoid segment of the Facial nerve canal.

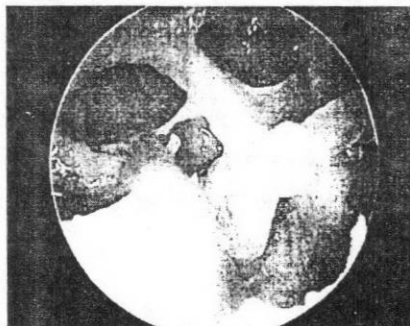


Fig 4: Right ear (30 degree otoendoscope), Panoramic view, showing the relations of Stapedius muscle to the structures of the retrotympanic area.

DISCUSSION

Although there are many variations in the gross morphology of the stapedius muscle, its relations to the surrounding structures and the patterns of the arrangement of the anatomical landmarks of the posterior mesotympanum and retrotympanic area, all these variations appear to have fairly predictable patterns. These variations can be explained by the generally accepted and popular theories of the middle ear development. Embryologically there is more than one element sharing in the complex formation of the retrotympanic area. In addition, postnatal development plays an important role in the completion of this process.

The posterior bony wall of the tympanum is derived from the second branchial arch, which contains Reichert's cartilage as its skeletal support. Reichert's cartilage extends up to the posterior aspect of the oval window, separated from both the cartilaginous labyrinth, and the cartilaginous annulus tympanicus by a narrow band of gelatinous material containing the primitive endothelium that is to line the future tympanum and its viscera

4. The upper club shaped part of the cartilage will form the stapes and the loose substance (usually known as interhyale). The lower; hyoid portion of the cartilage later develops into the stapedial muscle tendon. The muscle itself develops from blastema related to facial musculature. The isolated position of the muscle is due to development of the rapidly growing labyrinth capsule, the laterohyale and the proximal end of Reichert's cartilage (which ossifies to form the pyramidal eminence and bony muscular canal)5. The entire second arch structure, composed of cartilage and other arch mesodermal structures, can be referred to as the styloid complex 6.

Each branchial arch is supplied by a cranial nerve, which does not develop from the arch mesoderm but it arises from the neural tube and enters the respective arch to supply its musculature. The facial nerve is the cranial nerve that supplies the second arch. It courses on the posteromedial surface of the Reichert's cartilage 4. The complex course of the Facial nerve is a result of the development of the structures that surround it 7. The first genu may be considered the

result of the nerve being pushed forward by the developing otic capsule. Here the fallopian canal is derived from the mesoderm of the otic capsule. More distally, the fallopian canal is partly formed by Reichert's cartilage³. In the tenth week, the facial nerve makes its second genu in the middle ear, and its relationship to the external and middle ear structures is far anterior than in the adult. By week 26, there is partial closure of the fallopian canal by bone and the nerve has moved posteriorly, coming to lie in a position comparable to the adult. In a similar way to the nerve being pushed forward by the otic capsule more proximally, it is pulled posteriorly by the growing tympanic ring and structures of the posterior tympanum and pulled inferiorly by the developing meatus and mastoid system. The facial nerve comes to lie, therefore, between the tympanic and mastoid portions of the temporal bone. Even at birth, the nerve exits through the superficially positioned stylomastoid foramen and only comes to its more medial adult position with postnatal mastoid tip development.⁷

Another element takes part in the

process of formation of the retrotympanic spaces is the passage of the endothelial pouches of the primitive eustachian tube (sacculi) to develop the middle ear air cell system. Sacculus medius, leaves the mesotympanum via the anterior tympanic isthmus to extend posterior and forms the attic, and goes into the pars petrosal portion of the mastoid. Sacculus superior, ascends over the styloid complex (pyramidal eminence, styloid eminence, and chordal eminence) and through the posterior tympanic isthmus to form the antrum and squamosal portion of the mastoid. The facial sinus, descends behind the chordal ridge and drops downward on the lateral aspect of the facial canal. Sacculus posticus, forms the hypotympanum, round window niche, sinus tympani, and inferior half of oval window niche. Sacculus anticus may form the supratubal recess⁸.

After birth and during childhood, the neck grows at a more rapid pace compared to the skull, so that the inferior portion of the drum rotates outward, enlarging the hypotympanum while the mastoid is pulled down and out by the growth of the sternomas-

toid muscle. This growth pattern facilitates the expansion into the middle ear cleft of the endothelial-lined pouch originating from the primitive eustachian tube⁴. Now the stylomastoid foramen takes its final adult position, which is attained by growth of the mastoid tip⁷.

In adulthood the ridges of the posterior tympanum which always cross the floor of the hypotympanum from a medial to a lateral position and bony bridges from the styloid complex to the promontory give evidence to the original developmental processes. The subiculum runs from the styloid eminence to the posterior lip of the round window niche, and the ponticulus, extends as a ridge or bridge from the pyramidal eminence to the promontory immediately below the oval window niche⁸.

The multifactorial development could be the explanation of the variations in the gross morphology of the stapedius muscle and its relations to the surrounding structures. Each of these factors depends on rate of its occurrence (time factor), occurrence progress (quantity factor), and occur-

rence pattern (quality factor) and as it is expected, these factors would not be fixed in every fetus or growing child and would vary from one to another.

The muscle, being in the upper proximal part of the Reichert's cartilage, while the facial nerve on the cartilage posteromedial side, so the relation between the muscle and nerve would be governed by the rate of development and the level to which the cartilage might approach and in turn push the facial nerve. This also would be modified by the force of downward and outward traction of the developing mastoid and neck on the stylomastoid foramen and annulus tympanicus. At the same time, the rate of developing saccus posterior pushing up the sinus tympani and saccus superior pushing the facial recess down and anterior would affect development.

When these factors are balanced that the retrotympanic area is arranged in the usual commonly described pattern¹. When one of these factors becomes predominant in its rate or pattern of development, this

would give the type and shape of gross variation. Based on these patterns of development, we found the anatomic relationships to generally be predictable and related. The five categories of the relations between the facial nerve and the muscle are best explained by this concept. When the muscle was completely anterior to the facial nerve, this was due to predominant traction of mastoid by the sterno-mastoid muscle rather than pushing by developing cartilage and saccus posterior. When the muscle was anterior and extended laterally to the facial nerve, the cartilage development of Richert's cartilage appeared to be the predominant factor in development. Cartilage development also was predominant when the muscle was anterior, and extended laterally and then posterior to the facial nerve, but here the traction was the least affecting factor. When the muscle was anterior and extended medially to the facial nerve, the mastoid traction and the saccus posterior development were predominant rather than the cartilage development and saccus superior development. When, the muscle was anterior, extended medially and then posterior to the facial nerve, indi-

cated that all the factors were generally evenly balanced. However, the relation between the muscle and the posterior tympanic recesses and facial recess respectively was depending in the extent of the saccus posterior and superior development after the full maturation of the cartilage and hence on the force of the mastoid traction.

The difference of the tendon site of insertion mostly due to the inter-hyale amount separates from the stapes primordium rather than any other developmental factor ⁵. This also could be the reason for the formation of ectopic muscle tissue in isolated extraordinary palces ⁵.

Some other variations depended mainly on the development of the Reichert's cartilage. The dehiscence of the muscle canal and the common canal enveloping the vertical segment of the facial nerve together with muscle, were results of the cartilage pattern of development ⁵. The vascular connective tissue lodging the muscle with the nerve ², which was present only in bones with deficient separation between nerve and muscle, sup-

port the theory of the mesodermal origin of the canal. The size of the pyramidal eminence, as a derivative of the styloid complex, depends on the cartilage development also. However, this could not explain the relation between the eminence and the tendon (interhyale origin) or the tendon length. Another factor also should be taken in consideration, which may affect the lengths of the structures derived from the proximal part of the cartilage, is the otic capsule sharing in the formation of the footplate of the stapes and the fixed position for oval window in the otic capsule ³.

CONCLUSION

The stapedius muscle anatomy can vary significantly from one temporal bone to another. In some situations, these variations can be of surgical importance worth enough to be recognized.

REFERENCES

1. **Gulya AJ. (2007)** : Gulya and Schuknecht's Anatomy of the Temporal Bone with Surgical Implications, 3rd ed. New York: Informa; p. 80 - 2.
2. **Goldenberg RA. (1983)** : Delineating the facial nerve from the stapedius muscle. *Laryngoscope*; 93: 1612 - 3.
3. **Donaldson JA, Duckert LG, Lambert PM, Rubel EW. (1992)** : Anson - Donaldson Surgical Anatomy of the Temporal Bone. New York: Raven Press. p. 53 - 6.
4. **Proctor B. (1989)** : Surgical Anatomy of the Ear and Temporal Bone. New York: Thieme Medical Publishers. p. 41 - 2.
5. **Strickland EM, Hanson JR, Anson BJ. (1962)** : Branchial sources of auditory ossicles in man. *Arch Otolaryngol*; 76: 100 - 22.
6. **Proctor B. (1969)** : Surgical anatomy of the posterior tympanum. *Ann Otol Rhinol Laryngol*; 78: 1026 - 41.
7. **Sataloff RT. (1990)** : Embryology of the facial nerve and its

clinical applications. Laryngoscope; 100: 969 - 84.

ment of the middle ear spaces and their surgical significance. J. Laryngol Otol 78: 631 - 48 .

8. Proctor B. (1964) : The develop-

الملخص العربي

يهدف هذا المقال الى دراسة التشريح والتغيرات الظاهرية للعضلة الركابية وعلاقتها بالتراكيب التي تكون منطقة الأذن المتوسطة الخلف وسطيه. كما يهدف هذا المقال الى الوصول الى نظرية توضح سبب هذه التغيرات في ضوء الأسباب النشئية.

وقد اجريت هذه الدراسة على ٣٥ عظمه صخريه تم تشريحها ودراستها باستخدام الميكروسكوب الجراحي والمناظير الضوئية الخاصة بالأذن الوسطى.

وقد لوحظ وجود اختلافات عديدة بالنسبة للتشريح الظاهري للعضلة الركابية وذلك بالنسبة لمنبت العضلة وحجمها ومسارها داخل القناة العظمية الخاصة بها. كما لوحظ اختلاف علاقة العضلة ومسارها بالنسبة لمسار العصب الوجهي السابع. وكانت هذه الاختلافات تتأثر أساسا بنسبة نمو الجيب الطبلى. مما أثر على طول وتر العضلة وشكل وحجم النتوء الهرمى. كما وجدت حزمات عضلية مهاجرة في احدى العينات.

وخلصت الدراسة الى انه نظرا للتباين الواضح في هذه التغيرات التشريحية عن النموذج المتوقع للعضلة من فرد الى الاخر فان هذه التغيرات ذات اهمية شديدة تستحق أن تأخذ في الاعتبار أثناء جراحات الأذن الوسطى والنتوء الحلمى.

