

AGE CHANGES OF THE LACRIMAL GLAND OF RABBITS (LIGHT AND ELECTRON MICROSCOPIC STUDIES)

By

Hassan El-Bana Abd El -Adle*, MOSTAFA EL-GIZAWI*,
Hosam Eldin Hessian*, MOSTAFA .A.Abou El-Naga**
AISayed Abd El-Rahman Abd El-Hady Mohamed**

From

**Department of Anatomy Faculty of Medicine, Al Azhar university.*

***Department of Anatomy Damietta Faculty of Medicine,
Alazhar University*

ABSTRACT

The dry eye in senile people is a major ophthalmologic problem; the aim of this work was to study the histological and histochemical changes with advancement of age in the lacrimal glands in rabbits, and correlating these changes with those, which might be detected at the ultra structural level.

Thirty healthy rabbits of both sexes were divided into three groups. Young age group (3-5 months), adult group (9-12 months), and senile group (24-36months). The lacrimal glands, of each animal, were dissected out, isolated and processed; par-

affin section stained with Hx&E., Mallory Trichrome and PAS stains. Fresh frozen cryocut section for localization of acid phosphatase enzyme activity were done. Epon embedded semithin sections stained with toluidine blue and ultra thin sections for Electron Microscopic study were prepared.

The rabbits has a dorsal lacrimal gland in the postero dorsal region of the eye ball, it is about 4mm in diameter, and Harderian gland lies in the antero ventral region of the eye ball, it is about 6mm in diameter. In young and adult age consists of tubulo acinar units separated by dense sheets

of connective tissue septae into lobules. The acini lined by cubical cells, rounded basal nuclei and basophilic cytoplasm. In senile rabbits, the lacrimal gland showed thickening of the periductal and perivascular connective tissue infiltration of inflammatory cells and degeneration of some lacrimal acini.

The harderian gland in young and adult rabbits consists of of tubulo acinar unit, divided into lobules by sheets of connective tissue. The acini composed of two types (type I and type II). type I had a narrow lumen, and their cells showed small vacuoles and rounded basal nuclei. The type II acini had a wider lumen, larger vacuoles, and rounded basal nuclei. In senile group the acini were closer, irregular in shape, showing outpocketing of the acinar cells. Perivascular and periductal cellular infiltration was noticed.

The lacrimal acinar cells in young and adult rabbits showed positive PAS reaction while they showed a weak positive reaction in senile ones. The acinar and ductal basement membrane of the acini and ducts were thickened and showed strong

positive PAS reaction in senile age groups.

The lacrimal gland showed an increase in the amount of the collagenous fibers in adult animal and more condensation of these fibers were noticed around ducts and blood vessels in senile gland.

The basal portions of the acinar cells, in young age showed strong positive acid phosphatase reaction while the remaining cytoplasm showed moderate positive reaction. The senile gland showed weak reaction in the acinar cells. The epithelial lining of the ducts in all age group showed strong positive acid phosphatase reaction.

By E/M Some of the lacrimal acinar cells appeared darker than the others. The acinar cells showed supra nuclear Golgi complex, mitochondria and numerous secretory granules. The gland showed increase of the mitochondria in young age, while in senile rabbits signs of degeneration of the mitochondria in the form of pyknosis of the nuclei, and appearance vacuoles in the cytoplasm was noticed.

Review of Literature

The aqueous component of the tear film is responsible for keeping the cornea buffered, lubricated, nourished and protected. It is produced and secreted from the lacrimal gland (Dilly, 1994). Dry eye in senile people is a major problem present in some diseases such as kerato-conjunctivitis sicca and Sjogren's syndrome . (Farrell J, Patel s, Grierson DG, and Sturrock RD, 2003).

Sullivan and Krenzer, (1999) reported that Precorneal tear film is a sheet of tears, which cover the exposed inter palpebral portions of the globe and cornea.

Dry eye syndrome such as, kerato conjunctivitis sicca, Sjogren's syndrome and dacry adenitis are big problem in old age. Most dry eye symptoms result from an abnormal, non lubricative ocular surface that increases shear forces under the eye lids, and diminishes the ability of the ocular surface to respond to environmental challenges. Michael, E ,Stern, ph, Roger, W and Beuerman, (1998).

Clao, (2000) included that the ocu-

lar surface of the eye and lacrimal gland function are tightly integrated unit. Dry eye conditions; damage the ocular surface, lead to further damage of lacrimal gland.

Sullivan, D.A, wickham LA, and Krenzer, (1997) and Azzarolo. et al, (1997), stated that the lacrimal gland function was significantly influenced by sex hormone. Androgens were showing to exert essential and specific effect on maintaining normal glandular function to suppress inflammation in normal and autoimmune animal models. Sullivan and Krenzer, (1999), included that androgen deficiency may promote the progression of Sjogren's syndrome and its associated lacrimal gland inflammation, Meibomian gland dysfunction, and severe dry eye.

Azzarolo, (2003), stated that lacrimal glandular atrophy was observed after ovariectomy, he suggested that in addition to androgen, estrogen also seem to play a role to maintain lacrimal gland structure and function.

Cornell-Bell, DA Sullivan, and MR Allansmith, (1985), stated that acinar

area in lacrimal glands of males was larger than that of females. These findings suggest that gender differences in lacrimal gland morphology may be a general phenomenon in a variety of species.

Evaporation of tears :

The evaporation rate is normally low because of protective oily layer; no more than 20-25% of the total tears secreted are lost by evaporation per day, remaining fluid is drained through the nasolacrimal duct into the nose. In the absence of the protective oily layer, the rate of evaporation is increased 10 to 20 times. The tonicity of human tears is subject to a dynamic change because of the evaporation process and rate of tear flow. The overall thickness of the tear film is about 4-9 μ m but the eye can manage up to 30mm without over flow., (Peifer, R.L and Petersen Jones, 1997).

Most dry-eye symptoms result from an abnormal, non lubricative ocular surface that increases tear forces under eyelids and diminishes the ability of the ocular surface to respond to environmental changes. This ocular-surface dysfunctions may result from

immuno-compromise persons due to systemic autoimmune disease, locally from a decrease in systemic androgen support to the lacrimal gland as seen in aging and most frequently in the menopausal female. (Stern, 1998).

The function of the lacrimal gland is significantly influenced by sex hormone (androgen). Androgen is shown to exert essential and specific effects on maintaining normal glandular functions and to suppress inflammation in normal and autoimmune animal models. As the activity of androgen in lacrimal gland is proposed to be attributed to its ability to induce the accumulation of anti-inflammatory cytokines. (Azzarolo, AM, Olsen, E and Huang, ZM, 1997).

Androgen deficiency may promote the progression of Sjogren's syndrome and its associated lacrimal gland inflammation, Meibomian gland dysfunction and severe dryness of the eye. (Sullivan and Krenzer, 1999).

Ovariectomy result in the decrease of the level of estrogen which

lead to necrotic change in the acinar cell and inflammatory response of the lacrimal gland by lymphocytic infiltration. This suggests that estrogen play a role to maintain lacrimal gland structure and function . (Elhusseni, H. M, 2003).

Kerato conjunctivitis sicca and dry eye is associated with reduced tear secretion and therefore a reduction in the effectiveness of lacrimal gland function. This have been seen to occur with increasing age. The difference between the young and aged rat glands include deposition of connective tissue, inflammatory cell infiltration, periductal fibrosis, acinar atrophy. Also morphological change of the acini which occur with age from serous to seromucous and then to mucous acini, resulting in a reduction in the presence of protein secretory granules. The mast cell increases with tissue damage. This explains the phenomenon of reduced tear secretion with ageing (Draper; et al 1997).

Lacrimal gland is the primary tissue involved in the secretory immune system of the eye. This system

serves as the first line of defense to protect the ocular surface against microbial agents and toxic compounds. So, it significantly limits the eye susceptibility to infection and allergic diseases and help to maintain both corneal and conjunctival integrity and visual function . (Sullivan and Sato, 1999).

Certain disease, such as Sjogren's syndrome (SS) results in secretory dysfunction of the lacrimal gland. There are progressive lymphatic proliferations which correlates with loss of secretory acini. (Yoshino;et.al 1996).

Decrease or even prevention of tear drainage by lacrimal occlusion is of great clinical benefit for patients suffering from dry eye syndrome. Itching, burning, foreign body sensation and light sensitivity are markedly improved following progressive lacrimal passage occlusion. (Nava-Castaneda; et al 2003).

Material and methods : Thirty healthy rabbits of both sexes were divided into three groups. Young age group (3-5 months), adult group (9-12

months), and senile group (24-36 months). The animal were killed by decapitation and lacrimal glands, of each animal, were dissected out, isolated and processed; paraffin sections stained with Hx&E, Mallory Trichrome stains and PAS reaction. Fresh frozen cryocut sections prepared for localization of acid phosphatase enzyme activity. Epon embedded semithin section stained with toluidine blue and ultra thin sections prepared for Electrone Microscopic study.

RESULTS

Light microscope study :

- 1) *In the first group (young age, 3-5 months) of rabbits.*

Dorsal lacrimal gland :

The dorsal lacrimal gland appeared to be consisted of small serous acini with narrow lumen, acinar cells were pyramidal in shape with rounded basal nuclei and granular basophilic cytoplasm (Fig, 1). Interlobular connective tissue contained ducts and blood vessels. The ducts had wide lumen rounded basal nuclei. (Fig, 2).

A minimal amount of positively

stained collagenous fibers were found mainly in the interlobular connective tissue around ducts and blood vessels. (Fig 3).

Strong positive PAS reactions was observed in the basement membrane of acini, duct cells, and cytoplasm of acinar cells (Fig 4).

Some acinar cells showed strong positive acid phosphatase reaction. and negative reaction in some interlobular and periacinar connective tissue (Fig 5).

Semithin sections of the dorsal lacrimal gland, showed acinar secretory cells were packed with secretory granules .some of the acini was stained darker than the others (Fig,6).

Harderian gland; The acini of the harderian gland were composed of two types of cells (type I and type II). In.type I cells the acini had a narrow lumen, their cells showed small sized vacuoles, and rounded basal nuclei. Type II cells had a wider lumen, their cells had larger vacuoles, rounded basal nuclei and less amount of cytoplasm (Fig 7). The interlobular con-

nective tissue contained ducts and blood vessels. The duct cells had central rounded nuclei (Fig 8). It showed moderate amount of positively stained collagenous fibers mainly in the interlobular connective tissue around the duct and blood vessels in type I acini (Figs. 9). Type II acini showed mild amount of collagenous fibers around the duct and blood vessels and negative collagenous fibers in the interlobular connective tissue (Figs.10).

The gland showed moderate positive PAS reaction in the basement membrane of acini, and cytoplasm of acinar cells (Fig 11).

Strong positive acid phosphatase reaction in some acinar cells. and negative reaction in some interlobular and periacinar connective tissue were observed (Fig, 12).

2) *In the second group (adult age, 9-12 months) of rabbits.*

Dorsal lacrimal gland ;

The lacrimal acini were apparently large in size they were lined by columnar cells with rounded basal nuclei and basophilic granular cyto-

plasm. Myoepithelial cells surrounding the acini (Fig 13).

Moderate amounts of positively stained collagenous fibers were laid around intra and interlobular connective tissue mainly around fibrous capsule, ducts and blood vessels (Fig.14).

The positive PAS reaction were seen in the peri acinar, interlobular connective tissue and acinar basement membrane with negative reaction in the acinar cells. (Fig 15).

Harderian gland;

Acini were apparently large in size, they were lined by columnar cells, and rounded basal nuclei and some acini lined by cuboidal cells with flattened basal nuclei. Interlobular duct has large lumen, lined by columnar cells with rounded nuclei Myoepithelial cells surrounding the acini (Fig 16).

The moderate amounts of positively stained collagenous fibers were seen lie around intra and interlobular connective tissue mainly around fi-

brous capsule, duct and blood vessels (Figs.17).

A strong positive PAS reaction is seen in the peri acinar, interlobular connective tissue and acinar basement membrane and moderate positive reaction in the acinar cell (Fig 18)

3) *In the third group (senile age, 2-3 years) of rabbits.*

Dorsal lacrimal gland;

Acini were large in size, and had wide irregular lumen. Some acini showed outpocketing of the glandular cells and some show cellular degeneration. Acinar cells were cuboidal with rounded basal nuclei (Fig19). The ducts were intralobular inside the lobules, and interlobular between the lobules in interlobular septae. The cells of the ducts were cuboidal, with central nuclei. Myoepithelial cells surrounding the acini, and cellular infiltration was noticed especially around the duct (Fig.20).

There were more deposition of collagenous fibers showed in periductal, perivascular and peri acinar connective tissue (Figs, 21).

A strong positive PAS reaction were seen in the acinar basement membrane, weak reaction in the cytoplasm of acinar cells (Fig22).

A strong positive Acid phosphatase reaction showed in some cells lining the lacrimal duct. Moderate reaction in some interlobular and peri-acinar connective tissue and weak reaction in the acinar cells (Fig.23).

Semithin sections of dorsal lacrimal gland, stained with toluidine blue showed acini separated by connective tissue septae containing blood vessels. Acinar cells were cuboidal surrounded by basement membrane, and myoepithelial cells. Secretory vacuoles were present in the apical part of the acinar cells, where the rounded nuclei of the cells were basal in position (Fig24). Interlobular ducts were seen, and also showing some secretory vacuoles (Fig 25).

Harderian gland :

The acini were closer, irregular in shape, some showing outpocketing of the acinar cells. Acinar cells were cuboidal with basal nuclei, cellular degeneration of the acini also noticed.

(Figs,26,27). The duct had cuboidal cells with basal nuclei, perivascular and periductal cellular infiltrations were noticed (Fig27). Myoepithelial cells were noticed surrounding the acini (Fig 26).

More deposition of collagenous fibers was noticed around ducts and blood vessels and minimal amount of collagen fibers in the inter and intralobular connective tissue in cells with large vacuoles, more deposition of collagen fiber in the inter and intralobular connective tissue cells with small vacuoles (Fig, 28).

A strong positive PAS reaction was observed in the ductal cells, ductal basement membrane, moderately positive PAS reaction in acinar basement membrane, perivascular and interlobular connective tissue and negative reaction in the acinar cell (Fig 29)

Mild acid phosphatase reaction

was seen in some acinus cell, and weak reaction in some interlobular and periacinar connective tissue (Fig 30).

Electron microscopic result :

In the lacrimal gland of the young age rabbits; the lacrimal acini contained acinar cells filled with secretory granules, rounded or oval basal nuclei. Most of those granules had granular contents, while few of them had homogenous electron dense contents. Supranuclear Golgi complex and mitochondria were aparent. (Figs, 31, 32). The lacrimal gland of senile rabbits show, some intact acinar cells, while others had ill defined cell boundaries and the nuclei of some of them were pyknotic .nuclei have high content of condensed chromatin. The cytoplasm contained coalescent secretory granules, the secretory granules might be fused together which had dark or light varieties. It also contained cytoplasmic vacuoles, Supranuclear Golgi complex, mitochondria and vacuoles. (Figs33, 34)

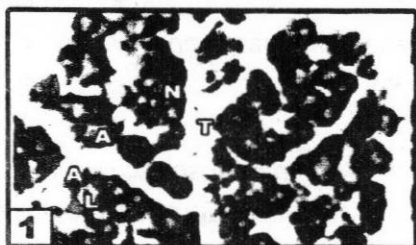


Figure 1 : A photomicrograph of section in the dorsal lacrimal gland of three month rabbit showing glandular acini (A), with narrow lumen (L), the nuclei are rounded and lies in the basal portion of the cell (N). Acini Separated by interlobular connective tissue (T). (Hx&E X 200)



Figure 2 : A photomicrograph of a paraffin section in the dorsal lacrimal gland of three month rabbit showing interlobular duct (D), with wide lumen (L), with rounded basal nuclei (N). (Hx&E X 400)

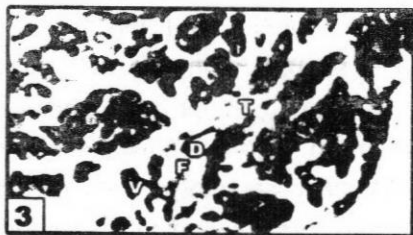

Figure 3 : A photomicrograph of a paraffin section in the dorsal lacrimal gland of three month rabbit showing collagen fiber (F) around interlobular connective tissue (T) mainly around interlobular duct (D) and blood vessels (V). (Mallory Trichrome X 100)

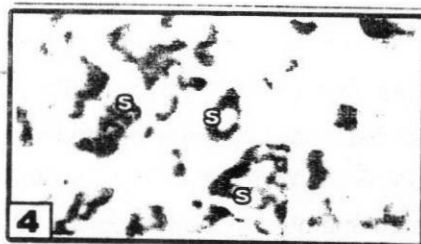


Figure 4 : A photomicrograph of a paraffin section in the dorsal lacrimal gland of three month rabbit showing strong positive PAS reaction in ductal cells (s), acinar basement membrane (s), and cytoplasm of acinar cells (S). (PAS X400)

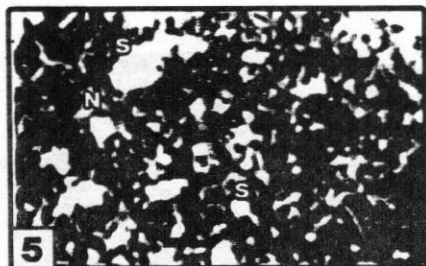


Figure 5 : A photomicrograph of frozen cryocut section in the dorsal lacrimal gland of three month rabbit showing positive acid phosphatase reaction in the acinar cell (S). And negative reaction in the interlobular and periacinar connective tissue (N). (Acid phosphatase X 200)

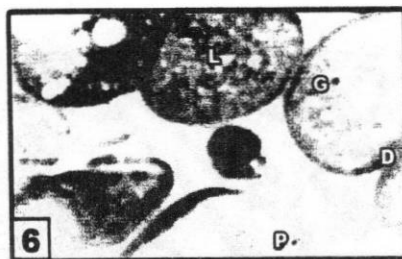


Figure 6 : A photomicrograph of a semithin section in the lacrimal gland of three month rabbit showing secretory acini, they have narrow lumen (L) and their cytoplasm are filled with secretory granules (G) some of the acinar cells appear darker (D) than the others (P). (Toluidine blue, X1000)

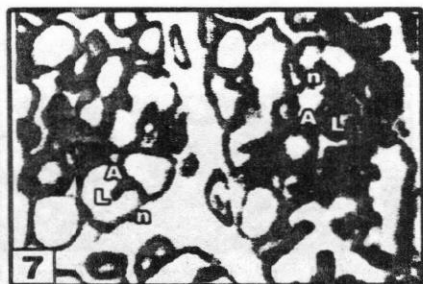

Figure 7 : A photomicrograph of section in the Harderian gland of three month rabbit showing different size and shape of acini (A). type I (I) with narrow lumen (L), rounded basal nuclei (n) and type II (II) with wide lumen (L) rounded basal nuclei (n). (Hx&E X 200)

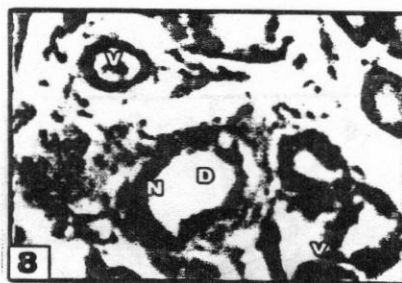

Figure 8 : A photomicrograph of section in the Harderian gland of three month rabbit showing acinar cells with large vacuole (v) in interlobular duct (D), duct cells have central rounded nuclei (n) and blood vessels (V). (Hx&E X 400)

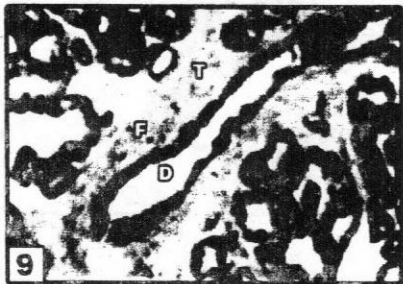


Figure 9 : A photomicrograph of section in the Harderian gland of three month rabbit showing collagen fiber (F) around interlobular connective tissue (T) mainly around interlobular duct (D) in acini with small vacuole. (Mallory Trichrome X 200)

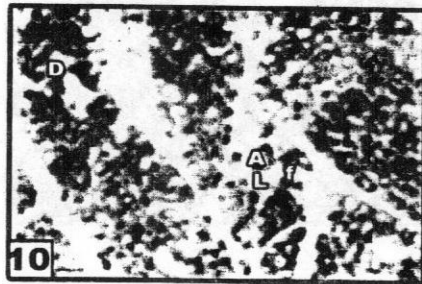

Figure 10 : A photomicrograph of section in the Harderian gland of three month rabbit showing mild collagen fiber (f) around ducts (d), in acini (A) with wide lumen (L) and negative collagen fiber around interlobular connective tissue. (Mallory Trichrome X 200)

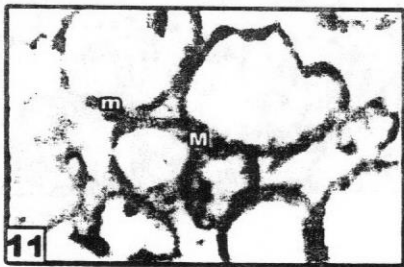


Figure 11 : A photomicrograph of a paraffin section in the Harderian gland of three months rabbit showing moderate positive PAS reaction in the acinar basement membrane (M), and acinar cells (m). (PAS X400)

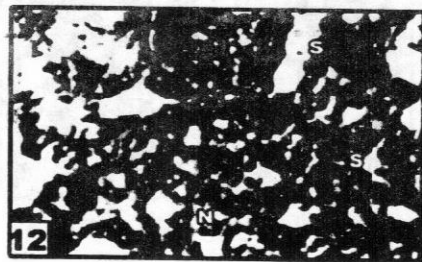


Figure 12 : A photomicrograph of frozen cryocut section in the Harderian gland of three month rabbit showing strong positive acid phosphatase reaction in some acinar cell (S), and negative reaction in some interlobular and periacinar connective tissue (N). (Acid phosphatase X 200)

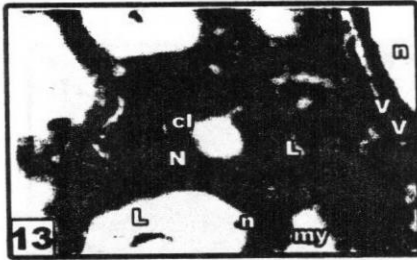


Figure 13 : A photomicrograph of section in the dorsal lacrimal gland of rabbit aged one year showing lacrimal acini, with different lumen (L), they are lined by columnar cells (cl) with rounded nuclei positioned in the basal portion of the cell (N), interlobular Blood vessels (V). Myoepithelial cells surrounding the acini(my), as flattened nuclei (n). (Hx&E X 400)

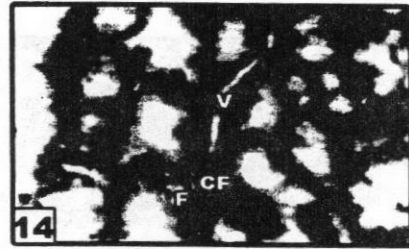


Figure 14 : A photomicrograph of section in the dorsal lacrimal gland of rabbit aged one year showing moderate amount of collagen fiber (F) in intra and interlobular connective tissue. And around blood vessels (V). (Mallory Trichrome X 400)

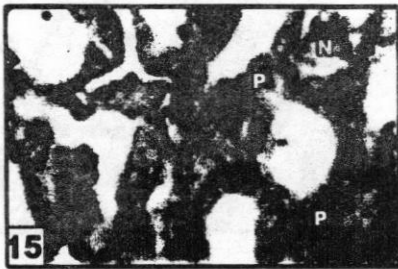


Figure 15 : A photomicrograph of section in the dorsal lacrimal gland of rabbit aged one year showing positive PAS reaction in the peri acinar, interlobular connective tissue, acinar basement membrane (P) and negative reaction in the acinar cells (N). (PAS X400)

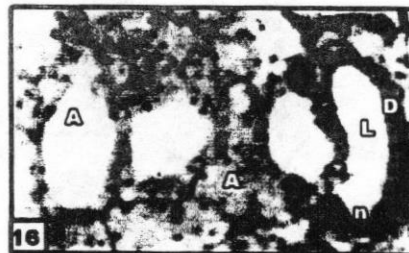


Figure 16 : A photomicrograph of section in the Harderian gland of rabbit aged one year showing large acini variable in size (A), interlobular duct (D) with central rounded nuclei (n), and large lumen (L). Myoepithelial cells surrounding the acini (my), as flattened nucleus (n). (Hx&E X 400)

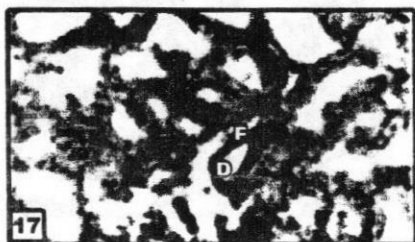


Figure 17 : A photomicrograph of section in the Harderian gland of rabbit aged one year showing moderate amount of collagen fiber (F) condensed around interlobular duct (D). (Mallory Trichrome X 200)

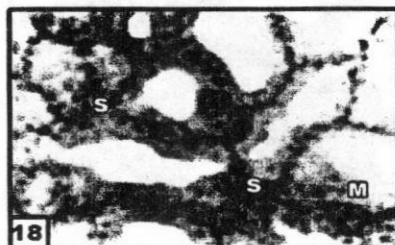


Figure 18 : A photomicrograph of section in the Harderian gland of rabbit aged one year showing strong positive PAS reaction in the peri acinar, interlobular connective tissue and acinar basement membrane (S).and moderate positive reaction in the acinar cell (M). (PAS X400)

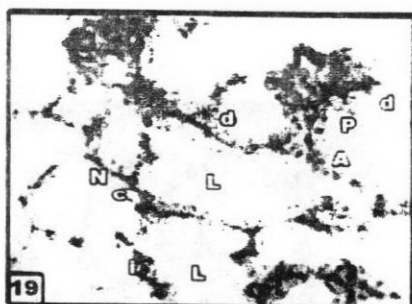


Figure 19 : A photomicrograph of section in the dorsal lacrimal gland of rabbit aged three years showing glandular lobules containing large acini(A),irregular lumen(L),outpocketing of acinar cells(p), some of them appear degenerated(d).acinar cell cuboidal in shape(c)with basal nuclei(N). (Hx&E X 400)

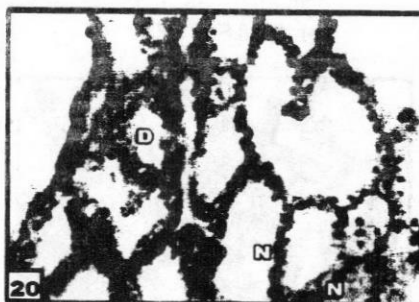


Figure 20 : A photomicrograph of section in the dorsal lacrimal gland of rabbit aged three years showing interlobular duct (D), myoepithelial cell with flattened nuclei(N). (Hx&E X 400)

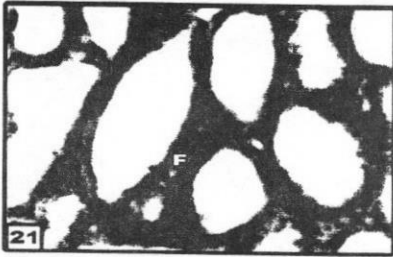


Figure 21 : A photomicrograph of section in the dorsal lacrimal gland of rabbit aged three years showing condensed amount of collagen fiber (F) mainly around intralobular duct and periacinar connective tissue. (Mallory Trichrome X 400)

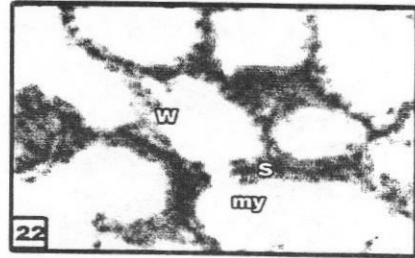


Figure 22 : A photomicrograph of section in the dorsal lacrimal gland of rabbit aged three years showing strong positive PAS reaction in (S) acinar basement membrane (b), and myoepithelial cells (my). And weak reaction in the acinar cell (W). (PAS X400)

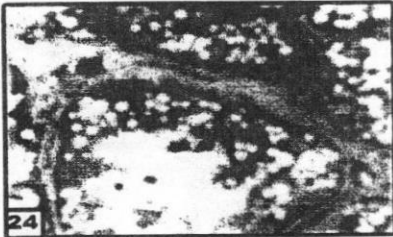


Figure 23 : A photomicrograph of section in the dorsal lacrimal gland of rabbit aged three years showing strong positive acid phosphatase reaction in the cell lining lacrimal main duct (S). (Acid phosphatase X 400)

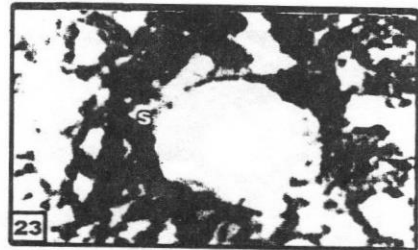


Figure 24 : A photomicrograph of a semi-thin section in the lacrimal gland showing secretory acini, they have rounded basal nuclei (N) their cytoplasm is filled with secretory vacuoles (s), acini surrounded by basement membrane. nuclei of myoepithelial cells were noticed (m), connective tissue septae contain blood vessels (v). (Toluidine blue, X1000)

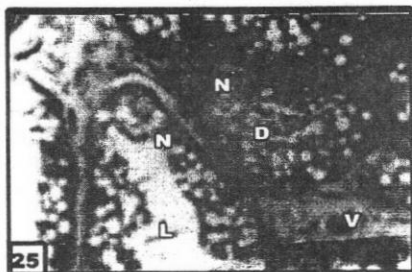


Figure 25 : Aphotomicrograph of a semi-thin section in the lacrimal gland showing secretory acini,they have wide lumens(L) with rounded basal nuclei(N) their cytoplasm is filled with secretory vacuoles (s) .connective tissue septae contain interlobular duct (D) with basal nuclei(N) and blood vessels (v). (Toluidine blue, X1000)

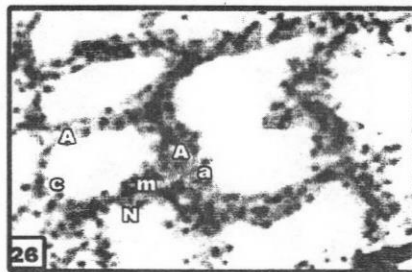


Figure 26 : A photomicrograph of a paraffin section in the Harderian gland of three years in rabbit showing large acini (A), acinar cells cuboidal in shape (c) with apical vacuole (a) and basal nuclei (N). myoepithelial cell (m) with flattened nuclei (N). (Hx&E X 400)

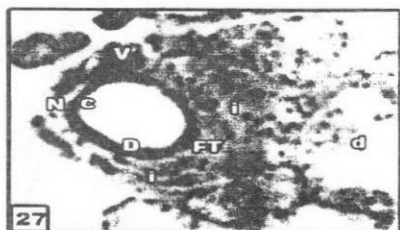


Figure 27 : A photomicrograph of a paraffin section in the Harderian gland of rabbit aged three years showing, Blood vessels (V), interlobular duct (D) had cuboidal cell (c), basal nuclei (N). acini (A) show cellular degeneration (d). cellular infiltration (i) was noticed around duct and blood vessels (Hx&E X 400).

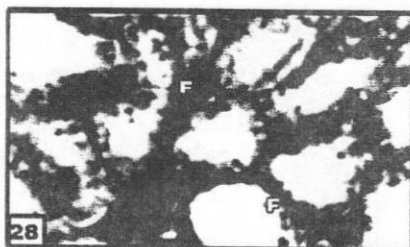


Figure 28 : A photomicrograph of a paraffin section in the Harderian gland of rabbit aged three years showing condensed amount of collagen fiber (F) mainly around interlobular connective tissue. (Mallory Trichrome X 400)

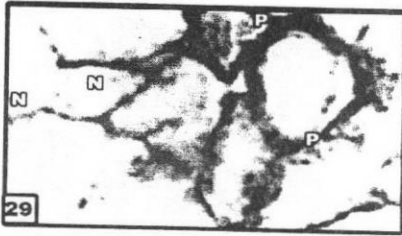


Figure 29 : A photomicrograph of a paraffin section in the Harderian gland of rabbit aged two years showing positive PAS reaction in acinar, basement membrane, perivascular and interlobular connective tissue (P). Negative reaction in the acinar cell (N). (PAS X400)

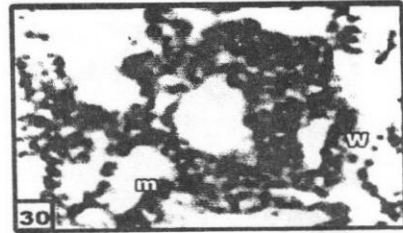


Figure 30 : A photomicrograph of frozen cryocut section in the Harderian gland of rabbit aged three years showing mild positive acid phosphatase reaction in some acinus cell (m) and weak reaction in some interlobular and periacinar connective tissue (W). (Acid phosphatase X 400)




Figure 31 : An electron micrograph of an acinar cell of young age rabbit lacrimal acinus showing oval nuclei (N), mitochondria (M), and secretory vacuole also present (S). (Uranyl acetate and Lead citrate X6610)




Figure 32 : An electron micrograph of an acinar cell of young age rabbit lacrimal acinus showing rounded nuclei (N), Supranuclear Golgi complex (G), mitochondria (M), their cytoplasm is filled with a homogenous electron dense material (H). (Uranyl acetate and Lead citrate X5200)

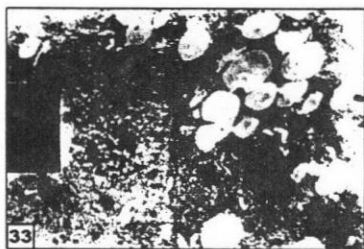

Figure 33 : An electron micrograph of an acinar cell of senile age rabbit lacrimal acinus. it part of acinus is intact ,its cell boundaries are defined ,with rounded nuclei(N) .the other part of acinus show ill defined cell boundaries and pyknotic nuclei (P). (Uranyl acetate and Lead citrate X 6610)




Figure 34 : An electron micrograph of an acinar cell of senile rabbit aged lacrimal acinus. showing nucle- us N) .some mitochondria ap- per intact (M), and vacuoles are noticed (V). (Uranyl acetate and Lead citrate X 8900)

DISCUSSION

In the present study, the acini were enlarged and dilated with the progress of age. In younger age the acini were small serous acini with narrow lumen and acinar cell pyramidal in shape with rounded basal nuclei. In senile group the acini enlarge in size, with wide irregular lumen without pocketing of glandular cells, some acini show cellular degeneration, and cellular infiltration. The acinar cells were cuboidal with rounded basal nu-

clei. Some of these acinar cells, on using toluidine blue stain, appeared darker than the others. These dark cells may contain in their secretory granules, more acidic and neutral glycoprotein than the pale cells. These contents also might cause the dark cells to attain a strong positive PAS reaction while the other pale ones attained a moderate positive reaction. These findings were in agreement with Ahmed (1983), who described two types of cells in the rabbit lacri-

mal acini; type I cells appeared pale while type II cells were dark. Allen, M, Wright, p. and Bron. et al, (1997) also reported that there were two types of cells lining the acini of the human lacrimal gland, one type was serous and the other was mucous. They added that the serous cells contained lysosomes and were similar to paneth cells. On the other hand, Kalleny, (1995), described only one type of cells in the acini of lacrimal gland in the rat. This controversy might be related to species differences

Draper. et al, (1997) in their study of age related morphological changes of male rat lacrimal gland, stated that the differences between young and aged rat glands included deposition of connective tissue, inflammatory cell infiltration, periductal fibrosis, acinar atrophy and reduced innervations. They estimated the percentage distribution of the acinar type of gland in different age groups, in young gland the majority of acini were serous (81%), few seromucous acini (17%), and pure mucous acini (2%).in aged gland their were significantly reduction in serous acini over all distribution was 23% when compared with

young gland .and marked increase in presence of seromucous acini over all distribution 53%.

In the present study, myoepithelial cells were seen around the secretory lacrimal acini. This in agreement with similar cells were noticed in lacrimal acini of one humped camels, Mongolian gerbils, mice and albino rats Prince, J.H, Diesem, C.D, Eglitis, I, Fahmy, M. F, Shain, Y.M, Sakai, yoh-ro, (1981) Johnston:et.al (1985) and Yaseen. et al, (1994). These myoepithelial cells were not noticed around the lacrimal intralobular or interlobular ducts, in this study. However, Gillette. et al, (1980) and Kalleny. (1995) described myoepithelial cells around these ducts, in the human lacrimal glands. They explained that these cells might have a role in squeezing the lacrimal secretion in the beginning of its flow.

In present study the lacrimal gland of the rabbits, have a well developed duct system in which the intralobular ducts are lined by a single layer of cuboidal or low columnar epithelial lining. These findings were in agreement with Gillette. et al, (1980) and Kalleny, (1995).

The increase in the size of the lacrimal acini in senile rabbits could be attributed to the accumulation of the secretory granules in these cells. These findings were in agreement with Yaseen. et al, (1994).

The increase of connective tissue fibers, inflammatory cells in senile lacrimal glands, might be attributed to the repeated episodes of inflammation of these glands throughout life. These inflammatory reactions might be followed by fibrosis with subsequent ischemia and degeneration of acinar cells. This was in agreement with Demato, B.E, Allen; et al (1984), Roen; et al (1985), Yaseen. et al, (1994) and Draper.et al, (1998).On the other hand, periductal areas as well as the structural damage of the acini. In senile age Makinodan and Kay, (1980), reported that repeated episodes of some systemic diseases such as rheumatoid arthritis were thought to involve the lacrimal gland.

The histological changes, in senile lacrimal glands, could be also due to recurrent episodes of vasculitis and arteriosclerosis and as aging lead to ischemia of the lacrimal acini. Parish,

(1980) and Friedlander, (1992) postulated similar explanation.

The presence of periodic acid Schiff reactive substance in the acini and connective tissue stroma of rabbits lacrimal glands, noticed in this study, came in agreement with Jensen, O.A, Hensen, F , Kalleny, (1995) and Garginlo, A.M, Aglio, C.D, Coliolo, P, Ceccarell, P and Pedimi.et al, (1999) who found polysaccharides in the Lacrimal acini of mouse, man, rabbits and sheep's. On the other hand, Yashimora. et al, (1980), and Khater , (1984), denied the presence of polysaccharides in the lacrimal acini and ducts of most mammals except the rabbits.

The presence of a moderate positive PAS reaction, in the lacrimal acinar cells of the young animals, might be due to the accumulation of glycogen droplets in these cells Nagato, (1993). This moderate positive PAS reaction, in the lacrimal acinar cells of both young and adult animals, and strong positive PAS reaction in ductal cells were noticed also by Draper. et al, (1998), in the rat lacrimal gland. However, the weak positive PAS re-

action, in the rat lacrimal acini of senile animals, might denote a decrease of the secretory capacity in the exhausted senile tissue. Furthermore, the thickening of the basement membrane, of the lacrimal acini in adult and senile animals, could be the result of recurrent addition of basement membrane materials from the surrounding connective tissue cells. This, in turn, aggravates the ischemic condition of the acini. These findings were documented by Yaseen. et al, (1994).

Draper. et al, (1998) postulated that the strong positive acid phosphatase reaction was observed in the basal portions of the lacrimal acinar cells in both young and senile animals, might explain why the lacrimal gland, in these two vulnerable ages, had high protective mechanisms from exposure to infections. However, the decline of the enzyme activity in the lacrimal acini, of senile rabbits, might be due to either a reduction in the ability of the acini to synthesize the enzyme or the number of acinar plasma membrane receptors for secretagogues. This is in agreement with study in which strong positive acid

phosphatase reaction was observed in the basal portions of the lacrimal acinar cells in both young and senile animals.

The presence of a strong positive acid phosphatase reaction, in the lacrimal ducts, in the present study, could be explained by Khater, (1984), who reported that the duct might secrete lysosomal enzymes. On the other hand, the appearance of acid phosphatase activity in the intralobular and interlobular connective tissue of the lacrimal glands of adult and senile animals might be attributed to the appearance of the macrophage activity.

The lacrimal acinar cells had Supranuclear Golgi apparatus, mitochondria, with lamellar cristae and secretory granules. This might signify that these cells had an active secretory function. Iwamoto and Jackobiec, (1982) and Draper. et al, (1997).

The acinar cells contained numerous secretory granules either granular or homogenous in character. The difference in electron density of the secretory granules in these acinar

cells could be attributed to the nature of the secretory materials inside these granules. Iwamoto and Jackobiec, (1982) said that the lacrimal secretory granules contained both serous (proteins) and mucous (polysaccharides) substances in various proportions that may differ from cell to cell. Furthermore, Miyazaki. et al, (2001) reported that the increase in the electron density of these granules denoted an increase in their protein content.

In present study the apparent increase of homogeneous electron dense granules, in the lacrimal acinar cells of the young animals, might denote the predominance of their protein content. On the other hand, most of these granules, in the senile groups, have granular contents, which might denote the predominance of their mucous content. These findings were supported by Dilly, (1994) and Draper. et al, (1998), who reported that, the maximum protein content output of the lacrimal gland occurred during the young age.

Draper. et al, (1997) noticed, in rat lacrimal gland, a change in the type

of secretory cells, and hence the type of acini, in different age stages. They found that the serous acini, in young rats were predominant while in growing and adult rats seromucous acini were predominant. They added that, in senile rats mucous acini became the predominant ones.

Draper. et al, (1998), noticed that signs of degeneration in the secretory acini of senile lacrimal gland were manifested by pyknosis of nuclei, and coalescence of the secretory granules. These degenerative changes might result from ischemia of the lacrimal acini, which in turn resulted from fibroses of the gland or vasculitis of its blood vessels. Deposition of collagen fibres as well as the presence of plasma cells, fibroblasts and fibrocytes were noticed inbetween the lacrimal acini, these changes might be attributed to the previous attacks of inflammation of the lacrimal gland throughout life. On the other hand, the degeneration of the cellular organelles and mitochondria was accompanied by decrease in the homogeneous electron dense granules of senile gland. This suggested that there is a reduction or an inability of the acini to

synthesize and secrete proteins and other substances as the animal proceeded in age.

The result of this study have demonstrated that lacrimal gland acini change with age both morphological and histological .the acinar cells in young glands were predominately serous (protein producing and secreting cells), change of acinar cells to seromucous (protein and mucous producing and secreting cells) in the adult age, and to mucous acini in senile age.

These results indicate progressive alteration in the specialized protein-secreting cells of the lacrimal gland with age. Initially from serous to seromucous to mucous acini, this progression from serous to mucous is important finding.however, the causes and mechanism of these change are duo to the normal process of cellular aging which involves loss of cellular homeostasis and maintenance over time Kirkwood, (1992), Rattan,(1995).

The major mode of cellular maintenance includes; processes of cellular

repair, cell division, cell replacement, neuronal and hormonal responsiveness, immune response. Loss of one or a number of these mechanisms may be responsible for the changes in the acinar cells, Draper. et al, (1998).

REFERENCES

1. **Ahmed, M.M.M. (1983)** : Astudy of Orbital glands in some mammals. M.sc. thesis in Histology and Cytology, Faculty of Medicine, Zagazeig University.
2. **Azzarolo AM, Olsen E and Huang ZM (1997)** : ovariectomy includes a poposis and necrosis in rabbit lacrimal gland. Prevention by androgen. Investigative ophthalmology&visual science, 1997: 38-S444.
3. **Azzarolo, AM. (2003)** : Estrogen Prevention of Lacrimal gland cell death and lymphocytic infiltration EXP Eye Res 2003 Sep: 77 (3) 347 -54.

4. **Bron, A.J., Tripathi, R.C. and Tripathi, B.J. (1997) :** Wolff's Anatomy Of the Eye and Orbit. Chapman and Hall Medical, London, 8th ed.: 72-82.
function of the tear film. In (David A Sullivan 1st ed.) Lacrimal Gland; Tear film and dry eye syndrome. Plenum Press, New York, U.S.A.,350:329-47.
5. **Claio, J. (2000) :** Why the eye become dry; a cornea and lacrimal gland feed back model. Department of ophthalmology, Oregon health Sciences University, Portland 97201, USA.Jun; 26(3); 159-1965.
6. **Cornell-Bell, DA. Sullivan and MR. Allansmith. (1985) :** Gender-related differences in the morphology of the lacrimal gland. Investigative ophthalmology&visual science, vol 26, 1170-1175.
7. **Demato, B.E., Allen, D., Murray, S.B and Lee, W.R. (1984) :** Senile atrophy of the human lacrimal gland; The contribution of chronic inflammatory disease. British J.of ophth., 86: 674-680.
8. **Dilly, P.N. (1994) :** Structure and Vol. 39, No. 1 & 2 Jan., & April, 2008
9. **Draper, C.E., Singh, J, Pallot and Adeghate, E.A. (1997) :** The effect of age on protein and peroxidase secretion and morphological changes in the isolated rate lacrimal gland. J. Physiol., 501p : 155p.
10. **Draper, C.E, Adeghate, E.A, Lawrence, P.A and Garner, A.(1998) :** Age Relates changes in morphology and secretory responses of male rate Lacrimal gland. J. Aut. Nerv. Syst., 69: 173-83.
11. **Elhusseni H. M. (2003) :** Estrogen prevention of the lacrimal gland cell death and lymphocytic infiltration.Exp Eye Res.2003 sep;77 (3):347-54.
12. **Farrell J, Patel s, Grierson DG**

- and Sturrock RD. (2003) :**
 Aclinical procedure to predict the value of temporary occlusion therapy in keratoconjunctivitis sicca. *Ophthalmic physiol opt.* 2003 Jan; 23:1-8.
- 13. Friedlander, M.H. (1992) :** ocular manifestation of Sjogren's syndrome and Kerato conjunctivitis sicca. *Rheum.Dis. Clin. North Am.*, 18, (3); 591-608.
- 14. Garginlo, A.M, Aglio, C.D, Coliolo, P, Ceccarell, P and Pedimi. (1999) :** Carbohydrate histochemistry and ultracytochemistry of the sheep lacrimal gland. *Anat. Histol. Embryol*, 29, (1): 19-23.
- 15. Gillette, L.T.E, Allansmith, M.R and Greiner, J.V. (1980) :** Histological and immunohistologic comparison of main and accessory lacrimal sue. *Am. J. Ophthalmol*, 89: 724.
- 16. Iwamoto, T and Jackobiec, F. A. (1982) :** Lacrimal Glands In: *Ocular Anatomy, Embryology and Teratology*. Harper and Row publishe, New York: 761 -763.
- 17. Johnston, H.S, Mc Gadey, J, Thompson, G.G, Moore, M.R, Breed, W.G and Payne, A.p. (1985) :** The harderian gland, its secretory duct and porphyrin content in the plains mouse (*pseudonyms Australis*). *J. Anat.*, 140, (2): 337 -350.
- 18. Kalleney, N.K. (1995) :** Histological study of the orbital glands in some mammals. M.sc thesis in Histology and Cytology, Faculty of Medicine, Ain shams University: 11.
- 19. Khater, N.A.A. (1984) :** Comparative Histological and Histochemical studies of the lacrimal apparatus in experimental animals. M. Sc. Thesis in Histology and Cytology, Faculty of Medicine, Zagazeig University.

20. **Kirkwood, T.B.L. (1992)** : Biological origins of ageing; In Oxford textbook of geriatric medicine (Evans. J.G. and Williams T.F. eds). Oxford University press, Oxford. U.K. 35-40.
21. **Makinodan, T and Kay, M.M. (1980)** : Age influence immune system. Adv. Immunol., 29: 287.
22. **Michael, E, Stern, ph, Roger, W and Beuerman. D. (1998)** : The pathology of dry eye: the interaction between the ocular surface and lacrimal glands. Cornea 17(6); 584-589.
23. **Miyazaki, T, Inoue, Y and Takan, K. (2001)** : Seromucous cells in human sublingual glands : Examination by immunocyto -chemistry of lysosome. Arch. Histol. Cytol, 64, (3) -305-12.
24. **Nagato. (1993)** : Lipid droplet accumulation in the exocrine glands of the newborn rat (Okayama-Folia). anat. Jpn., 69, (6):25263.
25. **Nava-Castaneda, A, Tovillacanales, J.L, Rodriguez, Land Tovolla, Y. (2003)** : Effect of lacrimal occlusion with collagen and silicon plugs with conjunctivitis association with dry eye. cornea, 22, (1):10-14
26. **Olsen , E. (1997)** : ovariectomy induced apoptosis and necrosis in rabbit lacrimal gland. Prevention by androgen. Invest Ophthalmol vis sci 1997, 38: 544.
27. **Parish, W.E. (1980)** : Microbial Antigens in Vasculitis: Wolfok and winkel -mann, R.K. eds., Lloyed -Lude, London : 129 -150.
28. **.Peiffer, R.L and Petersen Jones, S.M. (1997)** : Small animal ophthalmology: A problem -oriented approach. 2nd ed., Saunders Company LTD, London, Philadelphia, Toronto, Sydney: 219 -220.

- 29 . **Rattan, S.I.S. (1995)** : Aging: biological perspective. *Mol. Aspects Aging*, 16: 439-508.
30. **Roen, J.L, Stasior, O.G and Jackobiec, F.A. (1985)** : Aging changes in the human lacrimal gland: role of the ducts. *CLAOJ*, 11: 237 - 242.
- 31 .**Sakai, T and Yohro, T. (1981)** : A histological study of the harderian gland of Mongolian gerbils, (*Meriones meridianus*). *Anat. Rec.*, 200: 259-270.
32. **Stern. (1998)** : Department of biological sciences. Allergen, Inc, Irvine. Pathology of dry eye. *Cornea*. 198 Nov 17 (6) 584-589.
33. **Sullivan, DA and Krenzer, KL (1999)** : Dose androgen insufficiency cause lacrimal gland inflammation and aqueous tear deficiency. *Invests Ophthamol vis sci* 1999 may. 40 (6): 1261-5.
34. **Sullivan, D.A and Sato, E.H. (1999)** : Principles and Practice of Ophthalmology; Basic Science. In: *Immunology of the lacrimal gland*. WB Saunders Company, Philadelphia: 479.
35. **Sullivan, D.A, wickham, LA and Krenzer. (1997)** : Aqueous tear deficiency in Sjogren's syndrome; possible causes and potential treatment. *Oculo dermal disease, immunology of bullous. Oculo muococutaneous disorder*, Buren, the netherland; Aeolus press, 1997; 77; 95-152.
36. **Yaseen, A.H Sakkara, Z.A and Ibraheim, F.A. (1994)** : Age-related changes in the lacrimal glands of albino rat. *The Egyptian Journal of histology*, 17, (2): P. 437.
37. **Yashimora, M Sameshima, M and Ohba, N. (1980)** : Secretory Cell of the rabbit lacrimal gland *j. Ophthalmol.* 24: 407-419.

38. Yoshino, K, Garg, R and Monroy, D. (1996) : Production and secretion of transform-

ing growth factor beta by human lacrimal gland. Curr. Eye Res., 15, (6), 615-24.

الملخص العربي

التغيرات في الغدة الدرقية للأرناب مع تقدم السن (دراسات بالمجهر الضوئي والالكترونى)

حسن البنا عبد العدل محمود ، مصطفى السيد محمد الجيزاوى

حسام الدين حسين عثمان* ، مصطفى أحمد أبو النجا

السيد عبد الرحمن عبد الهادى محمد**

قسم التشريح بكلية طب بنين-جامعة الأزهر*

قسم التشريح بكلية طب بنين دمياط-جامعة الأزهر**

استهدفت هذه الدراسة إيضاح التغيرات الهستولوجية والهستوكيميائية التي تحدث في الغدة الدرقية في الأرناب في المراحل العمرية المختلفة مع ربط هذه التغيرات مع تلك التي تحدث في التركيب الدقيق لهذه الغدة.

ولقد استخدم في هذه الدراسة عدد ثلاثون أرناب في اعمار مختلفة مقسمة الى ثلاث مجموعات

المجموعة الاولى :- وعمرها من ٣ : ٥ شهور ، المجموعة الثانية :- من ٩ : ١٢ شهر

المجموعة الاخيرة :- من ٢٤ : ٣٦ شهر وتعتبر هذه هي المجموعة المسنة في العمر

وقد استخرجت الغدة الدرقية من كل حيوان على حده وعولجت للحصول على:

١- قطاعات شمعية صبغت بالهيماتوكسلين والايوسين وصبغة مالمورى وتفاعل الشيف الحامض.

٢- قطاعات ثلجية طازجة لتحديد نشاط انزيم الفوسفاتيز الحامض.

٣- قطاعات شبه رقيقة صبغت بالتولويدين الأزرق.

٤- قطاعات متناهية الرقة للفحص بالميكروسكوب الإلكتروني.

في الأرناب توجد غدة درقية ظهريّة في المنطقة الخلفية الظهرية لمقله العين قطرها حوالى

٤مم.

كما توجد غدة أخرى وهى غدة هاردير وليس لها نظير بالانسان توجد فى المنطقة الامامية البطنية لمقلة العين وقطرها حوالى ٦ مم.

وقد أظهرت هذه الدراسة أن الغدة الدمعية الظهرية فى الارانب من ٣ : ٥ شهور تتكون من وحدات انبوية حويصلية تنفصل عن بعضها بطبقات كثيفة من النسيج الضام لتقسمها الى فصوص تتكون الحويصلات من خلايا مكعبة ولها انوية قاعدية مستديرة وسيتم بلازم قاعدى محبب . اما فى الارانب المسنة فقد لوحظ زيادة فى كثافة النسيج الضام حول القنوات الدمعية وحول الاوعية الدموية وايضا لوحظ انتشار خلايا التهابية ووجود تحلل خلوى وتحلل فى جدار بعض الحويصلات الدمعية .

لوحظ فى تفاعل الشيف الحامضى ان الحويصلات الدمعية قد اكتسبت درجة متوسطة فى تفاعل الشيف الحامضى فى كل من الأعمار النامية والبالغة بينما اكتسبت هذه الخلايا درجة ضعيفه من ذلك التفاعل فى الحويصلات الدمعية للحيوانات المسنة كمايزداد سمك الغشاء القاعدى للحويصلات الدمعية فى كل من الحيوانات البالغة والمسنة.

اما فى تفاعل الفوسفاتيز الحامضى لوحظ تفاعل قوى فى الأجزاء السفلى من خلايا الحويصلات الدمعية بينما اكتسب باقى السيتوبلازم فى هذه الخلايا تفاعلا متوسطا للانزيم ,وقد قلت شدة هذا التفاعل مع تقدم العمر .

عند الفحص بالميكروسكوب الالكترونى وجد أن خلايا الغدة الدمعية بها جهاز جولجى اعلى نواة الخلية بالاضافة الى الشبكة الاندويلازمية المحببة والعديد من الميتوكوندريا والحبيبات الافرازية، وقد لوحظ أن هذه الخلايا فى الغدة الدمعية للحيوانات النامية قد احتوت على كمية زائدة من الشبكة الاندويلازمية المحببة والميتوكوندريا،وقد ظهرت بعض علامات التحلل الخلوى فى بعض من خلايا الحويصلات الدمعية فى الحيوانات المسنة مثل انكماش انوية بعض هذه الخلايا وتحلل فى الشبكة الاندويلازمية والميتوكوندريا وظهور بعض الحويصلات السيتوبلازمية.

غدة هاردير :

تتكون غدة هاردير من وحدات انبوية حويصلية تنقسم الى فصوص بطبقات من النسيج الضام . يوجد نوعان من الحويصلات فى غدة هاردير (نوع رقم ١) (وتوع رقم ٢) .

تتميز حويصلات النوع رقم (١) ان لها تجاويف ضيقة وخلاياها بها فجوات صغيرة مع انوية

قاعدية مستديرة . اما النوع رقم (2) يتميز بتجاويف واسعة وفجوات فى الخلايا اكبر وانوية مستديرة قاعدية . فى الارانب المسنة تكون الحويصلات اكثر تقاربا وغير منتظمة الشكل مع وجود انبعاث خارجى لخلايا الحويصلات .

الاستنتاج :-

يستنتج من هذه الدراسة انه قد تحدث تغيرات هستولوجية وهستوكيميائية واخرى دقيقة فى الغدة الدرقية للأرانب اثناء مراحل عمره المختلفة قد تساهم فى تفسير نقص افراز الدمع المائى فى الاعمار المتقدمة . يوصى بالعناية الفائقة بالعينين لمحاولة تجنب الاصابة المتكرره بالتهاب الغده الدرقيه حيث يقل افراز هذه الغده للانزيمات الواقيه فى عمر الشيخوخه .

