

# POSTNATAL DEVELOPMENT OF THE KIDNEY IN NORMAL AND MALNOURISHED PREGNANT ALBINO RATS

*By*

Ahmed O.Ibrahim\*, Mostafa El-Gizawi\*,  
Mostafa A. Abou-Elnaga\*\*, Fawzy  
Mahmoud Abou-Galala\*\*

*From*

*Anatomy Department\*, Faculty of Medicine El-Azhar University.*

*Anatomy Department\*\*, Dameitta Faculty of Medicine El-Azhar University.*

## ABSTRACT

This work was undertaken to study the effects of malnutrition during pregnancy on the postnatal development of the kidney in white rat offspring.

The female rats used in this investigation were housed with the males and vaginal smear was done daily. The pregnant ones were divided into two groups kept on two dietary regimens ;the first were fed on milk, water and bread, while the second on water, sugar and starch from the first day of conception till delivery. Fifteen offsprings from the first group (normal diet) and Fifteen from the second group (carbohydrate diet) were scari-fied at 1 day, 2 weeks and one month.

The animals were weighed, the kidneys were gently dissected out from the abdominal cavity and dropped into the fixative then weighed and the kidneys to body weight ratio was calculated, tabulated statistically and analysed. Paraffin sections of 5- $\mu$ m thickness were prepared from the kidneys of all animals. Different histological stains were used and the kidneys were examined microscopically

Compared to the control animals, both the body weight and kidney weight in the malnourished animals showed a significant reduction.

The tubules and renal corpuscles in the control animals increased in

size and number with increased age.

In the control animals the nephrogenic masses appeared in the sub-capsular zone at newborn rats in the form of oval, rounded or elongated structures. At the age of two weeks postnatally, the nephrogenic masses disappeared and were replaced by various structures of renal tubules and renal corpuscles. The nephrogenic masses in the malnourished animals appeared smaller in size and fewer in number with crowded elements of parenchyma.

The malnourished animals showed mild to severe degenerative changes in all parenchymal elements including the Bowman's capsule, the tubules and glomeruli. The glomeruli appeared collapsed with marked increase in their capsular spaces. The capillary tufts were shrunken with cleft formation.

In the malnourished animals the proximal and distal tubules appeared adherent to each other and showed wide tubular lumina, loss of brush borders, necrosis of the lining cells with mild to severe degeneration.

Some of the collecting tubules became wide, and showed accumulation of hyaline materials. The renal medulla showed interstitial haemorrhage, cellular infiltration and fibrous tissue formation.

In conclusion, it was clear that malnutrition during pregnancy exerted harmful effects on the kidneys of the developing embryo. These harmful effects might or could be an important cause for a variety of health hazards started from hypertension up to reaching a complete renal failure. This malnutrition during pregnancy should be corrected as early as possible.

## INTRODUCTION

Malnutrition is one of the leading causes of morbidity and mortality in childhood John et al. (2000). Malnutrition might be due to improper or inadequate food intake or might result from inadequate absorption of food, poor dietary habits emotional factor John et al. (2000).

The kidney is essential to the control of concentration of various substances in the body fluids e.g. main-

tained electrolyte and water balance in tissue fluid and they also had endocrine function Young et al. (2000).

Prenatal growth retardation due to maternal malnutrition resulted in a permanent abnormality of the structures and functional capacity of the kidney Hinchelife et al. (1992).

Feeding of low protein diet pregnant rat resulted in, disturbances in fetal growth and dimensions at birth. The offspring of rats fed low protein diet exhibited a number of metabolic and physiological disturbances Langley (2001) .

The intrauterine factors, are extremely important in determining the future health of the individual. There was strong evidence suggesting that one of the major organs affected by an unfavorable prenatal environment was the kidney Mortiz et al. (2003) .

Protein deficit in pregnant female nutrition during prenatal development of the offspring was accompanied by considerable changes in kidneys both in early and in late embryogenesis Timofeeva et al. (2002).

The kidney of albino rat was unipyramidal (unilobular) and the primary pyramid was observed at the first postnatal day and acquired the adult shape with a tapering papilla by the 3<sup>rd</sup> week Wassif (1991). The renal pelvis was of a simple type in early stages of development, and changes into a complex type at the third postnatal week with the development of secondary fornix due to the appearance of secondary pyramids at this age Wassif (1991). The upper pelvic cavity lined with transitional epithelium which is thinned out toward the primary fornix where it changes into one layer of low cubical epithelium. The renal pyramid and the tip of papilla are covered by cuboidal epithelium similar to that lining the collecting ducts Wassif (1991).

The postnatal changes of rat kidney, he was found that, the kidney and body weights of rat were progressively increased postnatally however, the proportion of the kidney weight to the body weight showed maximum value at three weeks and progressively decreased in older ages Hasaniien (1993).

The postnatal development of vascularity of the kidney of the rat, and found that, the general pattern of the renal vasculature of the rat kidney at different postnatal ages was nearly similar. However the histological structure of the renal vessels was different from one age to another Abou El-Naga (1997) .

#### *Effect of malnutrition*

Malnutrition is a world wide problem of enormous magnitude adversely affect the health of children and growing persons Chopra (1991). In the rat, permanent growth retardation was evident in offspring subjected to maternal protein restriction during the postnatal period Tredici et al.(1998).

The development and growth of the rat embryos are effected by malnutrition and the brain and the kidney of fetus were damaged in serious vitamin A deficiency Fan and Zhu (1999).

Recent epidemiological studies in people whose birth weight were recorded many years ago , suggested a link between impaired growth during early life and the long-term effects of

retarded early growth which resulted from malnutrition at critical period which led to reduction in the growth of organs and permanent changes in their metabolism or structure or both Desai et al . (1996).

Compelling evidence has suggested that one of the major organs affected by an unfavorable prenatal environment was the kidney . Many of the factors that affect fetal renal development include exposure to excess glucocorticoids, insufficient vitamin, protein / calorie malnutrition and alteration in the intrarenal renin angiotensinogen system Mortiz et al . (2003).

Maternal undernutrition before conception not only affect growth of vital organs, but also result in increased levels of glucose and cholesterol in the offspring at adulthood Joshi et al . (2003).

Nutritional restriction of the mother of the rat throughout gestation and found that there was intrauterine growth retardation ( IUGR). They reported that the mean body weight of fetuses in late gestation from the re-



stricted diets was significantly lower than that of fetuses from control rats Woodall et al. (1996).

The effects of paternal and maternal undernutrition on growth of offspring in rats and found that in adult males, undernutrition was associated with altered spermatogenesis. Maternal undernutrition was associated with decreased maternal weight gain lower offspring birth weights and body weights at weaning Abel (1990).

Small size of the body at birth is associated with increased blood pressure in adult men and women. In rats, isocaloric protein restriction reduced fetal growth and increased systolic blood pressure in adult rat Kind et al. (2002).

The offspring parameters studied were not affected by food restriction during the first half of the experimental period. On other hand, food restriction during the second half was more deleterious to the offspring. When food restriction was applied during the whole experimental period, the impairment in energy balance of offspring was similar to the one ob-

served when food restriction occurred during the 2<sup>nd</sup> half of pregnancy added to a decreased number of offsprings Griggio et al. (1997) .

Low birth weight (LBW) from non-rished mothers had little influence on renal development, glomerular number and volume while offspring rats of low birth weight delivered from malnourished mother suffered from a reduction in glomerular number that might, in turn, predisposed to hypertension in adulthood Jones et al. (2001) .

The number of nephrons, renal hemodynamics ,and glomerular morphology in rats submitted to a multideficient diet. These animal exhibited lower body and kidney weights and no glomerular hypertrophy. They concluded that the alterations induced by intrauterine malnutrition were compatible with the development of chronic renal failure Paixao et al. (2001).

Maternal malnutrition during pregnancy and lactation led to reduction in the offspring kidney weight Murillo et al. (2001).

## MATERIAL AND METHODS

The fifteen female rats used in this experiment and were housed with the males and vaginal smear was done daily. The pregnant ones were divided into two groups kept on two dietary regimens from the first day of conception till delivery. The rats of the first group (15) were used as control and were fed on milk, water and bread. The rats of the second groups (15) were fed on water, sugar and starch. Five offsprings from the first group (normal diet) and five from the second group (carbohydrate diet) were scarified at the age of 1 day (5), 2 weeks (5) and one month (5). The animals were weighed, the kidney were gently dissected out from the abdominal cavity and dropped into the fixative of 10% formaline for one to three days then weighed and the kidney to body weight ratio was calculated and tabulated. Paraffin sections of 5- $\mu$ m thickness were prepared from the kidneys of all animals. Different histological stains (H, E, PAS and Mallory stain ) were used to examine the kidney parenchyma microscopically

## RESULTS

### *NEWLY BORN (ONE DAY POST-ANTAL) :*

One layer of flattened mesothelial cells covered the kidney. The parenchyma of the kidney appeared to be composed of cortex and medulla and widely separated by a good amount of interstitial cellular tissue, but it appeared more crowded and separated by less interstitial tissue in the deep part of the cortex. The kidney was unipyramidal; the apex of the pyramid protruded into the renal pelvis and resembled the root of the tongue (Fig. 1).

### *THE CORTEX :*

Examination of H. & E. stained sections showed that the cortex appeared to be formed of two different zones, dense subcapsular zone and an inner wide less dense cortical zone. In the cortical zone, there was cortical labyrinth, which formed of renal corpuscles, proximal and distal convoluted tubules. The cortical labyrinths separated by medullary rays (Fig.1).

The parenchyma of the cortex showed different stages of postnatal

development of renal corpuscles with the immature ones toward the capsule and the mature corpuscles in the juxta-medullary region. Under the renal capsule, the nephrogenic area was contained rounded solid cellular mass with rounded nuclei (Mesenchyme) (Fig .2). Rounded vesicles were also observed lined by tall columnar cells with basal oval nuclei surrounded a narrow eccentric lumen (Fig .3).

Deeper in the cortex, the vesicles appeared curved shaped with slight dilatation of their lumina and having rounded masses of polygonal cells came in contact with their concave side ( Fig.3). The renal corpuscles in this zone appeared in different stages of development. Relatively immature renal corpuscles appeared with distinct capsular spaces. The degree of maturity increased toward the medulla. The corpuscles were large and most of them were rounded in shape, showed capsular spaces partially surrounded tuft of capillaries. The parietal layer of Bowman capsule was formed of simple squamous epithelium. The visceral layer of Bowman's capsule was formed of a single layer

of radially arranged columnar cells .In juxta-medullary area of the cortex, some cells of the parietal layer of Bowman's capsule were cuboidal in shape, while the other cells were flattened squamous. The columnar cells represented the visceral layer could no more identified as a distinct layer but appeared to become intermingled with and could not be differentiated from the cells of the glomerulus in the full formed renal corpuscles (Fig. 4).

The proximal convoluted tubules were seen in the deep parts of the cortex lined with cuboidal cells having rounded centrally situated deeply stained nuclei and acidophilic vacuolated granular cytoplasm. The luminal surface of the lining cells were highly irregular showed brush borders in some areas. The distal convoluted tubules could be differentiated by their wide lumen and being lined by cubical cells with central rounded or oval nuclei and faint acidophilic non granular cytoplasm. The basement membrane of the distal tubules appeared thin and ill defined (Fig.4).

The collecting tubules were characterized by their wide lumina and

were lined by low cuboidal cells with basally situated, darkly stained rounded or oval nuclei and acidophilic cytoplasm (Figs. 4&5).

PAS stain exhibited a positive reaction in the apical part of the cells and the basement membrane of the proximal convoluted tubules, which appeared thin and ill -defined. The basement membrane of Bowman's capsule, the tuft of capillaries, the proximal and distal tubules as well as collecting tubules were strongly PAS positive. The distal tubules were strongly PAS positive but to a lesser extent than that of the proximal tubules (Fig . 6) .

With Mallory stain , A little amount of collagenous fibers in the glomeruli and a rounded the convoluted tubules were showed (Fig. 7).

The thick parts of the descending and ascending limbs of Henle's loop were difficult to be differentiated from the proximal and distal tubules respectively.

#### *THE MEDULLA :*

The medulla formed the major

thickness of the kidney parenchyma. The thickness of the medulla represented more or less 2-3 times the thickness of the cortex. The parenchyma appeared to be formed of tubules separated by a good amount of cellular interstitial tissues in which fibroblast like cells were detected. The medulla formed of two segments, outer and inner. The outer medulla characterized by presence of medullary rays which pass through the inner layer of the cortex (Fig.1&7) .

The inner layer of the medulla was highly crowded with tubules separated by scanty amount of connective tissue. The tubules in the inner layer of the medulla were lined by columnar cells, and some of them lined by high cuboidal cells. The collecting tubules were lined with columnar epithelium (Fig.5).

#### *ONE DAY MALNOURISHED :*

The general structure of the kidney in malnourished animals resembled that of the control ones in this age.

Examination of H.&E. sections, showed that The elements of the

parenchyma of the kidney appeared crowded. Some changes were observed particularly in the renal corpuscles, proximal convoluted tubules, distal convoluted tubules and renal interstitium. The cortex had a large number of less differentiated renal corpuscles as compared with the control one (Fig.8).

The juxta-medullary region had some renal corpuscles with dilated Bowman's space and atrophic glomeruli (Fig. 9). The proximal convoluted tubules had dilated lumen with damaged lining epithelium. There was also vacuolated cytoplasm of the cells of the tubules ( Fig.9)

PAS stained section demonstrated that most of the proximal convoluted tubules had lost their apical PAS+v brush border (Fig. 10).

With Mallory stain, the amount of collagenous fibers in the glomeruli and around the tubules were marked increase (Fig.11).

#### *TWO WEEK POSTNATAL :*

#### *THE CORTEX :*

Examination of H.& E. sections of

these age showed that , The cortex of the kidney did not showed the outer nephrogenic zone observed in the previous ages and appeared to be formed of one zone .The parenchyma of the kidney appeared more crowded and separated by few interstitial cellular tissues (Fig.12).

In the cortical labyrinth, the renal corpuscles were increased in size and number than those detected in the previous age . The glomeruli were seen to be formed of fewer dens cellular masses of polygonal cells with increased in their capillary lumen. The parietal layers of Bowman's capsule were formed of flat epithelial cell also The visceral layer of the Bowman's capsule had became intermingled with the endothelium of the capillary tuft. They increased in width and diameter and took the mature form towards the outer medulla (Fig. 13&14).

The proximal convoluted tubules appeared to be lined by few pyramidal cells surrounded a narrow lumen. The cytoplasm of the cells were acidophilic and granular with ill-defined boundaries. The apical parts

of the cells were irregular, nuclei were central and rounded. The distal convoluted tubules could be differentiated by their wide lumen. Cubical cells with central rounded nuclei and faint acidophilic nongranular cytoplasm lined them. The cells rested on a thin basement membrane. The macula densa could be easily identified as cubical cells with rounded not so closely packed nuclei (Fig.15).

By BAS reaction, showed a positive reaction in the basement membrane of the glomeruli and in their tuft of the capillaries. Also PAS positive reaction was showed in the apical brush border and the basement membrane of the proximal convoluted tubules. the distal tubules were strongly PAS positive but to a lesser extent than that of the proximal tubules (Fig. 16).

With Mallory stain , a little amount of collagenous fibers around the glomeruli and convoluted tubules as compared to the malnourished one of the same age (Fig . 17) .

*TWO WEEKS MALNOURISHED :*  
Examination of H.& E. sections

showed that, the previously mentioned changed in one-week-old rats became even clearer and included increased numbers of degenerated renal corpuscles and tubules. The renal corpuscles showed marked decreased in their sizes and exhibited an irregular outlines . Some of them showed a partially disintegration of their glomerular tufts with increased in their capsular space , while the other showed appearance of wide space within the capillary tuft (Figs.18).

The degenerative changed in the convoluted tubules started to took a focal pattern. The affected tubules showed various levels of degeneration.

Many dilated proximal tubules with marked vacuolated cytoplasm with sloughing in their endothelial lining with appearance of remnants of cytoplasm and nuclei inside their lumen (Fig .19). Some collecting tubules, in the medulla, were dilated with appearance of cellular debris inside heir lumina (Fig.20).

By PAS stained sections, the most of the apical brush border of the



proximal convoluted tubules, the tuft of capillary of the renal corpuscles and the distal tubules had a weak positive PAS reaction . (Figs. 21).

By Mallory stains, marked increased in the collagenous fibers in the glomerulus and around the tubules were showed (Fig .22) .

#### *ONE MONTH POSTNATAL :*

Examination of H. &E. sections of this age showed that, the kidney of the one-month rats attained the adult form. Also in this age showed a relative increased in the thickness of the cortex. The parenchyma of the kidney appeared to be more crowded and separated by less interstitial tissue. The kidney recognized as outer cortex and inner medulla .

#### *THE CORTEX :*

Thin connective tissue capsule were covered the cortex externally. The renal corpuscles were seen to be lobulated, less cellular and had a relatively wider capillary lumen. Most of renal corpuscles had cleared capsular spaces as the previous age . (Figs 23).

Proximal tubules were numerous seen hading narrow lumina. They appeared to be lined with cubical cells with acidophilic granular cytoplasm and central rounded nuclei. Distal convoluted tubules could be differentiated by their wide lumen characterized by cubical cells with central rounded nuclei and faintly acidophilic non-granular cytoplasm lined them (Fig. 24).

By PAS stained sections The apical part of the proximal convoluted tubules, the basement membranes of the glomeruli and the parietal layers of the Bauman's capsules showed a strong positive PAS reaction (Fig.25) .

By Mallory stain, a little amount of collagenous fibers around the tubules and the glomeruli were noticed. (Fig.26).

#### *ONE MONTH MALNOURISHED :*

Examination of H. &E. sections showed that, the degenerative changed in the kidney of one-month malnourished rats started to included scattered areas of the renal tissue. The affected areas demonstrated al-

terations in all constituents of the renal tissue.

The renal corpuscles showed various steps of degeneration started from irregularities in their contour to partially disintegration of their glomerular tuft which replaced by necrotic debris. Some the renal corpuscles appeared smaller with atrophic glomeruli and increased in the capsular space. the parietal layer of Bowman's capsule was disrupted and broken in some location which led to contact between the adherent renal corpuscles. focal areas of hemorrhage were detected (Figs. 27). Sever degeneration of the renal tubules with sloughing of their endothelial lining were detected . in some areas , the renal tubules had lost their identity and appeared open into one another . cellular infiltration of the inflammatory cells were detected in these section (Figs . 27) .

PAS stained sections, the apical brush border of the proximal convoluted tubules, the basement membrane of the glomeruli and that of the distal

tubules showed marked weak positive PAS reaction (Fig.28). By Mallory stains, there was fibrous tissue formation around the dilated tubules (Fig .29).

There was statistically significant decrease in malnourished group in comparison to control group as regard body weight. The mean body weight was  $(40.27 \pm 50.51)$  in control group and  $13.53 \pm 8.50$  in malnourished group.

There was highly statistically significant decrease in malnourished group in comparison to control group as regard body weight in all age groups

There was statistically significant decrease in malnourished group in comparison to control group as regard weight of the kidney.

There was highly, statistically significant decreased in malnourished group in comparison to control group as regard weight of the kidney in all age groups (from one day to the adult).

**Table ( 1):** showing the average weight (gm) of the animal , kidney and percentage of weight of kidney to body weight in the control animal.

Age	Average weight of animals (gm)	Average weight of kidney (gm)	Percentage of weight of kidney to body weight
One day.	5.6	0.044	0.78%
Two week.	13.8	0.091	0.65%
One month.	35.8	0.20	0.55%

**Table ( 2 )** showing the average weight (gm) of the animal . kidney and percentage of weight of kidney to body weight in the malnourished animal.

Age	Average weight of animals	Average weight of kidney	Percentage of weight of kidney to body weight
One day.	4.2	0.029	0.69%
Two week.	10.8	0.061	0.56%
One month.	19.3	0.10	0.51%

**Table (3):** Comparison between control group and malnourished. group as regard body weight.

GROUP	Number of rat	Mean	S. D	t	p
Control	15	40.27	50.51	2.61	0.012* Sig.
Malnourished.	15	13.53	8.50		

\* The test is significant at  $p \geq 0.05$

\*\* The test is highly significant at  $p > 0.01$

**Table (4):** Comparison between control group and malnourished group as regard body weight marked by age

Age	Group	N	Mean	S. D	t	p
One day	Control	5	5.60	0.15	10.43	<0.001**
	malnourished	5	4.20	0.25		
Two weeks	Control	5	13.80	0.22	19.78	<0.001**
	malnourished	5	10.80	0.25		
One month	Control	5	35.80	0.22	88.19	<0.001**
	malnourished	5	19.30	0.35		

\* The test is significant at  $p \geq 0.05$

\*\* The test is highly significant at  $p > 0.01$

**Table (5):** Comparison between control group and malnourished group as regard weight of the kidney

GROUP	Number of rat	Mean	S. D	T	P
Control	15	0.21 gm	0.24	2.78	0.008* Sig.
Malnourished	15	0.077 gm	0.043		

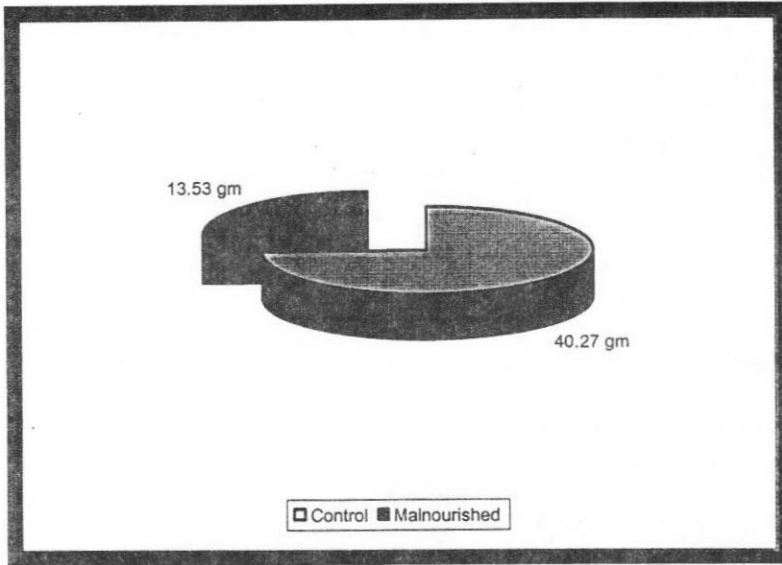
\* The test is significant at  $p \geq 0.05$

\*\* The test is highly significant at  $p > 0.01$


**Table (6):** Comparison between control group and malnourished group as regard weight of the kidney marked by age

Age	Group	N	Mean	S. D	t	p
One day	Control	5	0.044	0.0015	15.00	<0.001**
	malnourished	5	0.029	0.0015		
Two weeks	Control	5	0.091	0.0017	28.6	<0.001**
	malnourished	5	0.061	0.0015		
One month	Control	5	0.20	0.022	8.16	<0.001**
	malnourished	5	0.10	0.015		

\* The test is significant at  $p \leq 0.05$  \*\* The test is highly significant at  $p \leq 0.01$

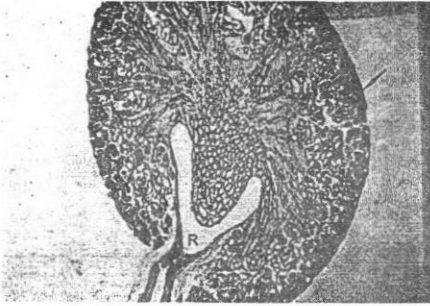


**Figure (1) :** Comparison between control group and malnourished group as regard body weight.

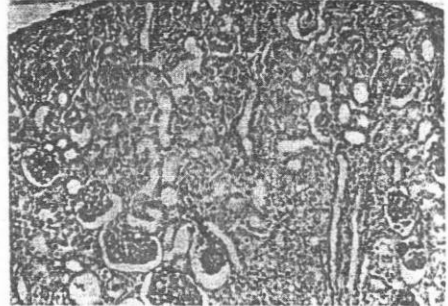

**Figure (2) :** Comparison between control group and malnourished group as regard weight of the kidney

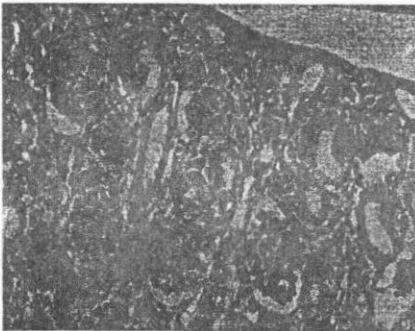



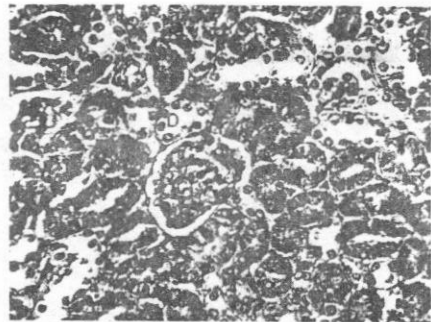
**Fig. 1 :** A photograph of a section in the kidney of control albino rat aged one day showing mesothelium (arrow), outer cortex (oc), inner cortex (i c), outer medulla(o m), inner medulla (i m) , Medullary rays (crossed arrow) and renal pelvis (R). (Hx&E.; x100)



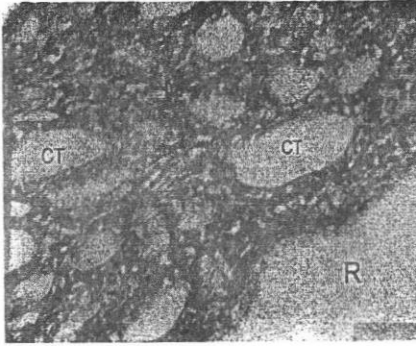
**Fig. 2 :** A photograph of a section in the renal cortex of control albino rat aged one day showing a multiple undifferentiated subcapsular nephrogenic masses in the form of, mesenchyme (ms) and vesicle (arrow). (Hx&E.; x200)



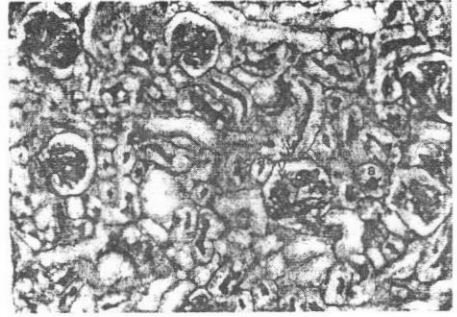
**Fig.3 :** A photograph of a section in the renal cortex of control albino rat aged one day showing multiple subcapsular vesicles (arrows) , one of them invaginated by tuft of capillaries (crossed arrow) subcapsular nephrogenic mass (arrows). (Hx& E.;x400)



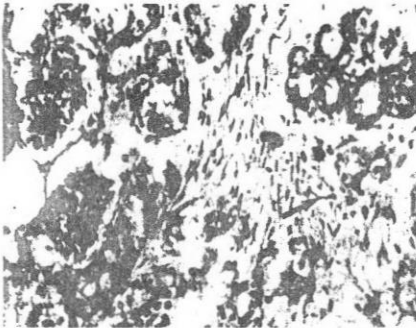
**Fig. 4 :** A photograph of a section at the deeper level of the renal cortex of control albino rat aged one day showing mature renal corpuscle (G) with distinct Bowman's spaces . also the proximal tubule (P) and distal tubule (D) are seen. (Hx&E.; x400)



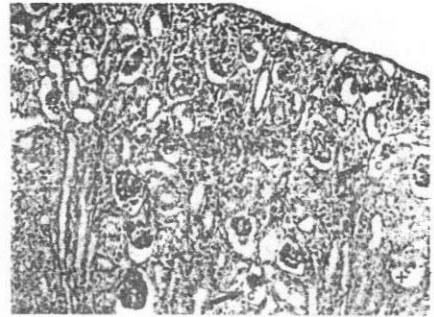
**Fig. 5 :** A photograph of a section in the renal medulla (M) and renal pelvis (R) of control albino rat aged one day showing a lot of collecting tubules (CT) (Hx & E.; x400)



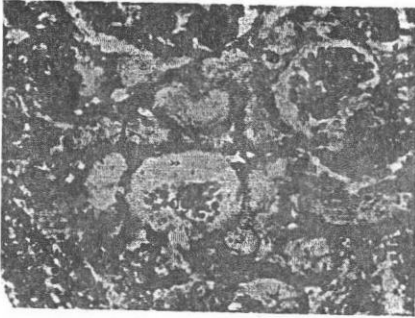
**Fig.6 :** A photograph of a section in the kidney of control albino aged one day showing strong PAS-positive reaction in the apical part of the proximal tubule ( a ) and distal tubules ( arrow ) The basement membrane of the glomerulus and the parietal layer of Bowman's capsule. are PAS positive reaction (>>). (PAS.;x400)



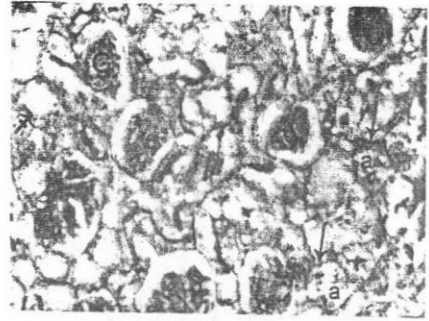
**Fig.7 :** A photograph of a section in the renal cortex of control albino rat aged one day showing a little amount of collagenous fibers in the glomerulus (G) and around the convoluted tubules (arrow). Notice appearance of fibroblast (+). (Mallory. x400) .



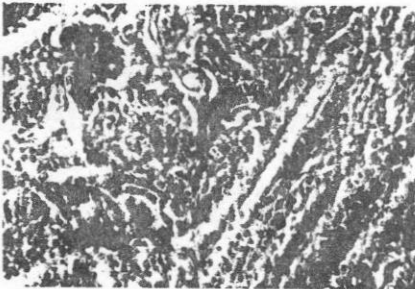
**Fig.8 :** A photograph of a section in the renal cortex of the malnourished albino rat aged one day showing, degenerated renal corpuscles ( arrow) in the form of collapsed glomerulus with marked increase in the capsular space ( c ) , some corpuscles are degenerated( + ) while others corpuscle appear normal (N).. (Hx & E.; x200)



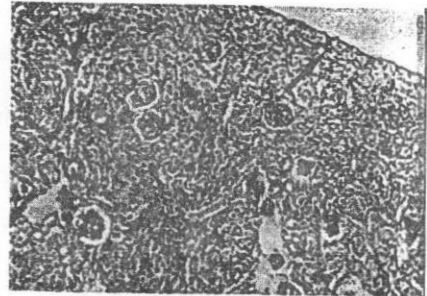
**Fig.9 :** A photograph of a section in the renal cortex of malnourished albino rat aged one day showing degenerated renal corpuscles in the form of collapsed glomerulus (dg) with marked increase in their capsular space (>>). Notice the marked dilatation of the convoluted tubules with disruption of their lining epithelium (arrow). (Hx&E.; x400)



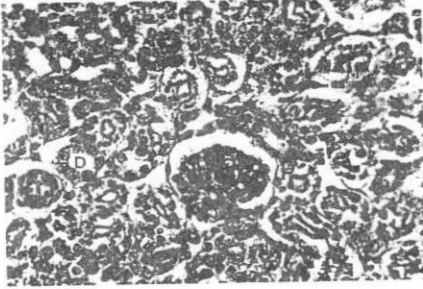
**Fig.10 :** A photograph of a section in the renal cortex of malnourished albino rat aged one day showing a weak PAS positive reaction in the basement membrane (arrow) of the glomerulus(G) and parietal layer of the Bowman's capsule (crossed Arrow), also some of the apical part of proximal convoluted tubules(a) (PAS.; x400)



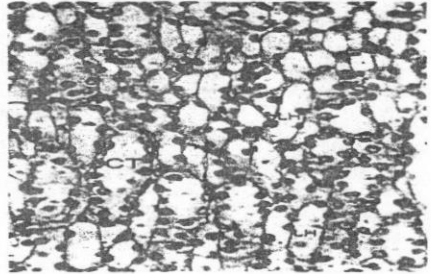
**Fig.11 :** A photograph of a section in the renal cortex of malnourished albino rat aged one day showing marked increase in the amount of collagenous fibers in the glomerulus (crossed Arrow) and around the convoluted tubules (arrow). (Mallory.;x400)



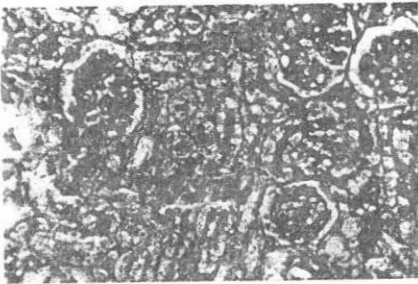
**Fig.12 :** A photograph of a section in the renal cortex of control albino rat aged two weeks old showing the disappearance of the outer nephrogenic zone ( arrow) . The parenchyma appears very crowded with the convoluted tubules ( Hx&E.; x200 )



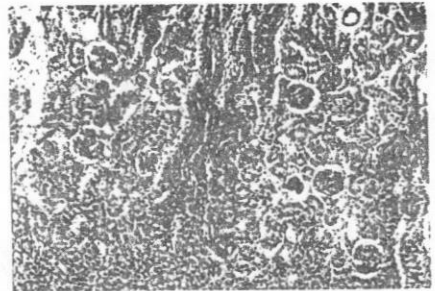
**Fig.13 :** A photograph of a section in the renal cortex of control albino rat aged two weeks old showing, mature renal corpuscles (R C). The convoluted tubules, proximal (P) and distal (D) are of normal appearance. Notice appearance of macula densa (arrow). ( Hx&E.; x400)



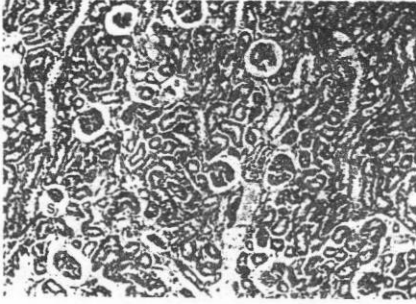
**Fig.14 :** A photograph of a section in the renal medulla of control albino rat aged two weeks old showing the loop of Henle(LH). Also the collecting tubule (CT) are seen . ( Hx&E.; X 400)



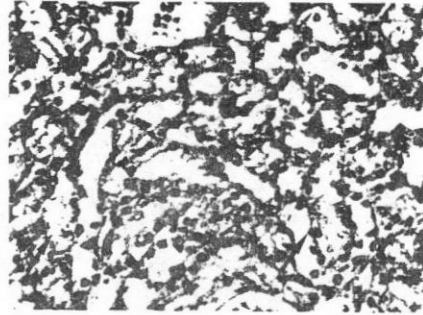
**Fig.15 :** A photograph of a section in the renal cortex of control albino rat aged two weeks old showing a strong positive PAS reaction in the apical part of the proximal convoluted tubules (P). Notice the basement membrane of the Bowman's capsule ( ), the parietal layer of Bowman's capsule (<<) and the distal tubules are also strongly PAS- positive (PAS.;x400)




**Fig.16 :** A photograph of a section of the kidney of control albino rat aged two weeks showing marked diminution of collagenous fibers around the glomerulus and the convoluted tubules (arrows). (Mallory; x 400)



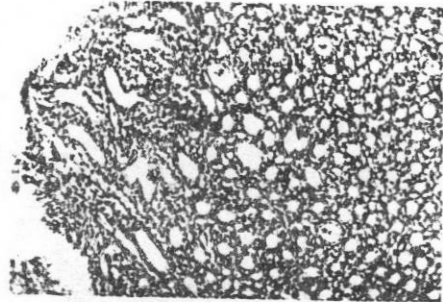
**Fig.17 :** A photograph of a section in the renal cortex of malnourished albino rat aged two weeks showing, degenerated renal corpuscles in the form of shrunken glomeruli (arrow) with marked increase in their capsular spaces (s). (Hx&E.;x200)



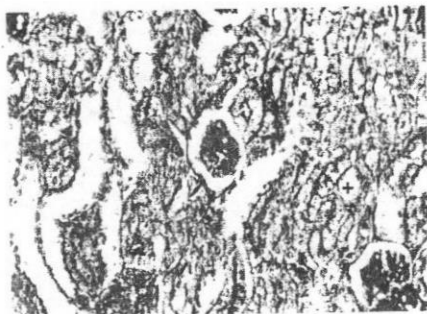**Fig.18 :** A photograph of a section in the renal medulla of malnourished albino rat aged two weeks showing, the degenerated renal corpuscle in the form of bulging of parietal layer of Bowman's capsule ( arrow ) and fragmentation of the capillary tuft (crossed arrow). (Hx&E.; x 400)



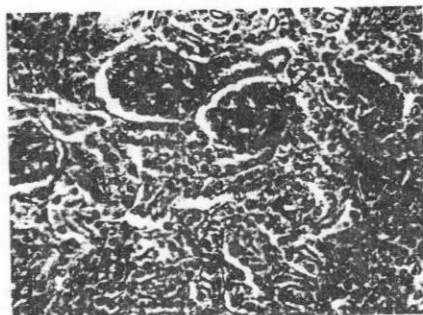
**Fig. 19 :** A photograph of a section in the renal cortex of malnourished albino rat aged two weeks old showing degenerated renal tubules with dilated lumen (arrow) with disruption of their lining epithelium and vacuolated cytoplasm. a remnants of cytoplasm (crossed arrow) and nuclei were detected inside their lumen. (Hx&E.; x400)



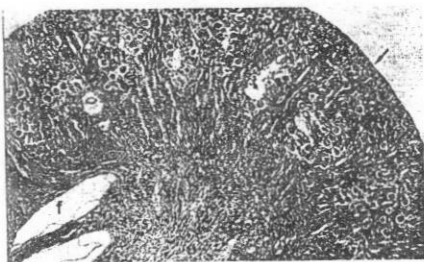
**Fig. 20 :** A photograph of a section in the renal medulla of malnourished albino rat aged two weeks showing marked dilatation of the collecting tubules (ct) with appearance of cellular debris inside their lumen (stare). (Hx&E.; x400)



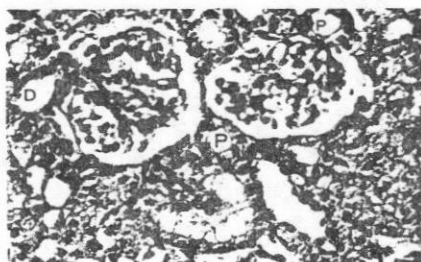**Fig. 21 :** A photograph of a section in the renal cortex of malnourished albino rat aged two weeks showing a weak positive PAS reaction in the apical brush border of the proximal tubule (arrow), also the basement membrane of the glomeruli (crossed arrow), the parietal layer of Bowman's capsule and that of distal tubules (+) showed a very weak positive PAS reaction. (PAS.; x400)



**Fig.22 :** A photograph of a section of the kidney of control albino rat aged two weeks showing marked increase of collagenous fibers around the glomerulus and the convoluted tubules (arrows). (Mallory; x 400)

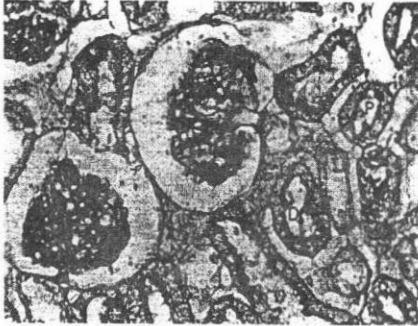


**Fig.23 :** A photograph of a section of the kidney of control albino rat aged one month old showing the cortex ( C ) which are covered by thin connective tissue capsule (arrow) . Notice the appearance of secondary fornix ( f ) . ( Hx&E.; x 50 )

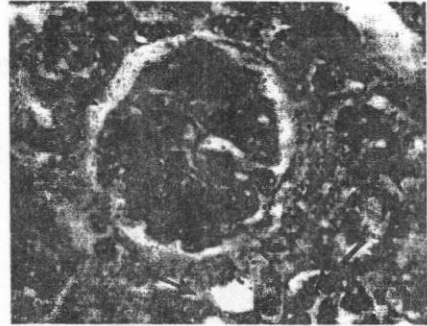


**Fig. 24 :** A photograph of a section in the renal cortex of control albino rat aged one month showing mature renal corpuscle (arrow) with lobulated less cellular glomerular tuft . Also the proximal tubule (P) and distal tubule (D) appeared normal. (Hx&E.; 400)

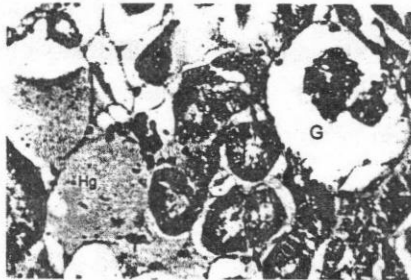



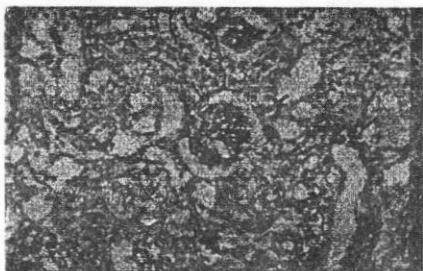
**Fig.25 :** A photograph of a section in the renal cortex of control albino rat aged one month showing a strong positive PAS reaction in the apical part of the proximal convoluted tubules (P). Notice the basement membrane of the Bowmen's capsule ( + ), the parietal layer of Bowman's capsule (<<) and the distal tubule(D) are also strongly PAS-positive reaction . (PAS.;x400)



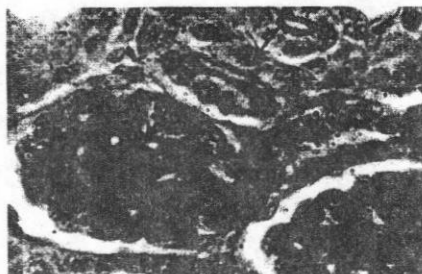
**Fig.26 :** A photograph of a section in the renal cortex of control albino rat aged one month showing a scanty amount of collagenous fibers around the glomerulus and the convoluted tubules( arrow ) . (Mallory. X 1000)



**Fig.27 :** A photograph of a section in the kidney of malnourished albino rat aged one month old showing marked shrunken glomerulus (G) with wide Bowman's space which contain a remnant sloughing of their endothelial lining some areas , the renal tubules(crossed arrow &+) ,lost their identity and appeared open into one another(arrow) . Notice the appearance of focal area of haemorrhage (HG) . (Hx&E.; x 650)



**Fig.28 :** A photograph of a section in the renal cortex of malnourished albino rat one month old showing a weak of PAS reaction in the Bowman's capsule (crossed arrow) and basement membrane of the proximal tubule (arrow) and the distal tubule(+). (PAS.; x 400)



**Fig.29 :** A photograph of a section in the renal cortex of malnourished albino rat one month old showing marked increased in collagenous contents in the glomeruli (arrow) and around the tubules (crossed arrow) as compared with the control one. (Mallory.; x 1000)

### DISCUSSION

In the present study, the body weight of the control animals increased gradually with age, while in the malnourished ones it showed a marked decline compared with the control one. This came in agreement with the reports of Kyong et al., (2003) who concluded that in the maternal malnutrition the body weights of the offspring were usually decreased.

In the present work the kidney weight in the malnourished animals

showed marked reduction when compared with the control animals. Similar observation was reported by Wilson (1991) and Langley (2001) who studied the effect of malnutrition on the postnatal development of the kidney:

In this study the kidney of one-day-old albino rat was unipyramidal or unilobular and a primary pyramid was observed. El-Hessy (1985) recorded that the primary pyramid appeared at the 20th day of prenatal life and became more apparent in

the neonatal rat, while Nossier (1989) demonstrated it at the 5<sup>th</sup> postnatal day and described it as globular rather than pyramidal. The controversial dates at which the primary pyramid could be noticed was explained by to be due to the different strains of the rats used by the different authors Wassif (1991).

The appearance of secondary fornices was noted in this study at the first postnatal month. Again different dates were reported by different authors regarding the appearance of the secondary fornices. So while Wassif (1991) mentioned that the secondary pyramid and fornices were noted at the 3<sup>rd</sup> postnatal week, Trimble (1970) and Nossier (1989) recorded that the secondary fornices started to appear by the 10<sup>th</sup> postnatal day and became well developed by the 20<sup>th</sup> day.

According to the presence of the secondary pyramid and secondary fornices, Pfeiffer (1968) classified the renal pelvis into two types; type one which was simple uncomplicated without secondary fornices, fold or extension and founded in water and

land animal of the rat family which bulds dams across streams, while type two was more extensive with specialized fornices and founded in man and adult rat.

In the present work, numerous subcapsular nephrogenic structures of basophilic cells (nephrogenic zone) were demonstrated in the one-day-old rat. These structures vary in shape from oval to rounded or elongated. They were invaginated by blood vessels to form the renal tubules and renal corpuscles. This description of nephrogenic structure in the kidney at birth coincided with that reported by Potter (1972), Arey (1974), Fris (1980), Wassif (1991) and Abou El-Nagga (1997). In that respect, El-Hessy (1985) demonstrated solid nephric primordia, hollow nephric vesicles and S-shaped segments in the rat kidney at 16<sup>th</sup> day parentally. These segments increased markedly by the 18<sup>th</sup> day. At the 20<sup>th</sup> prenatal day nephron in all stages of development were observed and at birth (neonate kidney) immature glomeruli together with some developed ones were present.

Lackovic and Mujovic (1980) and Abou El-Nagga (1997), mentioned also that, in rat, the nephrogenic zone was distinguished at 1st day after birth and was the most dominant part of the cortex of the kidney. There was only one row of differentiated juxta-medullary situated glomeruli. At the 2nd day, more mature glomeruli were arranged in two or three rows. By the 3rd to 5<sup>th</sup> day the nephrogenic zone was reduced with an increased in number of mature glomeruli.

Fris (1980) also observed in newly born pig, a thin nephrogenic zone in which nephrons were divided into many stages of development, first stages corresponded to the renal vesicle in which the glomerular analogue could be distinguished from the tubular analogue. The second stage of development corresponded to the transformation of renal vesicles to S-shaped, and then the third stages the glomerulus was spherical or oval with a distinct Bowman's space. But in the malnourished animals the nephrogenic zone appeared small in size, congested and degenerative changes were more observed when compared with control animals.

The thickness of the nephrogenic zone in the malnourished animals decreased compared to those observed in the control animals. The nephrogenic zone could be observed in two weeks old rats of control and malnourished animals. However, differentiation of nephrons continued till the 3rd week with very few undifferentiated renal corpuscles that lack Bowman's space. The formation of new nephrons during postnatal life in most mammals had previously been reported by Nash and Edelmann (1973). In this respect, Lackovic and Mujovic (1980) and Abou El-Nagga (1997) mentioned that in the rat, nephrogenesis was completed by the 15th postnatal day and the number of glomeruli was the same as in the adult.

From the data in this study, the kidney of early postnatal life was unable to concentrate urine till the 4<sup>th</sup> week. These data included the presence of subcapsular nephrogenic zone with less developed nephrons.lacking Bowman's space, absence of the lumen of the majority of the proximal and distal convoluted tubules as well as absence of secondary pyramid and secondary fornices.

This is in agreement with the result of Trimble (1970) and Abou El-Nagga (1997) who mentioned that the kidney was unable to concentrate urine until the 20<sup>th</sup> day of postnatal growth when secondary pyramid and secondary fornices were well developed. Moreover, Siptzer and Brandis (1972) reported that, the urine was highly concentrated after the 15<sup>th</sup> postnatal day when the nephrogenic zone disappeared and the nephrons were completely developed.

In the pig, Fris (1980) recorded that the kidney produced concentrated urine at the 3rd postnatal week when well-developed nephrons were reached. At one day postnatally, it was noted in the present work that, the degree of maturity of the renal corpuscle increased toward the medulla (corticomedullary area). Similar finding were reported by Potter (1972), Nash and Edelman (1973), El-Hessy (1985) and Abou El-Nagga (1997).

Cormack (1987) also mentioned that the first formed glomeruli, which were the largest, lied near the arcu-

ate vessels, where as the last formed glomeruli lied in the outer cortex immediately under the capsules, these outermost glomeruli were the smallest in the kidney. Wassif (1991) and Abou El-Nagga (1997) mentioned that, the more differentiated renal corpuscles were present in the corticom-edullary zone.

The present study revealed that in the control animals, the glomerulus appeared to be formed of a mass of polygonal cells enclosed very narrow capillary lumina, and surrounded by a single layer of radially arranged columnar cells represented the visceral layer of Bowman's capsule the parietal layer was formed of cubical cells. With more maturation the columnar cells of the visceral layer of Bowman's capsule became intermingled with and not differentiated from the glomerular cells. Similar results were given by Fris (1980).

In 14 - 21 days old rats, the nephrogenic zone was no more observed. The parietal layer of Bowman's capsule was formed of flat squamous cells, but occasionally some low cubical cells could be seen in the outer-

most located corpuscles. These cubical cells became flat squamous in adult rats. As regards the glomerular changes, in (14-21) days old rats, the glomeruli were seen spherical in shape formed of less dense cellular masses of polygonal cells with slight increased in their capillary lumen.

In this work, the renal corpuscles of malnourished animals showed degenerated changes which occurred at the age of one day with gradual increase in severity until the adult age. These changes were in the form of irregular Bowman's capsule, dilated, irregular capsular space, congested glomerular tuft with appearance of cleft in between, sort of haemorrhage, complete or partial disintegration of the glomerular tuft, partial or complete lose of parietal epithelium. Similar degenerative changes were reported in the kidney of malnourished animals by Di Tommaso et al (2002).

Snell (1984) stated that, the function of renal corpuscles in the glomerular filtration of plasma with practically no proteins so that the damage of glomeruli by number of diseases and malnutrition lead to complete degen-

eration of the glomeruli this lead to block of filtration which end by chronic glomerulonephritis, renal hypertension and chronic renal failure.

In the present study the macula densa could be distinguished in young rats 7- 21 days old in some of the distal convoluted tubules as cubical cells with rounded not so closely packed nuclei. It became columnar cells with closely packed oval nuclei in two month old rats and later, on the contrary, Vesna and Spomenka (1980) proved that, the macula densa cells which appeared cubical in one day old rats, became slightly taller than other epithelial cells of the distal nephron in the second day after birth and completely differentiated into cylindrical cells with closely packed elongated nuclei in two weeks old rats .

The majority of the proximal convoluted tubules in this study were found having no lumina at one week but some of them possessed a narrow lumen with brush border due to presence of the microvilli. By the age of two weeks most of them acquired the adult form.



Fris (1980) noticed that in the newborn pig, the proximal convoluted tubules had the same structural appearance of the renal vesicle cells and formed the irregular apical cell surface small prospective microvilli (brush border) protruded into the lumen. In advanced age, the cells of the proximal tubules had decreased in height and their initial diameter had increased. At the 4th postnatal week the proximal convoluted tubules acquired a brush border of constant width.

The proximal convoluted tubules of the malnourished animals decreased in number and showed degenerative changes that increased gradually from one day postnatally to adult age. The changes were in the form of crowded adherent tubules, desquamation of their lining epithelium with dilatation of their wall and lost of the apical brush border and absence of some nuclei. The vacuoles increased in severity in advanced ages with sloughing of many cells and haemorrhage between the tubules. Similar results were given by Di Tommaso et al. (2002) who stud-

ied the effect of vitamin B6 deficiency on the kidney of albino rat.

The function of the proximal tubules were reabsorption of 65% of glomerular filtration (water, Na, CL, glucose, amino Acids, Ca, K, Po<sub>4</sub> and vitamin C and excretion of creatinine, iodine compound and penicillin (Snell, 1981). When the tubules were exposed to malnutrition tubular necrosis might appear and led to an increased concentration of urinary salts, decreased production of the urinary colloid, which might form renal stones and end by chronic renal failure.

Di Tommaso et al. (2002) founded also that, the histological feature of kidney of vitamin B6 deficiency in rat were those of tubular-interstitial nephritis, characterized by tubular atrophy. The function of distal tubules was the reabsorption of 10 % Na, CL, H<sub>2</sub>O and secretion of NH<sub>4</sub>, H, K. So that in the malnutrition it led to a tubular necrosis which also end by chronic renal failure (Snell, 1984).

Malnutrition led to degenerative changes in these tubules added to

failure in the kidney function. The interstitial connective tissue between the renal corpuscles and different parts of the renal tubules was abundant in the early stages of development (one day postnatal) and decreased with the advance of age. Trimble (1970) found also that in 10-day-old rat, the interstitial connective tissue was more abundant and decreased with age being very minimal at the 20-day old rat. Malnutrition causes an increase in the amount of interstitial connective tissues, which seemed to replace the degenerating parenchyma of the kidney.

## REFERENCES

1. **Able, E. L. (1990)** : Effect of paternal and maternal undernutrition on growth of offspring in rats. Wayne State University, Detroit, Michigan. *Growth. Dev. Aging* . Fall; 54 (3): 125-9.
2. **Abou- El. Naga , M. A. (1997)** : Postnatal development of vascularity and effect of alcohol on the kidney of albino rat ", M.D. Thesis, Faculty of Medicine Al -Azhar University -Assiut.
3. **Arey , L.B. (1974)** : "Developmental Anatomy Revised ". 7<sup>th</sup> ed. W .b. Saunders Company, Philadelphia and London ., pp: 303-305.
4. **Chopra, J.S.(1991)** : Neurological consequences of protein and protein calorie undernutrition. *Crit. Rev. Neurobiology.*, 6:299-177.
5. **Cormack , D.H. (1987)** : Ham's Histology. Ninth edition. J.B. Lippincott Company .Philadelphia ., P. 588.
6. **Desai, M.; Crowther, N. J.; Lucas, A.; Hales, C.N. (1996)** : Organ -selective growth in the offspring of protein restricted mothers. Department of Clinical Biochemistry, University of Cambridge, Addenbrooke's Hospital, USA. . *Br.J. Nutr.* Oct; 76 ( 4) : 591-603.
7. **DI Tommaso, L.; Tolomelli, B.; Mezzini, R.; Marchetti, M.; and Cenacchi, G. ( 2002)** : Renal calcium phosphate

- and oxalate deposition in prolonged vitamin B6 deficiency: studies on a rat model of urolithiasis. *BJU. Int. Apr*; 89 (6): 571-575.
8. **El-Hessy, H.M. (1985)** : Experimental studies on the developing rat tissues following snake envenomation with special reference to kidney and adrenal. Ph.D. Thesis, Faculty of Medicine, Ain Shams University.
  9. **Fan, J and Zhu ,Q . (1999)** : Effect of vitamin A deficiency on the development and growth of rat embryos). *Wei. Sheng . Yan . Jiu . Jul* ; 28(4): 235- 6.
  10. **Fris, C. ( 1980)** : Postnatal development of the pig kidney: Ultrastructure of the glomerulus and the proximal tubule. *J. of Anatomy.*, (130) 513 -526.
  11. **Griggo, M.A.; Luiz, J.; Gorgulho, A.A . and Sucasas, C.M. (1997)** : The influence of food restriction during different periods of pregnancy. *Int. J. Food Sci.Nutr. Mar*; 48 (2) : 129- 34.
  12. **Hasanien, N.H. (1993)** : Postnatal study of rat kidney and developmental changes following cadmium administration, M.D. Thesis. Faculty of Medicine, Mansoura University.
  13. **Hinchelife, S.A., Lynch, M.R.J., Sargent, P.H., Howard, C.V. and Van Velzen, D. (1992)** : The effect of intrauterine growth retardation on the development of renal nephrons .*British Journal of Obstetrics and Gynecology.*, 99, 296-301.
  14. **John, S.C. and Lewis, A.B. (2000)** : *Nelson A Text Book of Pediatrics.*, P : 169.
  15. **Jones, S.E.; Nyengaard, J. R.; Flyvbjerg, A.; Bilous, R.W. and Marshall, S.M. (2001)** : Birth weight has no influence on glomerular number

and volume. *Pediatric Nephrol*, 2001 April; 16 (4):340-445.

(1980) : Postnatal development of the kidney juxtamedullary apparatus in rats. *Acta Anat.*, 108:281-287.

16. **Joshi, S., Garolve, V., Daware, M., Girigosavi, S .and Rao, S. ( 2003 )** : Maternal protein restriction before pregnancy affects vital organs of offspring in wistar rats. *metabolism*. 2003 Jun; 52 (1):13-18.
17. **Kind ,K. L.; Simonetta, G.; Clifton, P. M.; Robinson, J .S.; and Owens, J. A. ( 2002 )** : Effect of maternal feed restriction on blood pressure in the adult guinea pig. *Exp. University of Adelaide, SA. Physiol.*, Jul: 87 (4): 469 -77.
- 18 . **Kyong ;S.P.; Suk, K.K.; Min, S.K.; Fun, Y.C. (2003 )** : Fetal and early postnatal protein malnutrition cause long- term changes in rat liver and muscle mitochondria . *J . Nutr .* 133 : 3085 - 3090 .
19. **Lackovic, V. and Mujovic, S.**
20. **Langley -Evan , S.c (2001)** : Fetal programming of cardiovascular function th rough exposed to maternal under-nutrition .*Proc. Nutr. Soc .* Nov ; 60 ( 4) : 505 -31 .
21. **Lesson, T.S. (1957)** : The structure of mesonephros of the 17 - day's rabbit embryo. *Exp. Cell. Res.*, 12:670-672.
22. **Mortiz, K.M.; Dodic, M. and Wintour, E. M. ( 2003 )** : Kidney development and the fetal-programming of adult disease. *Bioessays .* Mar ; 25 ( 3) : 212 -20 .
23. **Murillo, F.L.; Artillo, R.; Carerras, O. and Murillo, L . (2001)** : Effect of maternal chronic alcohol administration in the rat : lactation performance and pups growth . *Eur .J . Nutr .* Aug ; 40 (4) : 147 -54.

24. **Nash, M.A. and Edelmann, C.M.** (1973) : The developing kidney . *Nephron* .,11:71 -90.
25. **Nossier, E.E.** (1989) : "Postnatal study of the anatomy and histology of the renal pelvis of the albino rat .M.Sc. Thesis. Faculty of Medicine, Ain Shams University.
26. **Paixao, A.D.; Maciel, C.R.; Teles, M.B. and Figueiredo, F.J.** (2001) : Regional Brazilian diet- induced low birth weight is correlated with changes in renal hemodynamics and glomerular morphometry in adult age. *Biol Neonate.*; 80(3) : 239-46.
27. **Pfeiffer, E.W.** (1968) : " Comparative anatomical observation of the mammalian renal pelvis and medulla. *J. Anat.*, 102 (2) : 321 -331.
28. **Potter, E.L.** (1972 ) : " Normal and abnormal development of the kidney .Chicago: Year book Medical Publisher Incorporated.
29. **Snell, R.** (1981) : "Clinical Anatomy for Medical Students" 3rd Ed., Brown and Company, Boston, Toronto.
30. **Snell, R.** (1984) : *Clinical and Functional Histology*, 1st ed. Brown and Company. U.S.A.
31. **Spitzer, A. and Brandis, M.** (1972) : "Superficial nephron and total kidney glomerular filtration in rat during development " *Pediatr. Res.*, 6 : 126 .
32. **Timofeeva, N. M.; Gordova, L. A.; Egorova, V.V.; Nikitina, A.A and Iezuitova, N.** (2002) : Delayed effects of protein deficiency in nutrition of the pregnant rats on development of the enzymatic system in digestive and nondigestive organs of offspring. *Russ. Fiziol. Zh. Im. Sechenova.* Aug; 88 (8) : 1028- 35.
33. **Tredici, G.; Buccellato, F.R; Braga, M.; Cavaletti, G.;**

- Ciscato, P; Moggio, A. and Scalabrino, G. (1998)** : Polyneuropathy due to cobalamin deficiency in the rat. *J. Neurol science* ., 156:1, 18-29.
- 34. Trimble, M.E. (1970)** : Renal response to solute loading in infant rats : relation to anatomical development. *Am. J. Physiol.*, 219 : 1089 - 1097 .
- 35. Vesna, L. and Spomenka, M. (1980)** : Postnatal development of the kidney juxtaglomerular apparatus in rats. *Acta. Anatomy.*, 108 : 281.
- 36. Wassif, G.A. (1991)** : "Study of the postnatal growth of the kidney of the albino rat ", M.S. Thesis, Faculty of Medicine, Ain -Shams University.
- 37. Wilson, G. Pond.; Ralph, R. Maurer and John Klindt . (1991)** : Fetal organ response to maternal protein deprivation during pregnancy in swine .*J. Nutr.*, 121: 504 -509 .
- 38. Woodall, S. M.; Breier, B .H.; Johnston, B. M. and Gluckman P, D. (1996)** : A model of intrauterine growth retardation caused by chronic maternal undernutrition in the rat : effects on the somatotrophic axis and postnatal growth. *J. Endocrinol* . Aug; 150 ( 2) : 231-42 .
- 39. Young, B.; Heath, J.W.; Stevens, A.; Lowe, J.S.; Deakin, P.J. (2000)** : *Weather's Functional Histology. A text and color atlas. 4<sup>th</sup> edition.*, Churchill Livingstone, Edinburgh, London, New York, Philadelphia, Sydney, Toronto, PP : 286- 288.

## الملخص العربي

### نمو الكلية بعد الولادة في الفئران البيضاء السليمة والمتعرضة لسوء التغذية

أحمد عمر إبراهيم ، مصطفى السيد محمد الجيزاوي \*

مصطفى أحمد أبو النجا، فوزي محمود أبو جلاله\*\*

\*قسم التشريح بكلية طب بنين - جامعة الأزهر

\*\*قسم التشريح بكلية طب بنين دمياط - جامعة الأزهر

أجرى هذا البحث على ٥٠ فأر أبيض تتراوح أعمارهم من حديثي الولادة حتى الشهر الأول لدراسة تطور الأنسجة الكلوية وتأثير سوء التغذية عليها .

وقد قسمت الفئران إلى مجموعتين :

المجموعة الأولى : وتشمل ١٥ حيوان أمهات ( ضابطة ) كانت تتغذى علي خبز ولبن وماء من اليوم الأول للحمل وحتى بلوغ الصغار

المجموعة الثانية : وتشمل ١٥ حيوان أمهات كانت تتغذى علي النشا والسكر والماء فقط ( سوء تغذية) وذلك من اليوم الأول للحمل وحتى الشهر الأول.

تم وزن الحيوان بعد قتله وكذلك الكليتين في اليوم الأول من الولادة والأسبوع الثاني والشهر الأول. ثم حُقن العينات المعالجة والسليمة بمحلول فورمالين ١٠% ثم تم تحضير العينات وصبغت مقاطع البرافين بصبغة الهيماتوكسلين والأيوسين إلى جانب البيرايدوك أسيد شيف وصبغة مالوري وتم دراستها بالميكروسكوب التشريحي المجهرى لدراسة تطور الأنسجة الكلوية وتأثير سوء التغذية عليها وقد لوحظ انخفاض في وزن الجسم وكذلك وزن الكليتين بدرجة ملحوظة في الفئران المعرضة لسوء التغذية وتبين بالدراسة التشريحية زيادة متدرجة لحجم وعدد الأنبيات الملتوية والحوصلات الكلوية مع التقدم في العمر.

وبدراسة تطور الأنسجة الكلوية وجد أن كلية الفأر الأبيض تتكون من فص واحد تشتمل على قشرة ونخاع خارجي (ما تحت القشرة ) أو نخاع داخلي ( الهرم الكلوي ) وان هذا التركيب ظهر في اليوم



الأول بعد الولادة وقد بدأ الهرم الكلوي في الظهور في اليوم الأول واستمر في النمو في الأسبوع الثاني حتى الرابع حيث أخذ الشكل الهرمي المماثل لعمر الفأر الأبيض وقد لوحظ في هذه الدراسة في اليوم الأول بعد الولادة كتلة أولية تحت القشرة تتكون من عدد من الأشكال الدائرية إلى البيضاوية كما أخذت أيضا شكل S وكانت مجوفة من طرف ومصمتة في الطرف الآخر وقد اختفت هذه الكتل في الأسبوع الثاني بعد الولادة ووجد اختلاف في نمو الحويصلة الكلوية من اليوم الأول بعد الولادة وحتى الأسبوع الرابع وكانت الحويصلات الكلوية الناضجة تقع بجوار الكلية بينما الحويصلات قليلة النضج كانت توجد في الجزء الخارجى من القشرة وكانت تفتقد إلى تجويف (بومان). وفي هذه الدراسة أيضا بفحص الأنبيات الدانية الملتوية المبطننة لخلايا مكعبة ليس لها تجويف في اليوم الأول بعد الولادة وكانت هذه الخلايا تحتوى على سيتوبلازم حبيبي وحامض الأصبغ مع وجود أنوية قاعدية الأصبغ وحافة ذات قطيفية واستمرت هذه الأنبيات في النمو حتى الأسبوع الثاني عندما أصبح لجميعها تجاويف.

أما الجزء النازل الرفيع من عروة (هنل) فهو مبطن بالخلايا الطلائية المفلطحة بينما الجزء الصاعد للعروة المبطن بخلايا مكعبة.

الأنبيات القاصية الملتوية تكون كاملة النمو من اليوم الأول بعد الولادة و مبطننة بخلايا مكعبة وتتفقد إلى الحافة القطيفية علاوة على ذلك لوحظت البقعة الكثيفة والتي تتميز بوجود أنوية معتمة كثيفة العدد في خلايا الأنبيات القاصية نتيجة تقاربها من القطب الدموى للحويصلة الكلوية . أما الأنبيات الجامعة المبطننة بخلايا مكعبة فقد افتقدت الى الحافة القطيفية وأخذت شكلا قوسيا في الطبقة القشرية وطوليا ومستقيما في الطبقة النخاعية لتكون الأشعة النخاعية التي امتدت الى القشرة وذلك مع بعض أجزاء من عروة هنل في المراحل الأولى للنمو، كما كان النسيج الضام الموجود بين الحويصلات الكلوية الأنبيات الكلوية موجود بكثرة وأصبح صعب الرؤية بعد الأسبوع الثاني بينما لوحظ فقط على امتداد الأوعية الدموية.

وتبين الدراسة المجهرية التأثيرات الضارة الناتجة عن سوء التغذية علي الأنسجة الكلوية فوجد أن الكتلة الأولية تحت القشرة أقل في الحجم والعدد بالمقارنة بالمجموعة الضابطة.

وقد وجد أن الحويصلات الكلوية قد تأثرت بشكل ملحوظ بسوء التغذية من أول يوم بعد الولادة ثم بدء يزداد تقدمها المرضى مع تقدم العمر وظهر هذا التغيير في صورة نقص الحجم وتكسیر في الغطاء الخارجى للحويصلة الكلوية وفقدان تجويف (بومان) واحتقان الأوعية الدموية

للحويصلة الكلوية وقد زاد هذا التفسير مع تقدم العمر في صورة ظهور شقوق بين الأوعية الدموية للحويصلة الكلوية حتى أن بعض منها اختفى تماما بالكلية. أيضا وجد أن الأنبيات الدائنية المتوية ظهر فيها تكسر وتهتك في الخلايا المبطنة لها وظهرت تجاوزيف غير عادية داخل هذه الأنسجة كما ظهر ضيق وعدم انتظام في القطر الداخلى وتكسر الانثناءات القاعدية للخلايا. كما لوحظت هذه التغييرات في الأنبيات القاصية المتوية وكذلك في الأنبيات الجامعة وأصبحت صفاتهم المرضية ظاهرة عن مثيلتها السليمة ولوحظ أيضا ظهور تغييرات مرضية حادة في النخاع الكلوى في صورة وجود نزيف دموى وزيادة مطردة في الخلايا التهابية.

ونستنتج من هذا البحث أن لسوء التغذية على الأم الحامل تأثير ضار وخطير على تطور كلية الأبناء مما قد يتسبب في المستقبل في حدوث فشل كلوى مزمن مع ارتفاع في الضغط. فينصح بتحسين الوضع الغذائى للأم أثناء الحمل.

