

UNILATERAL SECONDARY (ACQUIRED) POST MASTOIDECTOMY LOW SET EAR. A RARE COMPLICATION WITH POTENTIAL FUNCTIONAL AND COSMETIC IMPLICATIONS.

By

Mahmoud El-Sayed Ali, MSc, FRCS, MD

From

ENT Department Mansoura University Hospital

ABSTRACT

Introduction : Low set ear was not recognized as a complication of post-aural and end-aural incisions utilized in mastoidectomy before. It can cause cosmetic and functional implications.

Objective : This paper emphasis that post-operative low set ear is a potential complication which needs to be recognized and discussed with patients pre-operatively.

Setting : Two ENT clinics in 2 tertiary care referral hospitals

Method : Post mastoidectomy review patients seen by one ENT specialist throughout 5 years. Out of 942 post mastoidectomy reviews, 10 cas-

es of low set ear were found and are described. Case histories are analyzed and potential predisposing and precipitating factors are discussed.

Results : All cases had chronic middle ear infection. This condition can develop after one operation and can be recognized as early as one week post-operatively. Seven cases have noted some post-operative auricular changes. This condition results from weakening of supportive elements which keep the auricle in normal position

Conclusion : Low set ear should be recognized as a potential complication following post and end aural approached to middle ear surgery. Care should be taken to try and avoid its development.

INTRODUCTION

Low set ear is a rare condition, usually of congenital (primary) aetiology, in which the auricle develops at a lower level than normal. Primary bilateral low set ears are found in a number of congenital anomalies such as trisomy 21, 13, 14, 15, 18, Turner syndrome (XO) with gonadal dysgenesis¹ and IMAGE syndrome (intrauterine growth restriction, metaphyseal dysplasia, adrenal hypoplasia congenita, genital abnormalities²). Unilateral low set ear is more likely to attract attention and have cosmetic and functional implications than bilateral (usually congenital) low set ear.

Post mastoidectomy secondary (acquired) low set ear has not been reported before in the English literature. After the author of this article had noticed his first case of post mastoidectomy low set ear, he looked for this complication in all the post mastoidectomy patients he reviewed in his ENT clinic along 5 years. Ten cases were identified by the author and are described in this article.

This is not an exhaustive study of the incidence of post mastoidectomy

low set ear. The main aim of this article is to direct the attention of ENT surgeons to this rare complication. This could help to improve the preoperative consenting process. The article also aims to analyze potential factors which might have contributed to the development of post mastoidectomy low set ear and to discuss possible ways to avoid its development. As far as the author knows, this is the first detailed report and analysis of such a complication in English Literature.

PATIENTS AND METHODS

Post operative low set ear was looked for in all patients reviewed in the ENT outpatient clinic, by a single ENT specialist. During routine clinical interview, the author inspected patient's face from the front in the setting position. Toward the end of the interview and when the operated ear was noticed to be lower than the non operated ear, the patient was asked if he/she had noticed any post operative changes in the operated ear pinna or whether he/she had any other problems which could have developed after having his/her ear operation. Cases included in the study are

patients who came for post operative care at different times, from early to late post operative follow up. All patients had mastoid surgery as the surgical treatment modality to clear chronic suppurative otitis media with cholesteatoma. The study period span a total of 5 years, 1 year spent in one clinic and 4 years in the other clinic in another tertiary referral hospital.

The studied patients do not represent an exhaustive list of mastoidectomy cases reviewed in one particular ENT out patient department or all mastoidectomy operations in a particular hospital. They only include patients reviewed by one ENT specialist and therefore a conclusion of the true incidence of post operative low set ear can not be drawn. The reported cases of post operative low set ear presented in this article are illustrative of such a post mastoidectomy complication which needs attention to be paid to its existence, how it developed and how to try and avoid its development.

RESULTS

Out of a total of 942 post mastoi-

dectomy review patients seen in the 2 clinics (298 in the first clinic seen along one year and 644 in the second clinic seen along 4 years), 10 cases of unilateral secondary low set ears (4 from first clinic and 6 from second clinic) were identified. This series includes 8 males and 2 females.

Reported cases

The 10 cases are divided into 2 groups, 5 cases each; according to the side of low set ear.

Group 1 : Right side low set ear.
(Figure 1).

Case 1

This is a 22 year old man who had right mastoid exploration and myringoplasty through an end-aural incision. He was left with a dry ear and slight right facial weakness and a residual right drum perforation and a right low set ear. A few months after the operation, he noticed that he frequently needs to readjust the right side of his spectacle and right eyepiece. Cartilaginous ear canal has rotated in an anticlockwise direction around a fulcrum at the osteo-cartilagenous junction.

Case 2

This is a 35 year old man who had right tympanoplasty for attic cholesteatoma via an end-aural incision. Three week postoperatively, he stated that he has noticed that his right auricle looks lower than the left one and that he is no longer able to hold a pencil over his right ear pinna as he used to do before. He was rather unhappy. The low set right auricle has rotated anticlockwise with the upper edge protruding laterally more than the left side.

Case 3

This is a 55 year old man who had mastoidectomy 10 years beforehand via an end-aural approach. When he was reviewed for regular mastoid cavity microsuction, he stated that when he wears his glasses, he frequently needs to readjust the position of the eyepieces to maintain a comfortable vision and sensation of the spectacle over his nasal bridge and in front of his eyes.

Case 4

This 60 year old man had radical mastoidectomy at the age of 9 via a post-auricular incision. The low set

right auricle is slightly rotated anticlockwise. He was not aware of the different position of the right auricle. Knowing this, he had no concerns as the low set right ear was not causing him any trouble.

Case 5

This 78 year old man quoted having 15 ear operations including several mastoidectomy operations on both sides and bilateral meatoplasty. He could not recall which ear had more surgical interventions. However, as the right auricle was lower (inferiorly displaced) than the left, he might have had more surgical interventions on the right side in the past.

Group 1 : Left side low set ear.
(Figure 2).

Case 6

This is a 65 year old lady who, along a period of 5 years, had 4 left mastoid explorations utilizing post-aural incisions and 3 meatoplasty operations one of which involved post aural incision. Her left auricle has dropped more than 2 cm in the coronal plane. The patient was aware of the low position of the left auricle particularly on wearing her spectacles

when the horizontal bar of the spectacle becomes tilted and needs frequent readjustment.

Case 7

This is a 40 year old man who, 4 years beforehand, had left tympanoplasty through an end-aural incision. He was aware of the abnormal position and inferior displacement of the left auricle but this did not cause him any concerns. He was reviewed for routine mastoid cavity inspection and microsuction.

Case 8

This 83 year old man had right mastoidectomy at the age of 11 followed by left mastoidectomy at the age 21. Both operations utilized post-auricular incisions with canal wall down mastoidectomy. The low set left auricle was slightly shorter than the right one. Due to the bilateral ear surgery, it is not possible to decide if the left auricle was inferiorly displaced as well.

Case 9

This 39 year old lady had left mastoid exploration at the age of 22 followed 1 year later by ossicular recon-

struction. Revision tympanoplasty was performed at the age 26 through a post aural incision with canal wall down approach. She was aware of the inferior displacement of the left auricle and expressed her concerns with its new appearance.

Case 10

This 9 year old boy had left mastoid exploration at the age of 8. One year later, he had a modified radical mastoidectomy with meatoplasty. Both operations were performed via post-aural approach. The left low set ear was noted 9 days after the second operation in the first postoperative visit. The left auricle was also more protruding and slightly clockwise rotated in anterior view. The child's mother said that she had already noted the lower position of the operated ear a few days beforehand and expressed her concerns with this.

In summary all the 10 patients had mastoidectomy for the treatment of chronic middle ear infection. The post aural approach was employed in 6 cases (4-6, 8-10) and end aural approach in 4 (1-3, 7). The first case had the post aural incision five times.

The posterior bony ear canal wall was preserved (canal wall up mastoidectomy) in 3 cases (1, 2, 7) while it was drilled away (canal wall down mastoidectomy) in the remaining 7 cases. In 3 cases (1, 2, 8), the operated auricle was slightly shorter in longitudinal dimension than the non operated auricle. Three cases (4, 5, 8) were not aware of any abnormalities of the auricle while the remaining 7 cases

were aware of some postoperative auricular changes. Of these, 5 cases (2, 6, 7, 9, 10) have noted that the auricle on the operated ear was inferiorly displaced. Case 2 and 9 were unhappy with this displacement and expressed her concerns about it and the mother of case 10 was worried about the future management of her child's low set ear.

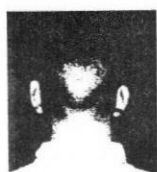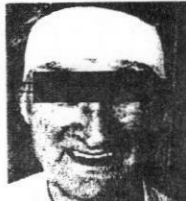**Case 1****Case 2****Case 3****Case 4****Case 5**

Figure 1. The first group of 5 cases who had right post-mastoidectomy low set ear.

**Case 6****Case 7****Case 8****Case 9****Case 10**

Figure 2. The second group of 5 cases who had left post-mastoidectomy low set ear.

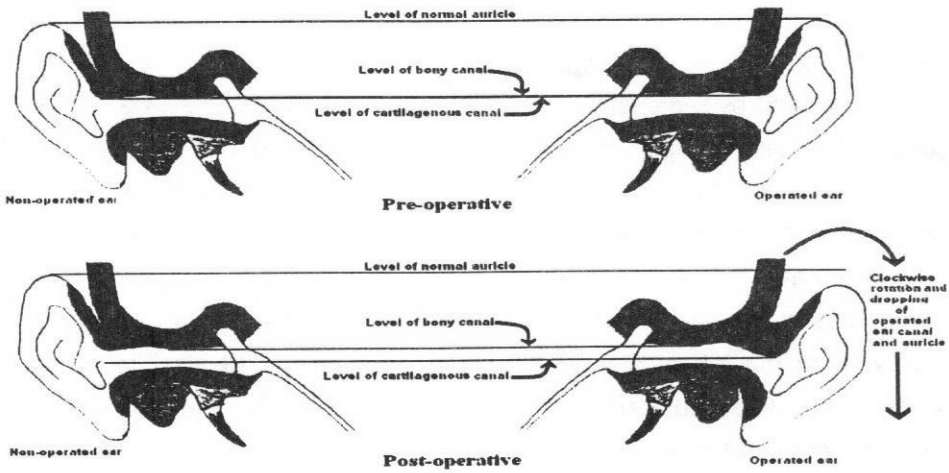


Figure 3. Diagram of coronal orientation of bony and cartilaginous ear canals in normal (non-operated) ear and operated ear. In both conditions, bony canal is kept in normal orientation and both sides are in the same level. In non-operated ear, the canal axis takes a smooth curve inferiorly and laterally. In post operative low set ear, the cartilaginous canal and pinna prolapse by post operative edema exaggerating the angle between bony and cartilaginous canal. The ear pinna is also slightly rotated around the bony-cartilaginous junction so that the tip of the auricle is rotated away from the side of the head (clockwise for left ear). The latter change can usually be counteracted by head bandage.

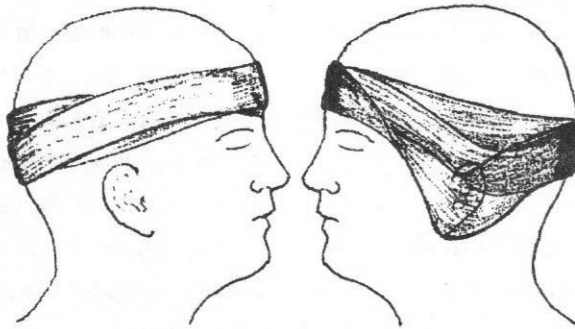


Figure 4. The head bandage manner suggested after mastoidectomy. Head bandage in a V-shaped manner with the apex of the V below the level of ear lobule to create upward traction on the operated left ear. This helps to maintain a normal position of the auricle and reduce the risk of developing post operative low set ear.

DISCUSSION

Auricular cartilage is connected to the temporal bone by two extrinsic ligaments. The anterior ligament runs from the tragus and the spine on the anterior rim of the crus of helix to the root of zygomatic arch. Posterior ligament runs from the medial surface of the concha to the lateral surface of mastoid bone. Attached also to the auricular perichondrium are three extrinsic auricular muscles: auricularis anterior, superior and posterior. These radiate out from the auricle to insert into epicranial aponeurosis. In addition, temporalis muscle has a fibrous attachment to superior aspect of conchal cartilage and the medial end of meatal cartilage is attached to the rim of the bony canal by a fibrous band. Development of low set ear in these cases is due to disruption of these elements which keep the auricle and cartilaginous canal in normal orientation.

Predisposing factors to the development of low-set ear in these cases include :

1- Detachment of ligamentous (and muscular) support of the cartilaginous canal

Detachment of auricular ligaments and fibrous band at the osteo-cartilaginous junction allows postoperative edema to displace cartilaginous canal and auricle depending on the extent of dissection. Detachment of the fibrous attachment of temporalis muscle to the superior aspect of conchal cartilage allows inferior displacement by post operative edema. Although auricular muscles have no significant motor function, they might still have some role in maintaining normal position of the auricle.

2- Loss of periosteal continuity

Dissection of the periosteum overlying the mastoid cortex and bony canal allows postoperative edema to further displace the cartilaginous canal and auricle. Although, the periosteum is repaired in post aural approach, postoperative edema might still displace the dissected periosteum at the ear canal inferiorly. In the end-aural approach, the periosteum is not usually repaired and can thus follow the displaced soft tissues to their new orientation.

3- Loss of continuity of the ear canal

Detachment of cartilaginous canal from bony canal allows postoperative edema to displace the cartilaginous part along with the auricle. The direction of displacement depends on the site of bony cartilaginous detachment, usually posteriorly and superiorly. Displaced canal and auricle tend to rotate around a fulcrum of bony cartilaginous attachment usually kept antero-inferiorly. This was noted early post-operatively (cases 2, 10) and later on in case 4.

4- Loss/lowering of the posterior bony meatal wall

In the canal wall down approach, the posterior bony canal wall is drilled away depriving the cartilaginous canal from the posterior (and sometimes superior) bony attachment. This can lead to further disruption of the bony and cartilaginous canal walls and facilitates cartilaginous canal and auricular displacement.

5- Partial excision of ear cartilage

In meatoplasty, posterior canal wall cartilage is excised occasionally extended to partial removal of conchal cartilage which may also be har-

vested for canal wall or ossicular reconstruction. Postoperative edema can thus rotate the rest of the cartilaginous canal in a downward direction hinged on anterior and inferior attachment to the bony canal.

6- Contraction scar tissue and auricular cartilage

In cases 1, 2 and 8, the operated ear looks relatively shorter than the non operated ear. This could be due to contraction of the scar tissue around the remaining conchal cartilage after partial excision of the cartilage for meatoplasty.

The precipitating factors include

1- Post operative edema. This depends, among several factors, on the amount of soft tissue dissection, haemostasis and use of diathermy. When the soft tissue swelling subsides, the cartilaginous canal and auricle might not return to their normal position due to postoperative fibrosis which holds the displaced canal and auricle into their new position (Figure 3).

2- Head bandage. Following mobilization of the auricle and cartilagi-

nous canal, an inappropriate bandage can hold the ear pinna and canal in a low position if not enough attention was paid to keep the pinna in its normal position. The bandage is usually removed the following day. This allows the developing postoperative edema to displace the cartilaginous canal and pinna in the directions dictated by the extent of soft tissue dissection. The bandage is usually kept for 24 hour to reduce the risk of haematoma formation. This however might not be enough to keep the auricle in a good anatomical position. Pressure bandage may prevent lateral rotation of swollen auricle and cartilaginous canal but may not prevent the dropping or downward displacement aided by the effect of gravity.

Measures to reduce the risk of developing postoperative low set ear :

- 1- The simplest way is to replace both the end- and post-aural incisions whenever possible with the trans-canal ear approach. Although all the reported cases had mastoid surgery for eradication of CSOM, low set ear can develop following end- or post-aural approaches for other ear surgery to obtain a wider

exposure of the surgical field (e.g. myringoplasty, stapedectomy .. etc.).

- 2- Avoidance of excessive soft tissue dissection whenever possible and stopping dissection on obtaining adequate exposure of the operative field.
- 3- Repair of the periosteum. This is usually easier to do after post aurial than end-aural incisions. Care should also be paid to avoiding periosteal lacerations.
- 4- Applying a head bandage which holds the auricle in normal position with upward traction. This can be done by upward pushing of the auricle with the overlying dressing pads during head bandage. A V-shaped bandage (Figure 4) with the apex of the V below the ear lobule creates upward traction on the auricle to maintain its normal position. Upward traction on the bandage over the operated ear with a cross-over band may also add more support to the auricle. This can reduce the risk of development of low set ear in the early post operative period when soft tissues edema and gravity encour-

age dropping and rotation of the auricle and cartilagenous canal. Keeping the head bandage for a longer than 24 hours might also be helpful.

- 5- The current practice of filling the whole ear canal with sterile dressing can have some impact in enforcing the contact between the soft tissues of the cartilaginous canal and the temporal bone.
- 6- Do we need to repair the severed auricular posterior muscle? The author usually preserves this muscle and repairs it at the end of operation if he had to divide it.

Low set ear is mainly a cosmetic problem which can be strikingly obvious unless covered by hairs. It can also lead to functional disadvantages for the patients (cases 1-3, 6, 7, 9). It can be recognized after one week postoperatively (case 10) while in other cases, the low set ear was subtle and accidentally noted later on in the routine follow up. Patient's reaction varied from having no concerns (cases 4, 5, 8) to being unhappy and concerned (case 2, 9, 10).

The ten cases reported in this article are randomly discovered by the author. They give an example of the wide spectrum of surgical conditions in which this complication can develop. Its incidence is not known. However, it is likely that more cases would be identified if the condition was carefully looked for in a prospective study including all patients operated in one (or probably many) centers. Such a study should take in consideration the different demographic, pathologic as well as surgical factors which could be involved in the development of this complication. The actual impact of this condition and the best ways to avoid its development need more investigation. Avoiding the development of postoperative lowest ear would be much easier than its treatment after it has developed.

Finally, a question related to the pre-operative consent may need to be raised: should the patient be informed of the potential risk of developing a postoperative low set ear? Certainly, there are always some patients who would not be happy to

have a postoperative ear scar. Those, at least, would not be happy to have their two ear pinna standing at different levels.

REFERENCES

1 Horowitz S, Morishima A, Vinkka H. (1976) : The position of the ex-

ternal ear in Turner's syndrome. Clin Genet; 9(3):333-340.

2 Pedreira CC, Savarirayan R, Zacharin MR. (2004) : IMAGE syndrome: a complex disorder affecting growth, adrenal and gonadal function, and skeletal development. J Pediatr; 144(2):274-277.