

LARYNGO-TRACHEAL OBSTRUCTION : RESULTS OF SURGICAL TECHNIQUE AND ROLE OF VIRTUAL ENDOSCOPY IN PATIENT EVALUATION

By

Nabil M. Rizk, M.D. Usama A. Hamza, M.D.*
Ahmd A. Abd Elrazk, M.D.** Amany Ezzat, M.D.**
And Dina El-Hashash, M.D.**

From

ORL , Cardiothorathic surgery* and Diagnostic Radiology**

Departments, Faculty of Medicine, Mansoura University,

Mansoura, Egypt

ABSTRACT

Introduction : Upper airway obstruction is a continuous challenge in diagnosis especially if surgical intervention is required. [1-2-3-4-5] Virtual laryngoscopy (VL) is a technique for creating computer simulations of anatomy from radiological image data and viewing those simulations in a way that is analogous to conventional endoscope. [6]

Aim of the work : The aim of this work was to evaluate the results of surgical reconstruction and to compare the findings with virtual laryngoscopy (VL) and conventional endoscopy in diagnosis of upper air way obstruction.

Patients and methods : A prospective study was done at Mansoura University Hospitals at Departments of Otolaryngology and Cardiothoracic surgery, on thirty two patients with an age range of 14-72 years.

Results : Patients presented with upper airway obstruction, 15 cases of laryngeotracheal trauma, advanced laryngeal carcinoma (10 patients), 2 patients of cervical tracheal carcinoma, and granulomatous lesions (5 patients). Fiberoptic and rigid endoscopy were attempted in all patients. Biopsy was done for 28 patients to confirm diagnosis. Spiral CT was performed with slice thickness 2 mm, pitch 1.2 mm, and reconstruction interval 1.5

mm. CT data was transferred to workstation software to analyze both ante-grade and retrograde endoluminal VL with conventional endoscopy and operative findings. Patients presented with cancer and trauma were operated for laryngectomy and laryngotracheo-plasty. Rigid endoscopy showed upper airway obstruction in 8 patients transglottic carcinoma (65%), 1 patients in granulomatous lesions (18%), and 3 (20%) cases of trauma with total success rate 41%. VL showed all luminal obstruction. Only three cases the narrowed segment length was less than operative measurement with total accuracy (94%). Operation was done for traumatic and cancer patients, comparing the results of operative finding and VL.

Conclusion : We conclude that high resolution and multiple image of VL are depicting the intraluminal and transmural extent of laryngeal disease non-invasively especially in traumatic causes. Surgical repair is a challenging procedure, however, it could be done with a good results and minimal morbidity and mortality. The mobilization of the trachea and larynx is essential step for closure sutures without tension is highly important. The usage of neck collar in the opposite

manner is useful to prevent patient from neck hyperextension and disruption of tracheal sutures.

INTRODUCTION

Subglottic obstruction is one of the most important causes of upper airway obstruction, especially if extended to the cervical trachea resulting in variable degrees of upper airway obstruction. [7]. Grillo 1982, classified upper airway into four groups. Management of laryngotracheal obstruction is a challenging problem that depends on several factors as the etiology, site and severity of intraluminal obstruction.[5-7-8].

Endoscopy is an essential stage in management of laryngo-tracheal disorder, but remains a difficult procedure especially in infants. Until now, the entire upper airway area could not be visualized by fiber optic endoscopy unless a tracheostomy is performed. Consequently, the caudal extent of the upper airway obstruction can not be endoscopically observed. [9].

Recently, the most useful diagnostic imaging technique for laryngotracheal stenosis is spiral CT scanning with multiplanar reformation. Virtual endoscopy (VE) is a new technique

used for creating computer simulations of anatomy from radiological image data and viewing those simulations in a way that is analogous to conventional endoscopy. VE is a non-invasive procedure and can produce new views such as retrograde views of endoluminal airway anatomy and external views.[10-9-11-12-13].

AIM OF THE WORK

Our aim of this study was to evaluate the results of surgery to laryngotracheal obstruction and to compare the operative findings with the preoperative virtual and conventional endoscopy. Demonstrate the role of helical CT scan with 3D virtual laryngoscopy VL in evaluating patients with laryngotracheal stenosis in order to define the line of management.

PATIENTS AND METHODS

Thirty two patients (19 male and 13female) in this study presented with stridor and suspected for upper airway obstruction with variable degree of stridor. The age ranged 5-65 years with mean age of 35 years. All patients were presented in otolaryngology service.

All of patients had ENT examina-

tion and fiberoptic laryngoscopy. Eighteen patients presented with severe stridor were tracheostomized urgently. Post intravenous contrast spiral CT of the neck with 3D VL as well as conventional laryngoscopy and bronchoscopy were performed for all of the patients under general anesthesia with biopsy in 21 out of 32 patients. Four of the tracheostomized patients underwent retrograde fiberoptic endoscopically under local anesthesia through the tracheotomy opening to determine the extent of obstruction as it was difficult to pass the rigid laryngoscope.

We used a Toshiba Asterion VS power helical CT scanner. The larynges were scanned by high speed helical CT using the following parameter ; x- ray beam collimation 3mm table speed 6mm / sec, FOV 10 cm, reconstruction interval 1mm, slice thickness 1.5 mm, pitch 1.7 and breadth hold 30 seconds. All patients received 100 ml of iopamiro administered via a powerful injector at a rate of 2 ml/sec using a 40 second initiation. In addition to the standard images raw data from helical scans was saved and transferred into a second workstation to retrospectively generate 3 D models (virtual laryngoscopy images). The 3D

VL images were reconstructed using a CT threshold value of - 600 HU to - 100 HU for mucous membranes. The optimal viewing angles and degree of rotation were determined depending on the exact location of the target. The VL program allows for display of multiple images; an endoluminal views, and views of the related CT slice. Helical CT and VL images were reviewed to estimate the level, extent, and cause of stenosis. We compared the results of helical CT, VL and CL.

As regards the anesthetic technique, the anesthesiologists prefer to use an armored endotracheal tube. Uncuffed no. 5 or 6 endotracheal tube should also be available that may be required at the end of the procedure. On the operative set, another armored tube no. 7 is necessary for ventilation across the surgical field when division of the airway has taken place. During completion of the anastomosis, intermittent ventilation with 100% oxygen permits up to 2 minutes of apnea for suture placement. As for monitoring is concerned, oximetry and end tidal carbon dioxide measurements are routine. Both are important when intermittent apnea is employed.

All cancer patients were operated

upon for classical total laryngectomy with neck dissection.

One patient operated for resection of laryngoscleroma and did the same way of traumatic management. Traumatic patients operated on for excision of the obstructive lesion and reconstructed by classical laryngo-tracheo-plasty. We did a transverse incision and localize the obstructed segment and resected. Mobilization of the trachea down to the carina and larynx up to the hyoid bone provided a tensionless suture line and facilitate the closure of the tracheal rings without tension. In some cases, stent of the endo-tracheal and larynx up to the under surface of the vocal folds was used. We used the Montgomery type stent with tracheostomy opening. Closure with vicryl 3.0 in interrupted manner. We used a neck collar in opposite position prevent the hyper extension of the neck and disruption of sutures. All operated patients sent for ICU for 2 days then get back to the ward. All patients were discharged after 10 days. Removal of the stent at one month later under general anesthesia and rigid endoscopy.

RESULTS

We had no perioperative mortality

or morbidity for all patients operated in this study.

All patients were sent home by the day of 10 days postoperative.

Early complications included the need for prolonged intubation because of glottic or anastomotic edema in five patients, superficial wound infection in three patients and suture granuloma in two patients that required bronchoscopic removal. No major early complications as far for bleeding or anastomotic dehiscence or skin rupture.

All patients were instructed for follow up every two weeks in the outpatient clinics.

The site and causes of upper airway obstruction were classified into groups as shown in tables [1] and [2].

The endoscopic diagnoses of airway obstruction included 14 patients with localized laryngeal lesion, 5 cases with laryngotracheal lesions and remaining 13 cases of localized laryngeal obstruction. Failure of passage of rigid laryngoscope and bronchoscope were in (19) patients due to near total obstruction or presence of laryngeal edema and fracture.

Both VL and CL were able to detect accurately the presence of narrowing lumen (Figures 1, 2, 3, 4 & 5).

The presence of upper airway obstruction and its site were correlated between VL, RL and open surgical findings. The Vertical extent of stenosis could be delineated with VL in all cases while it was not measurable in four cases by CL due to severe stenosis in three cases and spinal kyphosis preventing passage of rigid endoscope in the remaining one. Table [3].

In cases operated for correction of this obstruction, the findings were much correlated with VL finding RL showed upper airway obstruction in 8 patient's transglottic carcinoma (65%), 1 patient in granulomatous lesions (18%), and only three cases of trauma (25%) with total success rate 38%. VL showed all luminal obstruction. Only three cases the narrowed segment length was less than operative measurement (9.4%), one case of cancer not defined in VL as it was mobile 3%. In granulomatous lesion VL showed 4 patients accurately as the crustation problem (80%) and the overall success rate was 94%

Table (1): Site and etiology of upper airway obstruction:

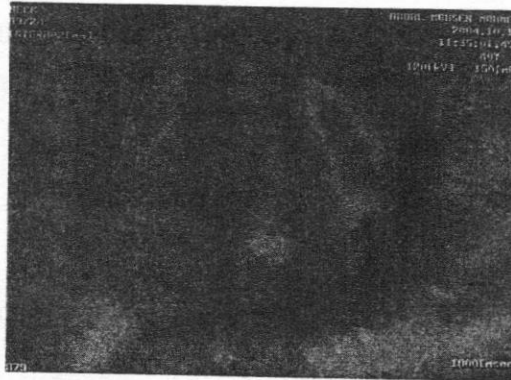Site	Trauma	Cancer	Granulomatous	Total
Laryngeotracheal	4	-	1	5
Tracheal	11	2	0	13
Laryngeal	0	10	4	14
Total	15	12	5	32

Table (2): Types of trauma:

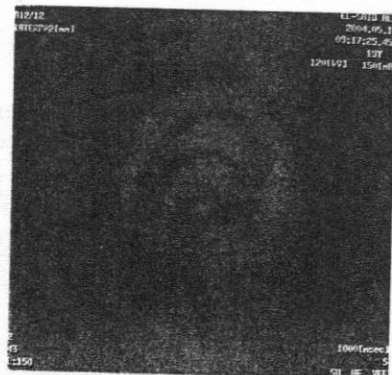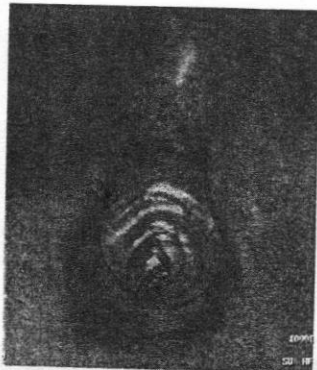Site	Blunt trauma	Post intubational	Post tracheostomy	Total
Tracheal	4	5	2	11
Laryngeotracheal	2	2	0	4

Table (3): Localization of upper airway obstruction:

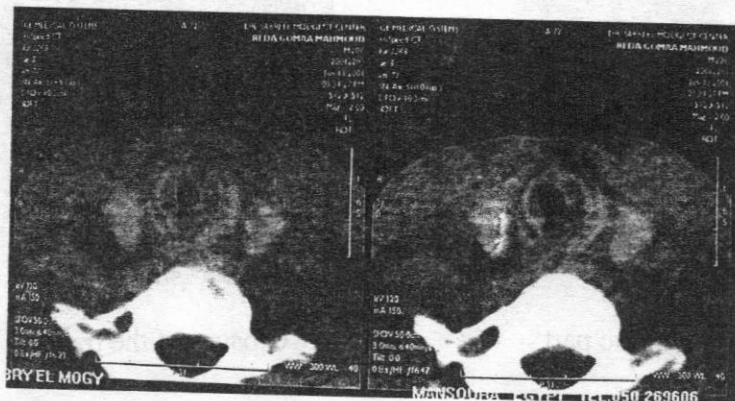
Etiology	Virtual laryngoscopy	Rigid laryngoscopy
Trauma	15 (100%)	3 (20%)
Cancer	11 (92%)	8(65%)
Granulomatous	4(80%)	1(18%)
Success	30(94%)	12(38%)



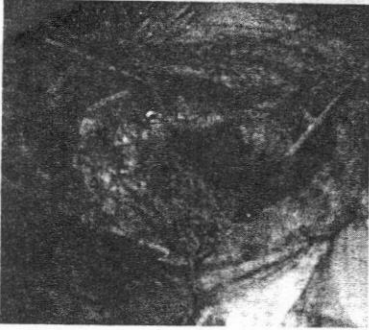Endoluminal view of virtual showing neoplastic obstruction



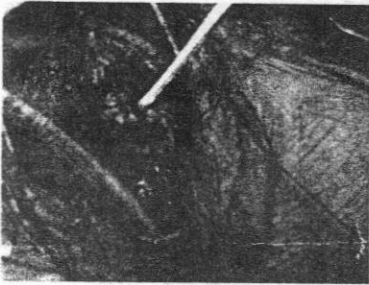
Endoluminal view of virtual showing post traumatic obstruction



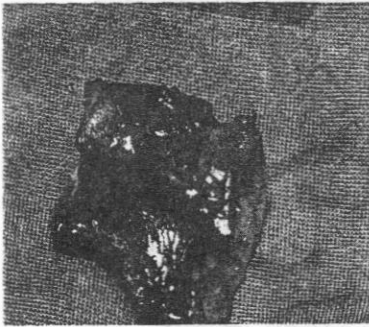
Conventional CT scan
showing the obstructed site



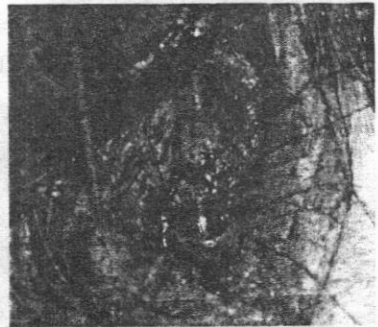
A Exposure of stenotic segment cervical trachea



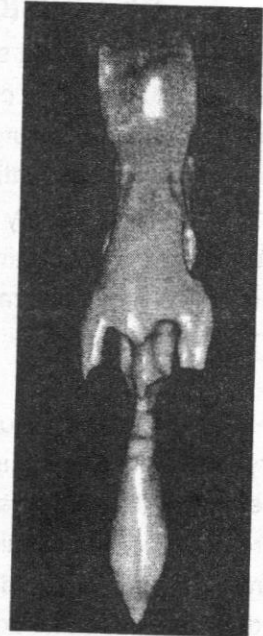
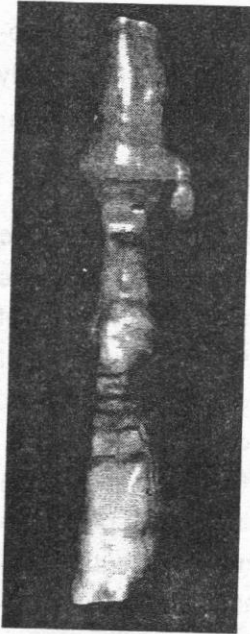B Resected stenotic segment with two end exposed




C Resected stenotic part



D Closure of the tracheal ends



External frame of the laryngotracheal showing the obstructed site



External view virtual of the larynx and cervical trachea with tracheostomy tube showing the obstructed site.

DISCUSSION

Teacheo- laryngeal surgery is one of the most technically challenging areas in all of thoracic surgery. Diagnostic precision is essential, operative timing must be carefully judged, operative technique is exacting and postoperative care must be meticulous.[14-15-16].

As described by most authors in laryngotracheal reconstruction we used the wide transverse neck exposure and good homostatic field. Exposure of the trachea and the larynx up to the hyoid bone and down to the supra sternal notch. Meticulous dissection with identification of the recurrent laryngeal nerves in both sides and preserving the blood supply of the trachea. Careful tracheal mobilization helped in reanastomosis without tension. [7-14-5].

Virtual CT scan is used in the analyses of the larynx, tracheo-bronchial tree, colon, vasculature, craniofacial skeleton, and the axial skeleton.[17-18-19-20].

VL allowed for display of multiple images including endoscopic view, an external view and axial CT slices. The ability to accurately recreate the up-

per airway, analyze its structural abnormalities, measure lesions, and fly through the lumen suggests an augmentative role for VE. [21].

The external and endoscopic views are accurate in detecting the vertical extent of stenosis. The view of related axial CT slices give additional information as cartilages invasion, fracture or dislocation, infiltration of the adjacent soft tissues and lymph nodes which are important specially in tumor staging and therapeutic planning. The simultaneous display of endoscopic and external views together with related axial CT slices allowed for better delineation of the stenotic lesions. [22].

Burke et al 2000 and Lecasse et al 2004 found that VL had its closest correlation to conventional endoscopy in analysis of airway obstruction. They stated that, there is no gold standard for comparing head to head measurement accuracy for two modalities, which is why their results are presented as the difference between the actual and virtual data. They found accuracy of VE 95% in correct diagnosis of airway obstruction which is coming with our study as VE accuracy is 94%. [13-21].

All cases of traumatic stenosis were soft tissue in nature and could be shown by both VL and in only one can pass RL in old trauma. Examination of related axial CT images was beneficial as it was able to exclude associated cartilaginous fracture or dislocation. One of these cases showed interruption of the stenotic segment by a short area of normal diameter. Fried et al 1999, stated that in their work VL showed more non-invasive data and can be used for acute cases which matched with our results. In our study, the success of VL was 100%, which matched with most of authors-[23]. The VL gives more information about the external frame of the larynx and cervical trachea which was helpful in surgical localization and laryngo-tracheo-plasty. [23-24].

In cases of granulomatous stenosis, VL was able to detect the soft tissue lesions causing the narrow which appeared as circumferential soft tissue thickening. One of these cases showed extension into the trachea while no case extended to the level of true vocal cords. One case did not visualize accurately due to the lesion crustation was mobile (80%). The endoscopic biopsy and tissue diagnosis in one case was still required which

can be performed only by RL that showed 18% visualization only due to marked stenosis. [25].

In cancer patient 8 patients 65% can pass RL, five cases of upper airway tumors extension, and two cases bulky tumor, the tumor was not assisted by RL due to bulky tumor size obstructing the lumen. VL can give accuracy and detailed in 11 cases (92%) that showed luminal obstruction and extension of the tumor the only case not showing results was due to swallowing artifacts ASchoff et al. 1988 showed in his study that swallowing artifacts affect the results of VL. [24-26-27-28-29].

Maintaining neck flexion in the postoperative period is an essential step to ensure tension free suture line. Suturing the chin to the front of the chest is a classic and effective method although non-comfortable to the patient. Many authors have described alternative methods for neck flexion. [8]. The technique we utilized using the neck collar in the opposite direction proved effective and in the same time avoided patient discomfort.

CONCLUSION

Diagnosis of airway disease, air-

way patency, lesion length and cross sectional area is important aspects of the management of airway disease, usually requiring invasive endoscopy, which is not without risk to the patient, although RL is still the gold standard for the evaluation of stridor and airway obstruction.

VL is non invasive technique has valuable role in laryngotracheal obstruction to guide the surgeon for diagnosis and selection of surgery required.

VL has advantages over rigid laryngoscopy RL in that: it is non invasive and can produce unconventional views such as retrograde views of endoluminal airway anatomy and external anatomical views.

Surgical repair is a challenging procedure, however, it could be done with a good results and minimal morbidity and mortality.

The mobilization of the trachea and larynx is essential step for closure sutures without tension is highly important.

The usage of neck collar in the opposite manner is useful to prevent pa-

tient from neck hyperextension and disruption of tracheal sutures.

REFERENCES

- 1-Fried MP, Hsu L, Topulos G, Jolesz FA. (1996) : Image-guided surgery in a new magnetic resonance suite: preclinical considerations. *Laryngoscop*; 106: 411-7.
- 2-Metes A, Hoffstien V, Dierenfeld V, Chapinck, JS, Zamel N. (1993) : three-dimensional CT reconstruction and volum measurements of pharyngeal airway before and after maxillofacial surgery in obstructive sleep apnea. *J Otolaryngol*; 22: 261-4.
- 3-Silverman PM, Zeiberg AS, Sessions RB, Troost TR, Zeman PK. (1995) : The three-dimensional imaging of the hypopharynx and larynx by means of helical (spiral) computed tomography. Comparison of radiological and otolaryngological evaluation. *Ann Otol Rhinol Laryngol*; 104: 425-31.
- 4-Alyassin AM, Lorensen WE.

- (1998) : Virtual endoscopy software applications on a PC. Proceedings of the sixth annual Conference on Medicine Meets Virtual Reality. San Diego, Calif.: 84-9.
- 5- **Ciccone A.M., De Giancomo T., Venuta F., Ibrahim M., Diso D., Coloni G.F. and Rendina E.A. (2004)** : Operative and non-operative treatment of benign subglottic laryngotracheal stenosis. Eur. J. Cardioth. Surg; 26: 818- 822
- 6-**Vining DJ, Liu K, Choplin RH, et al. (1996)** : Virtual bronchoscopy: relationships of virtual reality endobronchial simulations to actual bronchoscopic findings. Chest;109:549-553.
- 7-**Grillo HC (1982)** : primary reconstruction of airway after resection of Subglottic laryngeal and upper tracheal stenosis .Ann Thorac Surg, 33:3-11
- 8- **Mueller D.K., Becker J., Schell S.K., Karamchandani K. M., Munns J.R. and Jaquet B. (2004)** : An alternative method of neck flexion after tracheal resection. Ann Thorac. Surg.; 78: 720- 721.
- 9-**Rodenwaldt J, Kopka L, Roedel R, Grabbe E. (1996)** : Three-dimensional surface imaging of the larynx and trachea by spiral CT: virtual endoscopy. Fortschr. Röntgenstr.; 165: 80-83.
- 10-**Silver CE. (1981)** : Surgery of the larynx and related structures.; New York: Churchill Livingstone.
- 11-**Yumoto E, Sanuki T, Hyodo M, et al. (1997)** : Three dimensional endoscopic mode for observation of laryngeal structures by helical computed tomography. Laryngoscope, (107): 153-7.
- 12-**Frankenthaler R, Moharir R, et al. (1998)** : Virtual endoscopy. Otolaryngol Clin North Am; 31: 383-92.
- 13- **Lecasse Y., Martel S., Hebert A., Carrier G. and Raby B.**

- (2004) : Accuracy of virtual bronchoscopy to detect endobronchial lesions. *Ann. Thorac. Surg.*; 77: 1774-1780.
- 14- Mathisen D. J., Subglottic tracheal resection. (1998) :** Operative Techniques in Thoracic and Cardiovascular Surgery- Acomparative Atlas.; 3 (3): 142- 153.
- 15- Van den Boogert J, Hans Hoeve LJ, Struijs A, Hagenouw RR, Bogers AJ. (2004) :** Single-stage surgical repair of benign laryngotracheal stenosis in adults.: *Head Neck.* Feb;26(2):111-7.
- 16- Grillo HC, Mathisen DJ, Ashiku SK, Wright CD, Wain JC. (2003) :** Successful treatment of idiopathic laryngotracheal stenosis by resection and primary anastomosis.*Ann Otol Rhinol Laryngol.* Sep;112(9 Pt 1):798-800.
- 17-Schultz P, Wiorowski M, Million P, Veillon F, Debry C. (2003) :** Contribution of virtual endoscopy to the investigation of laryngotracheal pathological conditions. *ORL J Otorhinolaryngol Relat Spec.* Jan-Feb; 65(1):33-8.
- 18-Zinreich SJ, Mattox DE, Kennedy DW, et al. (1988) :** 3D CT for cranial, facial and laryngeal surgery. *Laryngoscope*, (98): 1212-9.
- 19- Newmark GM, Conces DJ, Kopeccky KK. (1994) :** Spiral CT evaluation of the trachea and bronchi. *J Comput Assist Tomogr*;18:552-4.
- 20-Gilani S, Norbash AM, Ring H, et al. (1997) :** Virtual endoscopy of the paranasal sinuses using computed tomography. *Laryngoscope*;107:25-9.
- 21- Burke AJ , Vining DJ , McGuirt Jr WF, et al. (2000) :** Evaluation of airway obstruction using virtual endoscopy. *Laryngoscope*, Jan, (110):23-9.
- 22- Hermans R, Verschakelen JA,**

- Baert AI. (1995) :** Imaging of laryngeal and tracheal stenosis. *Acta Otorhinolaryngol*; 49: 323-9.
- 23- Fried MP, Moharir VM, Shinmoto H, Alyassin AM, Lorenzen WE, Hs Kikinis R. (1999) :** Virtual Laryngoscopy. *Ann Otol Rhinol Laryngol Mar*; 108 (3):21-6.
- 24-Aschoff AJ, Seifarth H, Fleiter T, Sokiranski R, Gorich J, et al. (1998) :** High -resolution virtual laryngoscopy based on helical CT data sets. *Radiol*; 38:810-5.
- 25-Dunham ME, and Wolf RN. (1996) :** Visualization of pediatric airway: three-dimensional modeling of endoscopic images. *Ann Otol Rhinol Laryngol*; 105: 12 7.
- 26-Greess H, Nomayr A, Tomandl B, blank M, Lell M, Lenz M, Bautz W. (2000) :** 2D and 3D visualization of head and neck tumors from spiral data. *Eur J Radiol Mar*; 33 : 170-7.
- 27-Gallivian RP, Nguyen TH, Armstrong WB. (1999) :** Head and neck computed tomography virtual endoscopy : evaluation of a new imaging technique. *Laryngoscope*, Oct; 109 (10): 1570-9.
- 28-Yilmaz T, Hosal S, Gedikoglu G, Turan E, Ayas K. (1998) :** Prognostic significance of depth of invasion in cancer of the larynx. *Laryngoscope*; 108 : 764-8.
- 29-Williams DW. (1997) :** Imaging of laryngeal cancer. *Otolaryngol Clin North Am.*; 30:35-58.
- 26-Greess H, Nomayr A, Tomandl**

1. *Staphylococcus aureus*
2. *Staphylococcus aureus*
3. *Staphylococcus aureus*
4. *Staphylococcus aureus*
5. *Staphylococcus aureus*

6. *Staphylococcus aureus*
7. *Staphylococcus aureus*
8. *Staphylococcus aureus*
9. *Staphylococcus aureus*
10. *Staphylococcus aureus*

11. *Staphylococcus aureus*
12. *Staphylococcus aureus*
13. *Staphylococcus aureus*
14. *Staphylococcus aureus*
15. *Staphylococcus aureus*

16. *Staphylococcus aureus*
17. *Staphylococcus aureus*
18. *Staphylococcus aureus*
19. *Staphylococcus aureus*
20. *Staphylococcus aureus*

21. *Staphylococcus aureus*
22. *Staphylococcus aureus*
23. *Staphylococcus aureus*
24. *Staphylococcus aureus*
25. *Staphylococcus aureus*

26. *Staphylococcus aureus*
27. *Staphylococcus aureus*
28. *Staphylococcus aureus*
29. *Staphylococcus aureus*
30. *Staphylococcus aureus*

31. *Staphylococcus aureus*
32. *Staphylococcus aureus*
33. *Staphylococcus aureus*
34. *Staphylococcus aureus*
35. *Staphylococcus aureus*

36. *Staphylococcus aureus*
37. *Staphylococcus aureus*
38. *Staphylococcus aureus*
39. *Staphylococcus aureus*
40. *Staphylococcus aureus*

41. *Staphylococcus aureus*
42. *Staphylococcus aureus*
43. *Staphylococcus aureus*
44. *Staphylococcus aureus*
45. *Staphylococcus aureus*