

# MORPHOMETRIC AND HISTOPATHOLOGICAL CHANGES INDUCED BY MODERATE AND SEVERE DIETARY ZINC DEFICIENCY IN TESTES OF MALE ALBINO RATS

By  
**Osama Ibrahim Nassif**

From  
*Departments of Pathology Faculty of Medicine and  
Allied sciences, King Abdulazeez University*

## ABSTRACT

The testicular tissues are affected adversely by zinc deficiency. These changes are correlated with the degree of deficiency. In comparison with the control (C) group, moderate zinc deficiency (MZnD) leads to regressive changes in the adluminal germ cells but not in spermatogonia located in the basal compartments while severe zinc deficiency (SZnD) can affect both the adluminal and basal compartments. Although there was numerical differences between the mean tubular diameter of MZnD ( $184\mu\text{m} \pm 7$ ) and SZnD ( $168\mu\text{m} \pm 8.6$ ) in comparison with the C group ( $213 \pm 3.8$ ), it was statistically insignificant. Also, the spermatic index though showed numerical differences between MZnD ( $16.7 \pm 3.3$  sperms/tubule), SZnD ( $1 \pm 1.5$  sperms/tubule) and C group

( $33.7 \pm 3.9$  sperms/tubule), it was statistically significant only in SZnD ( $P < 0.05$ ). The setroli cell index for C, MZnD and SZnD groups was  $13.8 \pm 2.9$ ,  $16.7 \pm 3.3$  and  $20.7 \pm 5.9$  respectively, but it was statistically insignificant for all ( $P > 0.05$ ). The thickness of the tunica albuginea was the same for C, MZnD and SZnD groups while for basement membrane thickness, there was mild thickening in SZnD group. The sclerotic tubules ( $9 \pm 1.3\%$ ) and multinucleated giant cells ( $1.4 \pm 1.1$  cells/tubule) were found only in SZnD group.

## INTRODUCTION

Zinc deficiency was identified as a major cause for testicular atrophy and hypogonadism<sup>1</sup>. Zinc performs critical roles in the physiological functions of many metalloenzymes especially in

MANSOURA MEDICAL JOURNAL

the synthesis of ribonucleic acid (RNA) and deoxyribonucleic acid (DNA)<sup>2,3</sup>. Certain morphological features were described in the testes of zinc deficient rats as the presence of numerous atrophic seminiferous tubules lined only by spermatogonia<sup>4,5</sup>). Also abnormal spermiogenesis<sup>6,7</sup> affection of Leydig cell functions and the pituitary gonadal axis<sup>8,9</sup> were reported. On the other hand, it was found that zinc protects testicular injury induced by concurrent exposure to cadmium and lead<sup>10</sup>. Also the time-related histopathological changes induced by dietary Zinc deficiency in general was evaluated<sup>1</sup>. None of these studies included morphometry or statistical analysis for evaluation of tubular diameter or indices for assessing these changes. Furthermore, none of them correlated the atrophic changes with the degree of zinc deficiency.

This work was planned to evaluate the histological changes induced by moderate and severe dietary zinc deficiency on the testes of male albino rats and to assess the degree of these changes by: measuring the mean tubular diameter and the percentage of sclerotic tubules, the relative thickness of tunica albuginea and

basement membrane in relation to the control group, the spermatic index, sertoli cell index, the level of spermatogenic arrest and the percentage of tubules showing injury of the adluminal and /or basal compartments.

## MATERIAL AND METHODS

Thirty male albino rats (4 to 5 weeks old) each weighing about 60 grams were used in this experiment. They were divided into three groups (10 rats / group) and housed in plastic cages covered by wooden pens and kept at 30-32 °C.

### *Control Group (C):*

Rats of this group were fed a natural diet consisting of milk, bread, corns and carrots and had free access to tap water.

### *Moderate zinc deficient group (MZnD):*

Rats of this group were fed a semisynthetic moderate zinc deficient diet (2mg/kg body weight)<sup>11</sup> for 5 weeks. The diet was purchased from B.M. Clarton company (Los Angeles, USA).

### *Severe zinc deficient group (SZnD):*

They were pair-fed for 5 weeks by

severe zinc deficient diet containing less than 1mg/kg body weight in an amount according to weight to that consumed by the control group and the MZnD group.

The rats in each group were sacrificed at the end of the fifth week and the testes were rapidly removed and sliced. The slices were fixed in alcoholic Bouin's solution for 6 hours, washed in 70 % ethanol and then processed in ascending grades of ethanol. The tissues were cleared in xylol and embedded in paraffin wax. Sections were cut at 4 $\mu$ m thickness and step sections were taken at a distance of 16 $\mu$ m stained with hematoxylin and eosin , periodic acid-Schiff and Masson's trichrome stains.

Quantitative study was done by examining five randomly selected fields in each slide<sup>12</sup>. In each of these fields, the following parameters were assessed:-

- 1-The mean tubular diameter, using Leitz micrometer.
- 2-Percentage of sclerotic tubules.
- 3-Thickness of tunica albuginea (mild, moderate and marked) in relation to the control group.
- 4-Spermatic index (mean number of sperms per tubule).

5-Sertoli cell index (mean number of sertoli cell per tubule).

6-The degree of thickness of basement membrane in relation to the control group.

7-The mean number of multinucleated giant cell per tubule ( if any).

8-The extent of testicular injury (adluminal and basal testicular compartments) .

From the average values for each testis, the mean, the standard deviation and the standard error for each group of study were calculated . The significance of each parameter was done .by using the two tailed t- test.

## RESULTS

### *Moderate zinc deficient group(MZnD)*

In comparison with the control group, the mean diameter of the seminiferous tubules of MZnD group(184 $\pm$ 7 $\mu$ m) was less than that of the C group (213 $\pm$ 3.8 $\mu$ m) but this was statistically insignificant (P value>0.05). Seventy percent of the tubules of MZnD showed full maturation up to sperms while that of the C group was 93% The spermatic index for MZnD group (19.9 $\pm$ 3.3) was statistically insignificant (P>0.05) in relation to that of the C group (33.7 $\pm$ 3.9).The

Sertoli cell index showed also insignificant difference ( $P>0.05$ ) from that of the control group (MZnD  $16\pm3.3$  & C group  $13.8\pm2.9$ ). Regarding the relative thickness of the tunica albuginea and basement membrane, there was no significant difference between MZnD and C groups. This was also the same finding in relation to the percentage of sclerotic tubules and mean number of giant cells per tubule as both C and MZnD groups showed no sclerotic tubules or giant cells. The seminiferous tubules of the C group revealed normal spermatogenesis with its normal adluminal, intermediate (temporary) and basal compartments (Figure 1). Spermatogonia and young spermatocytes were present in the basal compartment while the adluminal compartment included maturing spermatocytes, spermatids and sperms. The intermediate compartment is a transient compartment and difficult to judge. In C group, 1.5% of the seminiferous tubules showed injury of the adluminal compartments in the form of arrested spermatogenesis at the level of spermatids while it was significantly higher ( $P<0.05$ ) than that of the MZnD group ( $12\pm4.9$ ). These regressive changes ranged from subnormal spermatogenesis up to spermatogenic arrest at the level of sec-

ondary spermatocytes (Figure 2). The basal compartments showed no atrophic changes (Figure 3). There was no remarkable changes that could be demonstrated in the interstitial cells of Leydig of the MZnD group compared to the C group.

#### Severe zinc deficient group (SZnD)

The testes of the SZnD group showed drastic histological changes compared to the C group. Most of the tubules seen in cross section were slightly smaller in diameter ( $168\pm8.1$   $\mu$ m) than the C group ( $213. \pm3.8$ ) but the difference was statistically insignificant ( $P>0.05$ ). Very few tubules showed maturation up to spermatids with occasional sperms. The spermatogenic index ( $1\pm1.4$  /tubule) was significantly lower ( $P<0.05$ ) than that of the control. The sclerotic tubules ( $9\pm1.3\%$ ) were dilated, markedly hypocellular and lined mainly by Sertoli cells with occasional spermatogonia (Fig. 4). Its lumens showed degenerated and sloughed cells with sclerosis (Figure 5). The atrophic changes were, statistically significant than that of the C group ( $P<0.05$ ), mainly affecting the adluminal ( $35.6\pm10.7\%$ ) and basal ( $11.8\pm4.9\%$ ) compartments. Variable number of multinucleat-

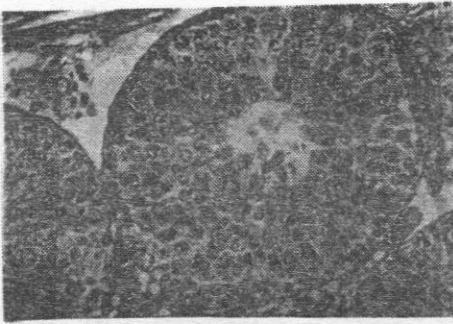


ed giant cells ( $1.4 \pm 1.1/\text{tubule}$ ) appeared inside the lumens of the tubules. These cells had eosinophilic cytoplasm and specific chromatin distribution in the form of densely stained patches with occasionally prominent nucleoli (Fig 6). These giant cells were associated with focal mild thickening of the basement membrane in comparison with the control group and variable degree of atrophic changes. These atrophic changes were adluminal, or adluminal and basal. The adluminal injury was in the form of sloughed germinal epithelium and spermatogenic arrest at the level of rounded or elongated spermatids where the chromatin pattern of rounded spermatids was similar to that of the giant cells (Figure.7). In spermatogenic arrest at the level of elongated spermatids, it was found that all the spermatids were embedded in the sertoli cell cytoplasm with no luminal sloughing of germ cells (Figure 8). The basal compartment injury was in the form of markedly hypocellular tubules lined mainly by sertoli cells and few basal spermatogonia with occasional luminal giant cells (Figure 9). The sertoli cell index of the SZnD

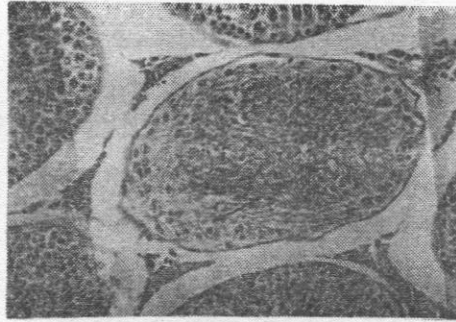
group was more than that of the control group (SZnD  $20.7 \pm 5.9$  & C  $13.8 \pm 2.4$ ) but it was of border line significance ( $P = 0.05$ ). The thickness of the tunica albuginea showed no difference between the control group and the MZnD group. Some of the tubules showed lymphocyte-like cells with deeply stained nuclei and a rim of lightly stained cytoplasm surrounded by a clear halo in between the tubular cellular elements (Figure 10). The interstitial cells of Leydig showed mild degenerative changes in comparison with the control group.

By comparing the mean values of SZnD group to that of the MZnD group, it was found that the mean tubular diameter was statistically insignificant ( $P > 0.05$ ). On the other hand, the sertoli cell index, spermatid index, percentage of sclerotic tubules, percentage of adluminal tubular injury, percentage of basal injury and mean number of multinucleated giant cells per tubule showed statistical significance ( $P < 0.05$ ). This means that the mean tubular diameter is not a good parameter for evaluation of dietary zinc deficiency.

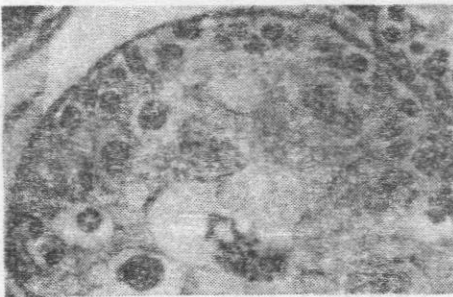




**Figure 3.** A seminiferous tubule of MZnD group demonstrating spermatogenic arrest at the level of secondary spermatocytes in the adluminal compartment with completely normal basal compartment, interstitial cells of Leydig and basement membrane. (H&E stain, original magnification X 200)



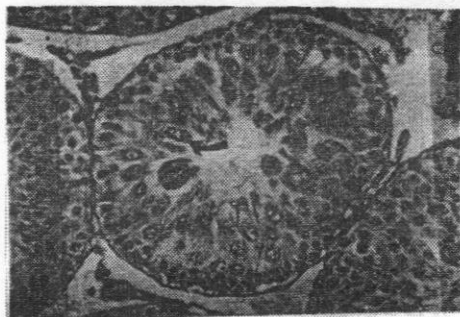
**Figure 5.** Sclerotic seminiferous tubule of SZnD group showing marked hypocellularity, basal and adluminal injury with occasional lymphocyte-like cells (arrow) surrounded by clear halo and normal interstitial cells of Leydig. (H&E stain, original magnification X 200).



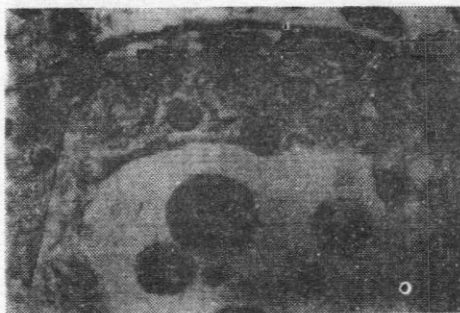**Figure 4.** Atrophied seminiferous tubule of SZnD group showing marked hypocellularity and degenerating cells lined by Sertoli cells with few spermatogonia. (H&E stain, original magnification X 400)



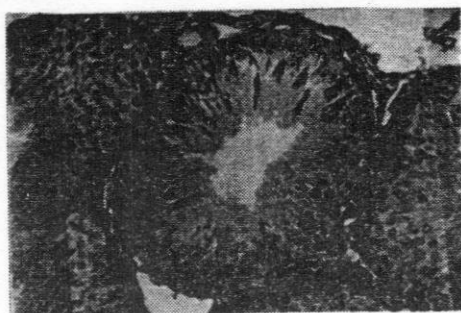
**Figure 6.** A multinucleated giant cell with nucleolar prominence embedded in the basal compartment of a seminiferous tubule of SZnD group with luminal sloughing of germ cells. (H&E stain, original magnification X 400)



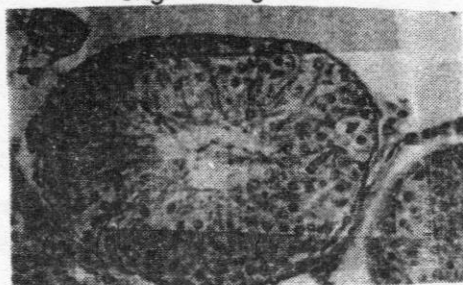**Figure 7.** Seminiferous tubule of SZnD group showing adluminal injury with arrest at the level of round spermatids (arrow), sloughed germinal epithelium and a multinucleated giant cell having thick eosinophilic cytoplasm. (H&E stain, original magnification X 200).



**Figure 9.** Adluminal and basal compartment injury in SZnD group showing mainly sertoli cell lining with triangular nuclei with ill defined abundant cytoplasm, sloughed cells and one multinucleated giant cell having coarse nuclear chromatin and thick eosinophilic cytoplasm. (H&E stain, original magnification X 400)



**Figure 8.** A seminiferous tubule of SZnD group showing spermatogenic arrest at the level of elongated spermatids (PAS positive) which are attached to the cytoplasm of sertoli cells with mild thickening of the basement membrane. (PAS stain, original magnification X 200).



**Figure 10.** A seminiferous tubule of SZnD group showing regressive changes with one lymphocyte-like cell (arrow) having deeply stained nucleus and a small rim of cytoplasm surrounded by a clear halo. (H&E stain, original magnification X 200).



## DISCUSSION

In the present study, the described histological changes observed were correlated with the degree of zinc deficiency in the diet. Previously, it was proved that the histological changes were dependent on the duration of dietary zinc deficiency without any reference to the degree of zinc deficiency<sup>1</sup>.

In MZnD group, the histological changes were mainly in the adluminal compartments with normal basal compartments. This is in agreement with the finding of other authors<sup>11</sup> who added that the adluminal changes are reversible because the spermatogonia in the basal compartment are not affected by neither moderate zinc deficiency nor short term zinc deficiency. A slight subjective decrease in the size of the seminiferous tubules after 4 weeks of their experiment was reported<sup>1</sup> although the present work showed the same difference numerically (MZnD  $184 \pm 7 \mu\text{m}$  & C  $213 \pm 3.6$ ) but it was statistically insignificant ( $P > 0.05$ ). The spermatogenic index was numerically less than that of the control group (MZnD  $19.9 \pm 3.3$  & C  $33 \pm 3.9$ ) and the same observation was reported subjectively,<sup>13</sup> however in the present work, this difference

was statistically insignificant ( $P > 0.05$ ) and there was no similar statistics in the available English literature for comparison.

Regarding sertoli cell index, there was no significant difference between C group ( $13.8 \pm 3$ ) and MZnD group ( $16.7 \pm 3$ ) ( $P > 0.05$ ). This might be explained by the fact that zinc deficiency affects mainly spermatogenesis in the adluminal compartment and leads to underdevelopment of the germinal epithelium.<sup>13</sup> The interstitial cells of Leydig showed no remarkable changes in comparison with that of the control group. Also, there was no remarkable difference between MZnD and C groups in relation to thickness of the tunica albuginea and basement membrane of the seminiferous tubules. This could be explained by the fact that these are non regenerating elements and zinc is needed for RNA and DNA synthesis<sup>3</sup>. There was no giant cells in seminiferous tubules of both groups. These histological changes were in accordance with that reported with others<sup>1</sup> but they described these changes after 4 weeks which in the present work it was 5 weeks. This might be explained by their use of markedly zinc deficient diet than we used.

The changes in SZnD group affected mostly both the adluminal (35.6%) and basal (11.8%) compartments. The maturation was mostly arrested at the level of spermatocytes or spermatids in 70% of the tubules. The spermatid index was significantly ( $P < 0.05$ ) reduced (SZnD, 1 sperm / tubule & MZnD, 19.9 sperms / tubule & C group 33.7 sperms / tubule). The mean tubular diameter was reduced (SZnD, 168  $\mu$ m & MZnD, 184  $\mu$ m & C, 213  $\mu$ m). This means that there is indirect relationship between the severity of zinc deficiency and the mean tubular diameter of the seminiferous tubule. This is in accordance with the subjective findings of others<sup>1</sup>, however, it was found statistically insignificant ( $P > 0.05$ ). The presence of multinucleated giant cells was seen only in SZnD group. It is thought to be of germ cell origin from the similarity in cytoplasmic staining and nuclear chromatin features of these giant cells to the round spermatids. It was suggested that these multinucleated giant cells are round spermatids<sup>15</sup>. However, these giant cells were observed in SZnD group with complete absence of spermatids which may point to an origin from germ cells other than spermatids contrary to that mentioned by others<sup>15</sup>. It may arise by either fu-

sion of germ cells or amitotic division<sup>15</sup>, and it was suggested that these round spermatids fused forming symplasts<sup>16</sup>. These symplasts are formed by opening of intercellular bridges between round germ cells. The cause of bridge opening is not known but severe zinc deficiency may affect the cytoskeletal apparatus maintaining the integrity of the bridge thus favoring the possibility of fusion of germ cells. We agree with them in that theory of fusion. The possibility of amitotic division can be ruled out by the fact that zinc is essential for synthesis of DNA and RNA, hence its deficiency will impair mitosis rather than accelerate it<sup>7</sup>.

The basement membrane showed mild thickening in SZnD group in comparison with that of the control group and MZnD group. The sclerotic tubules were present only in SZnD ( $9 \pm 1.3\%$ ) as well as the lymphocyte-like cells. The sertoli cells were numerically ( $20.7 \pm 6$ ) increased more than that of the C group ( $13.8 \pm 3$ ) and MZnD group ( $16.7 \pm 6$ ) but the findings were statistically insignificant ( $P > 0.05$ ). The leydig cells showed no significant difference between the C group and the MZnD group. This was similar to the histopathological

changes described by others 1 after 6 weeks of their experiment while in the present work, it was observed after 5 weeks. This is explained by the degree of dietary zinc deficiency which was more deficient in the diet we used in our experiment in SZnD group than theirs.

The histopathological findings recorded in this study adds further morphometric proof to the significant role of zinc in spermatogenesis. Further studies on the effect of zinc deficiency at the ultrastructural levels are suggested.

## REFERENCES

1. **Hafiez AA, El-Kirdassy ZHM, El-Malkh NM, El-Zayat EMI. (1990) :** Role of zinc in regulating the testicular function. Part 3. Histopathological changes induced by dietary zinc deficiency in testes of male albino rats. *Die Nah-rung.*;1:65-73.
2. **Parasade AS and Oberleas D. (1974) :** Thymidine kinase activity and incorporation of thymidine into DNA in zinc deficient tissue. *J. Lab. Clin. Med.*; 83:634-639.
3. **Chesters JK. (1978) :** Biochemical functions of zinc in animals. *World Rev. Nutr. Diet*; 32: 135 –1540
4. **Pitts WJ, Miller WJ, Fosgate OT, Morton JD, Clifton CM. (1966) :** Effect of zinc deficiency and restricted feeding from two to five months of age on reproduction in Holstein bulls.; 49:995-1000.
5. **Miller WJ, Pitts WJ, Clifton CM, Schmittle. (1967) :** Experimentally produced zinc deficiency in the goat. *J. Dairy Sci.*; 47: 556-559.
6. **Orgebin-Crist MC, Freeman M, Barney G.H. (1971) :** Sperm formation in zinc deficient rats. *Ann. Biol. Anim. Biochim. Biophys.*;11:547-558.
7. **Dinsdale D, Williams RB. (1980) :** Ultrastructural changes in the sperm-tail of zinc deficient rats. *J. Comp. Pathol.*; 90:559-566.
8. **Lei KYA, Abbasi A, Prasad AS. (1976) :** Function of pituitary

gonadal axis in zinc-deficient rats.

Amer.J.Physiol.; 230:1730-1732.

tis. Arch. Histol. Cytol.;54:401-410.

- 9.Hesketh J E. (1982) : Effects of dietary zinc deficiency on Leydig cell ultrastructure in the boar. J. Comp. Pathol.; 92: 239-247.

- 10.Walker MP and Perantoni A. (1988) : In vitro assesment of target cell specificity in cadmium carcinogenesis: interactions of cadmium and zinc with isolated interstitial cells of the rat testis. J In Vitro cellul & Develop Biol; 24: 558-565.

11. Vernet P, Fluton N ,Wallace C, Aitken RJ. (2001) : Analysis of reactive oxygen species generating systems in rat epididymal soermatozoa Biol repord Oct;65(4)1102-13.

12. Udea H, Kayama F, Mori N, Doi Y, and Fujimoto S. (1991) : Effects of dietary zinc deficiency on protein secretory functions of the mouse tes-

- 13.Nistal M, Jimenes F, Paniagua R. (1990) : Sertoli cell types in Sertoli-cell-only syndrome: relationships between Sertoli cell morphology and etiology. Histopathology;16: 173-180 .

- 14.Reeves PG and O'Dell BL. (1988) : Zinc deficiency in rats and angiotensin-converting enzyme activity: Comparative effects on lung and testis. J. of Nutrition.; 118:622-626 .

- 15.Russel L.D., Volg AW, and Webwe JE. (1987) : Actin localization in male germ cell intercellular bridges in the rat and ground squirrel and disruption of bridges by cytochalasin D. Am. J. Anatom,180:25-40 .

- 16.Mehta U, Mehta SN, Georgi GC, Mehta S, et al. (1989) : Effect of dietary zinc and copper on peripheral blood plasma cholesterol, testosterone and histomorphology of testes in rats. Indian J. of experimental biology.; 27 (5):469-471.