

OSSICULAR CHAIN TRAUMA DURING MIDDLE EAR ENDOSCOPY

By

Alaa A. Abou-Bieh, MD

From

Department of Otolaryngology, Faculty of Medicine,
Mansoura University, Mansoura, Egypt

ABSTRACT

objectives:

- 1- Evaluate the risk of ossicular chain trauma and injuries due to different middle ear endoscopic techniques and maneuvers.
- 2- Describe types, incidence and causes of these injuries.
- 3- Suggest methods to avoid them.

Methods:

Thirty temporal bones were approached utilizing 0°, 30° and 70° otoendoscopes with 2.7 mm and 4 mm diameters. Three areas were systematically approached in each bone: retrotympanum, protympanum and epitympanum. They were also manipulated using three sets of otologic surgical instruments: regular straight, regular curved and especially designed for endoscopic ear surgery.

Results:

The most common injury was the fracture of the posterior stapedial crus (27%). Other types were incudostapedial joint dislocation (23%), fracture of foot plate (23%), stapes dislocation (17%), fracture both stapedial crura (13%), fracture of the incus long process (6%) and incudomalleolar joint dislocation (3%). Single injuries were 44% and combined or multiple injuries were 56%. Highest incidence of injuries was with the 70° otoendoscope (89%) and with both the straight and curved regular instruments (67%). The diameter of otoendoscopes did not affect the number of injuries. Positioning of the scopes and familiarity with the technique reduced the incidence of trauma.

Conclusions:

Middle ear endoscopy can lead to

MANSOURA MEDICAL JOURNAL

a significant risk of ossicular chain injuries with their sequelae on hearing. Minimizing this risk necessitates adequate familiarity with the anatomy, techniques and otoendoscopes and usage of especially designed surgical instruments. In addition, combining both microscopic and otoendoscopic approaches or surgically assisted otoendoscopic approaches can reduce this risk considerably.

INTRODUCTION

Using otoendoscopes in middle ear and lateral skull base surgery have become an increasing trend nowadays due to the added indisputable benefits they can provide. However, as any surgical tool or technique, using otoendoscopes may carry certain defects, risks and complications. The published literature described and mentioned some types of these risks and complications. The main interest of most of authors was the surgical limitations and drops of the technique.¹⁻⁸ This included the loss of binocular vision and depth perception, one hand only available for surgery and the necessity of special training and relatively long learning curve.^{1-3,5} In addition,

there were the concerns about the need for special instruments and setup, the unreachable areas, the failure of the technique or prolongation of the operation time due to the anatomical limitations or bloody field and the debate about the incidence of residual disease.^{1,2,4-6} Thermal effects and how to minimize them were also the interest of some studies.^{7,8} The direct trauma and residual traumatic sequelae draw the attention of others.^{9,10} The injuries might affect the tympanic membrane and/or middle ear contents including the ossicular chain. To the best of our knowledge, none of the published literature studied the risk of the ossicular chain trauma with middle ear endoscopy in details.

The aim of our work is to try to explore the risk of ossicular chain different trauma types and injuries due to the different middle ear endoscopic techniques and maneuvers and also to try to describe types, incidence and causes of these injuries beside suggesting some methods to avoid them.

MATERIALS AND METHODS

Thirty fresh frozen temporal

bones were approached utilizing 0°, 30° and 70° otoendoscopes with 3 mm and 4 mm outside diameters (rigid Hopkins® rod - Karl Storz Endoscopy-America, Culver City, California) and 2.7 mm outside diameter (rigid Otoview® endoscopes - Gyrus, USA). A three-chip Telecom® video camera (Karl Storz Endoscopy-America, Culver City, California) and a software Digividio-Telecom® (Karl Storz Endoscopy-America, Culver City, California) were used. All of the procedures were performed working from the images on the monitor. Also a digital computer system - Photoswit® - was used to digitalis the pictures (Photoswit, USA).

To the best of our knowledge, all bones came from adult cadavers. There were 18 right temporal bones and 12 left. All bones were dissected by the same approach: three areas were systematically approached, retrotympanum, protympanum and epitympanum and were approached via two approaches the lateral transcanal approach and the posterior epitympanic (attic) approach. They were also manipulated using three sets of Otologic surgical micro-instruments: regular straight, regular

curved and special set of micro-endoscopic instruments which are especially designed for endoscopic ear surgery. Micro-endoscopic instruments included the Thomassin set® (Karl Storz-America, Culver City, California) and Telischi Otoview® set (Gyrus, USA). While approaching the different anatomical areas, any trauma or injury to the ossicular chain was noticed and recorded.

RESULTS

The total incidence of injuries and significant traumas was 34 injuries occurred in 23 temporal bones (TBs) of the 30 TBs which were included in the study (injuries general incidence and affected TBs were 77% of total study specimens). Single injuries were 15 injuries (occurred in 15 TBs) i.e. 44% of the total injuries (65% of affected TBs and 50% of the study specimens). The combined or multiple injuries were 56% of total injuries as there were 19 injuries in 8 TBs (35% of affected TBs and 27% of the study TBs) and the involved 8 TBs showed 4 injuries in 1 TB, 3 injuries in another TB and 2 injuries per each of the rest 6 TBs.

The injuries were as following:

MANSOURA MEDICAL JOURNAL

- 1- Fracture of the posterior stapedial crus (PSC #) was the most common injury and occurred 8 times (27% of the total study specimens).
- 2- Incudostapedial joint dislocation (ISJ #) occurred 7 times (23% of the total study specimens).
- 3- Fracture of the stapes foot plate (SFP #) occurred 7 times (23% of the total study specimens).
- 4- Stapes dislocation (St #) occurred 5 times (17% of the total study specimens).
- 5- Fracture both stapedial crura (S2C #) occurred 4 times (13% of the total study specimens).
- 6- Fracture of the incus long process (ILP #) occurred 2 times (6% of the total study specimens).
- 7- Incudomalleolar joint dislocation (IMJ #) occurred 1 time (3% of the total study specimens).


Combined or multiple injuries co-incidence are shown in table one.

There were some factors might have contributed to trauma and inju-

ries occurrence. The highest incidence of injuries was while approaching by the 70° otoendoscope (89% - 30 injuries) while it was minimal with both 0° and 30° otoendoscopes (this not mean injuries by direct trauma with scopes). Eighteen injuries (53% of total injuries) were due to direct trauma with surgical instruments while 16 injuries (47% of total injuries) were due to trauma with the scopes. In addition, 67% of the injuries (12 injuries) due to trauma by the surgical instruments, rather than by the scopes, were due to the usage of straight and curved regular Otologic micro-instruments and not the micro-endoscopic instruments. Injuries occurred mainly while approaching the anatomical areas via the lateral transcanal approach (24 injuries – 71%). There were 10 injuries (29%) with the posterior epitympanic approach. There was a considerable reduction (4:1) in the injuries incidence with the progress of the study.

Table 1. Injuries distribution for the affected Temporal Bones (T.B.)

T.B.	Type of Injury	T.B.	Type of Injury
T.B. 1	PSC # + SFP # + ISJ # + IMJ #	T.B. 9 to 12	PSC #
T.B. 2	PSC # + SFP # + ISJ #	T.B. 13 to 16	SFP #
T.B. 3	PSC # + SFP #	T.B. 17 & 18	ISJ #
T.B. 4	PSC # + ISJ #	T.B. 19 & 20	S2C #
T.B. 5 & 6	ISJ # + St #	T.B. 21 & 22	ILP #
T.B. 7 & 8	St # + S2C #	T.B. 23	St #



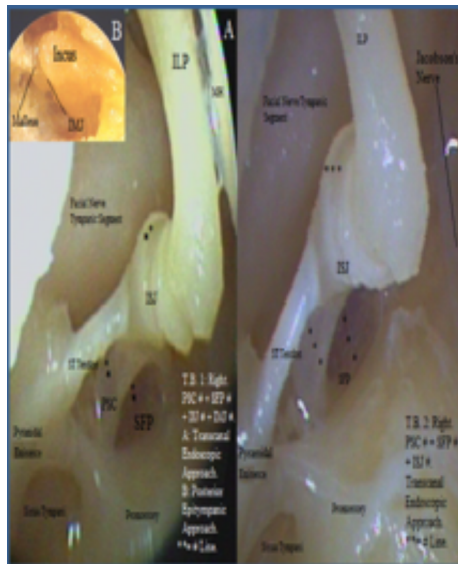


Figure 2. T.B. 1 & 2

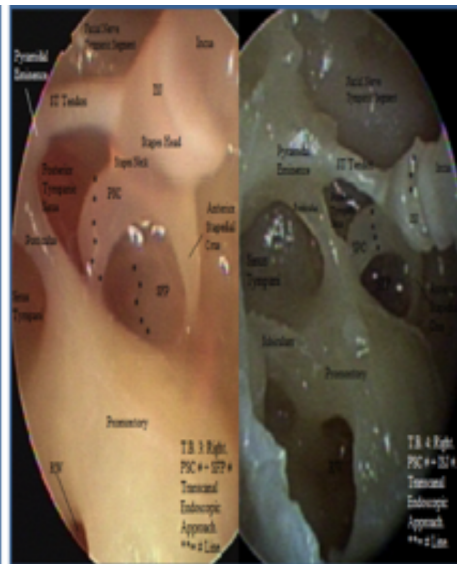


Figure 3. T.B. 3 & 4

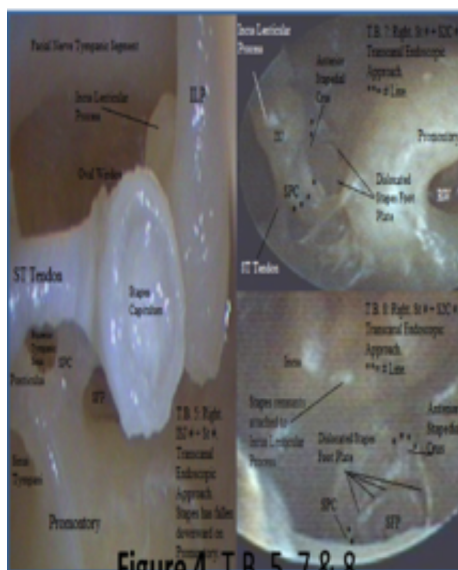


Figure 4. T.B. 5, 7 & 8

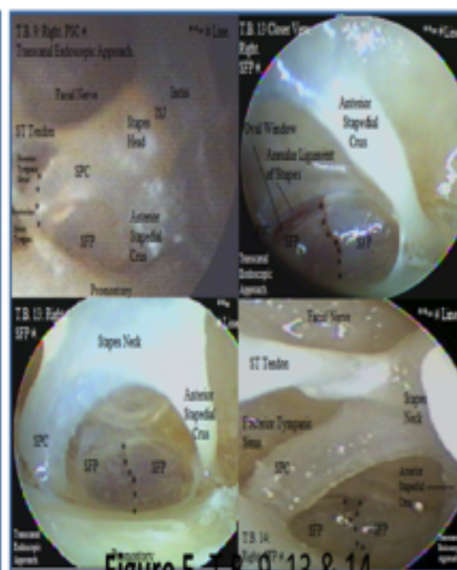


Figure 5. T.B. 9, 13 & 14




Figure 6. T.B. 17 to 23

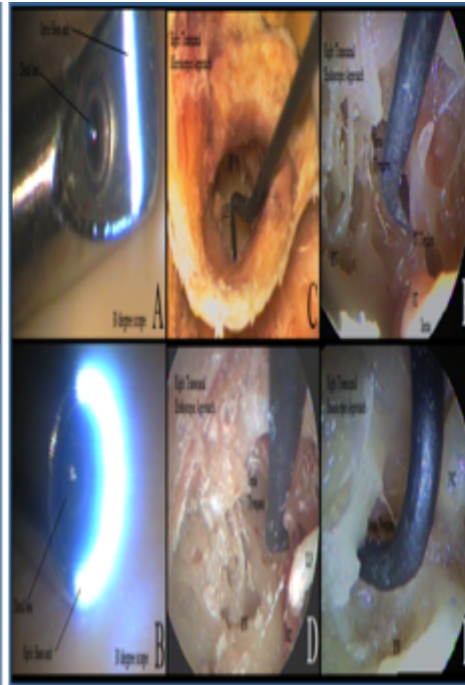


Figure 7. Instrumentation Risk

DISCUSSION

The results of this study show that otoendoscopic techniques can jeopardize the ossicular chain. The incidence of the injuries in the current study might look high and unreal or even biased against the technique. As a matter of fact, the reason for this higher incidence is that this study was designed to be performed while the author early training and practice of the techniques to accurately judge the risks and investigate the role of training with this tech-

niques. As most of the published studies^{1-6,9} have suggested, the current study has proved that this role is the most effective single factor in minimizing the risks. The familiarity with the techniques and mastering the positioning of the scopes, using the instruments, manipulating the structures and depending on one hand have reduced the incidence of trauma significantly.

This study results highlighted some factors to have a significant in-

fluence on the otoendoscopic techniques and in turn on the injuries incidence. By paying attention to some of these factors and trying to avoid some others the risk level might be very accepted due to the percentage of trauma related to these factors in the study results. These factors might be related to the surgeon, the technique, the scopes and instruments, the anatomy and the pathology (which is beyond the scope of this study). Besides the surgeon's experience as mentioned above, the type of the endoscopic approach, planning to it according to the anatomy and pathology, sticking to that approach and not trying to use it for areas or pathologies beyond its limits was very effective to reduce the injuries. In addition, combining both microscopic and otoendoscopic approaches or surgically assisted otoendoscopic approaches reduced the risks considerably. While the diameter of the otoendoscopes did not affect the number of injuries in the study, the angle of the scopes and their types regarding their optical assembly influenced the results significantly. Two types of the scopes were used, one type with limited optic fibers exit at distal end (Fig. 7a) and

the second type had its fibers exit all around at the distal end (Fig. 7b). The limited exit type was more risky. This can be explained by the same reason makes the higher angles scopes more risky, the blind spot created behind the distal end and as it is a must to come close to the objects to increase the magnification effect of the optics¹¹, this blind spot endangers that objects. The type, design, angle and size of instruments were very important in injuries occurrence. Although the usage of the micro-endoscopic instruments was associated with very minimal trauma, most of them need to be used very cautious as they still endanger the ossicles (Fig. 7c-f). In addition, this study agree with the idea of that during the course of training scopes and instruments are easily broken¹² due to the special nature of the TB cavities. Anatomical factors like the size of the external auditory canal and mastoid cavity and even the side of the TB either right or left were significant and should be taken in consideration.

CONCLUSION

Middle ear endoscopy can lead to a significant risk of ossicular chain

injuries with their sequelae on hearing. Minimizing this risk necessitates adequate familiarity with the anatomy, techniques and otoendoscopes and usage of especially designed surgical instruments. In addition, combining both microscopic and otoendoscopic approaches or surgically assisted otoendoscopic approaches can reduce this risk considerably.

REFERENCES

1. **Ghaffar S, Ikram M, Zia S, et al. (2006)** : Incorporating the endoscope into middle ear surgery. *ENT*; 85(9):593–6.
2. **Tarabichi M. (1999)** : Endoscopic middle ear surgery. *Ann Otol Rhinol Laryngol*; 108 (1):39–46.
3. **Pothier D. (2013)** : Introducing endoscopic ear surgery into practice. *Otolaryngol Clin North Am*; 46 (2):245–55.
4. **Thomassin J, Korchia D, Doris J. (1993)** : Endoscopic-guided otosurgery in the prevention of residual cholesteatomas. *Laryngoscope*, 310(8):939–43.
5. **Marchioni D, Alicandri-Ciufelli M, Gioacchini F, et al. (2013)** : Transcanal endoscopic treatment of benign middle ear neoplasms. *Eur Arch Otorhinolaryngol* 2013; 270:2997–3004.
6. **Ayache S, Tramier B, Strunski V. (2008)** : Otoendoscopy in cholesteatoma surgery of the middle ear: what benefits can be expected?; *29(8):1085–90*.
7. **Bottrill I, Perrault DF Jr, Poe D. (1996)** : In vitro and in vivo determination of the thermal effect of middle ear endoscopy. *Laryngoscope*; 106(2):213–6.
8. **Kozin ED, Lehmann A, Carter M, et al. (2014)** : Thermal effects of endoscopy in a human temporal bone model: implications for endoscopic ear surgery. *Laryngoscope*; 124(8):332–9.
9. **Horlbeck D, Ng M. (2014)** : Middle Ear Endoscopy. *Med-*

scape. Retrieved 2/81/2014
from <http://emedicine.medscape.com/article/860570>.

10. **Silverstein H, Rosenberg S, Arruda J. (1997) :** Laser-assisted otoendoscopy. ENT 1997;76(9):674–6, 678.

11. **Marchioni D, Alicandri-Ciufelli M, Grammatica A, et al.**

(2010) : Lateral endoscopic approach to epitympanic diaphragm and Prussak's space: a dissection study. Surg Radiol Anat; 32:843–52.

12. **Karhuketo T, Puhakka H, Laipala P. (1997) :** Endoscopy of the middle ear structures. Acta Otolaryngol Suppl.; 529:34-9.