

*Original Article*

# Hair Coil Strangulation of the Penis in Children: Single Center Experience in a Decade

Ahmed M. Shouman\*, Mohamed Abd El Wahab, Mohamed Aboul Fotouh Elgharably, Amr Mostafa

Department of Urology, Faculty of Medicine, Cairo University, Egypt; m.abdelwahab@kasralainy.edu.eg, m.a.grably@kasralainy.edu.eg, amrmostafa1981@yahoo.com

\* Correspondence: ashouman@kasralainy.edu.eg

Received: 18/11/2022; Accepted: 9/12/2022; Published online: 16/12/2022

## Abstract:

**Background:** Penile hair coil strangulation is a rare condition that might culminate in penile gangrene and amputation.

**Aim of work:** To report clinical presentation, management, complications and outcomes of hair coil strangulation of the penis in the pediatric age.

**Material and Methods:** We reviewed the data of 31 patients who presented with penile hair coil strangulation between January 2010 and December 2020 to the Urology Department at Cairo University Specialized Pediatric Hospital. Injury was graded as proposed by Bashir and El Barbary. Data regarding presentation, surgical intervention, complications and the outcomes were recorded.

**Results:** Mean age at presentation was  $4.43 \pm 2.5$  years. Thirty (97%) patients presented in the strangulation phase. Onset of symptoms was estimated to be 1-4 weeks earlier. All boys were circumcised. None had any neurological disease. Hair coil removal and medical management (antiseptic, antibiotics, anti-inflammatory) was done for all patients on the day of presentation. Examination under anesthesia and hair removal was done for 7 (22.5%) boys. Urinary diversion was not done on day of presentation. Mean follow up period was  $22.5 \pm 8.65$  months (6 - 36). Five (16%) boys had superficial skin injury grade (0) and were managed conservatively, 19 (61%) had partial transection of the urethra grade (1), 6 (19%) had complete transection of the urethra grade (2) and 1 (3%) had transection of the spongiosum and the cavernosum with amputated glans grade (3). Surgical intervention was delayed for 3 months after hair coil removal. Twenty six boys (84%) needed surgical intervention. Mean duration until catheter removal was  $7.65 \pm 3.05$  days (5-14). Twenty four boys (92%) had satisfactory cosmetic outcome (normal looking glans, no constriction ring), 2 (8%) had persistent constriction ring which was surgically corrected later and 4 (15.38%) had small urethrocutaneous fistula which was repaired after 6 months. None of our boys developed anastomotic strictures. Success rate was 77% after primary surgery.

**Conclusion:** Penile hair coil strangulation is a rare condition that can be easily misdiagnosed as balanitis, proper diagnosis requires high index of suspicion. Delayed single stage surgical intervention gives chance for inflammation to subside with satisfactory functional and cosmetic outcome.

**Level of Evidence of Study:** III (1).

**Keywords:** Hair coil, strangulation of the penis, constriction ring, urethrocutaneous fistula, Cairo University.

---

## Introduction

Strangulation of the penis is a type of tourniquet syndrome that can be caused by various objects as hair strands, rubber bands, rings, threads or bottles (2). It can also affect different parts of the body as fingers, toes, uvula and even the clitoris (3, 4). In hair coil strangulation, the penis is entrapped by human hair coil usually around the coronal sulcus causing ischemia at the site of strangulation and the distal part of the penis resulting in various degrees of injury starting by superficial skin injury (grade 0) up to gangrene and amputation of the glans (grade 3), however most cases commonly present by urethrocutaneous fistula (grade 1) or complete transection of the corpus spongiosum (grade 2) (5). In most cases penile strangulation accidentally occurs, however it has been reported that some parents intentionally coil any

material around the penis to prevent nocturnal enuresis (6). The degree of injury is directly proportional to the duration of ischemia which is the time interval between the onset of strangulation till the hair strand is removed. Presentation during the acute strangulation phase can be easily mistaken for other causes and misdiagnosed as balanitis and thus delaying the removal of the constricting hair and causing ischemia to the penis at the coronal sulcus. We aimed to report our experience with this uncommon condition regarding the clinical presentation, management, complications, and outcomes of hair coil strangulation of the penis in the pediatric age.

## Subjects and Methods

We reviewed the data of 31 patients with penile hair coil strangulation presented to the outpatient clinic (OPC), Urology Department, Cairo University Specialized Pediatric Hospital, Abou El Reesh, between January 2010 and December 2020. The study conformed with the requirements of Revised Helsinki Declaration of Bioethics (2013)(7). Confidentiality and privacy of participants were ensured.

### Methods

The data of 31 patients with penile hair coil strangulation was recorded. The collected data included the presentation, grade of injury, surgical intervention, complications and the outcomes. Most of our children presented in the strangulation phase. They all underwent removal of the tourniquet which was always a tuft of hair, probably mother's hair. Children who were not cooperative were examined in operation room under light general anesthesia (GA), and the tourniquet was removed. Parents were instructed to disinfect the penis. Analgesic, antibiotic and anti-inflammatory were prescribed. Children were examined 1 week later and were graded according to the grading system proposed by Bashir and El Barbary (5) as follows: grade 0: superficial skin injury with no deep structure affection; grade 1: ventral injury and partial transection of corpus spongiosum with urethrocuteaneous fistula; grade 2: complete transection of the urethra and corpus spongiosum and grade 3: gangrenous glans with or without auto amputation.

Patients with superficial skin injury were managed conservatively with local care, antibiotics and anti-inflammatory drugs. Those who required surgical repair (grade 1, 2 and 3), surgery was delayed for at least three months after hair removal. We followed the general principles of repair for these cases as follows (8): Patients with urethrocuteaneous fistula (partial transection), proper dissection of the fistula, trimming of the edges and transverse closure was done using continuous 6/0 Vicryl sutures (Ethicon Inc, Somerville, NJ). A second layer from nearby dartos was used to cover the suture line and decrease fistula rate. Urethral catheter was kept for 5-7 days.

Patients with complete transection of the urethra, proper dissection of the proximal and the distal ends of the urethra and the corpus spongiosum and a direct end to end anastomosis, after spatulation of both ends, was carried out with 3-4 interrupted 6/0 Vicryl sutures taking both the urethra and spongiosum. A second layer from nearby dartos was used to properly cover the anastomosis. Overlying skin was freshened and closed using 6/0 Vicryl sutures. Urethral catheter was kept for 10-14 days. Care had to be taken to completely release the constriction ring by good dorsal dissection and release all the fibrous tissue and reunite the glans to the corpus cavernosum with interrupted 5/0 Vicryl sutures. Only one boy with grade 3 injury gave history of penile strangulation 3 months earlier. On examination, the patient had buried penis and meatal stenosis. We primarily degloved the shaft of the penis and ventrally spatulated the urethral opening to create a new meatal opening. Full thickness skin graft was taken to cover the penile shaft and fashion a glans. Follow up of the patients was done in outpatient clinic every week for the first month, every 3 months for the first year and then when necessary thereafter. Parents were instructed to care about the wound, follow the urine stream and from where it comes. A video for the child while voiding was requested with each visit. Careful examination was done each visit. Successful repair was defined as restoring good urine flow from the external urethral meatus only and satisfactory cosmetic appearance approved by the treating doctor as well as the parents (a normal looking glans with no constriction rings).

### Statistical Analysis

Data were statistically described in terms of mean  $\pm$  standard deviation, median (range) and number (percent) when appropriate. Statistical calculations were done using computer program IBM SPSS (Statistical Package for the Social Science, IBM Corp, Armonk, NY, USA) release 22 for Microsoft Windows.

## Results

Total number of cases was 31. Mean age was 4.43 ( $\pm 2.5$ ) years, time interval between the onset of symptoms and presentation was roughly estimated to be 1-4 weeks as the exact onset was usually unnoticed by the parents. Mean follow up period was 22.5 $\pm$ 8.65 months (6 - 36 months). Most cases presented in hot summer months. Thirty (96.7%) boys presented in the strangulation phase with varying degrees of pain, swelling and inflammation of the glans starting at the coronal sulcus. Twenty five (81%) boys with grade 1 and 2 injuries had purulent discharge, constriction ring and the caretaker noticed urine coming from normal meatus as well as from the site of inflammation. (Table 1).

**Table 1.** Clinical Presentation of the studied boys with hair coil strangulation of penis.

	Number (total=31)	%
Previously Circumcised	31	100
Pain, swelling, balanitis like symptoms	30	97
Constriction ring	25	81
Urinary fistula	1	3
Glans amputation, buried penis	0	0
Associated neurological disease	0	0

All boys were previously circumcised and had a normal looking external urethral meatus. None of our boys had any neurological disease. Hair coil was removed on the day of presentation in outpatient clinic for 23 boys (74%) while 7 boys (22.5%) were too anxious and the tuft of hair was deeply buried and had to receive light general anesthesia in operating room to remove the hair coil on same day too. We did not place any diverting urinary catheters at the time of presentation. All boys were discharged home after hair coil removal. One boy presented with buried penis and amputated glans with history of penile strangulation 3 months before presentation.

Five boys (16%) had superficial skin injury and were managed conservatively, none of those boys had any complication. Nineteen (61%) boys had partial transection of the urethra, 6 (19%) boys had complete transection of the urethra and 1 (3%) had transection of the spongiosum and the cavernosum with amputated glans. (Table 2). Twenty six (84%) boys needed surgical intervention which was delayed for 3 months from time of presentation. One stage repair was done for all patients. All patients were repaired as described earlier over a Nelaton catheter which was kept for a mean period of 5.95 $\pm$ 0.85 days in grade 1 and 12 $\pm$ 1.4 days in grade 2 injuries. Mean duration until catheter removal for all patients was 7.65 $\pm$ 3.05 days. Patients were followed up to assess both functional and cosmetic outcome.

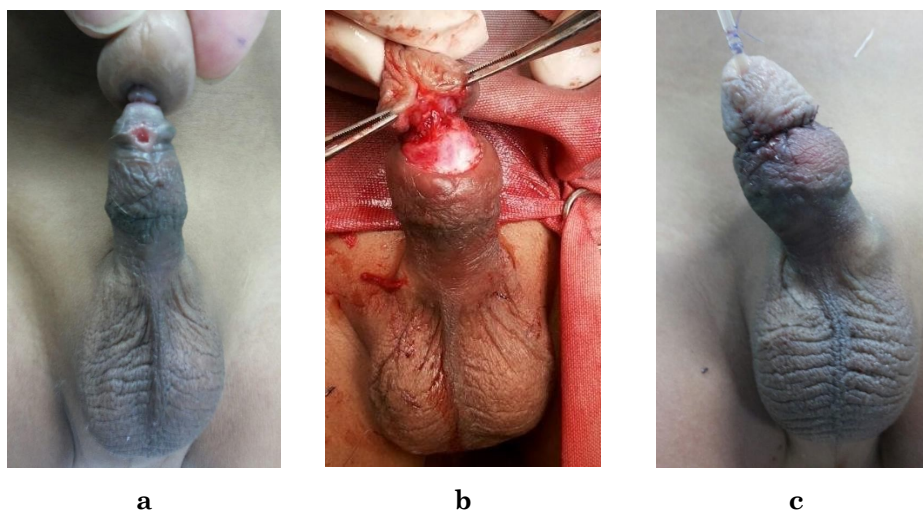
**Table 2.** Grading of injury, duration until catheter removal.

	Grade 0, superficial skin injury	Grade 1, partial urethral transection with fistula	Grade 2, complete urethral transection	Grade 3, complete transection with amputated glans	Total
Number (%)	5 (16.1%)	19 (61.2%)	6 (19.3%)	1 (3.2%)	31
Duration until catheter removal in days					
Mean	0	5.95 $\pm$ 0.85	12 $\pm$ 1.4	14	7.65 $\pm$ 3.05
Median	0	6	12	N/A	6.5
Range	0	5-7	10-14	N/A	5-14

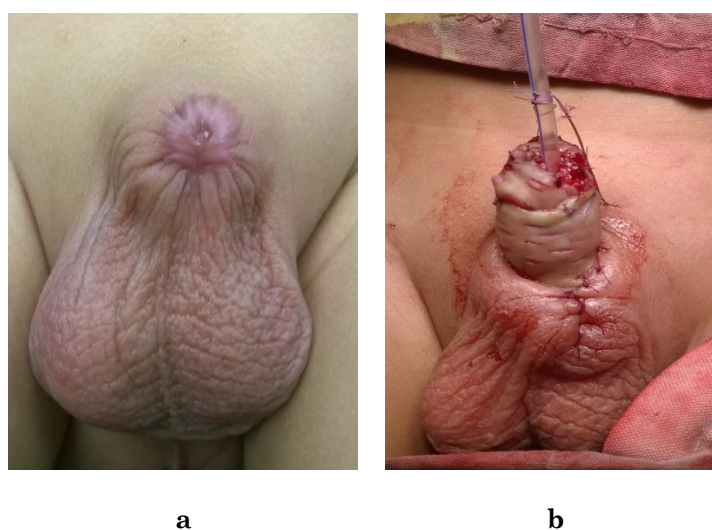
Out of the 26 boys who were operated upon, 24 (92%) had satisfactory cosmetic outcome while 2 (7.7%) had persistent constriction ring dorsally which was operatively managed after 6 months with good dorsal dissection to release fibrosis between the skin and underlying corpus. The patient with grade 3 injury and amputated glans on follow up had a good penile stump length with wide urethral opening which was very satisfactory for the parents. Four patients (15.38%) had urethrocutaneous fistula, 2 (10.5%) from the partial transection and 2 (28.5%) from the complete transection. Fistulae were small and were repaired 6 months postoperatively with 100 % cure. None of our patients developed anastomotic strictures. Success rate was 77% after primary surgical intervention. (Table 3).

**Table 3.** Complications after surgical intervention.

	Grade 1, Partial urethral transection with fistula	Grade 2, Complete urethral transection	Grade 3, Complete transection with amputated glans	Total
	Number %	Number %	Number %	Number %
Successful surgery	19 (61.2%)	6 (19.3%)	1 (3.2%)	26 (100%)
Complications	15	4	1	22 (77%)
Fistula	2 (10.5%)	2 (28.5%)	0	4 (15.3%)
Persistent Constriction Ring	2(10.5%)	0	0	2 (7.7%)



**Figure 1.** Child with partial transection of the urethra; (a) fistula and constriction ring, (b) surgery for partial transection of the urethra, note the healthy nearby Dartos for coverage (c)final appearance after correction



**Figure 2.** Child with amputated glans and buried penis; (a) at presentation, (b) after surgical correction



## Discussion

Hair coil strangulation of the penis or penile tourniquet syndrome is a condition, though scarcely addressed in literature is extremely dangerous and could end up in gangrene and amputation of the glans penis. It is almost always reported in circumcised young boys (9). Most publications report either a single case report or very few cases over many years. Imran et al reported only one case in an uncircumcised boy caused by a thread tied at the base of penis (10). Jennifer and Jean reported 1 case of penile strangulation in a 30 year old man with coronal urethrocuteaneous fistula due to a neglected condom ring on the coronal sulcus (11). Bouassida and coworkers reported a single case of penile hair coil strangulation in a 9 year old circumcised boy (12) while Qamar from Pakistan reported 15 cases in 27 years caused by hair and thread (13). We are not aware of the exact number of children who presented to our outpatient clinic in the decade 2010-2020, but the rough estimate is more than 11,000 children. The frequency of hair coil strangulation is very rare almost 0.002%. Mother's hair falls and coils around the penis usually at the coronal sulcus and is usually unnoticed. The hair starts to dry and strangulates around the glans penis causing initial edema and inflammation followed by gradual ischemia and injury (14, 15).

Pain, swelling and inflammation are the usual presenting symptoms which are easily mistaken for infection, trauma or insect bites for which antibiotics and antiseptics are usually prescribed but the inflammation worsens. If the condition is unnoticed or misdiagnosed, ischemia to the underlying tissues occurs resulting in various degrees of urethral injury and urinary fistula that could end up in glans ischemia, gangrene and amputation. The presence of balanitis like symptoms together with the pathognomonic constriction ring and coronal urinary fistula in a previously circumcised boy are usually diagnostic.

Management of such cases starts by the high index of suspicion of the surgeon and the awareness of the parents or the caretaker to seek medical care as early as they notice unexplained penile swelling and edema. Early diagnosis and removal of the strangulating object is the only way to stop the cascade of complications. The surgeon must carefully examine the coronal sulcus for any strangulating object in any circumcised boy with balanitis. Other factors can affect the severity of injury as the time from onset to diagnosis, the degree of strangulation by the hair coil and the inflammatory reaction to the hair strand (8). We noticed that most of our patients presented in hot summer months where young boys from rural areas take off all their clothes and thus increasing the risk of hair coiling around the penis. This is just an assumption.

In our series, most of our patients presented in the strangulation phase. Presentation started with pain, swelling and inflammation of the glans that was not resolving with treatment. That might explain why 24 (77.5%) of our patients presented with milder grades of injury (grade 0, 1). We always carefully examine any circumcised boy presenting with penile swelling and inflammation especially if parents report urine coming from an abnormal opening as well as from the normal meatus. We managed to find and remove the strangulating hair in the outpatient clinic for 74% of our patients and under anesthesia for the rest of our patients. We preferred to delay the surgical repair for three months after hair removal to give chance for tissues to recover from the ischemic damage caused by strangulation and to allow enough time for the infection to subside, however there is no consensus in literature about the timing of repair. We performed a single stage repair for both partial and complete urethral transection.

In 2010, Badawy and colleagues published their series on 25 cases with hair coil strangulation. Unlike us, they stated that their patients presented neither in the stage of edema nor in the stage of penile amputation. 18/25 (72%) of their patients presented with complete urethral transection. They performed early one stage repair and reported complications in four patients (16%) in the form of annular anastomotic narrowing in two cases that was managed endoscopically and fistula in the other two cases that was surgically repaired after 1 year (8).

Other surgeons prefer delayed repair, Bashir and El Barbary recommended delayed repair after six months (5). Abouzeid and Soliman performed staged repair for 16 boys with penile hair coil strangulation six months after hair removal and reported successful surgery for all patients (16). To our knowledge, our study is one of the largest series reporting such a rare case till present with 31 cases. We had a reoperation rate of 23% (6/26), we noticed higher fistula rate with complete transection of the urethra when compared to partial transection 28.5% and 10.5 %, yet the number of the studied groups is too small. The 2 cases with persistent constriction



ring were our first 2 cases, we were afraid to dissect more aggressively dorsally as this might affect the vascularity of the glans. This was avoided in later cases as we managed to dissect between the overlying skin and the underlying cavernosum to release the constriction without affecting the glans.

## Conclusion

Although rare, hair coil strangulation can cause severe complications if neglected or passed unnoticed. The main point for proper management is the high index of suspicion of the examining physician beside the awareness of the caretaker. Our work supports delayed single stage repair 3 months after hair removal to give chance for tissues to recover from the ischemic damage and to allow enough time for the infection to subside. Surgical correction done by experienced surgeons has good functional and cosmetic outcome.

## Author Contributions:

Ahmed M Shouman: Data analysis, interpretation, drafting and writing. Mohamed Abd El Wahab: Data acquisition, analysis, interpretation and writing. Mohamed Aboul Fotouh Elgharably: Data analysis, interpretation, writing, and revision. Amr Mostafa, Data acquisition, revision, and final approval. All authors have approved the published version of the manuscript.

## FUNDING

Authors declare there was no extramural funding provided for this study.

## CONFLICT OF INTEREST

The authors declare no conflict of interest in connection with the reported study. Authors declare veracity of information.

## References

1. S. Tenny, M. Varacallo, *Evidence Based Medicine*. (StatPearls Publishing; Treasure Island (FL), 2020; <https://www.ncbi.nlm.nih.gov/books/NBK470182/>).
2. J. M. Kirtane, K. V. Samuel, Hair coil strangulation of the penis. *Journal of Pediatric Surgery*. **29**, 1317–1318 (1994).
3. B. Peckler, C. K. Hsu, Tourniquet syndrome: A review of constricting band removal. *The Journal of Emergency Medicine*. **20**, 253–262 (2001).
4. J. L. Bacon, J. T. Burgis, Hair Thread Tourniquet Syndrome in Adolescents: A Presentation and Review of the Literature. *Journal of Pediatric and Adolescent Gynecology*. **18**, 155–156 (2005).
5. A. Y. Bashir, M. El-Barbary, Hair coil strangulation of the penis. *J R Coll Surg Edinb*. **25**, 47–51 (1980).
6. J. Sheinfeld, L. R. Cos, E. Erturk, A. T. K. Cockett, Penile Tourniquet Injury Due to A Coil of Hair. *Journal of Urology*. **133**, 1043–1044 (1985).
7. World Medical Association, WMA Declaration of Helsinki- Ethical Principles for Medical Research Involving Human Subjects (2013), (available at <https://www.wma.net/policies-post/wma-declaration-of-helsinki-ethical-principles-for-medical-research-involving-human-subjects/2013/>).
8. H. Badawy, A. Soliman, A. Ouf, A. Hammad, S. Orabi, A. Hanno, Progressive hair coil penile tourniquet syndrome: multicenter experience with 25 cases. *Journal of Pediatric Surgery*. **45**, 1514–1518 (2010).
9. A. J. Thomas, J. W. Timmons, A. D. Perlmutter, Progressive penile amputation. *Urology*. **9**, 42–44 (1977).
10. D. Imran, J. Ahmed, T. Shah, Delayed presentation of paediatric penile constrictive band injury. *British Journal of Plastic Surgery*. **56**, 300–302 (2003).
11. J. A. Tash, J. F. Eid, Urethrocutaneous fistula due to a retained ring of condom. *Urology*. **56**, 508 (2000).
12. K. Bouassida, K. Ben Ahmed, M. Ben Othmen, M. Jaidane, Penile hair coil strangulation in a 9-year-old patient: Surgical management and review of the literature. *Annals of Medicine and Surgery*. **60**, 50–55 (2020).
13. J. Qamar, Z. Kazmi, B. Dilawar, Z. Nazir, Penile strangulation injury in children — Reconstructive procedure and outcome. *Journal of Pediatric Surgery*. **55**, 1165–1168 (2020).



14. Col. N. R. Dar, S. Siddiqui, Lt. Col. R. Qayyum, M. T. Ghafoor, Hair Coil Strangulation? An Uncommon Cause of Penile Edema. *Pediatr Dermatol.* **24**, E33–E35 (2007).
15. J. J. Alpert, R. Filler, H. H. Glaser, Strangulation of an Appendage by Hair Wrapping. *N Engl J Med.* **273**, 866–867 (1965).
16. A. A. AbouZeid, M. H. Soliman, Surgical Management of Hair-coil Penile Injury: Anatomical Insights and Grading System. *Urology.* **98**, 154–157 (2016).



© 2022 submitted by the authors. Open access publication under the terms and conditions of the Creative Commons Attribution (CC- BY- NC- ND) license. (<https://creativecommons.org/licenses/by-nc-nd/2.0/>).