

EFFICACY OF PENTOXIFYLLINE AS AN ANTIFIBROTIC DRUG IN EXPERIMENTAL MURINE SCHISTOSOMAL HEPATIC FIBROSIS

By

EMAN A. KHALIFA¹ AND DALAL M. NEMENQANI²

Departments of Microbiology¹ and Pathology², Faculty of Medicine, Taif University, Taif, Kingdom of Saudi Arabia

Abstract

This study evaluated the possible antifibrotic effect of pentoxifylline on experimentally induced schistosomal hepatic fibrosis and its effect on serum leptin and transforming growth factor- β 1 levels as possible antifibrotic mechanisms in correlation with the hepatic fibrosis indices.

A total of ninety clean laboratories bred, males Swiss, albino mice were included, of which ten mice served as a control non-infected, non-treated group and sacrificed at one time. Eighty mice, each was subcutaneously infected with 50 *Schistosoma mansoni* cercariae and classified into groups: GI (infected & non-treated), GII (infected & treated with Mirazid[®]), GIII (infected & treated with Pentoxifylline[®]) and GIV (infected & treated with a combination of Mirazid and Pentoxifylline). Each group was further subdivided into 2 subgroups; subgroup 'a' which started treatment at 6th week post-infection (P.I.) and sacrificed at the end of 9th week P.I. and subgroup 'b' which started treatment at 14th week P.I. and sacrificed at the end of 17th week P.I. The efficacy of the treatment was assessed by histopathological examination of the liver with measurement of granuloma sizes, estimation of hydroxyproline content in the liver, and assessment of serum levels of leptin and transforming growth factor- β 1 (TGF- β 1)

Mirazid (MZD) caused significant reductions in granuloma sizes and hepatic hydroxyproline content and caused non-significant reductions in serum levels of leptin and transforming growth factor- β 1 at 9th & 17th weeks P.I (GII). Pentoxifylline (PTX) caused significant reductions in granuloma sizes, hepatic hydroxyproline, and serum levels of leptin and transforming growth factor- β 1 at the 9th & 17th weeks P.I (GIII). While combined therapy of both MZD & PTX in GIV caused more reductions in granuloma sizes, hepatic hydroxyproline, and serum levels of leptin and TGF- β 1 at the 9th & 17th weeks P.I when compared to the other groups.

Key words: Mice, Schistosomal hepatic fibrosis, Mirazid, Pentoxifylline, Histo-pathology.

Introduction

Schistosomal eggs trapped in the portal pre-sinusoidal venules induce a granulomatous inflammatory reaction with subsequent fibrosis, with a dynamic potentially reversible process mediated through the immunological responses to parasite eggs trapped in the liver (Cheng *et al*, 2013). The basic pathological changes of liver fibrosis are the excessive accumulation of extra-cellular matrix proteins (ECM). The major components of ECM, types I & II collagen constitute more than 95% of the total content of increased collagen in liver fibrosis. Activated hepatic stellate cells (HSCs) and portal fibroblasts have been identified as major collagen-producing cells in the injured liver. These cells are activated by fibrogenic cytokines such as leptin, transforming growth factor β 1

(TGF- β 1), and angiotensin II (Benyon and Iredale, 2000). Activated HSCs migrate and accumulate at the sites of tissue repair, secreting large amounts of ECM and regulating ECM degradation (Gabele *et al*, 2003).

Both CD4⁺ lymphocytes and Kupffer cells produce transforming growth factor β 1 (TGF- β 1) and fibrogenic mediators after contact with soluble egg antigen, TGF- β 1 is a multipotent cytokine recognized as playing an important role in regulating cell growth and development and implicated as a major stimulator of tissue fibrosis by stimulating fibroblast proliferation, activation and extra-cellular matrix production, particularly collagen and fibronectin, and reduces their degradation and the most critical cytokine in determining the process of fibrogenesis in schistosomiasis (Miao *et al*, 2014).

The adipocytokines, a group of cytokines produce exclusively from adipose tissue [i.e., leptin, adiponectin, resistin, plasminogen activator inhibitor (PAI)-1], play a pivotal role in the pathogenesis of liver fibrosis, leptin is one of the adipokines expressed in adipocytes and secreted into the bloodstream in proportion to adipose tissue mass, which lines indicate that leptin is a profibrogenic cytokine in the liver (García-Compeán *et al*, 2014). Leptin is produced by hepatic stellate cells (HSCs) but only following their activation where activation of HSCs is a central event in the fibrotic response to liver injury (Kamada, 2003).

Treatment with antifibrotic drugs was proposed as a way for preventing reversibility of advanced liver fibrosis and reducing its morbidity in schistosomiasis patients (Gianitrapani *et al*, 2014).

Emerging antifibrotic therapies are aimed at inhibiting the accumulation of fibrogenic cells and/or preventing the deposition of extracellular matrix proteins or inhibition of the accumulation of activated HSCs by modulating either their activation and/or proliferation or promoting their apoptosis (Bataller *et al*, 2003). Antagonists to hepatic fibrogenesis cytokine profile may be another strategy in the treatment of hepatic fibrosis. Since hepatic fibrogenesis depends largely on fibroblast growth factors, mainly TGF- β 1, so prevention of fibrosis by anti-TGF- β 1 intervention could be therapeutically useful in treating hepatic fibrosis (Choi *et al*, 2014).

El-Lakkany *et al*. (2011) stated that *S. mansoni* infection produced remarkable elevations in the serum levels of TGF- β 1, TNF- α , MMP-2 and the hepatic contents of Hyp, glutathione reductase (GR), MDA with significant reduction in reduced glutathione (GSH), glutathione peroxidase (GPx), glutathione-S-transferase (GST) and superoxide dismutase (SOD) when compared with their corresponding normal controls. They concluded that PTX experimentally attenuated liver fibrosis in early stages of *S. mansoni* infection through downregulation of profi-

brogenic cytokines, oxidative stress and collagen deposition..

Pentoxifylline (PTX) is a trimethylated xanthine derivative which is widely used in disorders of vascular perfusion due to its favourable effects on erythrocyte deformability, erythrocyte oxygen delivery, and its properties as a peripheral vasodilator. Grzela *et al*. (2003) reported that PTX was commonly used in the treatment of peripheral vascular diseases. It improves microcirculatory flow and tissue perfusion, with some immunomodulatory properties that presumably might affect the anticancer response and significantly promoted C-26-derived metastatic tumor growth in liver. They concluded that such effects could be relevant, since the stimulatory influence of pentoxifylline on proliferation does not appear to be a species- or tissue-specific.

On the other hand, Yakoot (2010) reported that Mirazid[®] is a patented preparation from a plant that had been used in folk medicine since ancient Egyptians (Myrrh). It was registered in Egypt for the treatment of schistosomiasis and fascioliasis, and that over 32 independent studies were reviewed and their results analyzed for its efficacy. The majority of these studies reported higher than 90% cure rates, that even higher in mixed than single trematodal infections in humans and in farm animals.

This study aimed to evaluate the possible antifibrotic effect of pentoxifylline on experimentally induced schistosomal hepatic fibrosis and also to investigate its effect on serum leptin and TGF- β 1 levels as possible antifibrotic mechanisms in correlation with the hepatic fibrosis indices.

Materials and Methods

Schistosoma mansoni cercariae shed from laboratory inbred infected *Biomphalaria alexandrina* purchased from Theodore Bilharz Research Institute, Giza, Egypt. Also, ninety Swiss albino mice of both sexes were included. Mice were clean laboratory bred, four weeks old and with average weight of 20-25 gm. Mice were maintained with free

access to commercial diet and water. Ten mice were served as control non-infected, non-treated group and sacrificed at one time for comparison. A total of 80 mice, each one was experimentally infected with 50 *Schistosoma mansoni* cercariae (Peters and Warren, 1969).

Mirazid[®] is a natural drug formed of the myrrh extract that derived from *Commiphora molmol* (*C. molmol*) tree, family: Burseraceae (Wallis, 1967). Much extract was obtained by spontaneously exudation from the cracks and fissures that commonly form in the bark. Myrrh consists of 7-17% volatile oil, 25-40% resin, 57-61% gum and 3-4% impurities (Hall and Oser, 1965; Marshall, 2004). Mirazid was given as two capsules for six successive days on an empty stomach an hour before breakfast (Tonkal and Morsy, 2008).

Pentoxifylline (PTX) is available as Trental[®] tablets (Hoechst Co.). It was given orally in a dose of 50 mg/kg/day and continued for 4 weeks.

Working protocol: The infected 80 mice were classified into the following five groups: GI comprised 20 infected mice, not receiving any drugs and served as an infected non-treated control group (G0) and divided into two subgroups: Subgroup Ia sacrificed at 9th week post-infection and subgroup Ib sacrificed at 17th week P.I. for comparison. GII comprised 20 mice which received MZD only. This group was divided into two subgroups: Subgroup IIa (10 mice) which received MZD at the 6th week P.I., subgroup IIb (10 mice) that received MZD at the 14th week P.I. These doses were followed by another dose after 9 days to assure killing of all eggs in the tissues (Giboda and Zdarska, 1994). GIII comprised 20 mice which received PTX only. This group was divided into two subgroups: subgroup IIIa (10 mice) which received PTX at the 6th week P.I. daily and continued for four weeks (from 6th to 9th week P.I.) and subgroup IIIb (10 mice) which received PTX at the 14th week P.I. for four weeks (from 14th to 17th

week P.I.). GIV comprised 20 mice which received a combination of both MZD and PTX. This group was subdivided into two subgroups: Subgroup IVa (10 mice) which received MZD and PTX at the 6th week P.I. (PTX continued for 4 weeks) and subgroup IVb (10 mice) received MZD and PTX at the 14th week P.I. (PTX continued for 4 weeks).

To assess the efficacy of PZQ and/or PTX on schistosomal hepatic fibrosis, animals of GsIa, IIa, IIIa and IVa were sacrificed at the end of the 9th week P.I. and animals of GsIb, IIb, IIIb and IVb at the end of the 17th week P.I. After sacrifice of mice, sera of all mice were collected and kept at -20°C for measurement of serum leptin and TGF-β1 levels. Livers were removed for histopathological examination, measurement of granuloma sizes and assessment of liver hydroxyproline content.

Histopathologic assay and measurement of granuloma sizes: One portion of the liver was fixed in 10% formalin and routinely dehydrated, embedded in paraffin and cut into sections 5μ in thickness. Some sections were stained with haematoxylin and Eosin (H&E) for histopathological examination and others stained with Masson's trichrome stain for collagen fibers staining. Measurement of the size of granulomas was done in H&E stained sections by the use of computer assisted morphometric analyzer (MacScope, Mitani Corporation, Fukui, Japan). The mean diameter of each granuloma was obtained by measuring two perpendicular diameters, for each section, ten granulomas were measured and the mean diameter of all lesions was then calculated using the method described by Jacobs *et al.* (1997).

Hydroxyproline assay: The other portion of the liver was frozen at -20°C and later processed for measurement of tissue hydroxyproline (Qiu *et al.*, 2014). Briefly, the protein was hydrolysed in 2 ml of 6 N HCl for 18 hours at 110°C. Then the reaction mixture was neutralized with sodium hydroxide titration to pH 7, and centrifuged at

1500rpm. Hydroxyproline in the samples was reacted with oxidant (1ml of 0.6 mol/L chloramines-T in acetate-citric acid buffer; Sigma) for 30 minutes and Ehrlich's reagent (7.5% p-dimethylaminobenzaldehyde; Sigma) in 60% perchloric acid (Fisher Chemical, Fair Lawn, NJ) at 65°C for 15 min, and hydroxyproline content was determined by spectrophotometer at 560 nm. Liver hydroxyproline was quantitated against a standard curve set up with purified hydroxyproline (Sigma).

Assessment of serum TGF- β 1: TGF β 1 was assayed by the Biosource Multispecies TGF- β 1 kit (BioSource Immunoassay kit, Catalog # KAC 1688/KAC 1689). It is a solid phase sandwich ELISA. TGF β 1 was assayed according to manufacturer's instructions (Xiong *et al*, 2003).

Leptin was estimated for measuring fibrogenesis (Han *et al*, 2001). Leptin was assayed by mouse using sandwich ELISA (Bio Vendor, Cat. No: RD291001200) for the non-radioactive quantification of sera leptin after manufacturer's instructions.

Statistical analysis: Present data was conducted by mean, standard deviation, independent sample Student's t-test; analysis of variance (ANOVA) followed by Tukey's test, rank and spearman correlation (r) coefficient tests using SPSS V.12

Results

Four mice from GI, two from GII, three from GIII and two from GIV died normally.

The efficacy of treatment on granuloma diameters (Tab. 1) as compared to the healthy liver (control non-infected non-treated G0 (Fig. 1), H & E stained sections of the livers of the infected non-treated mice killed at the 9th week P.I. (GIa) showed numerous viable eggs surrounded by large periovular cellular granulomas composed mainly of polymorphonuclear leucocytes, eosinophils, lymphocytes, plasma cells, small number of macrophages and fibroblasts with schistosome pigment in portal areas (mean diameter of granulomas was 600.50±69.28) (Fig. 2). While in infected

non-treated mice, killed at the 17th week P.I. (GIb) granulomas decreased in size (mean diameter 515.05±92.47) and become less cellular in comparison to mice killed at 9th week P.I. with marked increase in connective tissue around eggs, diminished eosinophils with relative increase in lymphocytes and development of periportal fibrosis (Fig. 3), without significant difference in granuloma size between GIa & GIb.

In Masson's trichrome stained sections of GIb, collagen fibers appeared as abundant fibers oriented in various directions in some granulomas, while in others showed progressive accumulation and concentric orientation (Fig. 4). In the treated groups, significant reductions in granuloma sizes were detected in GIIa (infected and treated with MZD only; 497.93±51.45, $p<0.05$) (Fig. 5), GIIb (infected and treated with PTX alone; 429.44±47.45, $p<0.01$) (Fig. 6) and GIVa (infected and treated with both MZD & PTX; 188.66±36.82, $p<0.001$) at 9th week P.I. as compared to GIa (infected and non-treated, 600.50±69.28). Significant reductions in granuloma size was detected at 17th week P.I. in GIIb (375.33±54.11, $p<0.05$) (Fig. 7), GIIIb (266.42±39.06, $p<0.01$) (Fig. 8) and GIVb (141.97±39.72, $p<0.001$) (Fig. 9 & 10) as compared to GIb (515.05±92.47).

The eggs in G II (a&b) and GIV (a&b) died, while eggs in GI (a&b), GIII (a&b) were viable. Reduction in granuloma size was more significant in GIII (PTX treated) than GII (MZD treated) as compared to GI, with most significant reduction in granuloma size in GIV as compared to GI, GII & GIII.

In Masson's trichrome stained sections, the collagen fragmented and dispersed into a loose amorphous matrix in GII and GIII at the 17th week P.I. (Fig. 11), in GIV, there was a marked resolution of collagen fibers and the granulomas were presented as small scars (Fig. 12).

The hepatic hydroxyproline assay (Tab. 2) and control infected non-treated GIb showed a significant increase in total hepatic hydroxyproline levels at the 17th week P.I.

(0.67 ± 0.06) as compared to GIa at the 9th week P.I. (0.46 ± 0.08 , $p < 0.001$). Treated Gs, showed significant decrease in HPO in GIIa (0.27 ± 0.05 , $p < 0.05$), GIIIa (0.26 ± 0.06 , $p < 0.01$), and IVa (0.18 ± 0.04 , $p < 0.001$) as compared to GIa (0.46 ± 0.08) at 9th week P.I. Also, there were significant decrease in HPO in GIIb (0.42 ± 0.07 , $p < 0.05$), GIIIb (0.36 ± 0.05 , $p < 0.01$), & GIVb (0.27 ± 0.15 , $p < 0.001$) as compared to GIb (0.67 ± 0.06) at 17th week P.I. The reduction in HPO was more significant in GIII (PTX) than GII (MZD) as compared to GI. The most significant decrease in HPO was in GIVa&b, which received a combination of PTX & MZD as compared to GIa&b, GIIa&b and GIIIa&b. The decrease in HPO content, when treatment started early (6th to 9th week P.I.) was more significant than that started late (14th to 17th week P.I.) in all treated groups.

The serum TGF- β 1 levels (Tab. 3) showed marked increased in infected, non-treated GIa (197.28 ± 11.41) & GIb (330.03 ± 35.15) as compared to control non infected, non-treated group (121.99 ± 5.74) with a significant difference ($p < 0.01$ and $p < 0.001$ respectively). In treated ones, serum TGF- β 1 levels decreased in GIIa (184.28 ± 16.81), GIIIa (157.65 ± 13.62) & GIVa (138.02 ± 11.22) in comparison to infected non-treated group (GIa) at 9th week P.I. with significant differences in GIIIa and GIVa ($p < 0.001$). Serum TGF- β 1 levels decreased in GIIb (282.40 ± 32.94), GIIIb (199.72 ± 11.20) & and IVb (164.85 ± 22.98) in comparison to G Ib; infected non-treated (330.03 ± 35.15) at

the 17th week P.I. with significant differences only in group IIIb ($p < 0.001$) and IVb ($p < 0.001$). The decrease of TGF- β 1 in MZD treated group was non-significant at the 9th and 17th weeks P.I as compared to GI (a&b). The most significant decrease in serum TGF- β 1 level was detected in GIVa & GIVb (treated with PTX & MZD) as compared to other groups.

Serum leptin (Tab. 4) showed marked increased in GIa (17.30 ± 2.55) & GIb (26.02 ± 2.41) as compared G0 (1.87 ± 0.41) with a significant difference ($p < 0.001$) at 9th and 17th weeks P.I. In treated ones, serum leptin levels decreased in GIIa (14.66 ± 2.20) GIIIa (10.84 ± 1.94) and GIVa (4.50 ± 0.90) in comparison to the infected non-treated group (GIa) but with significant differences at GIIIa ($p < 0.001$) and GIVa ($p < 0.001$). Also, serum leptin levels were decreased in GIIb (23.85 ± 3.06), GIIIb (14.91 ± 2.20) and GIVb (5.31 ± 1.7) in comparison to infected non-treated group (GIb) but with significant differences only at GIIIb & GIVb ($p < 0.001$). The decrease of serum leptin level in MZD treated G was non-significant as compared to GI at the 9th and 17th weeks P.I. The most significant decrease in serum leptin level was detected in GIVa and GIVb (treated with PTX & MZD) as compared to other Gs.

There was a significant (Tab. 5, Figs, 13, 14, 15) correlation between granuloma sizes in liver and hepatic HPO (collagen content) ($p < 0.001$), granuloma size and serum TGF- β 1 levels ($p < 0.05$) and granuloma size and serum leptin levels ($p < 0.05$).

Table 1: Mean diameters of granulomas (μ m) of groups at 9th & 17th weeks P.I.

Gs	9 th week P.I. (Ia)	17 th week P.I. (Ib)	ANOVA tukey's test
GI	$600.50 \pm 69.28^{a***}$	$515.05 \pm 92.47^{a***}$	GIa>GIIa, GIa>GIIIa, GIa>GIVa, GIb>GIIb, GIb>GIIIb, GIb>GIV
GII	$497.93 \pm 51.45^{*a***}$	$375.33 \pm 54.11^{*a***}$	GIIa<GIa, GIIb<GIb, GIIa>GIVa, GIIb>GIVb
GIII	$429.44 \pm 47.45^{***a**}$	$266.42 \pm 39.06^{***a*}$	GIIIa<GIa, GIIIb<GIb
GIV	$188.66 \pm 36.82^{***}$	$141.97 \pm 39.72^{***}$	GIVa<GIa, GIVa<GIIa, GIVa<GIIIa, GIVb<GIb, GIVb<GIIb, GIVb<GIIIb

Tukey's test $P < 0.05$ significant, *significant at (0.05), **significant at (0.01), ***significant at (0.001), ≠ : significant with GI. , a: significant with GIV. GIV most significant compared to all Gs.

Table 2: Estimated hydroxyproline levels ($\mu\text{g}/\text{gm}$ liver tissue) among groups at 9th & 17th weeks P.I.

Gs	9 th week P.I.	17 th week P.I.	ANOVA tukey's test
GI	0.46 \pm 0.08 ^{a***}	0.67 \pm 0.06 ^{a***}	Gla<Ib, Gla>IIIa, Gla>Iva, Glb>GIIb, Glb>IIIb, Glb>GIVb
GII	0.27 \pm 0.05 ^{a*}	0.42 \pm 0.07 ^{a**}	GIIa<Gla, GIIa>GIVa, GIIb<Glb, GIIb>GIVb
GIII	0.26 \pm 0.06 ^{a*}	0.36 \pm 0.05 ^{a*}	GIIIa<Gla, GIIIa>IVa, GIIIb<Glb, GIIIb>GIVb
GIV	0.18 \pm 0.04 ^{a***}	0.27 \pm 0.15 ^{a***}	GIVa<Gla, GIVa<GIIa, GIVa<GIIIa, GIVb<Glb, GIVb<GIIb, GIVb<GIIIb

Table 3: Serum TGF- β 1 levels (pg/ml) among groups at 9th & 17th weeks P.I.

Gs	9 th week P.I.	17 th week P.I.	ANOVA tukey's test
GI	197.28 \pm 11.41 ^{a***}	330.03 \pm 35.15 ^{a***}	Gla>G0, Gla>GIIIa, Gla>GIVa, Glb>G0, Glb>GIIIb, Glb>GIVb
GII	184.28 \pm 16.81 ^{a***}	282.40 \pm 32.94 ^{a***}	GIIa>GIVa, GIIa>GIIIa, GIIa>GIIIb, GIIb>GIVb
GIII	157.65 \pm 13.62 ^{a***}	199.72 \pm 11.20 ^{a***}	GIIIa<Gla, GIIIa>GIVa, GIIIb<Glb, GIIIb>GIVb
GIV	138.02 \pm 11.22 ^{a***}	164.85 \pm 22.98 ^{a***}	GIVa<Gla, GIVa<GIIa, GIVa<GIIIa, GIVb>Glb, GIVb<GIIIb-
G0	121.99 \pm 5.74		

Table 4: Serum leptin levels (ng/ml) among groups at 9th & 17th weeks P.I.

Gs	9 th week P.I.	17 th week P.I.	ANOVA tukey's test
GI	17.30 \pm 2.55 ^{a***}	26.02 \pm 2.41 ^{a***}	Gla>G0, Gla>GIIIa, Gla>GIVa, Glb>G0, Glb> GIIIb, Glb>GIVb
GII	14.66 \pm 2.20 ^{a***}	23.85 \pm 3.06 ^{a***}	GIIa>GIVa, GIIb>GIVb
GIII	10.84 \pm 1.94 ^{a*}	14.91 \pm 2.20 ^{a**}	GIIIa<Gla, GIIIa>GIVa, GIIIb<Glb, GIIIb>GIVb
GIV	4.50 \pm 0.90 ^{a***}	5.31 \pm 1.7 ^{a***}	GIVa<Gla, GIVa<GIIa, GIVa<GIIIa, GIVb> Glb, GIVb<GIIIb.
G0	1.87 \pm 0.41		

Table 5: Simple linear correlation (r) between granuloma size and other parameters.

Items	r	P. value
granuloma size & hydroxyproline	0.654***	< 0.001
granuloma size & TGF-B1 level	0.411*	< 0.05
granuloma size & leptin levels	0.397*	< 0.05

* Significant at P < (0.05), *** Significant at P< (0.001)

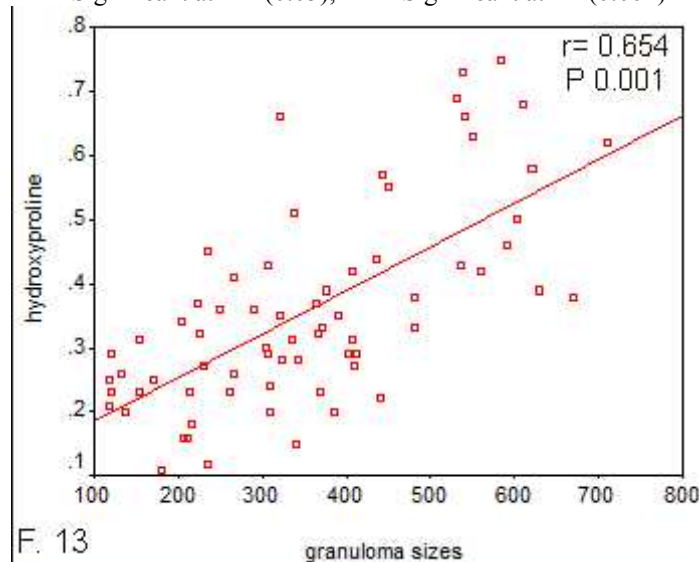


Fig. 13: Correlation between granuloma size and hepatic hydroxyproline levels

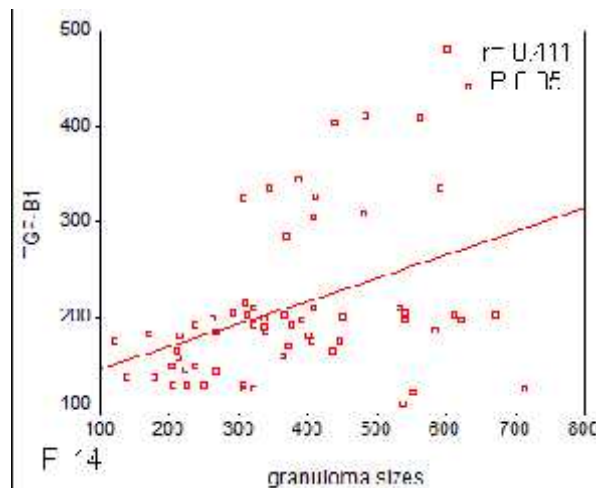


Fig. 14: Correlation between granuloma size and serum levels of TGF- β 1

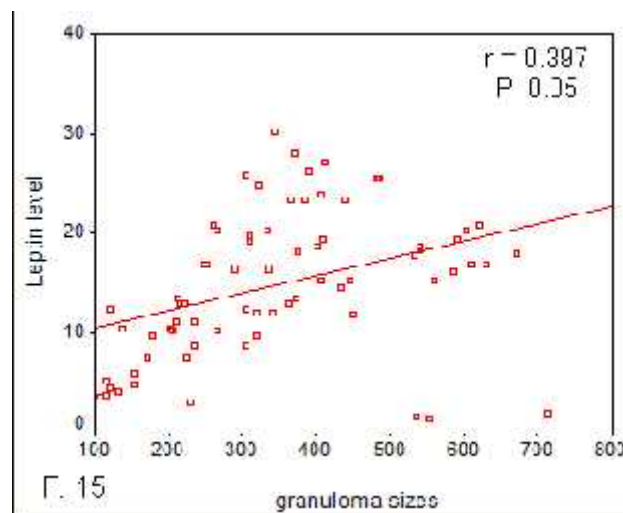


Fig. 15: Correlation between granuloma size and serum levels of leptin

Discussion

Regarding Mirazid, Omar *et al.* (2005) in Egypt compared mirazid and praziquantel. They concluded that praziquantel induced a significant hepatotoxic, genotoxic and carcinogenic effects, and was considered to be a hepatotoxic, genotoxic and carcinogenic drug. On the other hand, Mirazid seemed to be a safe and promising antiparasitic drug, free from hepatotoxic, genotoxic and carcinogenic effects.

Nomicos (2007) in USA reported that since antiquity, the genus *Commiphora* is composed of more than 200 species, and exploited as a natural drug to treat pain, skin infections, inflammatory conditions, diarrhea, and periodontal diseases. He added

that in more recent history, products derived from *C. myrrha* and various other species of *Commiphora* are becoming recognized to possess significant antiseptic, anesthetic, and antitumor properties. Auffray (2007) in France studied two types of antioxidant impact on sebum squalene peroxidation by UV irradiation. The first type was free radical scavenger (Butyl hydroxyl toluene and an olive extract rich in hydroxytyrosol). The second type was essential oil of *C. myrrha*, a singlet oxygen quencher. He found that essential oil of *C. myrrha* gave the best protection against squalene peroxidation, and that squalene peroxidation during solar exposure was mainly because of singlet oxygen and not due to free radical attack, and that sun care cosmetics should make use not only of

free radical scavengers but also of singlet oxygen quenchers. Al-Mathal and Fouad (2005) in Saudi Arabia successfully treated fascioliasis patients with Mirazid as two capsules (600mg) on an empty stomach an hour before breakfast for six consecutive days. Follow-up clinically and parasitologically was available in only seven fascioliasis patients who were completely cured. Baghdad and Al-Mathal (2010) experimentally used *Commiphora molmol* successfully as an anti-coccidial drug for domestic rabbit. Al-Mathal *et al.* (2010) reported that bertiellosis *studerii* patient was resistant to Niclosamide but successfully treated with *C. molmol* extract.

On the other hand, the liver fibrosis is the body's wound healing response to injury where a typical cascade of events occurs (Bataller and Brenner, 2005). This cascade includes injury; often with a component of oxidative stress which itself can amplify the fibrogenic cascade, followed by mobilization of the inflammatory cells and release of cytokines that amplify the overall response and contribute to the activation of the effector cells. Typical effector cells are matrix producing cells such as hepatic stellate cells (HSCs). Besides, liver disease is an independent risk factor for mortality in CF (Rowland *et al.*, 2014).

Understanding of the basis of hepatic fibrogenesis has advanced significantly in the past two decades, and with it, a field dedicated to therapeutic antifibrotics has emerged. A number of specific antifibrotic therapies have been tried, but have been met with poor or success. However, elucidation of the mechanisms responsible for fibrogenesis, with particular emphasis on stellate cell biology and the mechanisms underlying fibrogenesis has highlighted many putative novel therapies (Don, 2005). Graeser *et al.* (2009) stated that an overproduction of reactive oxygen species and impaired antioxidant defence accompanied by chronic inflammatory processes may impair joint health. Pro-inflammatory cytokines such as

interleukin-1beta (IL-1beta) and tumor necrosis factor alpha (TNF-alpha) stimulate the expression of metalloproteinases which degrade the extracellular matrix. They added that targeting of antifibrotic drugs to HSCs and fibrogenic cytokines is new strategy to block the fibrotic process.

In the present study, the pentoxifylline was tested alone and in combination with mirazid for treatment of schistosomal hepatic fibrosis. Histopathological examination of liver sections of GI (infected and non-treated) showed a non significant reduction in granuloma size with decreased cellularity in GsIb (infected non-treated, examined at 17th week P.I.) as compared to GIa (infected non-treated, examined at 9th week P.I.). The decrease in granuloma size in GIb can be explained by the natural immunomodulation of granuloma (Wyler, 1992). The present study also showed significant reductions in both granuloma size and hepatic hydroxyproline levels in MZD treated Gs (IIa & IIb), when compared to control ones in GIa & GIb. The decrease in both granuloma size and hepatic hydroxyproline levels in GII can be explained by results of Li *et al.* (2010) reported that once a mouse is cured from *Schistosoma*, granulomatous lesions in the liver shrink progressively afterwards, disappearing in 4 to 6 weeks after treatment, leaving scars. On the other hand, MZD caused a decrease in the levels of serum TGF- B1 and leptin but without significant as compared to GI.

On the other hands, pentoxifylline resulted in significant improvement in the estimated parameters of hepatic fibrosis (decreased in granuloma size, liver HPO, serum TGF-β1 and leptin levels) in GIII as compared to GI. The reduction in granuloma size in PTX G was more significant than MZD group when compared to GI. Reis *et al.* (2001) demonstrated that PTX decreased granuloma sizes and numbers in murine hepatic *Schistosoma*. They explained that the anti-fibrotic action of PTX on hepatic stellate cells was in response to transforming growth factor beta 1

(TGF β 1) which mediated by extracellular collagen degradation rather than by a reduction of collagen synthesis. They added that the lack of PTX effect on collagen synthesis may be due to the fact that the drug was administered after granulomas elicitation, when immune component cells were already stimulated. Mati *et al.* (2010) stated that the liver histological analysis showed a decrease in the inflammatory reaction and fibrous content of the granulomas studied, and a significant reduction ($P < 0.001$) in their mean diameter was observed in the groups of rodents treated with PTX in acute and chronic infection, when compared to their respective control groups.

The present histopathological examination of livers and biochemical assays the GIV that received both MZD and PTX showed the most significant reduction in fibrotic parameters (diminished granulomas sizes, hepatic hydroxyproline levels, decreased serum TGF β 1 and serum leptin levels) in comparison to GI (infected and non-treated), GII (given MZD only) and GIII (given PTX only). In Masson's trichrome stained sections for collagen staining, there was marked resolution of collagen in mice of GIV that treated with combined therapy (MZD & PTX), while there was scanty collagen in GII (treated with MZD) and GIII (treated with PTX only).

Collagen is secreted as a propeptide that contains high proportion of proline; the hydroxyproline arise from hydroxylation of proline residues by proline hydroxylase. This collagen accumulation could be inhibited by blocking proline hydroxylase activity. A common sense dictates that the earlier a fibrotic lesion is detected, the more likely it is to be amenable to therapy (Ramadori and Saile, 2004). The present results showed that a more significant decrease was observed in HPO content when treatment started early at the 6th week P.I. than at 14th week P.I. in the treated groups.

Tarcin *et al.* (2003) concluded that PTX, IFN- α and their combination have no

beneficial effect on experimental fibrosis induced by biliary obstruction. Miao *et al.* (2009) explained the capability of PTX to reduce the hepatic schistosomal fibrosis in a mouse model by its ability to decrease TGF- β 1, type I and type III collagens in hepatic tissue of mice with fibrosis. They stated that the ability of PTX to reduce the hepatic content of collagen III is similar to MZD and its effects on TGF- β 1 and type I collagen are weaker than MZD.

Concerning serum leptin and TGF- β 1 levels, in this study, they showed marked increase in the infected non-treated G as compared to non-infected, non-treated G indicating that leptin is a profibrogenic cytokine. Significant decreases in serum leptin levels were observed in GIII (PTX treated) and GIV (MZD and PTX treated) while the decreases in serum leptin levels in GII (MZD treated) were non-significant. The most significant decreases in serum leptin and TGF- β 1 were observed in GIV which treated with a combination of MZD and PTX. Several reports have implicated leptin as critical hormone in the development of liver fibrogenesis. In a number of studies, administration of recombinant leptin augments hepatic fibrogenesis induced by hepatotoxic chemicals (Ikejima *et al.*, 2001). Further, leptin-deficient ob/ob mice and leptin receptor (ObR)-deficient Zucker rats exhibit extremely poor profibrogenic responses in the liver caused by carbon tetrachloride (Leclercq *et al.*, 2000), thiouacetamide¹ and *Schistosoma* infection (Xiaokun *et al.*, 2005). Ikejima *et al.* (2005) stated that in these animal studies, leptin was shown to have only a permissive role in liver fibrosis, acting primarily by enhancing transforming growth factor β 1 mRNA in isolated sinusoidal endothelial cells and Kupffer cells, suggesting that leptin promotes hepatic fibrogenesis through upregulation of TGF β 1 in the liver.

Ding *et al.* (2006) confirmed the presence of leptin in activated but not quiescent HSCs, whereas only quiescent HSCs synthesized adiponectin mRNA and protein. Adiponectin

receptors were detected in both activated and quiescent HSCs, but only activated HSCs produced significant apoptosis after treatment with adiponectin. Cao *et al.* (2007) reported that leptin enhances alpha I collagen gene expression in HSCs stimulating collagen production through H₂O₂-dependent mechanism. Accordingly, they postulated that interference with leptin-induced oxidative stress by antioxidant may provide an opportunity for prevention of liver fibrosis. Yang *et al.* (2012) assessed the association between leptin gene promoter methylation and serum leptin concentrations in patients with impaired glucose regulation (IGR) and type 2 diabetes mellitus (T2DM). Lower levels of leptin gene promoter DNA methylation and serum leptin concentrations are associated with the development of diabetes. Measurement of the methylation status of leptin gene promoter and expression can facilitate early intervention of the disease. Zhai *et al.* (2013) reported that leptin increased β -catenin protein but not mRNA levels in cultured HSCs. Leptin induced phosphorylation of glycogen synthase kinase-3 β at Ser(9) and subsequent stabilization of β -catenin protein was mediated, at least in part, by ERK and p38 MAPK pathways. The leptin-induced β -catenin pathway reduced SREBP-1c expression and activity but did not affect protein levels of key regulators controlling SREBP-1c activity, and was not involved in leptin inhibition of liver X receptor α . In a mouse model of liver injury, the β -catenin pathway was shown to be involved in leptin-induced liver fibrosis. The β -catenin pathway contributes to leptin regulation of SREBP-1c expression in HSCs and leptin-induced liver fibrosis in mice, which had potential implications for clarifying the mechanisms of liver fibrogenesis associated with elevated leptin levels.

No doubt, the molecular mechanisms that cause fibrosis in different types of human liver diseases in order to identify new targets for therapy are a must. Treatment of schistosomiasis and malnutrition are very important

factors in Egyptians to lead a balanced life and raise the immunity against viral infections. This is true with Hepatitis C when compared with the associated conditions and their complications (Mangoud *et al.*, 2004).

Conclusion

Pentoxifylline (PTX) is a promising antifibrotic drug, acting by reducing serum TGF- β 1 and leptin levels in the experimental schistosomal hepatic fibrosis. Also the use of this antifibrotic drug in combination with antischistosomal drug, Mirazid (MZD) was very effective in the control of fibrotic processes in schistosomal hepatic fibrosis.

References

- Al-Mathal, EM, Fouad, MA, 2005:** Human fascioliasis among immigrant workers in Saudi Arabia. J. Egypt. Soc. Parasitol. 35, 3:S1199-207.
- Al-Mathal, EM, Saleh, NM, Morsy, TA, 2010:** Human infection with *Bertiella studeri* (Cestode: Anoplocephalidae) in an Egyptian worker returning back from Saudi Arabia. J. Egypt. Soc. Parasitol. 40, 1:89-92.
- Auffray, B, 2007:** Protection against singlet oxygen, the main actor of sebum squalene peroxidation during sun exposure, using *Commiphora myrrha* essential oil. Int. J. Cosmet. Sci. 29, 1: 23-9
- Baghdadi, HB, Al-Mathal, EM, 2010:** Anticoccidial effect of *Commiphora molmol* in the domestic rabbit (*Oryctolagus cuniculus domesticus* L.). J. Egypt. Soc. Parasitol. 40, 3:653-68.
- Bataller, R, Brenner, D, 2005:** Liver fibrosis. J. Clin. Invest. 115, 2:209-18.
- Bataller, R, North, KE, Brenner, DA, 2003:** Genetic polymorphisms and the progression of liver fibrosis: a critical appraisal. Hepatol. 37: 493-503.
- Benyon, RC, Iredale, JP, 2000:** Is liver fibrosis reversible? Gut 46:443-6.
- Cao, Q, Mak, KM, Lieber, CS, 2007:** Leptin represses matrix metalloproteinase-1 gene expression in LX2 human hepatic stellate cells. J. Hepatol. 46, 1:124-33.
- Cheng, PC, Lin, CN, Peng, SY, Li, LL, Luo, TY, et al, 2013:** A study of immuno-modulatory genes responses to macrophages of *Schistosoma japonicum* infection during different stages by microarray analysis. Acta Trop. 127, 3:251-60

- Choi, J, Corder, NL, Koduru, B, Wang, Y, 2014:** Oxidative stress and hepatic Nox proteins in chronic hepatitis C and hepatocellular carcinoma. *Free Radic. Biol. Med.* 72:267-84
- Ding, X, Saxena, K, Lin, S, Xu, A, Anania, F, 2006:** The role of leptin and adiponectin: a novel paradigm in adipocytokine regulation of liver fibrosis and stellate cell biology. *Am. J. Pathol.* 166, 6:1655-9
- Don, CR, 2005:** Antifibrotic therapy in chronic liver disease. *Clin. Gastroenterol. Hepatol.* 4:95-107.
- El-Lakkany, N, el-Din, SS, Ebeid, F, 2011:** The use of pentoxifylline as adjuvant therapy with praziquantel downregulates profibrogenic cytokines, collagen deposition and oxidative stress in experimental schistosomiasis *mansoni*. *Exp. Parasitol.* 129, 2:152-7.
- Gabele, E, Brenner, DA, Rippe, RA, 2003:** Liver fibrosis: signals leading to the amplification of the fibrogenic hepatic stellate cell. *Front. Biosci.* 8:D69-77.
- García-Compeán, D, Jáquez-Quintana, JO, Lavallo, FJ, González, JA, Maldonado-Garza, HJ, et al, 2014:** Plasma cytokine levels imbalance in cirrhotic patients with impaired glucose tolerance and diabetes mellitus: A prospective study. *Ann. Hepatol.* 13, 4:403-10.
- Giannitrapani, L, Soresi, M, Bondi, ML, Montalto, G, Cervello, M, 2014:** Nanotechnology applications for the therapy of liver fibrosis. *World J. Gastroenterol.* 20, 23:7242-51
- Giboda, M, Zdarska, Z, 1994:** Alkaline phosphatase as a marker of *Schistosoma mansoni* egg viability. *Folia Parasitol. (Praha)*, 41:55-8.
- Graeser, AC, Giller, K, Wiegand, H, Barella, L, Boesch, C, et al, 2009:** Synergistic chondroprotective effect of alpha-tocopherol, ascorbic acid, and selenium as well as glucosamine and chondroitin on oxidant induced cell death and inhibition of matrix metalloproteinase-3--studies in cultured chondrocytes. *Molecules* 15, 1:27-39
- Grzela, T, Lazarczyk, M, Niderla, J, Golab, J, Lazarczyk, MA, et al, 2003:** Pentoxifylline promotes development of murine colon adenocarcinoma-derived metastatic tumors in liver. *Oncol. Rep.* 10, 6:1805-9.
- Han, DC, Isono, M, Chen, S, Hong, SW, Wolf, G, Ziyadeh, FN, 2001:** Leptin stimulates type I collagen production in db/db mesangial cells: glucose uptake and TGF- β type II receptor expression. *Kidney Int.* 59:1315-23
- Ikejima, K, Honda, H, Yoshikawa, M, Sato, M, 2001:** Leptin augments inflammatory and profibrogenic responses in the murine liver induced by hepatotoxic chemicals. *Hepatol.* 34: 288-97.
- Ikejima, K, Okumura, K, Lang, T, Honda, H, Sato, N, 2005:** The role of leptin in progression of non-alcoholic fatty liver disease. *Hepatol. Res.* 33, 2:151-4
- Jacobs, W, Bogers, J, Deelder, A, Wery, M, Van Marck, E, 1997:** Adult worms positively modulate soluble egg antigen induced inflammatory hepatic granuloma formation in vivo: Stereological analysis and immunophenotyping of extracellular matrix proteins, adhesion molecules and chemokines. *Am. J. Pathol.* 150:2033-45.
- Kamada, Y, 2003:** Enhanced carbon tetrachloride-induced liver fibrosis in mice lacking adiponectin. *Gastroenterol.* 125:1796-807.
- Leclercq, I, Farrell, G, Schriemer, P, Robertson, G, 2000:** Leptin is required for development of hepatic fibrosis. *Hepatol.* 32:302-9.
- Li, X, Shen, J, Zhong, Z, Peng, J, Wen, H, et al, 2010:** Paeoniflorin ameliorates schistosomiasis liver fibrosis through regulating IL-13 and its signalling molecules in mice. *Parasitol.* 137, 8:1213-25.
- Mangoud, AM, Eissa, MH, Sabee, EI, Ibrahim, IA, Ismail, A, Morsy, T.A, et al, 2004:** New concept in histopathological grading and staging of chronic hepatitis C infection at Sharkia Governorate, Egypt. *J. Egypt. Soc. Parasitol.* 34, 1:S385-400.
- Marshall, S, 2004:** Myrrh: magi, medicine and mortality. *Pharmaceut. J.* 273:919-20.
- Mati, VL, Freitas, RM, Melo, AL, 2010:** Effects of pentoxifylline during *Schistosoma mansoni* infection in Swiss mice: an analysis of worm burden, fecundity and liver histopathology. *J. Helminthol.* 84, 4:348-54.
- Miao, XY, Hu, JX, Dai, WD, Zhong, DW, Huang, SF, et al, 2009:** Anatomic mesohepatectomy with extrahepatic control of hepatic veins. *Hepatogastroenterol.* 56, 96:1730-4.
- Miao, ZF, Zhao, TT, Wang, ZN, Miao, F, Xu, YY, et al, 2014:** Transforming growth factor- β 1 signaling blockade attenuates gastric cancer cell-induced peritoneal mesothelial cell fibrosis and alleviates peritoneal dissemination both in vitro and in vivo. *Tumor Biol.* 35, 4: 3575-83.

- Nomicos, EY, 2007:** Myrrh: medical marvel or myth of the Magi? *Holist. Nurs. Pract.* 21, 6: 308-23
- Omar, A, Elmesallamy, Gel-S, Eassa, S, 2005:** Comparative study of the hepatotoxic, genotoxic and carcinogenic effects of praziquantel distocide & the natural myrrh extract Mirazid on adult male albino rats. *J. Egypt. Soc. Parasitol.* 35, 1:313-29.
- Peters, PA, Warren KS, 1969:** A rapid method of infecting mice and other laboratory animals with *Schistosoma mansoni* by subcutaneous injection. *J. Parasitol.* 55-8.
- Qiu, B, Wei, F, Sun, X, Wang, X, Duan, B, et al, 2014:** Measurement of hydroxyproline in collagen with three different methods. *Mol. Med. Rep.* 10, 2:1157-63.
- Ramadori, G, Saile, B, 2004:** Portal tract fibrogenesis in the liver. *Lab. Invest.* 84:153-9.
- Reis, LF, Ventura, TG, Souza, SO, Arana, A, Takiya, CM, 2001:** Quantitative and qualitative interferences of Pentoxifylline on hepatic *Schistosoma mansoni* granulomas: Effects on extracellular matrix and eosinophil population. *Mem. Inst. Oswaldo. Cruz.* 96:107-20.
- Rowland, M, Gallagher, C, Gallagher, CG, Laoide, RO, Canny, G, et al, 2014:** Outcome in patients with cystic fibrosis liver disease. *J. Cyst Fibros* 2014 Jun 7. pii: S1569 1993(14) 00119-2.
- Tarcin, O, Avsar, K, Demirturk, L, Baloglu, H, Gurbuz, A, 2003:** In vivo inefficiency of by tissue collagen content and prolidase activity. *J. Gastroenterol. Hepatol.* 18, 4:437-44.
- Tonkal, AMD, Morsy, TA, 2008:** An update review on *Commiphora molmol* and related species. *J. Egypt. Soc. Parasitol.* 38, 3:763-96.
- Wallis, A, 1967:** Textbook of Pharmacogeny, Churchill Livingstone, London.
- Wyler, DJ, 1992:** Why does liver fibrosis occur in schistosomiasis? *Parasitol. Today*, 8: 277-9.
- Xiaokun, D, Neeraj, K, Saxena, S, Xu, A, Shanthi, S, 2005:** The roles of leptin and adiponectin: A novel paradigm in adipocytokine regulation of liver fibrosis and stellate cell biology. *Amer. J. Pathol.* 166:1655-69.
- Xiong, LI, Zhu, JF, Luo, DD, Cai, SQ, 2003:** Effect of pentoxifylline on the hepatic content of TGF-B1 and collagen in schistosomiasis *japonica* mice with liver fibrosis. *World J Gastroenterol.* 9, 1:152-4
- Yakoot, M, 2010:** A short review of the anthelmintic role of Mirazid. *Arq. Gastroenterol.* 47, 4:393-4.
- Yang, M, Sun, JZ, Sun, YL, You, W, et al, 2012:** Association between leptin gene promoter methylation and type 2 diabetes mellitus. *Zhonghua Yi Xue Yi Chuan Xue Za Zhi.* 29, 4:474-7.
- Zhai, X, Yan, K, Fan, J, Niu, M, Zhou, Q, Zhou, Y, et al, 2013:** The β -catenin pathway contributes to the effects of leptin on SREBP-1c expression in rat hepatic stellate cells and liver fibrosis. *Br. J. Pharmacol.* 169, 1:197-212.

Explanation of figures

- Fig. 1: A liver section of a control non-infected non-treated mouse showing normal liver architecture (H & E, X 200)
- Fig. 2: A liver section of control infected non-treated mouse at 9th week P.I. (GIa) showing cellular bilharzial granulomas with collections of eosinophils, mononuclear cells and macrophages around viable eggs (H&E, X 400)
- Fig. 3: A liver section of control infected non-treated mouse at 17th week P.I. (GIb) showing bilharzial granulomas with increased connective tissues around eggs and reduced cellularity giving whorly appearance (H&E, X 250)
- Fig. 4: A liver section of control infected non-treated mouse at 17th week P.I. (GIb) showing multiple bilharzial granulomas with concentric collagen fibers oriented in various directions (Masson's trichrome, X250)
- Fig. 5: A liver section of a mouse of GIla (infected and treated with MZD) at 9th week P.I showing decrease in granuloma size with dead egg centrally (H&E, X400)
- Fig. 6: A liver section of a mouse of GIlla (infected and treated with PTX) at 9th week P.I showing decrease in granuloma size with healthy egg in centrally (H&E, X400)
- Fig. 7: A liver section of a mouse of GIlb (infected and treated with PZQ) at 17th week P.I showing mild decrease in granuloma size (H&E, X250)
- Fig. 8: A liver section of a mouse of GIllb (infected and treated with PTX) at 17th week P.I showing moderate decrease in granuloma size (H&E, X250)
- Figs. 9,10: A liver section of a mouse of GVlb (infected and treated with MZD & PTX) at 17th week P.I showing marked decrease in granuloma size with increased cellularity (H&E, X250)
- Fig. 11: A liver section of a mouse of GIllb (infected and treated with PTX) at 17th week P.I showing collagen fibers fragmented and scanty (Masson's trichrome, X250)
- Fig. 12: A liver section of a mouse of GVlb (infected and treated with MZD & PTX) at 17th week P.I showing scarring (Masson's trichrome, X250)

