

EVALUATION OF GRAFTLESS SINUS LIFTING THROUGH LATERAL WINDOW APPROACH WITH SIMULTANEOUS IMPLANT PLACEMENT

Shorouk A. Abd-Almonem^{1*} BDS, Mahitab M. Soliman² PhD,
Mohamed M. Shokry³ PhD

ABSTRACT

INTRODUCTION: Maxillary sinus lifting for dental implant placement is a well-known and versatile technique; new techniques have been presented based on the physiology of bone repair inside the maxillary sinus, now blood clot can be considered autogenous osteogenic graft material, into which osteoprogenitor cells can migrate, differentiate, and regenerate bone.

OBJECTIVE: Evaluation of the effectiveness of graftless sinus lifting technique through lateral window with simultaneous placement of dental implant.

PATIENTS AND METHODS: Ten patients were selected to match inclusion and exclusion criteria. They were treated using graftless sinus lifting through lateral window technique with simultaneous implant placement. New bone formation was assessed radiographically by measuring bone height, bone volume, bone density, and implant stability.

RESULTS: In all treated cases bone volume and bone height increased significantly. Radiological and clinical follow-up was conducted throughout 6-months postoperatively. All patients showed successful bone formation beneath the schneiderian membrane.

CONCLUSION: Graftless sinus lifting with immediate implant placement is a predictable, time saving technique. Also, it decreases the overall cost of the procedure and the complications that maybe encountered when using any bone substitutes.

KEYWORDS: Tenting implant, Graftless sinus elevation, Sinus floor augmentation

1 BDS 2014, Faculty of Dentistry, Alexandria University, Egypt.

2Professor of Oral and Maxillofacial Surgery, Oral and Maxillofacial Surgery Department, Alexandria University, Alexandria, Egypt.

3Assistant Professor of Oral and Maxillofacial Surgery, Oral and Maxillofacial Surgery Department, Alexandria University, Alexandria, Egypt.

**Corresponding author:*

E-mail: sheeroww@yahoo.com

INTRODUCTION

For many years, dental implants have been utilized for supporting dental prosthetics, as they could be considered the nearest equivalent in the replacement of natural teeth (1). Posterior maxillary area is usually considered to be a challenging area in the placement of dental implants because of the insufficient vertical bone height resulting from alveolar bone resorption following extraction and continuous maxillary sinus pneumatization (2). Sinus lifting procedures have been performed routinely for providing the desired bone height around inserted dental implants (3). Modifications such as the crestal approach was used to be more conservative and to lower the rate of complications. Even though the crestal approach is less invasive, the amount of bone and access gained is less and it requires at least

6 mm of vertical bone height after the augmentation of the maxillary sinus to achieve the sufficient primary stability for the dental implant, which is usually not possible to achieve using most trans-crestal techniques in cases of severely atrophied alveolar bone, except for ultrasonic surgical based intra-lift approach (4). Therefore, lateral approach is still indicated in cases of advanced alveolar bone atrophy (5).

Tatum was the first to describe maxillary sinus augmentation, then Boyne and James published it as a clinical study (6), after that it has been universally accepted since it was primarily introduced. Even though using bone grafts in augmentation of the maxillary sinus have a high success rate, irrespective of the used technique. However, it has demerits such as the need for another surgical site in autogenous

bone grafts, liability to infection of bone graft, more operative time, increased complications rate, and also increased cost (7).

It has been reported that spontaneous deposition of new bone below the maxillary sinus floor after enucleation of a cyst exhibits a tendency in the Schneiderian membrane potential for bone formation (8). Then, according to multiple studies, insertion of dental implants and rehabilitation were performed successfully with no need for the use of any bone substitute. Those studies reported that new bone was formed after sinus membrane elevation due to the creation of a void with the presence of blood clot which induces bone deposition based on the principles of guided tissue regeneration (9).

Healing process of bone after maxillary sinus lifting passes by the following stages; first is the formation of a stable blood clot which is mainly acting by vascular endothelial growth factor (VEGF). Then, immobilization of the blood clot and vascular ingrowth. Then, formation of the "callus" (i.e. collagen fibers; which are the very base of all organs). Finally the callus is being mineralized by the periosteum and endosteum (10).

The osteogenic property of the maxillary sinus membrane was proved, histologically, the human schneiderian membrane is composed of several layers including an epithelial lining, a highly vascularized lamina propria, and the deepest layer which represents an interface with the underlying bone, Troedhan et. al. (2014) have found after microscopic investigation at $\times 40$ magnification that this layer is a periosteum with its osteogenic content of osteoblast and mesenchymal stem cells, then Berbéri et. al. (2017) supported this conclusion. So that the basal layer of the schneiderian membrane provides the exclusive ability to regenerate bone. Only intact periosteum and endosteum enables mineralization of augmentation sites as well as routine bone-healing and bone-remodelling (4,11,12).

With more studies indicating the successful implants placement below the sinus floor without additional bone grafting procedures, the focus was shifted to develop a technique that was faster and also less invasive. Graftless sinus lifting is applicable to both lateral and crestal approach for sinus elevation with high success rates (13).

Therefore, the aim of this study was to evaluate the effectiveness of graftless sinus lifting through lateral window technique with simultaneous implant placement in terms of new bone formation around the inserted implant.

PATIENTS AND METHODS

1. Study Design

Informed consent

The surgical procedure was clarified to all the participants and prior to being enrolled in the study, each participant gave written consent, and it was also stated that any participant could leave the study at any time with no repercussions.

This study has received ethical approval from the research ethics committee, Faculty of Dentistry, Alexandria University prior to the beginning of the study.

Patient selection and evaluation

This study was conducted as a one-arm clinical trial. Ten patients were chosen from the outpatient clinic of the Oral and Maxillofacial Surgery Department, Faculty of Dentistry, Alexandria University who required placement of dental implants in the posterior maxilla (Kennedy Classification: Class 1 or Class 2) with maxillary sinus pneumatization and residual alveolar ridge bone height was 3 to 5 mm.

The inclusion criteria for the current study were: Patient's age ranged between 38-50 years irrespective of the gender, teeth extractions were conducted at least four months before the surgical procedure at the site of implants placement. Also, residual bone height from the crest of the alveolar ridge to the maxillary sinus floor ranging between 3 to 5 mm (14). While the exclusion criteria were: presence of pathologies within the maxillary sinuses, such as sinusitis or long-term nasal obstruction (15), and any condition contraindicating implant placement such as uncontrolled diabetes, heavy smokers, acute intraoral infections, untreated periodontal disease, poor oral hygiene, history of head and neck radiotherapy as well as pregnancy (16).

I. Pre-surgical phase

History was taken to all the patients including name, age, sex, occupation, residence, chief complaint, systemic diseases, drugs and previous operations, then preoperative dental impressions have been taken, and mounting of the study models was done to evaluate the relation between maxillary and mandibular arches, preoperative radiographic evaluation for the patients involved panoramic x-ray and cone beam computerized tomography (CBCT), for evaluation of the residual alveolar ridge height and width, maxillary sinus anatomy, as well as for treatment planning (17).

II. Surgical phase

All the surgeries have been performed using local anesthesia (Articaine hydrochloride 40 mg/mk with adrenaline 1:100,000, Artinibsa, Spain). Before the surgery, the patients were

given instructions to wash their mouths with 0.125 percent chlorhexidine antiseptic mouthwash for two minutes. (Hexitol: Chlorhexidine 125mg/100ml, concentration 0.125%: Arabic drug company, ADCO).

A crestal incision was made horizontally and slight palatal to the alveolar ridge crest followed by two vertical relieving incisions at 45 degrees over the mesial and distal ends of the horizontal incision. A full-thickness mucoperiosteal flap has been raised using a mucoperiosteal flap elevator enabling the apical osteotomy (18). (Figure 1A)

The borders of the bony window at the lateral wall of the maxillary sinus have been demarcated in a rectangular fashion 5 to 6 mm apical to the planned implant location, with dimensions of 3 mm horizontally and 2 mm vertically, using standardized spherical Piezoelectric inserts (SL1, SL2) and sterile saline irrigation. (ACTEON® Group, France) (Figure 1B). Detachment of the sinus membrane from the peripheries of the bony window was accomplished by the use of a standardized spherical Piezoelectric insert (SL3) with sterile saline irrigation and the dome-shaped sinus membrane elevator (XSE1L) (Dentium Co., Ltd, South Korea). Sinus membrane elevators (XSE2L), (XSE3L), and (XSE4L) have been used delicately for the elevation of the schneiderian membrane from the sinus floor and anterior wall to make enough space for the collagen membrane (T-Gen, Alpha-Bio Tec Ltd., Korea) to be placed. The sinus membrane was also elevated from the medial wall so it could provide further blood supply from this bone. The absence of membrane perforations was detected by the Valsalva maneuver or direct vision of the schneiderian membrane, thus the up and down motion of the schneiderian membrane was observed when the patients drew a breath (19). (Figure 1C)

The collagen membrane size was adjusted to fit the lateral bone window size, then two incomplete cuts were made in the collagen membrane and it was folded and fitted as its upper part was fitted horizontally beneath a part of the schneiderian membrane of the floor of the maxillary sinus, and its lower side was fitted vertically to cover the osteotomy window, and the buccal side of the implant, so the anterior, posterior, medial, and lateral sides and part of the inferior side of the schneiderian membrane were left uncovered. The collagen membrane was used in this step for management of any invisible minute perforations could be performed during the dissection and the elevation of the schneiderian membrane, or by means of the implant itself, to cover the osteotomy window, and also to

tent the schneiderian membrane, so that the membrane wouldn't collapse and impinge between the inserted implants. (Figure 1D)

The implants (Dentium Co., Ltd, South Korea) were drilled following manufacturer instructions in their positions guided by the prefabricated surgical stent, then the implants have been inserted at torque 30~45N°cm. Blood from surrounding bleeding was allowed to fill the space between the implants and the schneiderian membrane. (Figure 1E)

Implants stability were measured using implant stability meter (OsstellISQ®), SmartPeg was screwed over the installed implants, and the transducer was kept parallel to the occlusal surfaces of the teeth and 0.5 to 1 mm apical to the end of the smart peg. Repeated measurements were taken in mesiodistal, labiolingual directions and the value most frequently observed was recorded (20).

After that, the flap was sutured with watertight sutures using Vicryl 4/0 suture material (Ethicon J&J Medical Supply, New Jersey, United States).

III. Postsurgical phase

Patients were given necessary postoperative and oral hygiene instructions such as: Avoid opening the mouth when sneezing, avoid suction by drinking straws, avoid nose blowing and smoking, soft diet for the first 2 days and avoid chewing on the surgical site, also patients have been informed to apply ice packs opposite to the surgical site for 10 minutes each hour during the first 24 hours.

Patients were advised to take the following prescribed medications including: Amoxicillin 875 mg + Clavulanic acid 125 mg (Augmentin 1g tablets: GlaxoSmithKline (GSK), UK) every 12 hours for 5 days. Xylometazoline hydrochloride 0.1% (Otrivine nasal spray: GlaxoSmithKline (GSK), UK) every 6 hours for 7 days. Chymotrypsin + Trypsin 300 E.A.U (Alphintern: Chymotrypsin 300 E.A.U. (14 micro Katal) + Trypsin 300 E.A.U. (5 micro Katal): Amoun Pharmaceutical Co. S.A.E) every 8 hours for 5 days. Diclofenac potassium 50 mg (Cataflam: Diclofenac Potassium 50 mg: Novartis, Switzerland) every 8 hours for 5 days. Chlorhexidine antiseptic mouth wash 3 times daily for 2 weeks.

IV. Follow up phase

Patients have been followed up for 6 months, both clinically and radiographically. Implant stability was measured by implant stability meter (OsstellISQ®) immediately following implant placement and after 6 months postoperatively.

Cone beam CT (CBCT) was performed immediately postoperative and 6 months postoperative for evaluation of the accuracy of implant position, vertical bone height gained, bone volume, and density.

The On Diamond 3D App-DBM software system (Cybernet, Korea) was used to perform the CBCT measurements, as the bone height was assessed in mm, bone density in Hounsfield Units (HU), and bone volume was computed in cm³.

The patients received definitive porcelain fused to metal restorations. after 6 months postoperatively.

Statistical analysis

Normality was checked for quantitative variables using descriptive statistics, plots, and normality tests. Means and standard deviations (SD) were calculated for normally distributed variables (age, ISQ, bone volume, and bone height), in addition to median and interquartile range (IQR) for not normally distributed quantitative variables (Bone density), while frequencies and percentages were calculated for qualitative variable (gender, occurrence of complications).

Change across time in quantitative normally distributed variables were compared using Paired test while Wilcoxon Sign Rank Test was used to assess bone density.

Percent change for all variables was calculated according to the following formula; [(values after -values before) / values before) x 100]

Data were analyzed using SPSS for Windows version 25.0. Significance level was set at p value 0.05.

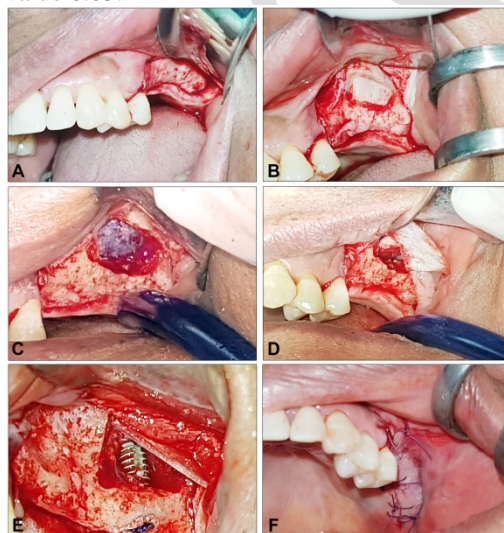


Figure 1: A) Reflection of full thickness mucoperiosteal flap opposing the maxillary sinus lateral wall, B) Outline of the bony window formed by Piezoelectric device, C) Elevation of the schneiderian membrane, D) Folding and insertion of the collagen

membrane with its horizontal part beneath the schneiderian membrane E) Insertion of the dental implant tented by the collagen membrane, F) Suturing of the flap using vicryl 4/0 suturing material.

RESULTS

In this study, ten patients were presented indicated for sinus lifting and implants placement. The surgeries were performed at Oral and Maxillofacial Surgery Department, Faculty of Dentistry, Alexandria University. Four male and six female patients have been selected with ages ranging between 38-50 years and the mean age was 42.86 years.

A total of 17 implants have been inserted; Seven implants were inserted with 3.6 mm diameter and 10 mm length, three implants with 4 mm diameter and 8 mm length, four implants with 4 mm diameter and 10 mm length, and three implants with 4 mm diameter and 12 mm length.

The patients have been followed up on for 6 months postoperative, both clinically and radiographically, none of the participants encountered any postoperative complications.

I. Clinical evaluation

Implant stability

The implant stability metre (OsstellISQ®) device was used to check the stability of the implants immediately postoperative and after 6 months. The mean ISQ value recorded postoperatively was 63.71 ± 2.75 and it was increased significantly to 74.29 ± 3.30 (P value <0.0001) and the mean percentage of increase was 16.66% (SD= 3.3%). (Table 1)

II. Radiographic evaluation

1. Vertical bone height gained

The mean vertical bone height measured preoperatively was 3.88 ± 0.94 mm and it was increased significantly after 6 months postoperative to 10.03 ± 0.73 mm (P value <0.0001). The mean percentage of increase was 174.80% (SD=79.07%). (Table 2, Figure 2A,B)

2. Bone density

The mean bone density recorded postoperatively was 410.00 ± 55.07 Hounsfield Units (HU) and after 6 months postoperatively it was increased to 577.00 ± 226.51 HU (P value = 0.018) as the difference between preoperative and postoperative bone density was statistically insignificant. The mean percentage of increase was 40.62% (SD = 52.39%). (Figure 3)

3. Bone volume

The mean bone volume recorded postoperatively was 1.098 ± 0.147 cm³ and after 6 months it was significantly increased to 1.644 ± 0.192 cm³ (P value = 0.002). The

mean percentage of increase was 52.66% (SD=30.44%). (Table 4, Figure 4 A,B)

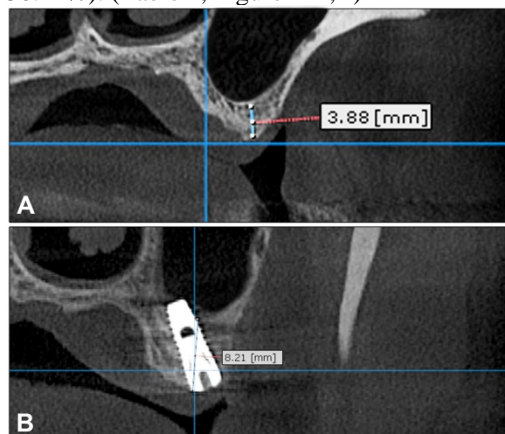


Figure 2: A) CBCT showing preoperative bone height, B) CBCT showing implant in place and bone height 6 months postoperative.

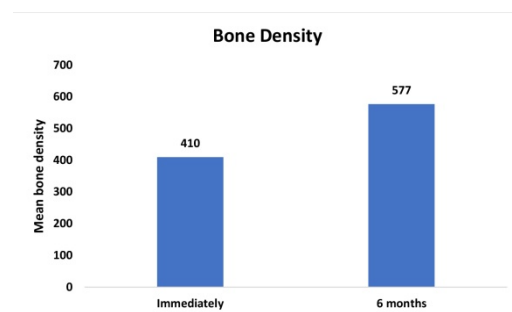


Figure 3: Bar chart graph showing mean bone density immediately and after 6 months postoperatively.




Figure 4: A) CBCT showing preoperative assessment of bone volume, B) CBCT showing bone volume assessment 6 months postoperative.

Table 1: Implant stability (ISQ) immediately and after 6 months postoperatively

	Immediately	After 6 months	% Increase
Mean (SD)	63.71 (2.75)	74.29 (3.30)	16.66 (4.65)
Median (IQR)	64.00 (6)	75.00 (7)	18.33 (8.06)
Min - Max	60 – 67	70 - 78	9.38 – 21.88
Paired test P value	9.918 <0.0001*		

*Statistically significant at p value ≤ 0.05

Table 2: Bone height immediately and after 6 months postoperatively

	Immediately	After 6 months	% Increase
Mean (SD)	3.88 (0.94)	10.03 (0.73)	174.80 (79.07)
Median (IQR)	3.78 (2.00)	10.26 (0.14)	171.42 (159.32)
Min - Max	2.76 – 5.20	8.38 – 10.44	61.15 – 273.91
Paired t test P value	10.679 <0.0001*		

*Statistically significant at p value ≤ 0.05

Table 3: Bone volume immediately and after 6 months postoperatively

	Immediately	After 6 months	% Increase
Mean (SD)	1.098 (0.147)	1.644 (0.192)	52.66 (30.44)
Median (IQR)	1.123 (0.318)	1.628 (0.270)	49.26 (41.83)
Min - Max	0.900 – 1.252	1.332 – 1.930	10.45 – 100.00
Paired t test P value	5.432 0.002*		

*Statistically significant at p value ≤ 0.05

DISCUSSION

Using bone substitutes in augmentation of the maxillary sinus surgeries regardless of the used technique was associated with significant success rates, however, it has many demerits such as the need of a second surgical site for the harvesting of autogenous bone grafts, possibility of infection transmission when allografts are used, poor regeneration capacity in comparison to the natural autogenous bone, increased surgical time and higher cost (21,22).

The significance of blood clot formation has been established by a broad and firm consensus, which acts as an autogenous graft for regeneration of bone during the graftless maxillary sinus lifting, as it has high levels of growth factors, which initiates and promotes bone neoformation (23), moreover clinical reports and animal experiments revealed that the sinus membrane has osteoinductive properties (24).

In this study, some armamentariums were used like Piezoelectric device, which has been used in the lateral window osteotomy. Using Piezoelectric device, a blood-free surgical field was maintained during bone osteotomy due to the air-water cavitation action of the device, so that the vision of the operation site was better, which agrees with Shokry et al. (2018) as they concluded that the Piezoelectric surgery is an effective device that is safer in performing the lateral maxillary sinus lift surgery than the conventional rotary method, but it takes longer operation time (25). Palma et al. (2006) performed a study which histologically described the integration of simultaneously inserted dental implants with different surfaces, and they concluded that the amount of new bone which was formed wasn't different after they have compared between the lifting of the schneiderian membrane with and without using bone grafts, however histological examination revealed that, bone deposition was a continuous process from the beginning at the elevated group without bone grafts, whereas a resorption pattern of the bone particles predominated in bone graft sites, which indicates the importance of the growth factors and the osteoprogenitor cells which are carried by the schneiderian membrane, as those cells and growth factors have been blocked by the bone graft in the grafted sinus group (26). In comparison to Palma et al., (2006) study (26). In the current study, the collagen membrane didn't block the schneiderian membrane. Two incomplete cuts were made in the middle of the membrane so it could be folded as its horizontal part was fitted beneath a small portion of the schneiderian membrane of the floor of the maxillary sinus, and its vertical part covered the osteotomy window and the buccal side of the implant. The anterior, posterior, medial, lateral sides, as well as a large portion of the inferior side of the schneiderian membrane were left uncovered, as the schneiderian membrane contains the osteoprogenitor cells and growth factors which were needed for bone neo-formation (4,11).

Collagen membrane importance in this study was to exclude unwanted tissues and cells, help in the management of minor

perforations of the sinus membrane which could be performed accidentally by the clinician during the dissection or the elevation of the schneiderian membrane, also it protects the membrane from perforation by the implant during its placement, as well as it covers the osteotomy window and the buccal side of the implant. Membrane perforations increase the possible side effects of infection, disruption of the sinus functions, and even may affect implants survival as mentioned by Schwarz et al. (2015). Marin et al., (2019) concluded that covering schneiderian membrane perforations with size up to 10 mm with a collagen membrane during maxillary sinus lifting is found to be effective in preventing the possible postoperative complications (27,28). Moreover the collagen membrane was used to tent the schneiderian membrane, so that the membrane wouldn't collapse and impinge between the inserted implants.

Implant stability was measured immediately following insertion of implants and 6 months postoperatively before loading of the abutments using the OsstellISQ® device. The mean ISQ value recorded postoperatively was increased significantly. Similar results were obtained by Marković et al. (2016), where the mean ISQ values increased significantly 6 months after sinus lifting without placement of bone graft. According to the literature, ISQ numbers greater than 70 designate high implant stability and success of the implant placed (29).

Bone volume was measured preoperative and after 6 months postoperatively before insertion of the abutment, it was observed that the mean bone volume was significantly increased. Similar results were obtained by Berberi et al. (2015) where the mean bone volume measured after 4 months of sinus lifting with the placement of cortical bone allograft was increased significantly (30).

Evidence of bone deposition has been observed around the implants after 6 months postoperative. The mean bone density value recorded statistically insignificant increase (p -value > 0.001). This was against the results of a study conducted by Altintas et al. (2013), where the mean density gained 6 months postoperatively in the graftless sinus lifting group as the results increased significantly (31). The variation between the results could be related to the small sample size in the current study.

Vertical bone height has been assessed preoperatively and after 6 months postoperatively. A statistically significant increase (p -value < 0.001) in vertical bone height gain was observed 6 months postoperative, these

results agree with Arora et al. in 2019 as average vertical bone height increased significantly 6 months postoperatively in the evaluation of sinus floor augmentation with the use of bioactive synthetic grafting material (32).

Many recent publications have reported performing graftless sinus lifting utilizing different techniques, Palma et al. (2006) performed graftless sinus lifting and did not recommend the use of any other material for tenting the schneiderian membrane, and this technique has achieved successful outcomes (26). In our study we used collagen membrane for tenting the schneiderian membrane and to gain other benefits as mentioned before, and also the technique achieved successful outcomes, Menassa et al. (2021) used absorbable collagen sponge for graftless sinus augmentation (33). While Luongo et al. (2020) reported using Porcine bone layer in graftless maxillary sinus floor augmentation (34), therefore a future study is suggested to compare between the different techniques for graftless sinus lifting, with histological evaluation so we can assess the quality of the newly formed bone, thus we can gain the maximum benefits from the mentioned studies.

This study had some limitations include the collection of the sample that fulfill the proposed inclusion and exclusion criteria, many recalls of patients for follow up, difficulties in the motivation of patients to follow postoperative instructions, and also difficulty in measurement of bone volume gained postoperatively.

CONCLUSION

Within the limitations of this study, it can be concluded that graftless sinus lifting through lateral window displayed successful outcomes in regards to safety and effectiveness. It was found that new bone was observed radiographically formed directly on and around the inserted implants without using any bony substitutes. With the aid of the piezoelectric device, lateral window osteotomy became possible with less incidence of sinus membrane tearing. Dispensing the use of bone substitutes means that the morbidity of harvesting donor site for graft collection can now be avoided also less surgical time, which led to decreased postoperative pain, edema, and liability to infection. The lateral window position facilitates sinus membrane visibility and detachment and also decreases intraoperative and postoperative complications.

CONFLICT OF INTERSET

The authors declare that they have no conflict of interest.

FUNDING STATEMENT

This research did not receive any funding.

REFERENCES

1. Pal S. Dental Implants: Their Design and Manufacture. In: Pal S (ed). Design of Artificial Human Joints & Organs. Boston, MA: Springer US; 2014. pp. 75-100.
2. Urban IA, Ravidà A, Saleh MHA, Galli M, Lozada J, Farkasdi S, et al. Long-term crestal bone changes in implants placed in augmented sinuses with minimal or moderate remaining alveolar bone: A 10-year retrospective case-series study. Clin Oral Implants Res. 2021;32:60-74.
3. Al Dajani M. Recent trends in sinus lift surgery and their clinical implications. Clin Implant Dent Relat Res. 2016;18:204-12.
4. Troedhan A, Mahmoud ZT, Wainwright M. Transcrestal hydrodynamic ultrasonic cavitation sinuslift: results of randomized clinical study. Clin Oral Implants Res. 2017;28:15.
5. Zhu L, He L, Wang Q, Chen X, Xu J, Wang H. Modified maxillary sinus floor elevation via a mini-lateral window with simultaneous placement of dental implants: a clinical and radiographical study. Int J Clin Exp Med. 2017;10:9314-21.
6. Fugazzotto PA. The modified trephine/osteotome sinus augmentation technique: technical considerations and discussion of indications. Implant Dent. 2001;10:259-64.
7. Lundgren S, Andersson S, Sennerby L. Spontaneous Bone Formation in the Maxillary Sinus after Removal of a Cyst: Coincidence or Consequence? Clin Implant Dent Relat Res. 2003;5:78-81.
8. Lundgren S, Anderson S, Gualini F, Sennerby L. Bone reformation with sinus membrane elevation: A new surgical technique for maxillary sinus floor augmentation. Clin Implant Dent Relat Res. 2004;6:165-73.
9. Srouji S, Kizhner T, Ben David D, Riminucci M, Bianco P, Livne E. The Schneiderian Membrane Contains Osteoprogenitor Cells: In Vivo and In Vitro Study. Calcif Tissue Int. 2009;84:138-45.
10. Mammoto A, Connor KM, Mammoto T, Yung CW, Huh D, Aderman CM, et al. A mechanosensitive transcriptional mechanism that controls angiogenesis. Nature. 2009; 457:1103-8.

11. Angelo T, Marcel W, Andreas K, Izabela S. Biomechanical Stability of Dental Implants in Augmented Maxillary Sites: Results of a Randomized Clinical Study with Four Different Biomaterials and PRF and a Biological View on Guided Bone Regeneration. *Biomed Res Int*. 2015;2015:850340.
12. Berbéri A, Al-Nemer F, Hamade E, Noujeim Z, Badran B, Zibara K. Mesenchymal stem cells with osteogenic potential in human maxillary sinus membrane: an in vitro study. *Clin Oral Investig*. 2017;21:1599-609.
13. Moon JW, Sohn DS, Heo JU, Shin HI, Jung JK. New bone formation in the maxillary sinus using peripheral venous blood alone. *J Oral Maxillofac Surg*. 2011;69:2357-67.
14. Rawat A, Thukral H, Jose A. Indirect sinus floor elevation technique with simultaneous implant placement without using bone grafts. *Ann Maxillofac Surg*. 2019;9:96-102.
15. Pignataro L, Mantovani M, Torretta S, Felisati G, Sambataro G. ENT assessment in the integrated management of candidate for (maxillary) sinus lift. *Acta Otorhinolaryngol Ital*. 2008;28:110-9.
16. Gómez-de Diego R, Mang-de la Rosa M del R, Romero-Pérez MJ, Cutando-Soriano A, López-Valverde-Centeno A. Indications and contraindications of dental implants in medically compromised patients: Update. *Med Oral Patol Oral Cir Bucal*. 2014;19:483-9.
17. Tadinada A, Fung K, Thacker S, Mahdian M, Jadhav A, Schincaglia GP. Radiographic evaluation of the maxillary sinus prior to dental implant therapy: A comparison between two-dimensional and three-dimensional radiographic imaging. *Imaging Sci Dent*. 2015;45:169-74.
18. Scarano A, Lorusso F, Arcangelo M, D'Arcangelo C, Celletti R, De Oliveira PS. Lateral sinus floor elevation performed with trapezoidal and modified triangular flap designs: A randomized pilot study of post-operative pain using thermal infrared imaging. *Int J Environ Res Public Health*. 2018;15:1277.
19. Kim JM, Sohn DS, Heo JU, Park JS, Jung HS, Moon JW, et al. Minimally invasive sinus augmentation using ultrasonic piezoelectric vibration and hydraulic pressure: A multicenter retrospective study. *Implant Dent*. 2012;21:536-42.
20. Kastala VH, Rao MVR. Comparative evaluation of implant stability in two different implant systems at baseline and 3–4 months intervals using RFA device (OSSTELL ISQ). *Indian J Dent Res*. 2019;30:678-86.
21. Kumar VS, Swetha MS, Reddy KS. A consolidated review on sinus lift procedures. *Saudi J Oral Dent Res*. 2019;4:176-87.
22. Soltan M, Smiler DG. Antral Membrane Balloon Elevation. *J Oral Implantol*. 2005;31:85-90.
23. Mijiritsky E, Barbu H, Lorean A, Shohat I, Danza M, Levin L. Use of implant-derived minimally invasive sinus floor elevation: A multicenter clinical observational study with 12- to 65-month follow-up. *J Oral Implantol*. 2016;42:343-8.
24. Srouji S, Kizhner T, Ben David D, Riminucci M, Bianco P, Livne E. The Schneiderian Membrane Contains Osteoprogenitor Cells: In Vivo and In Vitro Study. *Calcif Tissue Int*. 2009;84:138-45.
25. Shokry M, Elsharkawy RT, Arakji H. Evaluation of efficiency and safety of piezosurgery versus conventional rotary instruments in lateral maxillary sinus floor elevation: a prospective randomized controlled clinical trial. *Egypt Dent J*. 2018;64:3209-17.
26. Palma VC, Magro-Filho O, de Oliveria JA, Lundgren S, Salata LA, Sennerby L. Bone reformation and implant integration following maxillary sinus membrane elevation: an experimental study in primates. *Clin Implant Dent Relat Res*. 2006;8:11-24.
27. Schwarz L, Schiebel V, Hof M, Ulm C, Watzek G, Pommer B. Risk Factors of Membrane Perforation and Postoperative Complications in Sinus Floor Elevation Surgery: Review of 407 Augmentation Procedures. *J Oral Maxillofac Surg*. 2015;73:1275-82.
28. Marin S, Kirnbauer B, Rugani P, Payer M, Jakse N. Potential risk factors for maxillary sinus membrane perforation and treatment outcome analysis. *Clin Implant Dent Relat Res*. 2019;21:66-72.
29. Marković A, Mišić T, Calvo-Guirado JL, Delgado-Ruiz RA, Janjić B, Abboud M. Two-center prospective, randomized, clinical, and radiographic study comparing osteotome sinus floor elevation with or without bone graft and simultaneous implant placement. *Clin Implant Dent Relat Res*. 2016;18:873-82.
30. Berberi A, Bouserhal L, Nader N, Assaf RB, Nassif NB, Bouserhal J, et al.

- Evaluation of Three-Dimensional Volumetric Changes After Sinus Floor Augmentation with Mineralized Cortical Bone Allograft. *J Maxillofac Oral Surg.* 2015;14:624-9.
31. Altintas NY, Senel FC, Kayıpmaz S, Taskesen F, Pampu AA. Comparative radiologic analyses of newly formed bone after maxillary sinus augmentation with and without bone grafting. *J Oral Maxillofac Surg.* 2013;71:1520-30.
32. Arora A, Khadtale D, Agarwal B, Yadav R, Bhutia O, Roychoudhury A. Radiographical and histological evaluation of bioactive synthetic bone graft putty in sinus floor augmentation: A pre- and post-intervention study. *Natl J Maxillofac Surg.* 2019;10:13-9.
33. Menassa G, Kassir AR, Landi L, Naaman NBA, Chakar C. Implant placement with sinus floor elevation via the lateral approach using only absorbable collagen sponge: 12-month post-loading radiographical outcomes and implant survival rate. *Oral Maxillofac Surg.* 2021;25:231-6.
34. Luongo R, Sgaramella N, Traini T, Bugea C. Graftless Maxillary Sinus Floor Augmentation with Simultaneous Porcine Bone Layer Insertion: A 1- to 5-Year Follow-up Study. *Int J Oral Maxillofac Implants.* 2020;35:808-15.