

Histopathological Changes of Inferior Turbinate in Patients with Allergic and Non allergic Rhinitis

Ahmed Serag^{1*} MSc., Ahmed Sobhi Abdelaal² MD., Mohamed Abdelmonem² MD. and Yasien Abd El Ghafour³ MD.

* Corresponding Author:

Ahmed Serag
as308664@gmail.com

Received for publication October 21, 2021; Accepted April 06, 2022;
Published online April 06, 2022.

Copyright The Authors published by Al-Azhar University, Faculty of Medicine, Cairo, Egypt. Users have the right to read, download, copy, distribute, print, search, or link to the full texts of articles under the following conditions: Creative Commons Attribution-Share Alike 4.0 International Public License (CC BY-SA 4.0).

doi: 10.21608/aimj.2022.101701.1619

¹Department of Otorhinolaryngology , Faculty of Medicine, AL Mahla Hospital, Egypt.

²Department of Otorhinolaryngology , Faculty of Medicine, Al-Azhar University, Cairo, Egypt.

³Department of Pathology, Faculty of Medicine, Al-Azhar University, Cairo, Egypt.

ABSTRACT

Background: Inferior turbinate hypertrophy is one of the most common causes of nasal obstruction. Understanding the histopathological changes of the inferior turbinate mucosa in allergic and non-allergic rhinitis could leads to better diagnosis and accurate treatment..

Aim of the work: to assess the histopathological changes in the inferior turbinate in allergic rhinitis and non -allergic rhinitis and control subjects.

Patients and Methods: This prospective study includes 74 patients divided into 28 patients with allergic rhinitis, 24 patients with non - allergic rhinitis, 22 normal control group. The inferior turbinate (IT) biopsy was taken for assessment the thickness of medial, lateral mucosal and bony layer of IT and the predominant inflammatory cells.

Result: the mean thickness of medial mucosal layer of inferior turbinate was larger in allergic rhinitis(AR) group 6.03 mm , and non-allergic rhinitis(NAR) group 5.3 than in control group 4.47mm. The main thickness of the lateral mucosal layer of inferior turbinate in AR group is 3.1mm , in NAR group was 2.5mm and 2.16 in control group .The main thickness of the bony layer of IT was 3.57mm in AR group is 3.56mm in NAR group was and 3.58mm in control group .The predominant inflammatory cells in AR group were eosinophiles and mast cells ,where in NAR group, were plasma cells and lymphocytes.

Conclusion: Significant increase the thickness of the medial and lateral mucosal layers of inferior turbinate with AR and NAR .Infiltration of eosinophiles and mast cells in AR and non - specific inflammatory cells in NAR.

Keywords: Allergic rhinitis, Inferior turbinate Hypertrophy, Non - allergic rhinitis, Histopathology.

Disclosure: The authors have no financial interest to declare in relation to the content of this article. The Article Processing Charge was paid for by the authors.

Authorship: All authors have a substantial contribution to the article.

INTRODUCTION

Allergic rhinitis (AR) is a type 1 hypersensitivity reaction of the nasal mucosa that has a negative impact on the patient's quality of life. Rhinorrhea, nasal blockage, sneezing, nasal itching, and postnasal drip are the main symptoms of AR, which is caused by inflammation of the nasal mucosa¹.

Non allergic rhinitis (NAR) is a type of rhinitis that affects a wide range of individuals, including those with vasomotor rhinitis and rhinitis medicamentosa, but does not show clinical evidence of infection or systemic indicators of allergic inflammation, and allergy tests are negative².

Vasomotor rhinitis is defined by the presence of chronic symptoms of rhinitis (sneezing rhinorrhea nasal congestion and post nasal drainage) with absence of specific immunological, infectious, pharmacological ,hormonal or atrophic causes and not associated with nasal eosinophilia and the tests of allergy is negative³.

Rhinitis medicamentosa is a non-allergic rhinitis caused by excessive use of a topical nasal decongestant. Nasal blockage, nasal discomfort, and mucosal hypertrophy were all symptoms of rhinitis medicamentosa⁴. The use of a topical nasal decongestant (oxymetazone) causes nasal soft tissue hypertrophy and vasoconstriction⁵.

The mucosa of the inferior turbinate is vital for maintaining good nasal defence, humidification, warming, and filtration of the inspired air, and the inferior turbinates play an important part in normal respiratory processes⁶.

The buildup of inflammatory cells in the nasal mucous membranes, as seen in biopsy, is linked to mucosal inflammation in rhinitis. Mast cells and eosinophiles are recruited specifically in the pathophysiology of allergic rhinitis because when mast cells are activated, they degranulate and produce inflammatory mediators.⁷

This research is carried to detect the histopathological changes of inferior turbinate associated with allergic and non allergic rhinitis and normal control group to clarify the main prominent inflammatory cell, the main thickness of the medial and lateral mucosal and bony thickness of the inferior turbinate in each group.

PATIENTS AND METHODS

This prospective cohort study will be conducted on 74 patients from January 2021 to October 2021; Patients will be selected from otorhinolaryngology (ORL) outpatient clinics of Al-Azhar University Hospitals. All patients were informed about the benefits and risks and complications of the procedures. Written informed consent was taken from all participants after explanation of the study. Approval of the ethical committee for the study at faculty of medicine Al-Azhar University. The patients aged from 18 -58 years. The patients will be subjected to the following, detailed history with clinical and ENT examination (endoscopic examination of the nose with 0 degree endoscope).investigated with CBC and skin prick test. The test is considered positive if the mean diameter is more than 3 mm with erythema. Positive skin prick test and eosinophilia is diagnostic in patients with allergic rhinitis.

The patients were subdivided into 3 groups:

Group A: 28 patients with allergic rhinitis with manifestation of nasal allergy and positive skin prick test.

Group B: 24 patient with non-allergic rhinitis with nasal manifestation and negative skin prick test and patients past history with topical nasal decongestants.

Group C: 22 normal control group (nasal mucosa appearing normal without nasal or debilitating diseases).

Inclusion Criteria: Patients with a history of allergic rhinitis, vasomotor rhinitis, rhinitis medicamentosa and normal control group, with age: between 18-40 years old, no systemic disease affecting the nasal mucosa of the inferior turbinate

Exclusion Criteria: Patients with a history of upper and lower airway infections. Patients with bleeding tendency, pregnant patients and patients with systemic disease as (DM,HTN), patients with deviated nasal septum associated with contralateral compensatory hypertrophied inferior turbinate.

The samples were taken from inferior turbinate (mucosa ,submucosa and the underling bone) the patients underwent partial turbinectomy for hypertrophied inferior turbinate who have allergic and non-allergic rhinitis with hypertrophied inferior turbinate with persistent nasal obstruction with failure of medical treatment for 3 months and confirmed by CT scan. The biopsy was taken from control group who underwent rhinoplasty or underlying trauma that has no previous nasal or systemic diseases affecting the nose. The turbinates were processed in the department of pathology in a regular manner, and slides were made, taking care to

include all three layers of the turbinate. The biopsy was kept in 10% buffered formaldehyde, the biopsy is then dehydrated with increased concentration of alcohol and embedded in paraffin blocks. The representative sections are stained with hematoxylin-eosin. The dimensions of the inferior turbinates were measured using a calibrated eyepiece mounted to a microscope at magnification of 40. The thickness of each layer (medial mucosa, bone, and lateral mucosa) was also included in the latter. The relative proportions of the different inferior turbinate soft tissue constituents were measured using standard stereological and morphometric methods. The biopsy is handling carefully to ensure the integrity during the retrieval and preparation.

RESULTS

The mean age in allergic rhinitis was 33.6+10.6 with non-allergic rhinitis was 24.9+10.5 and in Control was 33.05+8.9.as shown in table (1)

There were 16 male (57.1%) and 12 female (42.9%) in allergic rhinitis 13 male (54.2%) and 11 female (45.8%) in non- allergic rhinitis and 13 male (59.1%) and 9 female (40.9) in normal control group. There was no significant difference between the 3 groups according to age and sex.

		Allergic rhinitis		Non allergic rhinitis		Control		P value
		Mean	SD	Mean	SD	Mean	SD	
	age	33.68	10.60	34.92	10.54	33.05	8.97	0.814
sex	female	12	42.9%	11	45.8%	9	40.9%	0.944
	male	16	57.1	13	54.2%	13	59.1%	

Table 1: Comparison between allergic rhinitis, non-allergic rhinitis and control regarding to age and sex.

As regarding to the main complaint and clinical presentation; nasal obstruction was reported in 28 patients with allergic rhinitis and 24 patients with non allergic rhinitis;nasal discharge was reported in 15 patients 53.5% and 16 patients 66.6% with non allergic rhinitis, sneezing was reported in 12 patients 42.8% and 17 patients with non allergic rhinitis 70.8% and epistaxis was reported in 3 patients with allergic rhinitis 10.7% and 2 patients with non allergic rhinitis 8.3%. as shown in table 2.

		Allergic rhinitis		Non allergic rhinitis		Control	
		Count	%	Count	%	Count	%
Complaint and Clinical presentation of patients	Nasal obstruction	28	100%	24	100%	0	0.0%
	Nasal discharge	15	53.5	16	66.6%	0	0.0%
	Sneezing	12	42.8	17	70.8%	0	0.0%
	Epistaxis	3	10.7%	2	8.3%	0	0.0%

Table 2: Comparison between allergic rhinitis, non -allergic rhinitis and control regarding to main complaint (clinical presentation).

As regarding the main inflammatory cells between the studied groups, eosinophiles and mast cells were the predominant cells in allergic rhinitis in 28 patients and chronic non-specific inflammatory cells

were reported in non allergic rhinitis as reported in table 3 and figure (1,2,3).

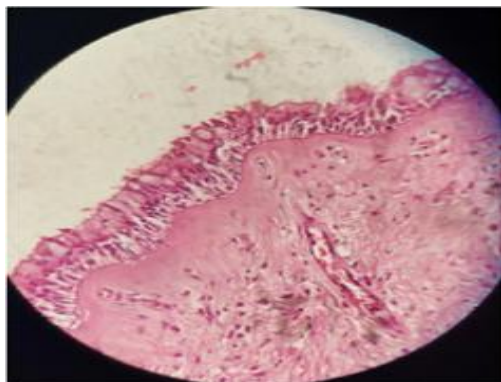


Fig.1: cross section of the inferior turbinate of normal control group revealed, intact epithelium, normal basement membrane and normal stroma-

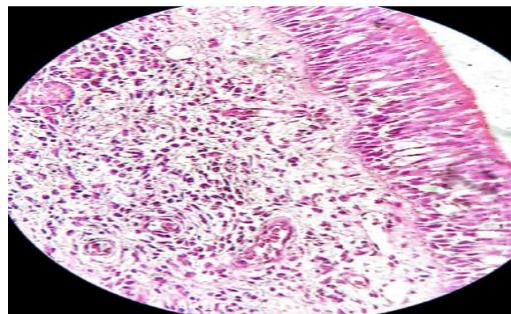


Fig. 2: Cross section of inferior turbinate of allergic rhinitis group revealed infiltration of excess eosinophiles and mast cells and thickened basement membrane.

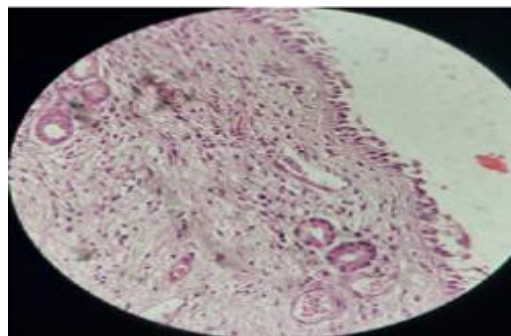


Fig. 3: Cross section of inferior turbinate of non-allergic rhinitis group revealed infiltration of plasma cells, macrophages and lymphocytes with thickened basement membrane.

		Allergic rhinitis		Non allergic rhinitis		Control	
		Count	%	Count	%	Count	%
The main prominent inflammatory cells	Eosinophils and mast cells with increased the number of blood sinusoids	28	100.0 %	0	0.0%	0	0.0%
	Chronic non- specific inflammatory cells with Significant increase the number of blood sinusoids	0	0.0%	24	100.0 %	0	0.0%
	Normal	0	0.0%	0	0.0%	22	100.0 %

Table 3: comparison between allergic rhinitis, non-allergic rhinitis and control regarding to the main prominent inflammatory cells.

The histopathological changes of inferior turbinate with allergic rhinitis were reported in allergic rhinitis as the main thickness of inferior turbinate was 12.7 mm, while in non-allergic rhinitis was 11.52 mm and 10.21 mm in control group. The mean thickness of medial mucosal layer of inferior turbinate was 6.03 mm in allergic rhinitis, 5.38 in non allergic rhinitis

and 4.47 in control group .The main thickness of lateral mucosal layer of inferior turbinate was 3.1 in allergic rhinitis, 2.58 in non-allergic rhinitis and 2.16 in control group. The main thickness of bony layer of inferior turbinate was 3.57mm in allergic rhinitis, 3.56 in non- allergic rhinitis and 3.58 in control group, table 4 and Fig.(4,5,6,7).

	Allergic rhinitis		Non allergic rhinitis		Control		P value
	Mean	SD	Mean	SD	Mean	SD	
Main thickness of inferior turbinate (mm)	12.7	2.03	11.52	1.78	10.21	1.65	< 0.001
Thickness of medial Mucosal layer of inferior turbinate (mm)	6.03	1.27	5.38	1.26	4.47	1.40	< 0.001
Thickness of the lateral mucosal layer of inferior turbinate (mm)	3.10	0.69	2.58	0.73	2.16	0.65	< 0.001
bony layer thickness (mm) of inferior turbinate	3.57	0.33	3.56	0.32	3.58	0.34	0.612

Table 4: Comparison between allergic rhinitis, non-allergic rhinitis and control regarding to main thickness of inferior turbinate, thickness of medial Mucosal layer of inferior turbinate (mm), thickness of the lateral mucosal layer of inferior turbinate, bony layer thickness (mm) of inferior turbinate.

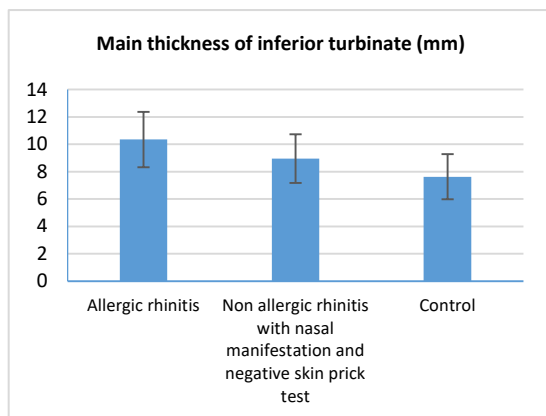


Fig. 4: The main thickness of inferior turbinate (mm) of 3 groups of allergic rhinitis, non-allergic rhinitis and control groups.

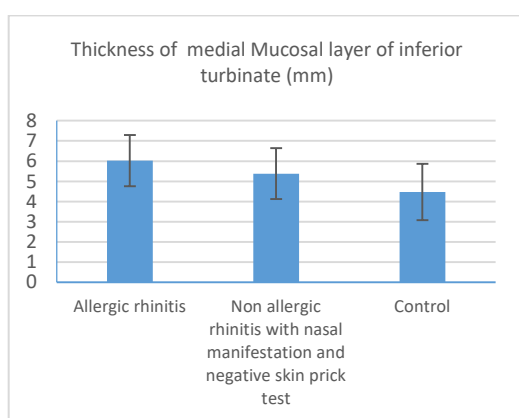


Fig. 5: The main thickness of medial mucosal layer of inferior turbinate (mm) of 3 groups of allergic rhinitis, non-allergic rhinitis and control groups.

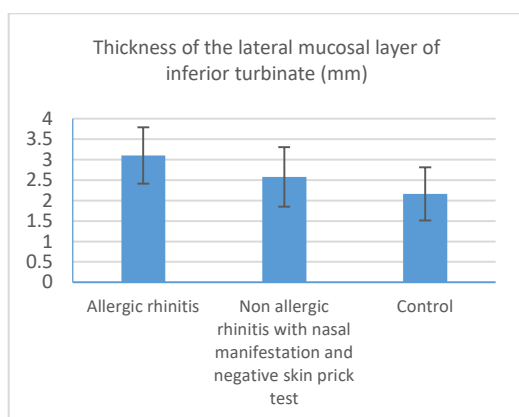


Fig. 6: the main thickness of lateral mucosal layer of inferior turbinate (mm) of 3 groups of allergic rhinitis, non-allergic rhinitis and control groups.

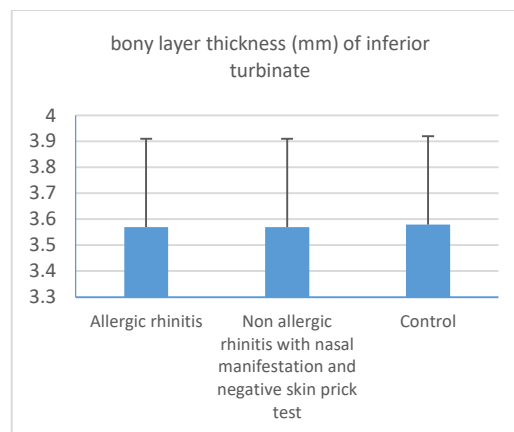


Fig. 7: The regarding the main thickness of bony layer of inferior turbinate (mm) of 3 groups of allergic rhinitis, non-allergic rhinitis and control groups.

DISCUSSION

Nasal obstruction is one of the most common presenting symptoms in otorhinolaryngology. Nearly always the most common cause of nasal obstruction is due to hypertrophied inferior turbinate (HIT). Allergic and non-allergic rhinitis is frequently related with chronic hypertrophic rhinitis. Nasal blockage occurred and the inferior turbinate becomes hypertrophied encroaching on the airway passage. Nasal blockage is found to be present in nearly always all patients of allergic and non-allergic rhinitis while other symptoms like rhinorrhea and sneezing are greatly variable in most studies. Bandos et al 2006; reported that nasal blockage was 100% patients with underlying partial inferior turbinectomy alone and patients underlying partial inferior turbinectomy with septoplasty, while the incidence of nasal discharge was 30% in patients with underlying partial inferior turbinectomy, this lower rate could be related to a positive response to medical treatment⁸.

While the present study are in agreement with the previous results as the nasal obstruction was present in 100% of patients with allergic and non-allergic rhinitis, it differs significantly in rhinorrhea, it represent 53.5% in allergic rhinitis and 66.6% non-allergic rhinitis. This could be due to the present study reported the symptom before treatment and these figures could be changed after treatment. Sneezing is a common symptom of allergic rhinitis. Campo et al 2015, in their study about local nasal allergy (LNA) and NAR reported that patients with NAR had greater nasal obstruction, while LAR patients had more sneezing⁹. Unlike these results; the present study showed that, there was no significant difference in nasal symptoms between AR and NAR. Nasal obstruction was the most prevalent symptoms of AR and NAR (100%) and sneezing was higher in NAR (70.8%) compared to (42.8%) in AR.

AR is an antigen antibody reaction (Type 1 hypersensitivity) characterized by chronic inflammatory cells mostly eosinophils and mast cells.

The interaction of antigen, specific IgE, and the high affinity receptor for IgE on the mast cell surface result in cell degranulation. Release of the vasoactive

mediators leading to vasodilatation and localized oedema. Histopathological study of HIT, revealed that the predominant inflammatory cells in allergic rhinitis patients lymphocyte, plasma cells and eosinophil's whereas non-specific inflammatory cells were predominant in the ITH patients with deviated nasal septum and compensated hypertrophy as stated by Hegazy et al¹⁰.

Furthermore, Amin et al., 2001, obtained biopsy specimens from 27 patients with perennial AR, from 12 patients with perennial NAR, with eosinophil's present in the nasal smear, and from 6 control subjects without rhinitis. They found that the characteristic feature of perennial rhinitis was the accumulation of degranulated mast cells and eosinophil's in the nasal mucosa. Moreover, the number of eosinophil correlated with the loss of epithelial integrity¹¹.

They concluded that, loss of epithelial integrity in the nasal mucosa may be a consequence of the activity of accumulated eosinophils¹¹. The present study found the same result as the main predominant inflammatory cells in AR group were eosinophils and mast cells while non-specific inflammatory cells with lymphocytes and plasma cells in NAR group. Based on this results; the main treatment of AR are topical corticosteroid and antihistamine, due to presence IgE reaction and release of eosinophil's and mast cells, while in NAR, only antihistamines and anticholinergic drugs are accepted.

AR and NAR are the main cause of IT hypertrophy causing significant nasal obstruction. Histopathologic measurement of the main thickness of IT (mm), The thickness of medial mucosal layer of IT (mm), The thickness of lateral mucosal layer of IT (mm) and the bony layer thickness of IT (mm) in various diseases gives an idea about the pathologic changes that occurs in IT mucosa and helps in proper treatment.

El-Demerdash et al.,2020, studied the inferior turbinate thickness in patients with DNS with HIT and patients with allergic rhinitis ,they found the major thickness of the IT was 9.3 ± 2.1 mm in patients with DNS with HIT and 9.8 ± 3.4 mm in individuals with allergic rhinitis, according to the findings. Patients with DNS plus HIT and patients with allergic rhinitis had medial mucosal layer thickness of 4.3 ± 1.5 mm and 5.9 ± 1.9 mm, respectively, compared to lateral mucosal layer thickness of 2.2 ± 0.8 and 3 ± 1.6 in patients with DNS plus HIT and allergic rhinitis, respectively. The thickness of the bony layer was 2.8 ± 1 in patients with DNS and HIT and 0.9 ± 0.6 in patients with allergic rhinitis¹².

The considerable increase of the medial mucosal layer plays a big role in the feeling of nasal obstruction; hence, nasal obstruction treatment primarily necessitates the reduction of this layer, this reported by Hadar et al¹³.

In our study the thickness of medial mucosal layer was significant enlarged in both allergic and non-allergic rhinitis groups, the main thickness of medial mucosal layer was 6.03 mm in allergic rhinitis and 5.3 mm in non- allergic rhinitis patients. The main bony thickness of the inferior turbinate was 3.57 mm in allergic rhinitis .3.56 in non- allergic rhinitis.

Because the changes in the thickness the bony layer of HIT is minimal or no changes, while significant enlargement of the medial mucosal layer was found; so that reduction of the medial mucosal layer is fairly enough to reduce the size of the HIT, widening the airway and improving the nasal obstructions.

Berger et al.,2000, reported that, the anatomical deformity (DNS with compensating ITH) that bony layer contributes significantly to the turbinate hypertrophy , and it should be the surgical target with adequate surgical technique, so submucous diathermy will not be able to relieve this patient's nasal blockage. Mucosal layers, on the other hand, the mucosal layer account for the majority of the turbinate thickness in patients with non-anatomical malformations (allergic and non- allergic rhinitis groups), whereas the bone layer accounts for thickness of the turbinate. For such people, surgical procedures (which attempt to remove the mucosa while leaving the bone component of the turbinate) are appropriate¹⁴. This corresponding to our study the main factor for enlargement of inferior turbinate in allergic and non- allergic rhinitis was the medial mucosal layer. So excision of mucosal layer of hypertrophied inferior turbinate in patients with allergic rhinitis with persistent nasal obstruction with failure of medical treatment is the target of treatment¹⁴.

CONCLUSION

In the present study, that the main prominent inflammatory cells in AR group were eosinophils and mast cells while non-specific inflammatory cells with lymphocytes and plasma cells in NAR so that the main treatment of AR are topical corticosteroid and antihistamine due to presence of IgE reaction and release of eosinophil and mast cells. While in NAR only antihistamine and anticholinergic drugs are accepted.

Significant enlargement of the medial mucosal layer was found, so that reduction of the medial mucosal layer is fairly enough to reduce the size of the HIT widening the airway and improving the nasal obstructions.

REFERENCES

1. Bellanti JA and Wallerstedt DB.: Allergic rhinitis update: Epidemiology and natural history. *Allergy and Asthma Proceedings*; Providence. 2000; 21:367–70.
2. Kowalski ML, Asero R, Bavbek S, et al.: Classification and practical approach to the diagnosis and management of hypersensitivity to Non-steroidal anti-inflammatory drugs. *allergy*. 2013; 68:1219-32.
3. Dana V. Wallace, Mark S, Dykewicz, et al. The diagnosis and management of rhinitis: An updated practice parameter, *Journal of Allergy and Clinical Immunology*, 2008; 122, 2, S1-S84, ISSN 0091-674.

4. Graf P. Rhinitis medicamentosa: A review of causes and treatment. *Treat Respir Med.* 2005;4:21-9.
5. Dykewicz MS, Fineman S, Skoner DP, et al.: Diagnosis and management of rhinitis: complete guidelines of the Joint Task Force on Practice Parameters in Allergy, Asthma and Immunology. American Academy of Allergy, Asthma, and Immunology. *Ann Allergy Asthma Immunol.* 1998;81:478-518
6. Grymer L. The management of enlarged turbinates. In: Gleeson M, editoScott-Brown's otorhinolaryngology, head and neck surgery. London: *Arnold Hodder*; 2008. pp. 1589–92.
7. Bentley AM, Jacobson MR, Cumberworth V et al.: Immunohistology of the nasal mucosa in seasonal allergic rhinitis: increases in activated eosinophils and epithelial mast cells. *J Allergy Clin Immunol* 1992; 89: 877-83
8. Bandos RD, DeMello VR, Ferreira MDS, Rossato M, Lima WTA; Clinical and ultrastructural study after partial inferior turbinectomy. *Rev. Bras Otorrinolaringol* 2006; 72(5): 609-16.
9. Campo P, Rondon C, Gould HJ, et al. Local IgE in non-allergic rhinitis. *Clin Exp Allergy.* 2015; 45(5): 872–81.
10. Hegazy, M.A., Mohamed, A.S., El-Hennawy, A.Y. et al. Histopathological study of hypertrophic inferior turbinate. *Egypt J Otolaryngol* 2014;30, 23–9.
11. Amin K, Juhani Rinne, Tari Haahtela, et al, Inflammatory cell and epithelial characteristics of perennial allergic and nonallergic rhinitis with a symptom history of 1 to 3 years' duration, *Journal of Allergy and Clinical Immunology*, 2001;Volume 107, 2, , 249-57, ISSN 0091-6749.
12. El-Demerdash, A.A., Beheiry, E.A.W., El-Aini, S.M. et al. Morphological and histopathological study of hypertrophied inferior nasal turbinate in Egyptian patients: in clinical perspective. *Egypt J Otolaryngol* 2020; 36, 24.
13. Hadar T, Ophir D, Yaniv E, et al. Inferior turbinate arterial supply: histologic analysis and clinical implications. *J Otolaryngol.* 2005; 34:46-50
14. Berger G, Hammel I, Berger R, et al .Histopathology of inferior turbinate with compensatory hypertrophy in patients with deviated nasal septum. *The Laryngoscope.* 2000; 110:2100-5.