

## Benign Thyroid Nodule Management Using Radiofrequency Ablation

Hossam H. Farahat<sup>\*1</sup>, Ihab M. Salem<sup>1</sup>, Ayman A. M. Nsrallah<sup>1</sup>, Sameh Saber<sup>2</sup>, Mohamed G. Hamed<sup>1</sup>

<sup>1</sup>Internal Medicine & Endocrinology Department, Faculty of Medicine, Zagazig University, Egypt

<sup>2</sup>Interventional Radiology Department, Faculty of Medicine, Zagazig University, Egypt

**\*Corresponding author:** Hossam Hosny Farahat, **Mobile:** (+20) 01216251270, **Email:** thepoortoallah15@gmail.com

### ABSTRACT

**Background:** Thyroid nodule results in morbidity due to local compression or hyperthyroidism. There are several methods available now, including Radiofrequency Ablation (RF), for image-guided ablation of benign thyroid nodule.

**Objective:** This study's goal is to assess how well RF ablation works for managing benign solitary thyroid nodule.

**Patients and methods:** This study involved 40 participants from the internal medicine and endocrinology department's outpatient clinic at Zagazig University Hospitals. All subjects with benign thyroid nodule received RF ablation, and six-month follow-up were carried out. **Results:** Thyroid Imaging Reporting and Data Systems (TIRADS) 2, TIRADS 3, and TIRADS 4 categories were present in 20%, 60%, and 20% of cases, respectively. Regarding the initial assessment before RF; the mean values of TSH, T3 and T4 were  $3.6 \pm 0.87$ ,  $2.76 \pm 0.39$  and  $1.07 \pm 0.23$ , respectively. The mean size of nodules was  $9.51 \pm 2.11$ . Concerning echogenicity, 53.3% of patients were isoechoic. 73.3% of patients had no calcifications; 80% had regular contour. Regarding the final assessment at 6 month after RF; the mean values of TSH, T3 and T4 were  $1.86 \pm 0.43$ ,  $2.8 \pm 0.41$  and  $1.11 \pm 0.21$ , respectively. The mean size of nodules was  $2.3 \pm 0.43$ . About 93.3 % of patients had no calcifications. All managed subjects with RF ablation had 100 % regular contour with no halo. **Conclusion:** RF ablation is regarded as a successful technique for the management of benign thyroid nodules.

**Keywords:** Radiofrequency ablation, Thyroid nodules, Size of nodules.

### INTRODUCTION

Thyroid nodules are frequently discovered incidentally in the general population. The majority of thyroid nodules are benign, and 10% of people who have thyroid nodules when they first present are at risk of cancer <sup>(1)</sup>. When using the ultrasound (US) evaluation, which is the first form of examination utilized for neck imaging, thyroid nodules are frequently found in the general population, primarily as incidental discoveries, with a prevalence of 19–68% <sup>(2)</sup>. Thyroid follicular cells are the source of the majority of thyroid nodules. The most frequent mass lesions are benign follicular nodules, which can be either solitary or part of a multinodular goiter <sup>(3)</sup>.

The majority of patients are symptom-free. Pain, dysphagia (difficulties swallowing), and globus feeling (the sensation of a lump or foreign body in the throat) are all indications of a thyroid nodule or thyroid enlargement (due to acute increase of nodule size, as in case of bleeding into the nodule). Depending on its size and location, a thyroid nodule may or may not cause symptoms. Particularly, a nodule that is larger than 3 cm in size and located close to the trachea is more likely to cause a globus sensation (isthmus nodules more than paraisthmus nodules) <sup>(4)</sup>. Due to many thyroid nodules' modest size, posterior placement inside the gland, or consistency resembling the thyroid gland, physical examinations are commonly normal <sup>(5)</sup>.

There are currently a number of US-guided, minimally invasive treatments (MIT) available for nonsurgical management of thyroid lesions that are symptomatic or expanding <sup>(6)</sup>. When compared to surgery, these methods have a number of benefits. MIT are inexpensive outpatient treatments with almost

minimal chance of long-term consequences, no cervical scarring, and no loss of thyroid function <sup>(1)</sup>.

Since its introduction in 2006, RF ablation of thyroid nodules has been said to be both secure and successful in managing benign thyroid nodules and recurrent thyroid cancer <sup>(7)</sup>. However, the effectiveness of RF ablation can also be diminished by perfusion-mediated tissue cooling or <sup>(1)</sup> the heterogeneous structure of the target tissue in the presence of fibrosis or calcification by changing electrical and heat conduction or <sup>(2)</sup> nearby blood flow <sup>(8)</sup>.

There have been several difficulties noted. An unfavourable occurrence that results from heat injury and/or compression from bleeding of the RLN or the vagus nerve is voice alteration <sup>(9)</sup>. Burns to the skin, discomfort at the surgery site, hypothyroidism, damage to the brachial plexus, and nodule rupture brought on by haemorrhage are other potential side effects. Horner Syndrome, damage to cranial nerve XI (spinal accessory), lidocaine toxicity that manifests as muscular twitching, seizures, and rarely confusion are examples of potential rare RF Ablation side effects <sup>(10)</sup>.

Therefore, the purpose of this study is to evaluate the effectiveness of RF ablation to manage benign solitary thyroid nodule.

### PATIENTS AND METHODS

This study involved 40 participants from the outpatient clinic of the internal medicine and endocrinology department at Zagazig University Hospitals. All participants with a benign thyroid nodule underwent RF ablation of the thyroid nodule and followed-up for 6 months.

### Inclusion and exclusion criteria:

The subjects who have benign thyroid nodule-related symptoms with mean age of 37.8 years. On US-guided biopsies, a benign thyroid nodule was confirmed by cytology. Patients who never had thyroid surgery or other treatment. While, patients with malignant thyroid nodules, neck radiation therapy, laryngeal nerve palsy and any previous thyroid surgery or other treatment were excluded from this study.

### Methods:

*All subjects with benign thyroid nodule were submitted for:*

1. Full medical history taking.
2. Thorough thyroid gland clinical examination.
3. Thyroid profile (fT3, fT4 and TSH) by ELISA.
4. Coagulation Profile (PT, PTT, INR).
5. Neck ultrasonography including sonographic features of thyroid nodule.
6. Fine needle aspiration biopsy (performed ultrasound guided).
7. Radiofrequency ablation of the thyroid nodule.

All participants underwent RF ablation of the thyroid nodule were followed-up at 1 and 6 months for post procedure clinical evaluations.

### Ethical Consideration:

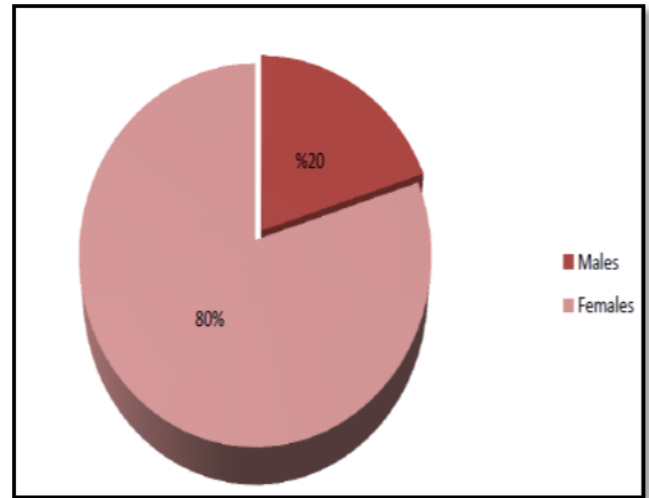
An approval of the study was obtained from Zagazig University Academic and Ethical Committee. Written informed consents from all participants were obtained. This work has been carried out in accordance with The Code of Ethics of the World Medical Association (Declaration of Helsinki) for studies involving humans.

### Statistical analysis

Statistical Package for Social Sciences, Windows® version 27, was used to analyse the data (IBM SPSS Inc). Quantitative data within a group were expressed as a number (%). The quantitative group is represented by mean and standard deviation. Unpaired Chi-square ANOVA, ROC curve, and linear correlation coefficient [r] were applied. P value was chosen at 0.001 for highly significant results and 0.05 for outcomes that were significant.

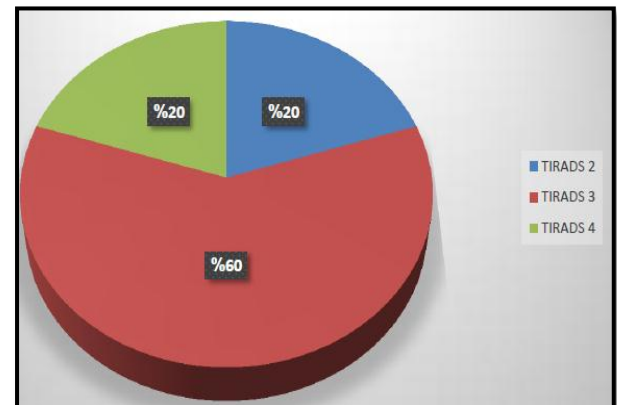
### RESULTS

The subjects with range of age between 20 and 55 years. About 80% were females and 20% were males (**Figure 1**).



**Figure (1):** Sex distribution of the cases in the study

According to TIRADS classification, there was 20% of cases had TIRADS 2 category; 60% of cases had TIRADS 3 category; and 20% of cases had TIRADS 4 category (**Figure 2**).



**Figure (2):** TIRADS categories of the cases in the study

Regarding the initial assessment before RF, the mean values of TSH, T3 and T4 were  $3.6 \pm 0.87$ ,  $2.76 \pm 0.39$  and  $1.07 \pm 0.23$ , respectively. The mean size of nodules was  $9.51 \pm 2.11$ . Concerning echogenicity, 53.3% of patients were Isoechoic. About 73.3% of patients had no calcifications; 80% had regular contour (**Table 1**).

**Table (1):** Initial assessment before RF among the studied subjects

Variables	Initial (n=40)
TSH (mIU/L), Mean $\pm$ SD	3.6 $\pm$ 0.87
Free T3 (nmol/L), Mean $\pm$ SD	2.76 $\pm$ 0.39
Free T4 (mcg/dl), Mean $\pm$ SD	1.07 $\pm$ 0.23
Nodule size (cm <sup>2</sup> ), Mean $\pm$ SD	9.51 $\pm$ 2.11
Echogenicity: (%)	
• Anechoic	13.3
• Hypoechoic	33.3
• Isoechoic	53.3
Calcification: (%)	
• None	73.3
• Microcalcification	13.3
• Macrocalcification	13.3
Contour:	
• Regular	80%
• Irregular	20%
Halo:	
• None	93.3%
• Rim	6.7%

Regarding the final assessment at 6 month after RF; the mean values of TSH, T3 and T4 were 1.86  $\pm$  0.43, 2.8  $\pm$  0.41 and 1.11  $\pm$  0.21, respectively. The mean size of nodules was 2.3  $\pm$  0.43. About 93.3 % of patients had no calcifications. All managed subjects with RF had 100 % regular contour with no halo (Table 2).

**Table (2):** Final assessment at 6 months after RF among the studied subjects

Variables	Initial (n=40)
TSH (mIU/L) Mean $\pm$ SD	1.86 $\pm$ 0.43
Free T3 (nmol/L) Mean $\pm$ SD	2.8 $\pm$ 0.41
Free T4 (mcg/dl) Mean $\pm$ SD	1.11 $\pm$ 0.21
Nodule size (cm <sup>2</sup> ) Mean $\pm$ SD	2.3 $\pm$ 0.43
Echogenicity: (%)	
• Anechoic	6.7 %
• Hypoechoic	46.7 %
• Isoechoic	46.7 %
Calcification: (%)	
• None	93.3 %
• Microcalcification	6.7 %
• Macrocalcification	0
Contour:	
• Regular	100%
• Irregular	0
Halo:	
• None	100 %
• Rim	0

## DISCUSSION

The majority of benign thyroid nodules have no symptoms and merely need to be monitored for management <sup>(11)</sup>. But some nodules need to be treated because of symptomatic growth, aesthetic issues, or a potential for malignant change <sup>(12)</sup>. Surgery is seen as an acceptable option in certain circumstances <sup>(13)</sup>.

Thyroid nodules are managed with nonsurgical, minimally invasive therapeutic techniques such as ethanol ablation (EA), percutaneous laser ablation (LA), and RF ablation <sup>(9,14)</sup>. RF ablation has been utilized for both benign nodules and recurrent thyroid cancer in patients who had relative contraindications to surgical therapy, while its effectiveness is still debatable <sup>(11)</sup>.

The current study patients with a benign thyroid nodule underwent RF ablation of the thyroid nodule and followed-up exams for 6 months for evaluate the effectiveness of RF ablation to manage benign solitary thyroid nodule.

In our study, the range of age between 20 and 55 years. About 80% were females and 20% were males. This similar to **Popoveniuc and Jonklaas** <sup>(15)</sup> revealed that Females are 4 times as likely than males to have thyroid nodules. The higher incidence of conception and multiparity is evidence that gender difference results from the influence of oestrogen and progesterone. Similarly, **Lee et al.** <sup>(11)</sup> found that thyroid nodules were more common in women.

Also, clinical studies have shown that the prevalence in pregnant and fertile women was much higher <sup>(16,17)</sup>, suggesting it's possible that the combined effects of oestrogen and progesterone are what cause gender differences <sup>(18)</sup>.

**Jiang et al.** <sup>(18)</sup> explained that oestrogen affects the thyroid gland and increases the production of thyrotropin (TSH), and that both healthy and malignant thyroid tissues exhibit oestrogen receptors, it may be inferred that oestrogen may be involved in the development of thyroid nodules and the expansion of thyroid cells.

In our study, there was 20% of cases had TIRADS 2 category; 60% of cases had TIRADS 3 category; and 20% of cases had TIRADS 4 category.

The guidelines of the American College of Radiology (ACR) TIRADS, and the Korean Society of Thyroid Radiology's K-TIRADS system, have proposed risk stratification systems with the goal of detecting nodule at greatest risk for malignancy and then to recommend graduated size cut-offs for FNA cytology <sup>(19)</sup>.

In our study, the initial assessment before RF; the mean values of TSH, T3 and T4 were 3.6  $\pm$  1.77, 2.76  $\pm$  0.39 and 1.07  $\pm$  0.23, respectively. While, the final assessment at 6 month after RF; the mean values of TSH, T3 and T4 were 1.86  $\pm$  0.43, 2.8  $\pm$  0.41 and 1.11  $\pm$  0.21, respectively.

**Mittal *et al.***<sup>(20)</sup> reported that measurement of serum TSH should be part of the first examination for all patients who report with a thyroid nodule. A subclinical or overt hyperthyroid condition should be taken into consideration if TSH levels are low. The presence of a subnormal TSH can be found in 10% or less of solitary nodules. Due to the development of autonomy in the nodules, it is linked to decreased TSH.

The previous findings denote preservation of thyroid functions after RF ablation, which was also confirmed by **Che *et al.***<sup>(21)</sup> noted that following this procedure, there were no patients with hypothyroidism compared to 71.5% after surgery. The same concept was also reported by Beck *et al.*, who reported that after thyroid RF ablation, there was only 0.07% (1/1459) hypothyroidism<sup>(22)</sup>.

RF ablation has demonstrated its effectiveness even in patients with hyperfunctioning benign thyroid nodules, as the reported rate of euthyroid condition after RF ablation ranges between 56% and 82% according to prior studies<sup>(21,23)</sup>.

In our study, the mean size of nodules was  $9.51 \pm 6.42$  before RF and was  $2.3 \pm 0.43$  after RF ablation. The mean volume reduction was 80%, 84%, 89%, 92%, and 95% at the 12-, 24-, 36-, 48-, and 60-month follow-ups, respectively, according to a previous study. In most individuals, symptoms and aesthetic issues improved or vanished after this procedure<sup>(24)</sup>. Usually, throughout the first month of RF ablation, the most volume reduction is seen, and thereafter, more volume reduction is gradually seen<sup>(22)</sup>.

Several mechanisms lead to a significant reduction of the nodule if the nodule is appropriately ablated, such as the frictional heat produced by oscillating ions and the slower-moving damage caused by heat conduction to the nearby remote area, result in a large diminution of the nodule<sup>(25, 26)</sup>.

According to Jung and his coworkers' findings, which are similar to ours, the volume of the ablated nodules dropped from 14.2 cm before to intervention to 8.1 and 3.2 cm after one and twelve months, respectively, with a statistically significant fall ( $p$  0.001). At the same follow-up visits, the diameter of these nodules fell from 3.8 before RF ablation to 3 and 2 cm, respectively ( $p$  0.001)<sup>(27)</sup>.

**Che *et al.***<sup>(21)</sup> noticed that at one-, three-, and six-month follow-up visits, the volume of the ablated nodules dropped from 5.4 cm prior to surgery down to 3.1, 2.1, and 1.2 cm, respectively ( $p$  0.05).

In an observational study, 215 individuals were monitored in a retrospective longitudinal observational study for more than 3 years following a single RF ablation. With continued progressive volume reduction at 1- and 2-year follow-up, the median nodule volume was considerably lower at 6 months following the surgery than it had been at baseline. At 3 and 4 years,

there was no discernible change in the nodule volume, but at 5 years, there was a further modest volume reduction. Small nodules with a volume under 10 mL showed the highest response (early decrease of 82%). Smaller volume reductions were seen in large nodules (75% for nodules with a volume of 10 to 20 mL and 65% for nodules with a volume of 20 mL). This demonstrates how challenging it is to completely ablate big nodules in a single session. Large nodules may need extra therapy for untreated peripheral nodule sections that can recur over time<sup>(27)</sup>.

In our study, 53.3% of patients were Isoechoic before RF ablation and was 47% post RF ablation. An earlier investigation found that the nodule's echogenicity was lower than it had been before ablation, and the intra-nodular vascularity had vanished<sup>(28)</sup>. Additionally, the ablated nodule changed to a very low echogenicity on the follow-up US<sup>(29)</sup>. It was also discovered in a more recent investigation that isoechoic nodules could turn weakly or noticeably hypoechoic<sup>(6)</sup>.

## CONCLUSION

Thyroid RF ablation is an effective and safe modality in people with benign thyroid nodule. It is a crucial tool for reducing benign thyroid nodule size and symptoms.

**Financial support and sponsorship:** Nil.

**Conflict of interest:** Nil.

## REFERENCES

1. **McDow A, Pitt S (2019):** Extent of surgery for low-risk differentiated thyroid cancer. *Surgical Clinics*, 99 (4): 599-610.
2. **Fresilli D, David E, Pacini P *et al.* (2021):** Thyroid nodule characterization: how to assess the malignancy risk. Update of the literature. *Diagnostics*, 11 (8): 1374.
3. **Wong R, Farrell S, Grossmann M (2018):** Thyroid nodules: diagnosis and management. *Medical Journal of Australia*, 209 (2): 92-98.
4. **Detweiler K, Elfenbein D, Mayers D (2019):** Evaluation of thyroid nodules. *Surgical Clinics*, 99 (4): 571-586.
5. **Peng J, Pan F, Wang W *et al.* (2020):** Malignancy risk stratification and FNA recommendations for thyroid nodules: A comparison of ACR TI-RADS, AACE/ACE/AME and ATA guidelines. *American Journal of Otolaryngology*, 41 (6): 102625-29.
6. **Deandrea M, Trimboli P, Mormile A *et al.* (2021):** Determining an energy threshold for optimal volume reduction of benign thyroid nodules treated by radiofrequency ablation. *European Radiology*, 31 (7): 5189-5197.
7. **Shin J, Baek J, Chung J *et al.* (2016):** Ultrasonography diagnosis and imaging-based management of thyroid nodules: revised Korean Society of Thyroid Radiology consensus statement and recommendations. *Korean Journal of Radiology*, 17 (3): 370-395.

8. **Baek J, Lee J, Sung J *et al.* (2012):** Complications encountered in the treatment of benign thyroid nodules with US-guided radiofrequency ablation: a multicenter study. *Radiology*, 262 (1): 335-42.
  9. **Muhammad H, Santhanam P, Russell J (2021):** Radiofrequency ablation and thyroid nodules: updated systematic review. *Endocrine*, 72 (3): 619-632.
  10. **Haugen B (2017):** 2015 American Thyroid Association management guidelines for adult patients with thyroid nodules and differentiated thyroid cancer: what is new and what has changed? *Cancer*, 123 (3): 372-381.
  11. **Lee G, You J, Kim H *et al.* (2019):** Successful radiofrequency ablation strategies for benign thyroid nodules. *Endocrine*, 64 (2): 316-321.
  12. **Tsai C, Pei D, Hung Y *et al.* (2006):** The effect of thyroxine- suppressive therapy in patients with solitary non- toxic thyroid nodules—a randomised, double-blind, placebo- controlled study. *International Journal of Clinical Practice*, 60 (1): 23-26.
  13. **Gharib H, Papini E, Garber J *et al.* (2016):** AACE/ACE/AME Task Force on Thyroid Nodules. American Association of Clinical Endocrinologists, American College of Endocrinology, and Associazione Medici Endocrinologi medical guidelines for clinical practice for the diagnosis and management of thyroid nodules—2016 update. *Endocr Pract.*, 22 (5): 622-639.
  14. **Hahn S, Shin J, Na D *et al.* (2019):** Ethanol ablation of the thyroid nodules: 2018 consensus statement by the Korean Society of Thyroid Radiology. *Korean Journal of Radiology*, 20 (4): 609-620.
  15. **Popoveniuc G, Jonklaas J (2012):** Thyroid nodules. *Medical Clinics*, 96 (2): 329-349.
  16. **Struve C, Haupt S, Ohlen S (1993):** Influence of frequency of previous pregnancies on the prevalence of thyroid nodules in women without clinical evidence of thyroid disease. *Thyroid*, 3 (1): 7-9.
  17. **Kung A, Chau M, Lao T *et al.* (2002):** The effect of pregnancy on thyroid nodule formation. *The Journal of Clinical Endocrinology & Metabolism*, 87 (3): 1010-1014.
  18. **Jiang H, Tian Y, Yan W *et al.* (2016):** The prevalence of thyroid nodules and an analysis of related lifestyle factors in Beijing communities. *International Journal of Environmental Research and Public Health*, 13 (4): 442-46.
  19. **Tessler F, Middleton W, Grant E *et al.* (2017):** ACR thyroid imaging, reporting and data system (TI-RADS): white paper of the ACR TI-RADS committee. *Journal of the American College of Radiology*, 14 (5): 587-595.
  20. **Mittal M, Ganakumar V, Shukla R *et al.* (2020):** Thyroid Nodule: Approach and Management. In *Goiter-Causes and Treatment*. Intech Open. DOI:10.5772/intechopen.91627
  21. **Che Y, Jin S, Shi C *et al.* (2015):** Treatment of benign thyroid nodules: comparison of surgery with radiofrequency ablation. *American Journal of Neuroradiology*, 36 (7): 1321-1325.
  22. **Baek J, Jeong H, Kim Y *et al.* (2008):** Radiofrequency ablation for an autonomously functioning thyroid nodule. *Thyroid*, 18 (6): 675-676.
  23. **Baek J, Moon W, Kim Y *et al.* (2009):** Radiofrequency ablation for the treatment of autonomously functioning thyroid nodules. *World Journal of Surgery*, 33 (9): 1971-1977.
  24. **Ospina N, Iñiguez-Ariza N, Castro M (2020):** Thyroid nodules: diagnostic evaluation based on thyroid cancer risk assessment. *BMJ.*, 368: 16670. doi: 10.1136/bmj.l6670
  25. **Wong K, Lang B (2013):** Use of radiofrequency ablation in benign thyroid nodules: a literature review and updates. *Int J Endocrinol.*, 13: 428363. doi: 10.1155/2013/428363
  26. **Huber T, Park A (2021):** Radiofrequency ablation of benign thyroid nodules. *Seminars in Interventional Radiology*, 38: 377-381.
  27. **Jung S, Baek J, Lee J *et al.* (2018):** Efficacy and safety of radiofrequency ablation for benign thyroid nodules: a prospective multicenter study. *Korean Journal of Radiology*, 19 (1): 167-174.
  28. **Jeong W, Baek J, Rhim H *et al.* (2008):** Radiofrequency ablation of benign thyroid nodules: safety and imaging follow-up in 236 patients. *European Radiology*, 18 (6): 1244-1250.
- Middleton W, Teefey S, Reading C *et al.* (2017):** Multiinstitutional analysis of thyroid nodule risk stratification using the American College of Radiology Thyroid Imaging Reporting and Data System. *American Journal of Roentgenology*, 208 (6): 1331-1341.