

Role of MR Spectroscopy in Characterization of Breast Masses

Sherif T Gamal El Din *, Mohammed A Darwish *, Ahmed M Monib *,
Togan T Abd El Aziz *.

* Department of Radiodiagnosis, Ain Shams University.

Abstract

Introduction: Dynamic contrast enhanced magnetic resonance imaging “MRI” is not 100 percent accurate in distinguishing benign from malignant lesions, resulting in a large number of breast biopsy procedures recommended on the basis of imaging findings. Proton magnetic resonance spectroscopy “¹H MRS” can provide chemical information about a lesion by measuring the levels of choline compounds, which are markers of an active tumor. In most cases, the results indicate whether the lesion is cancerous without need for biopsy. In addition to being used in breast cancer diagnosis, in vivo ¹H MRS has also been used to monitor breast cancer response to chemotherapy as well as in differentiating between scar tissue and recurrent cancer after breast-conserving therapy.

Aim of the work: To evaluate the diagnostic performance of magnetic resonance spectroscopy “MRS” in characterization of breast masses with histopathologic findings or follow up used as the reference standard.

Methods: The studied group included 50 female patients referred for MRI breast for workup of a suspicious clinical, mammographic, or sonographic abnormality. ¹H MRS was added to the routine study. Results of the contrast enhanced bilateral breast MRI and ¹H MRS of the 50 patients were all reported and compared with the histo-pathological results of surgery or biopsy and with the results of follow up of lesions that were not surgically removed or biopsied.

Results: there was a highly significant relation between ¹H MRS and histopathological. Follow Up results with p value = 0.005. The sensitivity, specificity, positive and negative predictive values of ¹H MRS for characterization of suspicious breast lesions in patients included in the study, were 90%, 93.3%, 90%, and 93.3% respectively.

Conclusion: ¹H MRS is a short non-invasive scan that can be inserted easily into standard clinical breast MRI protocols as a potential adjunct that can be added routinely to conventional breast MRI. Detection of choline peak with estimation of the choline signal to noise ratio “SNR” can accurately differentiate benign from malignant breast lesions with high sensitivity and specificity especially when its results are combined with the results of the standard dynamic MRI scan.

Key words: MRI, ¹H MRS, Spectroscopy, Breast Masses.

INTRODUCTION

During the past two decades, several well-established clinical imaging modalities have been in use to study the architecture, physiology and function of breast cancer. Methods such as X-ray mammography, ultrasound and physical examination are often limited in sensitivity and specificity, especially in young women ⁽¹⁾.

MR imaging of the breast is non-invasive and uses no ionizing radiation. Its primary benefit is high sensitivity, the highest of any imaging technique for breast lesions. MR offers high soft-tissue contrast, multi-planar sectional imaging with 3-D rendering of 1 or both breasts, the ability to detect small volume residual tumor and measurement of lesion size that corresponds with pathological measurement ⁽²⁾. Consequently, there has been considerable interest in the development of adjunct MR imaging methods to improve the specificity of dynamic contrast-enhanced breast MR imaging, and proton MR

spectroscopy “¹H MRS” imaging is being investigated for its potential to improve breast disease diagnosis at the cost of a small increase in examination time ⁽³⁾.

Magnetic resonance spectroscopy “MRS” offers unique possibilities for non-invasive clinical studies of human biochemistry in vivo. Chemical shift, which refers to the variation in the resonance frequency due to the chemical environment, can be explained by the fact that the moving electrons surrounding the protons can generate their own local magnetic field. With its ability to identify different compounds by their chemical shifts, MRS is especially useful in studying cellular metabolism to detect cancer cells ⁽⁴⁾.

Rather than generating an image, MRS produces a graph of the resonance amplitudes of various metabolites on the y-axis (in arbitrary units) versus the resonance frequencies on the x-axis (in Hz or ppm). The

resonance amplitudes and frequencies are determined by the relative concentrations and the chemical structures of the metabolites, respectively ⁽⁴⁾.

The markers that are useful in breast diseases are centered at 3.2 ppm and are generally referred to as the choline peak. Choline is considered an important metabolite in ¹H MRS of the mammary gland area because they are precursors of the phospholipids that compose cell membranes, increases in choline signals are thought to reflect increased membrane synthesis. In the mammary gland area, choline shows a promise of enabling differentiation between benign and malignant tumors and of serving as an indicator of tumor activity and viability ⁽⁵⁾.

¹H MRS can provide chemical information about a lesion by measuring the levels of choline compounds, which are markers of an active tumor ⁽⁶⁾.

In addition to being used in breast cancer diagnosis, in vivo ¹H MRS has also been used to monitor breast cancer response to chemotherapy as well as in differentiating between scar tissue and recurrent cancer after breast-conserving therapy ⁽¹⁾.

We aimed at this study to evaluate the diagnostic performance of MRS in characterization of breast masses with histopathologic findings or follow up used as the reference standard.

PATIENTS & METHODS

During the period between June 2011 and October 2013, 50 female patients, ranging in age from 22-59 years, were included in this prospective study. They were referred to perform Contrast-enhanced bilateral breast MRI at Ain Shams University Hospitals and Misr Radiology Center for workup of a suspicious clinical, mammographic, or sonographic abnormality. ¹H MRS study was added to the routine study. We excluded patients with bad general conditions or those having contraindication for MRI.

The protocol of our study was approved by The Research Ethics Committee at the Faculty of Medicine, Ain Shams University. Informed consent, including potential risks and benefits of the procedure, was obtained from all patients.

MRI was performed using a 1.5Tesla superconductive Philips scanner. Following the patients' informed consent and exclusion of contraindications, patients were placed in prone position and examined using bilateral breast surface coils.

MRI protocol was: both axial T1W & T2W images, axial/ sagittal STIR "short tau inversion recovery and axial/ sagittal T1W post-contrast.

Dynamic post-contrast MRI: Using a 3D fat-suppressed volumetric interpolated breath hold examination (VIBE) sequence with parallel acquisition was performed every minute for the following seven minutes after injection of a bolus of Gadopentate dimeglumine (0.1 mmol/kg; Magnevist, Bayer HealthCare) at a rate of 2 mL/s, followed by a 20-mL saline flush administered using an automatic injector. Both breasts were examined in the axial plane at 30 s, 1 min, 2 min, 3 min, 4 min, 5 min and 6 min after contrast injection, respectively. The parameters for dynamic MRI were as follows: 5.2/2.3; flip angle, 12 degrees; field of view, 33 cm; matrix, 448X318; receiver bandwidth, 430 Hz per pixel; interpolated slice thickness, 0.9 mm; partitions, 144; and time of acquisition, 60 s.

The analysis of enhancement kinetics is done by measuring the signal intensity in region of interest (ROI), and tracking its course over the dynamic series (time–signal intensity curve). ROIs were placed into the area that exhibits strongest enhancement on the first postcontrast image.

For single voxel ¹H MRS, it was performed after all MRI sequences had been performed by using a point-resolved spectroscopy sequence (PRESS). The parameters of MRS were TR/TE; 620/270; voxel size; 15x15x15 mm³; 256 acquisitions; spectral width, 1,000 Hz; 1,024 data points; and time of acquisition, 7 min. This relatively long TE (270 ms) was chosen to increase the visibility of the Choline "Cho" resonance because of the longer T2 of Cho in comparison with that of lipids. For voxel placement, coronal and sagittal contrast-enhanced T1-WIs was used as scout images.

Shimming was performed automatically first, followed by manual shimming on the water resonance for optimization of the homogeneity in each volume of interest. After the shimming procedure, spectra were acquired with water suppression by applying three chemical shift-selective excitation pulses. By spectral suppression using dual band-selective inversion with gradient dephasing the transverse magnetization was selectively dephased before and after the second spin-echo pulse.

In this study, a threshold signal-to-noise ratio of 2 was used for choline. Results were deemed positive when the signal to noise ratio was greater than or equal to 2 and negative in all other cases.

First, we evaluated contrast-enhanced MR images prospectively & used the BI-RADS MRI lexicon for diagnostic interpretation. Second, we reviewed the spectroscopic study for final radiological characterization of focal breast lesions.

Analysis of data was done by using SPSS (Statistical Program for Social Science version 15) as follows: Description of quantitative variables as mean, SD and range, Description of qualitative variables as number and percentage, Chi-square test was used to compare qualitative variables “P value <0.05 significant and P value <0.01 highly significant” and finally we calculated: Sensitivity, Specificity, PPV (positive

predictive value) and NPV (negative predictive value).

RESULTS

This study included 50 female patients. The mean age of included women was 41.58 ± 9.42 years (range 22 - 59 years). Among the studied cases the most common clinical presentations were breast lumps **and** previous history of surgery for breast carcinoma to differentiate recurrence from post surgical scarring.

Among the 50 studied patients, 22 patients were followed up for having lesions which are thought to be probably benign and the follow up of these lesions didn't show growth over time and confirmed the benign nature of such lesions and 28 patients among the studied group had been subjected for biopsy and 20 patients were discovered to have malignant lesions and 8 patients were classified as benign lesions “figure 1”.

Figure 1: pie chart showing histopathological and follow up results among the studied group.

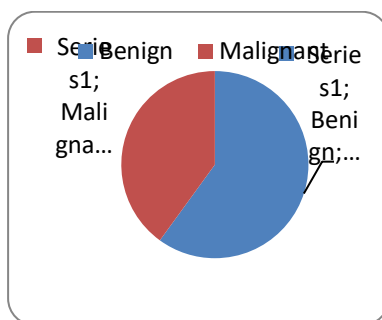


Table 1: Distribution of the studied group as regards histopathology findings and Follow up:

Histopathology/Follow up	Frequency	Percent
Fibroadenoma	14	28%
Benign Postoperative scar/granulation tissue	6	12%
Phylloids (with malignant change to undifferentiated carcinoma)	2	4%
Abcess	2	4%
Mastitis	2	4%
Simple/Complicated cysts	4	8%
Condensed glandular tissue	2	4%
Intra-ductal papilloma	0	0%
Invasive ductal carcinoma (IDC)	14	28%
Invasive lobular carcinoma (ILC)	4	8%
Ductal carcinoma in situ (DCIS)	0	0%
Total	50	100%

Table 2: The correlation between the MR lesion type and pathology/ Follow Up results:

MR shape	Pathology/ Follow Up results		Total
	Benign	Malignant	
Mass	21	19	40
Non-Mass	9	1	10
Total	30	20	50

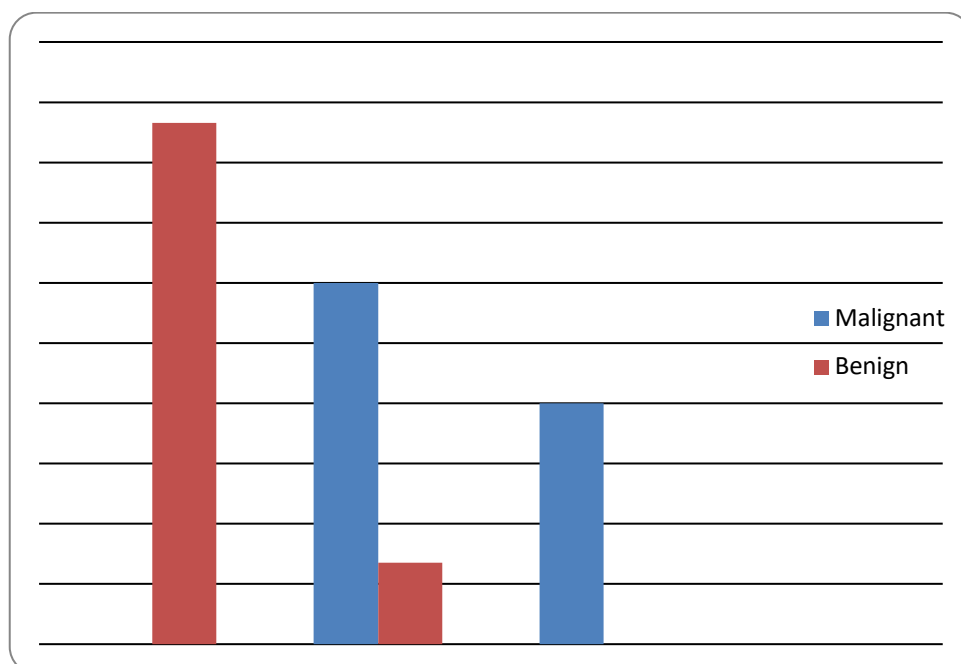


Figure 2: A column chart showing the correlation between type of dynamic curve and pathology/ Follow up results.

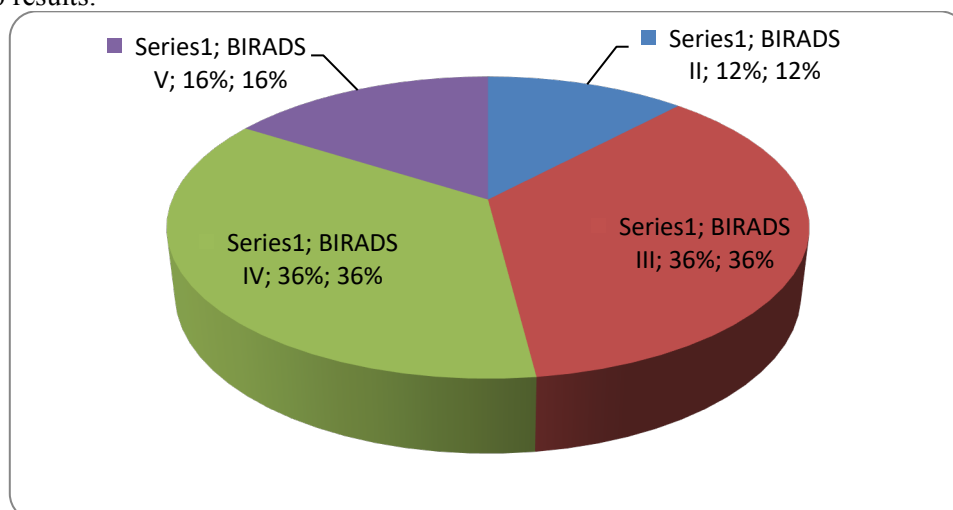


Figure 3: A pie chart showing different MRI findings among the studied group.

¹H MRS study didn't demonstrate a choline peak in 20 of the 50 studied lesions & all of them were benign by histopathology. It was able to accurately detect 18 of the 20 malignant lesions as choline SNR more than or equals 2 with two false +ve as well as two false -ve cases "Table 3" and "figure 4". There was highly significant relation between our results by ¹H MRS and histopathological/ Follow Up results with p value = 0.005.

Table (3): Showing the correlation between the ¹H MRS outcome and pathology/ follow up “FUP” results:

Proton MR Spectroscopy	Pathology/FUP		Total	P
	Benign	Malignant		
Negative Choline peak (Benign):	20	0	20	0.005*
Choline SNR less than 2 (Benign):	8	2	10	
Choline SNR more than or equals 2 (Malignant)	2	18	20	
Total	30	20	50	

P* ≤0.01 = highly significant.

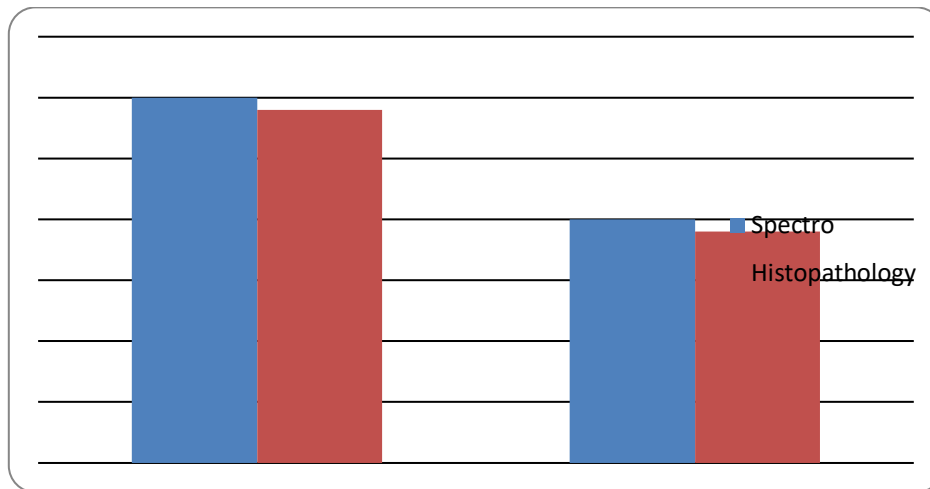


Figure 4: a column chart for comparison between ¹H MRS versus pathology and follow up results.

Table 4: Comparison between the validity of interpreting dynamic MRI without spectroscopy versus dynamic MRI with spectroscopy among the studied group:

Variables	Dynamic MRI <u>without</u> spectroscopy	Dynamic MRI <u>with</u> spectroscopy
Sensitivity	100%	100%
Specificity	80%	93.3%
PPV	76.9%	90.9%
NPV	100%	100%
Accuracy	88%	96%

The above table indicates improved breast cancer detection through the combination of morphological and enhancement information from DCE-MRI and metabolic information from 2D MRS. The sensitivity and specificity of their combined contrast enhanced MRI with MRS increased to 100% and 93%, respectively (Only two False +ve cases) & this means that we partially overcame the problem of unnecessary biopsy characterizing the two components individually.

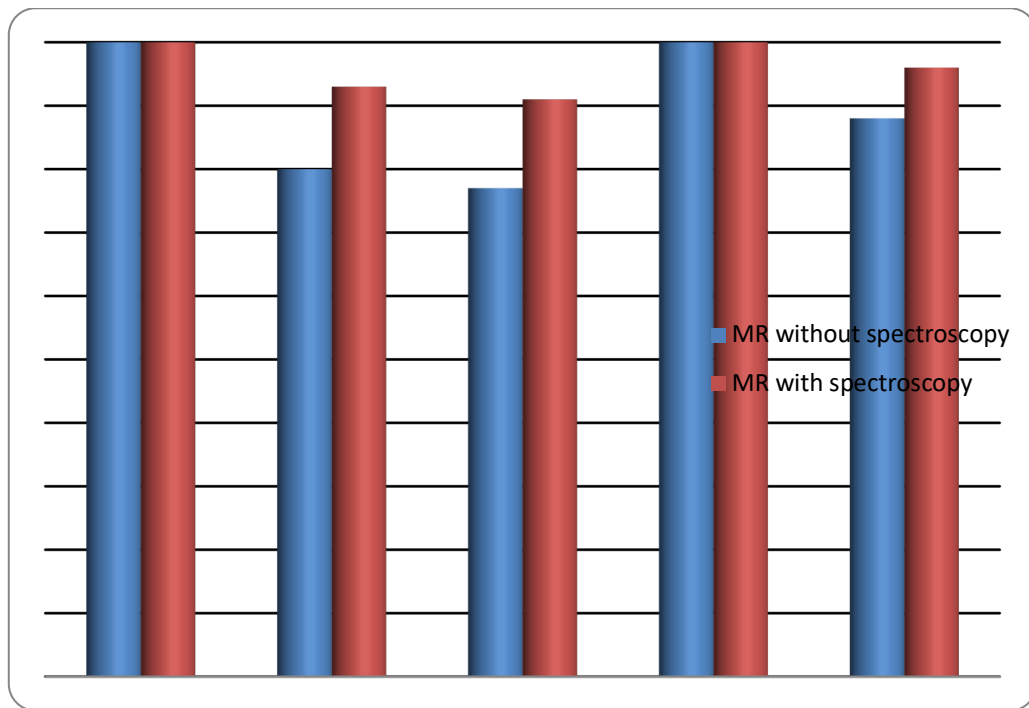


Figure 5: A column chart for comparison between validity of dynamic MRI without Spectroscopy versus dynamic MRI with Spectroscopy in characterization of breast lesions among the studied group.

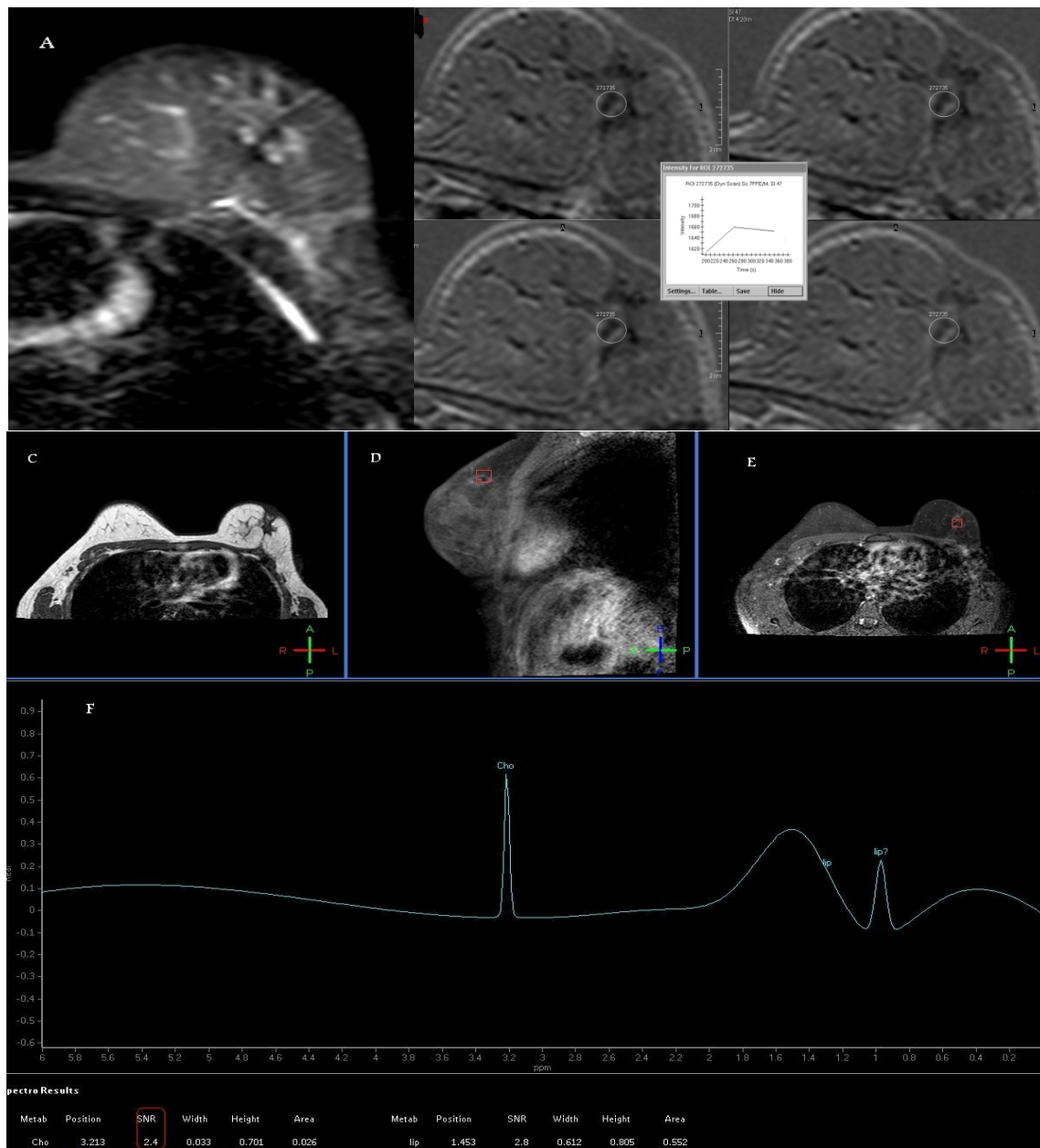


Figure 6: (A) T2 STIR: an area of architectural distortion of heterogeneous signal intensity was seen at about 11 o'clock position in the left breast in the operative bed of previous lumpectomy (B) T1W post-contrast fat suppression: showing non mass appreciable enhancement with plateau signal intensity dynamic curve (Type II curve). (C), (D) & (E) are pre-contrast T1 & post contrast T1 after fat suppression in the sagittal & axial views respectively showing the area of architectural distortion with obvious post-contrast enhancement. (F) ¹H MRS: revealed elevated choline peak with choline SNR of 2.4 (red rectangle at the lower left part of the image) consistent with recurrent malignant tumor at the operative bed. This patient had an excisional biopsy which revealed recurrent invasive ductal carcinoma "grade2"

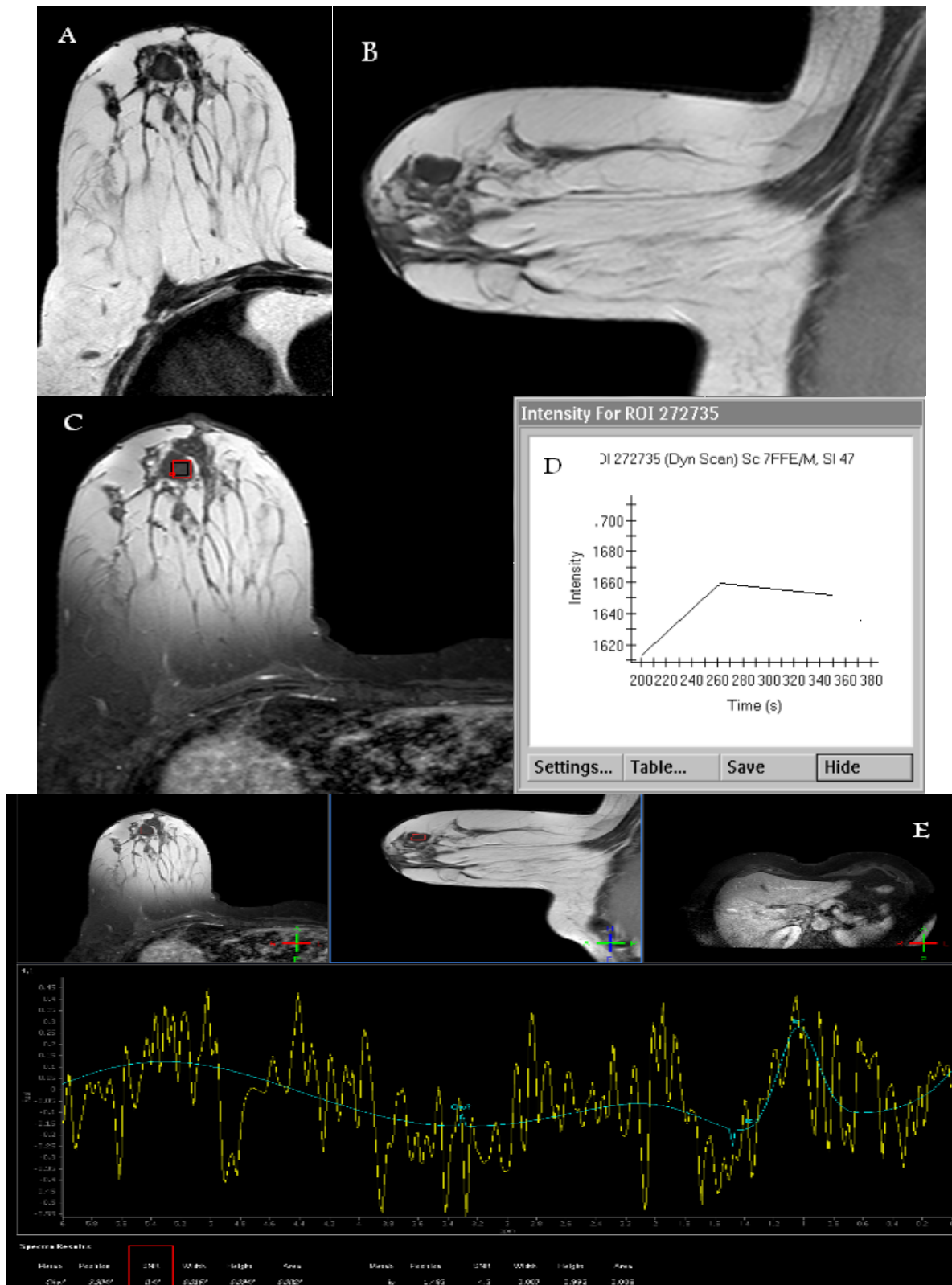


Figure 7: (A): T2 WI showing Retro-areolar lobulated mass lesion of intermediate signal intensity in this old lady with +ve family history of breast cancer as well as past history of left mastectomy for malignant mass. (B): Sagittal T1W: Hypointense lobulated mass. (C): T1W post-contrast fat suppressed axial image showing mass enhancement with plateau signal intensity dynamic curve (Type II curve) (D). (E) ¹H MRS: Minimally elevated choline peak with choline SNR of 0.4 (red rectangle at the lower left part of the image) consistent with benign entity. This patient had an excisional biopsy which revealed fibroadenoma.

DISCUSSION

As, MR imaging of the breast known for its inherently high sensitivity but only moderate specificity for the characterization of breast lesions. Thus, efforts have been directed toward developing new pulse sequences and evaluation methods that improve lesion characterization⁽⁷⁾.

The most studied application for breast ¹H MRS is to distinguish benign from malignant lesions before biopsy. The first published papers on this topic proposed the idea that total choline "tCho" could be used as a marker of malignancy⁽⁸⁾.

In MRI, the characterization of the nature of a breast tumor is dependent on the lesion morphology (architectural configuration, margin status), as well as the permeability of the lesional tissue to contrast agents. ¹H MRS, in contrast, utilizes a totally different mechanism, by the detection of increased content of composite choline metabolites within malignant lesions and this is the useful criteria on which ¹H MRS differentiation between benign and malignant lesions is based⁽⁴⁾.

Our study included 50 patients, among which 20 patients turned out to be malignant. About 70% of the presented malignant cases were in the 41- 50 age group.

This study included a wide range of lesion sizes, ranging from 0.6 cm up to 10 cm yet; our study is not a reliable indicator of the effect of lesion size on the detectability of choline containing compounds in breast lesions since only two benign cases were less than 1 cm & the rest of the lesions are predominantly more than 1.5 cm with no DCIS cases included in the studied group.

It is to be noted that the two false –ve cases by 1H MRS were both ILC of more than 8 cm each & this could be explained by presence of areas of necrosis within the tumor.

In patients with history of surgically resected breast cancers, the expected alterations in the treated breast include the surgically caused scar formation and deformity as well as radiation induced inflammatory pattern and fibrosis in patients subjected post-operatively to radiotherapy regimen. The ability of mammography to show the tumor in the irradiated breast is somewhat compromised by the increased density and surgical deformity present in these breasts⁽⁹⁾. Diagnostic problems are also encountered with ultrasonography because of hypoechoic areas and shadowing within the scar tissue. Ultrasonography was

insufficient for the detection of recurrent disease. Fine-needle aspiration biopsy has insufficient sampling rate. A negative result should be interpreted cautiously and should not preclude further investigation of a suspect or equivocal lesion. Core needle biopsy has demonstrated high accuracy and it should be considered an alternative for obtaining a non-surgical histologic diagnosis due to the high sensitivity of breast MRI, yet, the limitation with breast MRI is its specificity, with a wide range reported, but an average of slightly less than 65%⁽¹⁰⁾.

In our study, we investigated 1H MRS as an important resource to increase breast MRI specificity in these patients. We had 16 patients comprising 32% of the studied population with history of previous surgery for breast malignancy presented with suspicion of tumor recurrence or to differentiate post-surgical scar from recurrent malignant process. 8 cases out of the 16 patients had recurrence and the 1H MRS study could accurately diagnose them, in which there were obvious detectable choline peaks at the frequency of 3.2 ppm with a choline SNR between 2.3 & 2.5 in the 8 cases. The recurrence was observed in the contra-lateral axillary LNs in two of the 8 +ve cases.

1H MRS was able precisely to exclude recurrence in 6 of the 16 postsurgical patients as no choline peak was detectable in the affected breast. Two patients out of the 16 showed false +ve results (Chronic inflammatory lesions with minimal atypia) with detectable choline peak & choline SNR of 2.1 Thus; According to our results, 1H MRS is a sensitive method to differentiate tumor recurrence at the prior surgery site after conservative surgery and radiation therapy with sensitivity of 100%, specificity of 75% and overall accuracy of 88%.

Our results agree with E.M. Khattab *et al.*⁽¹¹⁾ who studied the value of Magnetic resonance spectroscopy in recurrent breast masses following conservative surgery and radiation therapy and found that 1H MRS was a sensitive method to differentiate tumor recurrence at the prior surgery site after conservative surgery and radiation therapy with sensitivity of 94.7% and positive predictive value of 94.7%.

Most enhancing non-mass lesions, except those with homogeneous internal enhancement, have areas of normal glandular tissue interspersed between areas of abnormal enhancement. This interspersing of abnormal enhancement with normal glandular tissue in

enhancing non-mass lesions theoretically could pose technical problems for 1H MRS. Mobile lipids, present in areas of normal glandular tissue within the prescribed MR spectroscopy voxel, may produce spurious echoes (sidebands) that interfere with other breast metabolite signals and cause problems in identifying the choline resonance. Skill is necessary in planning MRS to select an appropriate voxel size and a position that includes as much of the lesion as possible (to maximize the choline signal) while minimizing the presence of adipose tissue ⁽¹²⁾.

In this study, we had 10 cases out of the 50 had non-mass-like lesions in MRI. 8 of them turned out to be benign while 2 had malignancy on histo-pathological assessment namely Invasive Ductal Carcinoma (IDC). The Choline SNR for the two malignant lesions presenting with non-mass-like pattern were around 2.4. Two false +ve cases (Chronic inflammatory lesions with minimal atypia) were recorded out of the 10 non-mass like lesions with choline SNR of each 2.1. The remaining 6 non-mass like lesions were benign by 1H MRS with no detectable choline peak in any of them.

Despite the forementioned pitfalls, we found that MRS was useful in the evaluation of enhancing non-mass lesions. During lesion selection, lesions that were 1 cm in volume or larger were included; this size allowed enhancement to be seen filling most of the selected region. Although lipid sidebands were detected in our population, they did not obscure the choline resonance peak and therefore did not interfere with the detection of this peak.

In our study population, 1H MRS had 100% sensitivity and 75% specificity for the detection of malignancy in enhancing non-mass lesions. Larger studies, ideally from multiple centers and with a variety of malignant and benign histologic findings, are needed to further evaluate the diagnostic performance of breast 1H MRS in assessment of non-mass enhancing lesions.

These results were in agreement with Bartella et al. ⁽¹²⁾ who evaluated prospectively the diagnostic accuracy of 1H MRS in diagnosis of malignant enhancing non-mass lesions identified at breast MR imaging & concluded that 1H MRS had 100% sensitivity and 85% specificity for the detection of malignancy in enhancing non-mass lesions.

The most widely used form of DCE-MRI "Dynamic Contrast Enhanced-MRI" analysis is the assessment of the type of time-signal intensity curve (i.e., kinetic curve) by categorizing the washout pattern of a

gadolinium contrast agent. Despite the good results reached within this technique, in Nicolosi's et al. ⁽¹³⁾ study, the number of false positive cases going through unnecessary biopsy approaches the 14% of total population. This result is considered in good accordance with literature where a positive washout phenomenon (type III) is associated with a likelihood of breast cancer of 87%; whereas a progressive signal intensity increase (type I) is associated with a likelihood of breast cancer of only 6%, irrespective of other imaging findings that are used for the diagnosis; and, finally, a plateau signal intensity time course (type II) is seen both in malignant and benign lesions but with a distribution of three to two. Therefore, a type II time course is generally used to support the suspicion of breast cancer ⁽¹³⁾.

In this study, we had 26 patient out of the 50 patients had type I curve which on pathology/ follow up turned out to have benign lesions. 8 cases had type III curve which on pathology turned out to be malignant. The rest of cases "the remaining 16 cases" had type II curve with 12 patients of them turned out to have malignancy on pathology and 4 patients were benign lesions on pathology/ follow up.

Although type II curve is more going with malignant lesions as above described by Kuhl ⁽⁷⁾ yet, we had 4 patients having benign lesions comprising 25% of those presented with type II curve pattern. So in cases having type II curve, further assessment by another technique "such as 1H MRS" may be required to help in further confirmation of the nature of the lesion.

From our results, 2 of the patients presented with type II curve have detectable choline peak with choline SNR of 0.2 (Benign pattern), 12 cases had detectable choline peak with choline SNR between 2.1 & 18.2 (malignant pattern) & only 2 false +ve cases (Chronic inflammatory lesions with minimal atypia) having detectable choline peak with choline SNR of 2.1. From above mentioned data, we can conclude that 1H MRS could be a valuable additional tool in cases with inconclusive dynamic MR results.

In our study 24 cases were benign (BIRADS II and BIRADS III) by dynamic MRI criteria and 26 cases were suggestive of malignancy by dynamic MRI criteria alone without taking into consideration the (1H) MRS results (BIRADS IV and BIRADS V).

According to our results, the diagnostic sensitivity and specificity of dynamic MRI without 1H MRS was 100% & 80% respectively with statistically highly significant association

between dynamic MRI and pathology (P value <0.001 highly significant). There were 6 false +ve results among the 26 malignant cases diagnosed at first instance by conventional dynamic MRI without spectroscopy (2 Atypical fibroadenomata, 2 Chronic inflammatory lesions with minimal atypia & 2 post-operative scars with surrounding inflammatory changes) yet, no false -ve results were noted among the 24 benign cases.

In our study 1H MRS didn't demonstrate a choline peak in 20 of the 50 studied lesions & all of them were benign by histopathology. It was able to accurately detect 18 of the 20 malignant lesions as choline SNR more than or equals 2 with two false +ve (Chronic inflammatory lesions with minimal atypia) as well as two false -ve cases (ILC with large tumor size around 8 cm).

From our data, it seems that the joint use of DCE + MRS does not encompass the problem of misdiagnose of ILC characterizing MRS and DCE indexes and ascribable to the weak or absent angiogenic activity associated with this kind of cancer.

According to our results, the diagnostic sensitivity and specificity of 1H MRS in characterization of breast lesions were 90% & 93.3% respectively with statistically highly significant association between 1H MRS and histopathology (P value = 0.005).

The most of previous works analyzing spectroscopic metabolites as potential markers of malignancy limit to calculate sensitivity and specificity associated to choline without quantifying the added values of spectroscopy on DCE-MRI. To the best of our knowledge only five works try to assess benefits deriving by the joint use of the two techniques. Jacobs *et al.* ⁽¹⁴⁾ analyze 9 patients regarding morphology, enhancement curve and Choline SNR. Their analysis is qualitative and concludes that a combination of DCE and MRS may improve specificity. Meisamy *et al.* ⁽¹⁶⁾ conducted an analysis on 55 patients. Four radiologists assessed the percentage probability of malignancy based on morphologic features, time-signal intensity curve and choline concentration. On the basis of this percentage ROC curves have been generated showing a mean sensitivity, specificity and accuracy (94%, 57% and 90%) greater than DCE-MRI (87%, 51% and 73%) and MRS (69%, 90% and 83%). Dorrius *et al.* ⁽¹⁵⁾ analyze in 24 patients the BIRADS index and Choline concentration showing that MRI alone manifests a sensitivity of 100%, specificity of 45.5% and accuracy of

96% while accuracy of MRS is 100%. A qualitative analysis of the joint use of the two techniques brings them to conclude that MRS can improve the accuracy of DCE-MRI. Lipnick *et al.* ⁽¹⁷⁾ analyze in 18 patients the enhancement curve and some metabolites ratio. As in our works they calculate sensitivity and specificity associated to dynamic curve type obtaining 100% and 70%, respectively. Finally, they show that two malignant lesion having plateau curve enhancement show a choline SNR greater than cutoff value while one malignant lesion having Choline SNR lower than cutoff manifests a washout pattern. They conclude that the joint use of the two techniques brings to the correct diagnosis of all subjects in their study (sensitivity and specificity both equal to 100%) ⁽¹³⁾. We observed (based on our results) improved breast cancer detection through the combination of morphological and enhancement information from DCE-MRI and metabolic information from 2D MRS. The sensitivity and specificity of the combined assessment of contrast enhanced MRI & 2D MRS had increased to 100% and 93.3% respectively.

In this study and among our 20 malignant cases, 4 cases were -ve for axillary LNs on either side by conventional MRI criteria, 4 cases underwent axillary clearance as a part of previous breast surgery & we did 1H MRS study for only 6 cases out of the 12 cases who were +ve for axillary LNs to investigate the diagnostic power of 1H MRS in differentiating metastatic from reactionary lymphadenopathy. 4 out of the 6 studied cases showed obvious choline peak with choline SNR more than 2.5 indicating metastatic spread from the contralateral removed breast in the 4 cases. The remaining 2 morbidly obese cases were falsely -ve for choline in the tumor itself as well as the ipsilateral hugely enlarged LNs but histopathology confirmed that these LNs are malignant.

Although, these numbers are not enough to draw a significant conclusion, it is expected that 1H MRS could be of value in differentiating metastatic from reactionary lymphadenopathy yet; studies with larger groups of patients are still needed to confirm this. This observation is coping with the results of Yeung *et al.* ⁽¹⁸⁾ who investigated the possibility of obtaining interpretable 1H spectra in vivo from untreated patients with primary breast cancer scheduled to undergo breast surgery and axillary nodal dissection. They reported that 1H MRS is a feasible in vivo technique that is capable of detecting choline in metastatic nodes.

It should be kept in mind that MRS has a generally low signal-to-noise ratio. This fact limits the applicability of MRS in the diagnosis of early breast cancer and generally small lesions. Although breast cancer might be detected by means of spectroscopic imaging only, single voxel spectroscopy cannot be used for lesion detection. Consequently, MRS depends on further MR imaging-based imaging techniques.

One of the most important limitations, this study didn't include a variety of malignant pathological entities i.e. mucinous carcinomas and pure DCIS was not represented in our study.

Finally, like in other studies, the sample of the present study is relatively small, and future studies with greater populations should be considered, and this is one of the next steps of the authors.

CONCLUSION

¹H MRS is a short non-invasive scan that can be inserted easily into standard clinical breast MRI protocols as a potential adjunct that can be added routinely to conventional breast MRI. Detection of choline peak with estimation of the choline SNR can accurately differentiate benign from malignant breast lesions with high sensitivity and specificity especially when its results are combined with the results of the standard dynamic MRI scan.

REFERENCES

1. **Jagannathan NR (2009):** Breast MR.NMR Biomed.,22: 1-2
2. **Odle TG (2006):** Breast MR. Radiologic Technology 78:45M-65M
3. **Pereira FP, Martins G and Figueiredo E (2009):** Assessment of breast lesions with diffusion-weighted MRI: comparing the use of different b values. AJR Am J Roentgenol.,193(4):1030–1035.
4. **Gary M Tse, Jingfei Ma and Humairah S Cheung (2009):** Chapter 2: Basic Principles and Techniques of MR Spectroscopy. In: Magnetic Resonance Spectroscopy Of Breast Tumors, 1st edition, edited by Gary M. Tse, Humairah Samad Cheung, and Jingfei Ma, Nova., 2:15-35.
5. **Tozaki M & Maruyama K (2010):** Current status and future prospects of proton MR spectroscopy of the breast with a 1.5T MR unit. J Oncol; Vol. 2010. PID: 781621.
6. **Dershaw DD (2006):** Proton MR Spectroscopy with choline peak as malignancy marker improves positive predictive value for breast cancer diagnosis: preliminary study. Radiology, 239(3):686-692.
7. **Kuhl C (2007):** The current status of breast MR imaging Part I. Choice of technique, image interpretation, diagnostic accuracy, and transfer to clinical practice. Radiology, 244(2): 365- 378.
8. **Patrick J Bolan, Michael T Nelson, Douglas Yee and Michael Garwood (2005):** Imaging in breast cancer: Magnetic resonance spectroscopy. Breast Cancer Research, 7:149-152.
9. **Belli P, Costantini M, Romani M, Marano P, Pastore G. (2002):** Magnetic resonance imaging in breast cancer recurrence. Breast Cancer Res Treat, 73(3):223–35.
10. **Rinaldi P, Giuliania M, Belli P, Costantinia M, et al. (2010):** DWI in breast MRI: Role of ADC value to determine diagnosis between recurrent tumor and surgical scar in operated patients. Eur J Radiol, 75 (2): e 114-23.
11. **Enass M Khattab, Ghada Abdulmonaem, Ahmed Zain El-Abden Al-Attar (2012):** Magnetic resonance spectroscopy in recurrent breast masses following conservative surgery and radiation therapy. The Egyptian Journal of Radiology and Nuclear Medicine, 43, 19-24.
12. **Bartella L, Thakur SB, Morris EA, et al. (2007):** Enhancing non-mass lesions in the breast: evaluation with proton 1H MR spectroscopy. Radiology, 245:80–87.
13. **Stefania Nicolosi, Giorgio Russo, Ildebrando D'Angelo, Giuseppe Vicari, Maria Carla Gilardi, Giovanni Borasi (2013):** Combining DCE-MRI and 1H-MRS spectroscopy by distribution free approach results in a high performance marker: Initial study in breast patients. J. Biomedical Science and Engineering, 6, 357-364.
14. **Jacobs MA, Barker PB, Argani, P et al. (2004):** Combined dynamic contrast enhanced breast MR and proton spectroscopic imaging: A feasibility study. Journal of Magnetic Resonance Imaging, 21, 23-28.
15. **Dorrius MD, Pijnappel R M, van der Weide Jansen M et al. (2012):** The added value of quantitative multi- voxel MR spectroscopy in breast magnetic resonance imaging. European radiology, 22, 915-922.
16. **Meisamy S, Bolan PJ, Baker EH et al. (2005):** Adding in vivo quantitative 1H MR spectroscopy to improve diagnostic accuracy of breast MR imaging: Preliminary results of observer performance study at 4.0 T. Radiology, 236, 465-475.
17. **Lipnick S, Liu X, Sayre J et al. (2010):** Combined DCE-MRI and single voxel 2D MRS for differentiation between benign and malignant breast lesions. NMR in Biomedicine, 23, 922:930.
18. **Yeung DK, Yang WT, Tse GM. (2002):** Breast cancer: in vivo proton MR spectroscopy in the characterization of histopathologic subtypes and preliminary observations in axillary node metastases. Radiology, 225: 190–197.