

## Corneal Endothelial Changes after Iris-Claw Anterior Chamber Phakic Intraocular Lens Implantation

Magdy E. Khallaf<sup>1</sup>, Hassan M. Bayomi<sup>2</sup>, Taha A. Farouk<sup>3</sup>

<sup>1,2,3</sup>Department of ophthalmology, Faculty of Medicine, Al-Azhar University, Cairo, Egypt

### ABSTRACT

**Background:** Compared to other refractive surgeries, implantation of phakic intraocular lenses (pIOL) have more desirable results and are potentially reversible procedures due to the possibility of explanting these lenses. These methods usually do not require expensive or special surgical equipment and most ophthalmologists are able to perform these procedures., however disabilities resulting from pIOL are more severe compared to corneal refractive surgery. Due to the potential risk of damage to anterior segment structures, especially corneal endothelial cell loss, pIOL implantation is subjected to debate.

**Aim of the Work:** To evaluate the endothelial cell count changes in eyes implanted with the iris-claw phakic lens for treatment of moderate to high myopia as regard changes in cell density.

**Patients and Methods:** This study included Ten eyes of patients with moderate to high myopia implanted with The Iris-Claw Anterior Chamber Phakic Intraocular Lens at Al-Hussein University Hospital, In this prospective randomized study we did Preoperative specular microscopy and serial postoperative specular microscopy (Topcon SP- 1P, Topcon Medical Inc., Japan.) were performed to evaluate endothelial cell count changes over 6 months. Endothelial cell images were collected in the central region of the cornea before surgery and 1 and 6 months after surgery. The main outcome measures were central corneal ECD and the percentage of corneal endothelial cell loss. Secondary outcome measures were UCVA, BCVA, manifest refraction, and complications.

**Results:** Preoperative mean endothelial cell count was  $3198.50 \pm 444.67$  cells/ mm<sup>2</sup> (range, 2715.00 – 3846.00 cells/ mm<sup>2</sup>)., it was  $3074.50 \pm 410.76$  cells/ mm<sup>2</sup> (range, 2609.00 – 3686.00 cells/ mm<sup>2</sup>) at 1 month after surgery.,  $3003.00 \pm 411.91$  cells/ mm<sup>2</sup> (range, 2532.00 – 3610.00 cells/ mm<sup>2</sup>) at 6 months after surgery. The mean endothelial cell loss was 6.07% at the end of the follow up period with 3.79% at one month postoperative, 2.37% from one to six months postoperative. The mean BCVA improved from  $0.27 \pm 0.09$  preoperatively to  $0.44 \pm 0.12$  postoperatively and the mean UCVA, from  $0.02 \pm 0.01$  to  $0.33 \pm 0.09$  postoperatively, the mean SE was  $-0.93 \pm 0.57$  D Postoperatively.

**Conclusion:** Artisan phakic IOL had excellent results including., their suitability for high myopes, reversibility, high optical quality, predictability, safety, efficacy, potential gain in visual acuity in myopic patients and did not produce significant corneal endothelial cell loss 6months after surgery.

**Keywords:** phakic intraocular lenses, endothelial cell loss, high myopia.

### INTRODUCTION

High myopia represents a multiple management challenge. Surgical options such as refractive lens exchange are less desirable in younger patients as they result in the total loss of accommodation and a higher risk of retinal detachment. Another option is excimer laser treatment, effective in the correction of low-to-moderate myopia. However, high refractive errors are beyond the boundaries of safety and effectiveness of corneal surgery. Even with wavefront-optimized and wavefront-guided treatment, common concerns include lower predictability of the refractive outcome, postoperative refractive instability, and the risk of postoperative ectasia<sup>(1)</sup>.

A healthy corneal endothelium is essential to maintain corneal clarity. Corneal endothelial safety has been a main concern not only regarding intraocular refractive procedures, namely phakic intraocular lens (pIOL) implantation, but also regarding corneal refractive surgery<sup>(2)</sup>.

Thus, in the absence of contraindications, the safest and most effective procedure for treating young patients with moderate-to-high refractive errors and/or low corneal thickness is phakic intraocular lens (pIOL) implantation. This is a preferred technique, since it preserves accommodation and corneal architecture, is potentially reversible, and has outcomes that are more predictable, with faster recovery than excimer surgery<sup>(1)</sup>. The iris-claw or lobster-claw lens was first designed by Worst in 1977 for aphakic eyes<sup>(3)</sup>. Later, in 1986, Worst and Fechner modified this IOL to a biconcave anterior chamber lens for the correction of myopia. To increase the safety of this IOL and minimize the possibility of IOL-cornea contact<sup>(4)</sup>, in 1991 the biconcave design was changed to a convex- concave model with a lower shoulder, a thinner periphery, and a larger optic diameter (5.0mm) to reduce photopic phenomena. This lens, called the Worst myopia claw lens, has been implanted successfully since

then. In 1998, the name of the lens was changed to the Artisan-Worst lens, without a change in lens design. In 2002, AMO(*Abbott Medical Optics, Inc.*) acquired the global distribution rights of the Artisan, now known as the Verisyse lens<sup>(5)</sup>. Previously, it has been shown that these PIOL display stable and predictable visual results. However, the effects of iris fixated PIOL on endothelial cell loss have remained a matter of controversial debate<sup>(6)</sup>.

## AIM OF THE WORK

The aim of this work is to evaluate the endothelial cell count changes in eyes implanted with the iris-claw phakic lens for treatment of moderate to high myopia as regard changes in cell density.

## PATIENTS AND METHODS

This study included Ten eyes of patients with moderate to high myopia implanted with The Iris-Claw Anterior Chamber Phakic Intraocular Lens at Al-Hussein University Hospital, we did Preoperative specular microscopy and serial postoperative specular microscopy ( Topcon SP-1P, Topcon Medical Inc., Japan).) were performed to evaluate endothelial cell count changes over 6 months. Endothelial cell images were collected in the central region of the cornea before surgery and 1 and 6 months after surgery.

### Study design

A prospective randomized study from October 2016 till June 2017 . It was approved by the ethical board of Al-Azhar University and an informed written consent was taken from each participant in the study

### Patient's selection

#### Inclusion criteria

- Age >20 years.
- Stable refraction defined as less than 0.5 D change for more than 1 year .
- Ammetropia not correctable with excimer laser surgery.
- Intolerance of contact lenses or spectacles.
- Clear cornea with no opacities and no evidence of endothelial
- Normal anterior chamber depth > 2.8 mm measured from the endothelium
- Preoperative endothelial cell count of 2300 cells/mm<sup>2</sup> or greater.

#### B) Exclusion criteria

- Previous corneal or intraocular surgery.
- Background of active disease in the anterior segment.

- Any form of clinically significant cataract.
- Recurrent or chronic uveitis.
- IOP >21 mm Hg or glaucoma.
- Preexisting macular degeneration or macular pathology.
- Systemic diseases (eg, autoimmune disorder, connective tissue disease, atopia, diabetes mellitus).

•

### Preoperative evaluation

A complete ophthalmological examination included: visual acuity, refraction, slit-lamp examination, indirect Ophthalmoscopy and specular microscopy.

#### -Visual Acuity:

Uncorrected (UCVA) and best corrected visual acuity (BCVA).

#### -Refraction:

Manifest and cycloplegic refraction were done, cycloplegic refraction is done one hour after instillation of 1% cyclopentolate eye drops.

#### -Slit-Lamp Examination:

Anterior segment examination using the slit lamp was performed.

#### -Indirect ophthalmoscopy:

Fundus examination was done to assess the periphery as well as the central part of the retina.

#### -Applanation tonometry.

### -Investigations

(1) **AC depth (ACD)** (the distance between the anterior corneal surface and anterior surface of crystalline lens) measurement and keratometry readings using the Sirius Scheimpflug Analyzer (CSO, Costruzione Strumenti Oftalmici, Florence, Italy).

(2) **Corneal Endothelial Cell Count** (central area):

Central area of the corneal endothelium was evaluated using specular microscopy. A non-contact specular microscopy was performed by Topcon SP- 1P (Topcon Medical Inc., Japan).

#### -Lens Power Calculation:

The manufacturers calculated the IOL power required to achieve emmetropia using the Van der Heijde formula after they were provided with the patient's information. which consisted of the preoperative spherical equivalent (SE) refraction at spectacle plane (12.0 mm in front of the cornea) , keratometry readings, and corrected AC depth. The AC depth in Van der Heijde's formula is the distance between the anterior corneal surface and the cardinal plane of the IOL.

**The procedure:( Fig. 1)**

- The procedure was performed under peribulbar anesthesia or general anesthesia.
- Povidone iodine (Betadine) 5% was used to sterilize the eye, and povidone iodine 10% to sterilize the eyelids and surrounding skin.
- A plastic sterile drape (Opsite) was applied to draw away the lashes, followed by the application of a wire speculum to separate the eyelids.
- a 2-plane, 5.2 mm or 6.2 mm posterior corneal incision is centered at 12 o'clock and 2 vertical paracenteses directed toward the enclavation area are performed at 2 o'clock and 10 o'clock.
- The pupil should be constricted to protect the crystalline lens from contact with the pIOL or the instruments during surgery. This is achieved by injecting acetylcholine (Myochol) in the anterior chamber at the beginning of the procedure.
- After the anterior chamber is filled with a cohesive ocular viscoelastic device(OVD), the IOL is introduced and rotated 90 degrees into a horizontal position. The pIOL is fixated with an enclavation needle that has a bent shaft and a bent tip that pushes the iris into both claws.
- The needle is introduced through one paracentesis and holds the fold of iris while the pIOL is slightly depressed with the implantation forceps so the claws will automatically grasp the iris. Hands are then switched, and the same maneuver is performed through the other paracentesis.
- If the pIOL is not well centered, enclavation can be released by pushing in the central portion of the claw with the enclavation needle. A peripheral iridectomy is performed at 12 o'clock to prevent pupillary block . The viscoelastic is removed.
- The corneal wound is then sutured with interrupted 10-0 nylon Sutures or figure of eight suture.

- Subconjunctivally, Gentamycin 20 000u and Dexmathasone 2.5mg were injected.

**Post-operative medication**

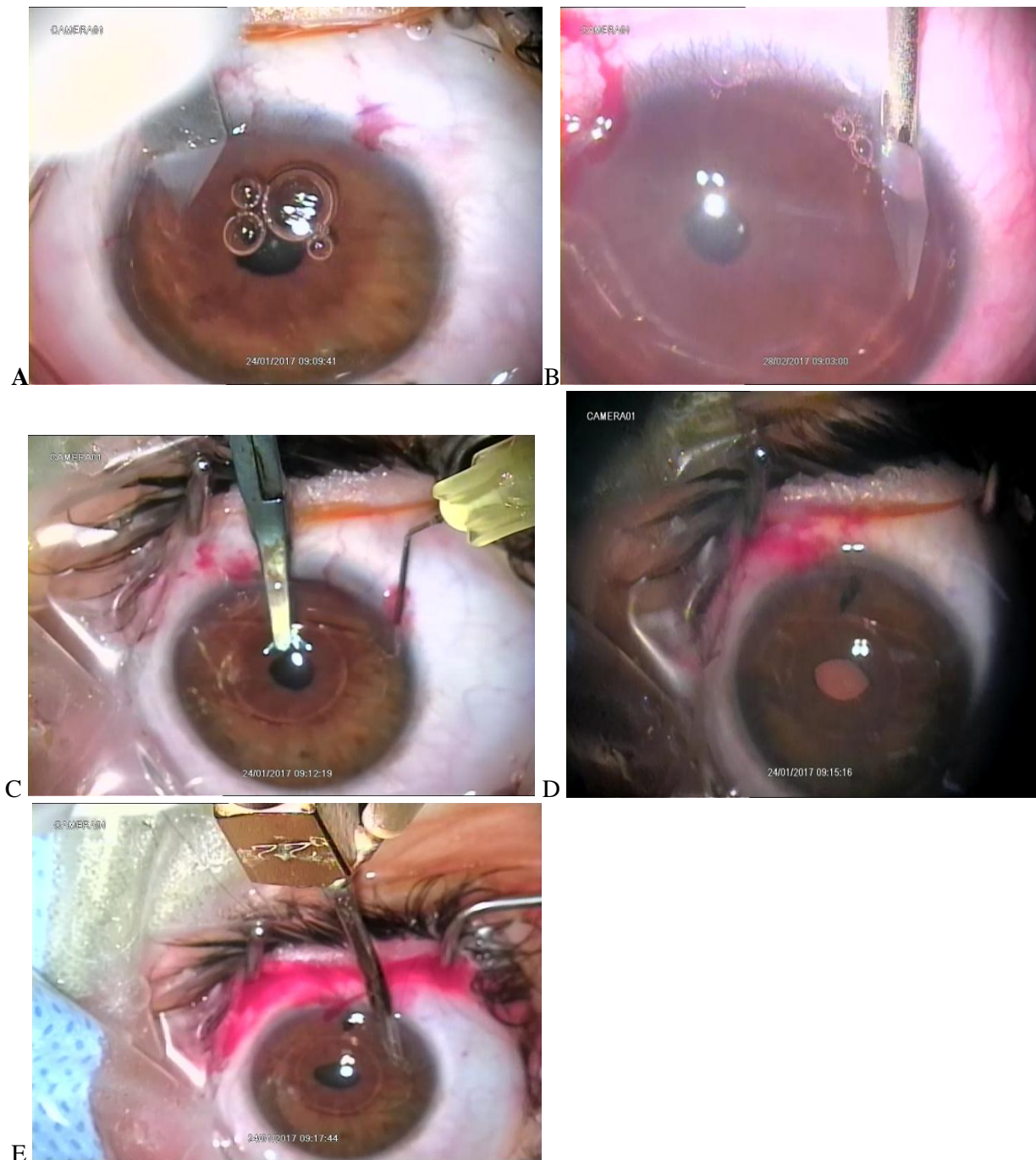
- Topical Prednisolone acetate 1% eye drops every two hours (while the patient is awake only) for one week then tapered gradually over six weeks.
- Topical Gatifloxacin 0.3% eye drops every two awaken hours for one week then four times per day for two weeks.
- Combined Tobramycin 3% with Dexamethasone phosphate 0.1% eye ointment once before sleep for one week.
- Actezolamide 250 mg tablet every 12 hours for 48 hours according to the needs.

**Postoperative follow-up:**

Initial postoperative examination was done on the first day postoperative followed by periodic follow-ups on the first week then after one month, two months and six months .

***In each visit the following was done:***

- UCVA
- Checking IOP using Air puff Tonometer.
- Assessment of inflammation (Aqueous flare and cellular reaction )with the room light dimmed, The slit lamp specifications are highest intensity slit beam, smallest aperture, illumination angle of 30° to 45° and magnification X16
- Assessment of lens clarity using the Slit lamp.
- ECD will be done using the non contact specular microscope: Central area of the corneal endothelium was evaluated using specular microscopy. A non-contact specular microscopy was performed by Topcon SP- 1P(Topcon Medical Inc., Japan) and compared with the preoperative data at the first and six months after implantation.



**Fig. 1:** Implantation of Artisan implants. (A): The corneal incision . (B): vertical paracenteses directed toward the enclavation area are performed at 2 o'clock. (C): The pIOL is fixated with an enclavation needle (D) peripheral iridectomy is performed at 12 o'clock (E) The viscoelastic is removed.

**The study was done after approval of ethical board of Al-Azhar university and an informed written consent was taken from each participant in the study.**

### *Statistical analysis*

The data were collected, revised, coded and entered to the statistical package for social science (SPSS) version 20. The qualitative data were presented as **number** and **percentages** while the quantitative data with parametric distribution were presented as **mean, standard deviations and ranges**. Comparison between two paired groups with quantitative data and parametric distribution were done by using *paired t-test*.

*Spearman correlation coefficients* were used to assess the correlation between two quantitative parameters in the same group.

The confidence interval was set to 95% and the margin of error accepted was set to 5%. So, the ***P Value (Probability)*** was considered significant as the following:

$P > 0.05$  means it is not statistically significant.

$P < 0.05$  means it is statistically significant.

$P < 0.01$  means it is statistically highly significant.

## RESULTS

Ten eyes of seven patients with moderate to high myopia were implanted with iris-fixated anterior chamber phakic IOL. Nine eyes belonging to females (90%) and one eye to a male (10%). The mean age of patients was 24.10 years ranged from 20 to 28 years. The UCVA ranged from 0.01 (CF at 50cm) to 0.03 (2\60) with the mean of 0.02 (1\60)  $\pm$  0.01. The BCVA ranged from 0.25 (6\24) to 0.5 (6\12) with the mean of 0.27 (6\22)  $\pm$  0.09.

The spherical error ranged from -11.50D to -20.00D with the mean of  $-15.24 \pm 2.76$ D. The

cylindrical error ranged from 0D to -2.5D with the mean of  $-1.15 \pm 0.85$ D. Cylindrical error was present in 8 eyes (80%) and two eyes had no cylindrical error (20%). IOP ranged from 12 to 18 mmHg with the mean of  $15.45 \pm 1.9$  mmHg. The ACD ranged from 2.95 to 3.52mm with the mean ACD of  $3.17 \pm 0.21$ mm. The corneal thickness ranged from 480 to 577 $\mu$ m with the mean thickness of  $530 \pm 0.03$  $\mu$ m. The endothelial cell counts ranged from 2715 to 3846 cell/mm<sup>2</sup> with the mean endothelial cell count of  $3198.50 \pm 444.67$  cell/mm<sup>2</sup>. The IOL powers ranged from -17.50D – -11.50D with the mean IOL power of  $-14.40 \pm 2.02$  D.

**Table (1): Preoperative patient characteristics.**

Parameter	Pre Operative patients Characteristics	
	Mean $\pm$ SD	Range
SE (D)	$-15.24 \pm 2.76$	-20.00 – - 11.50
ACD (mm)	$3.17 \pm 0.21$	2.95 – 3.52
CCT ( $\mu$ m)	$530 \pm 0.03$	480 – 580
ECC (cell/mm <sup>2</sup> )	$3198.50 \pm 444.67$	2715 – 3846
Cylinder (D)	$-1.15 \pm 0.85$	-2.50 – 0.00
IOL power(D)	$-14.40 \pm 2.02$	-17.50 – -11.50
ACD : anterior chamber depth., CCT : central corneal thickness., ECC : endothelial cell count ., SE : spherical equivalent		

Seven eyes were operated under local anesthesia (70%) while Three eyes under general anesthesia (30%). Surgery was uneventful in 9 eyes (90%). Difficult insertion of the IOL was encountered in 1 eye (10%) with the tendency of the AC to get shallow and difficult iris enclavation. This eye was operated under local peribulbar anesthesia and it seems that the shallow AC (2.95 mm) and high IOP during surgery were the causes of this difficulty.

## Postoperative results

**Table (2): Changes in the mean postoperative UCVA from the preoperative value.**

UCVA	Mean Preoperative	Mean Postoperative	Paired test	
	No.=10	No.=10	T	P-value
Mean $\pm$ SD	$0.02 \pm 0.01$	$0.33 \pm 0.09$	-10.992	0.000
Range	0.01 – 0.03	0.30 – 0.50		

Mean preoperative UCVA was  $0.02 \pm 0.01$ (range, 0.01 – 0.03).(Table 2) shows that postoperative UCVA had *statistically very highly significant improvement* from preoperative value (P = 0.000)

**Table (3): Changes in the mean postoperative BCVA from the preoperative value.**

BCVA	Mean Preoperative	Mean Postoperative	Paired test	
	No.=10	No.=10	t	P-value
Mean $\pm$ SD	$0.27 \pm 0.09$	$0.44 \pm 0.12$	-4.177	0.002
Range	0.20 – 0.50	0.30 – 0.60		

(Table 3) shows that postoperative BCVA had *statistically very highly significant improvement* from preoperative value (P= 0.002).

**Safety**

In terms of safety, the BCVA remained the same or improved in ten eyes (100%). The safety index (mean postoperative BCVA / mean preoperative BCVA ) was 1.62 at 6 months.

**Efficacy:**

In terms of efficacy, the postoperative UCVA at 6 months was better than or equal to the preoperative BCVA the efficacy index (mean post operative UCVA / mean preoperative BCVA) was 1.22 at 6 months.

Table (4): Changes in the mean postoperative spherical error from the preoperative value.

<b>Spherical equivalent</b>	<b>Mean Preoperative</b>	<b>Mean Postoperative</b>	<b>Paired test</b>	
	<b>No.=10</b>	<b>No.=10</b>	<b>T</b>	<b>P-value</b>
Mean±SD	-15.24 ± 2.76 D	-0.93 ± 0.57 D	-15.399	0.001
Range	-20.00 – -11.50 D	-2.00 – 0.00 D		

Emmetropia was aimed in all eyes.(Table 4) shows that postoperative spherical error had statistically very highly significant improvement from preoperative value (P = 0.000). All eyes were within ± 1.50 D of emmetropia.

Table (5): Changes in the mean postoperative cylindrical error from the preoperative value.

<b>Cylinder</b>	<b>Mean Preoperative</b>	<b>Mean Postoperative</b>	<b>Paired test</b>	
	<b>No.=10</b>	<b>No.=10</b>	<b>T</b>	<b>P-value</b>
Mean ±SD	-1.15 ± 0.85D	-1.50 ± 0.63D	1.681	0.127
Range	-2.50 – 0.00D	-3.00 – -0.75D		

The corneal wound was oriented superiorly (at 90°) irrespective to the axis of astigmatism present.(Table 5) shows that mean postoperative cylindrical error had *no statistically significant change* from preoperative value (P=0.127) .

Table (6): Changes in the mean postoperative IOP from the preoperative value.

<b>Mean Preoperative mmHg</b>	<b>Factor</b>	<b>Postoperative mmHg</b>	<b>P value</b>
15.45 ± 1.98	1 day	17.20 ± 1.005	0.0002
	1 week	15.85 ± 0.875	1.0001
	1 month	14.80 ± 1.794	1.0001
	2 months	14.60 ± 1.353	1.0001
	6 months	14.30 ± 2.029	0.9034

(Table 6) shows that postoperative mean IOP had *statistically highly significant increase* from preoperative value in the first day postoperative (P = 0.0002). IOP had *no statistically significant change* from the preoperative value from one week – 6 months postoperative .

Table (7 ): Changes in the mean postoperative ECC one month after surgery from the preoperative value

<b>ECC</b>	<b>Pre</b>	<b>Post1 M</b>	<b>Paired test</b>	
	<b>No.=10</b>	<b>No.=10</b>	<b>T</b>	<b>P-value</b>
Mean±SD	3198.50 ± 444.67	3074.50 ± 410.76	4.629	0.001
Range	2715.00 – 3846.00	2609.00 – 3686.00		

**Preoperative** mean endothelial cell count was 3198.50 ± 444.67 cells/ mm<sup>2</sup> (range, 2715.00 – 3846.00 cells/ mm<sup>2</sup>)., it was 3074.50 ± 410.76 cells/ mm<sup>2</sup> (range, 2609.00 – 3686.00 cells/ mm<sup>2</sup>) at **1 month** after surgery., 3003.00 ± 411.91cells/ mm<sup>2</sup> (range, 2532.00 – 3610.00cells/ mm<sup>2</sup>) at **6 months** after surgery.

(Table 7 ) shows that **1 month** postoperative ECD had *statistically highly significant decrease* from preoperative value (P = 0.001).

Table (8 ): Changes in the mean postoperative ECC 6 month after surgery from the preoperative value.

<b>ECC</b>	<b>Pre</b>	<b>Post 6 M</b>	<b>Paired test</b>	
	<b>No.=10</b>	<b>No.=10</b>	<b>T</b>	<b>P-value</b>
Mean±SD	3198.50 ± 444.67	3003.00 ± 411.91	7.556	0.001
Range	2715.00 – 3846.00	2532.00 – 3610.00		

(Table 8 ) shows that **6 month** postoperative ECD had *statistically highly significant decrease* from preoperative value (P = 0.000)

**Table (9) : percentage of mean endothelial cell loss 1,6 months postoperative**

ECC		Total no. = 10
% change at 1month	Mean $\pm$ SD	-3.791 $\pm$ 2.540
	Range	-8.13 – -0.56
% change at 6month	Mean $\pm$ SD	-6.070 $\pm$ 2.384
	Range	-10 – -3
% change between 1m and 6m	Mean $\pm$ SD	-2.370 $\pm$ 0.424
	Range	-3 – -2

The mean endothelial cell loss was 6.07% at the end of the follow up period with 3.79% at one month postoperative, 2.37% from one to six months postoperative( table 9) .

### **Patient compliance and satisfaction**

Patient satisfaction was encountered in 9 eyes (90%) with only one eye (10%) where the patient was not satisfied with the quality of vision. Although this patient achieved UCVA of 0.25 (6\24) and BCVA of 0.5 (6\12), he had residual cylindrical error of -2.0D and spherical error of 1.Night glare was complained of in three eyes (30%) after 1month of the surgery that was minimized to only 1 eye (10%) after 3months.

### **Complications:**

Anterior uveitis occurred in 3 eyes (30%) after surgery all responded well to topical and oral steroids, Slight pupil ovalization was reported in two eyes (20%) which were visually insignificant and not accompanied by any other problem, Iris-tissue depigmentation and atrophy at the enclavation site occurred in (20%) 2 eyes at the last follow-up. Crystalline lens opacities, retinal detachment, and pupillary block were not observed

## **DISCUSSION**

Our study included Ten eyes of seven patients with moderate to high myopia were implanted with *iris-fixated anterior chamber phakic IOL*. All patients had UCVA less than 0.10 (6/60) before surgery. However, all eyes (100%) had UCVA of 0.25 (6\24) or better six months after surgery, the recorded levels of UCVA and BCVA in patients with high myopia due to myopic chorioretinal degeneration must be considered.

Regarding final refraction., 90 % of eyes were within  $\pm$  1.50 D of emmetropia, only one eye (10%) had residual cylindrical error of -2.50D and spherical error of 1.5D that might be due to improper preoperative cycloplegia, so cycloplegic refraction is mandatory in all cases of PIOL. The refractive results were stable and the BCVA improved one to two lines from the preoperative values.

The major statistically significant finding in our study was the decrease in the endothelial cell density (ECD). The total endothelial cell loss

was 6.07% at 6 months postoperative at the end of the follow up period with 3.79% at 1 month, 2.37% from one to six months. No eye required explantation of the iris-fixated pIOL due to unacceptable cell loss.

Natural loss of corneal endothelial cells is about 0.6% per year, as reported by **Bourne *et al.***<sup>(7)</sup>. In 1991, **Fechner *et al.***<sup>(8)</sup> described the first results of this type of PIOL with a follow-up of more than 12 months: Five of 109 eyes experienced corneal endothelial cell loss by surgical trauma and 5 eyes showed progressive corneal endothelial cell loss that caused corneal edema in one eye. In a prospective study that included 111 eyes with a follow-up of 4 years, **Menezo *et al.***<sup>(9)</sup> reported that the largest percentage of corneal endothelial cell loss was noticed during the first 6 months after implantation ,The mean cell loss was 3.9% at 6 months, 6.6% at 1 year and conclude that the main cause for corneal endothelial cell loss is surgical trauma.. Other studies have shown similar results. (**Krumeich *et al.***<sup>(10)</sup>, **Landesz *et al.***<sup>(11)</sup>, **Groß *et al.***<sup>(12)</sup> and **Alió *et al.***<sup>(13)</sup>) .

This goes with results was revealed by **Moshirfar *et al.***<sup>(14)</sup> who reported a 6.8% decrease 12 months after Verisyse, In the **Benedett *et al.***<sup>(15)</sup> study, the mean endothelial cell loss was 2.8% at 4 months, 3.9% at 12 months, and 5.4% at 24 months after implantation of Artisan PIOL, **Stulting *et al.***<sup>(16)</sup> showed a mean decrease of, 1.06% at 12 months 4.8% three years after Verisyse, **Doors *et al.***<sup>(17)</sup> described a decrease of 3.3% 12 months after after Artisan/Artiflex implantation ,**Yuan *et al.***<sup>(18)</sup> reported a 5.3 % decrease one year after Verisyse implantation.

**Bouheraoua *et al.***<sup>(6)</sup> found that the endothelial cell loss was 6.27% at 1 year after Artisan PIOL implantation, In the **Shajari *et al.***<sup>(19)</sup> study, the mean endothelial cell loss was 4.5 % at 12 months ,**Yaşa *et al.***<sup>(20)</sup> found that the cell loss at six months postoperatively (3.4% loss). ECD loss from six months postoperatively to two years postoperatively was not statistically significant ,In

a recent study done on **Guerraet al.**<sup>(1)</sup> the mean endothelial cell loss was 2.68 % at 12 months after implantation of Verisyse PIOL. Researchers therefore considered surgery to be the cause of the early corneal endothelial cell loss for pIOL, this is also affected by the learning curve of the surgeon<sup>(21)</sup>.

In contrast to our findings., **Pérez-Santonja et al.**<sup>(22)</sup> reported more corneal endothelial cell loss of 17.6%, 24 months after Artisan implantation and **Coullet et al.**<sup>(23)</sup> reported a decrease of 9.4% and 9% in endothelial cell counts following Artisan and Artiflex implantation after 1-year, **Titiyal et al.**<sup>(24)</sup> reported a corneal endothelial cell loss of 12.5% 4 years after Artisan/Verisyse implantation. **Karimian et al.**<sup>(25)</sup> reported a decrease of 10.1 % corneal endothelial cells after three years following implantation of **Artisan /Artiflex** pIOL.

On the other hand., **Maloney et al.**<sup>(26)</sup> reported no difference in corneal endothelial cells between preoperatively and 6 months postoperatively. **Budo et al.**<sup>(27)</sup> reported a corneal endothelial cell loss of 0.7% 3 years after Artisan/Verisyse implantation. **Pop and Payette et al.**<sup>(28)</sup> reported no significant change in corneal endothelial cells 2 years after Artisan implantation. **Senthil et al.**<sup>(29)</sup> did not find significant corneal endothelial cell loss 24 months after Artisan surgery. Recently **Venter et al.**<sup>(30)</sup> reported that, the cell loss of 1.4% at 5 years which was not statistically

There is a wide variation in reported cell loss in the literature ,Such variation might be attributable to the measurement techniques used and repeatability of measurements. Important issue must be considered when analyzing postoperative ECD is the effect of the surgical procedure itself. In a retrospective cohort study, **Na et al.**<sup>(31)</sup> found that intraoperative manipulation during iris-claw pIOL implantation had a direct effect on the survival of endothelial cells. The percentage of endothelial cell loss was significantly higher in eyes that had even transient events, such as intraoperative bleeding, postoperative IOP rise, and anterior uveitis Therefore, surgeon experience and close follow-up are key to preventing unwanted damage to the corneal endothelium.

**Tazhib et al.**<sup>(32)</sup> did not find a correlation between endothelial cell loss at 10 years and the preoperative ACD. However, **Saxena et al.**<sup>(33)</sup> showed a significant negative correlation between ACD and endothelial cell loss. No other factors, including patient age, sex, refractive error, incision size, or side of the eye, was associated with endothelial cell loss.

Endothelial cell loss might be attributed to the damage of the corneal endothelium by direct close

contact between the Artisan AC pIOL and the inner surface of the cornea either during implantation or from postoperative changes in Artisan position with leaning forward or eye rubbing. Moreover, chronic postoperative subclinical inflammation might cause direct toxicity to the endothelium and led to further damage<sup>(34)</sup>.

Regarding **glare and halos.**, night glare was complained of only in three eyes (30%) after 1month of the surgery that was minimized to only 1 eye (10%) after 3months. This might be attributed to pupil dilatation in darkness rather than pupil ovalization. By the end of the follow up period., 90% of eyes had no glare and halos. This was the same explanation as **Maroccos et al.**<sup>(36)</sup> who reported significantly less glare and halos with the Artisan PIOL than with other PIOL, especially the 6.0 mm optic. This was attributed to the larger optic (6.0 mm versus 5.0 mm) and the fixation of the IOL to the iris, which causes less pupil dilation. Therefore, the 6.0 mm optic iris-fixed pIOL seems to be preferable to the 5.0 mm optic.

Regarding **surgically induced astigmatism (SIA).**, The corneal wound was oriented superiorly (at 90°) irrespective to the axis of astigmatism present, our results reported no significant increase in postoperative astigmatism (P=0.127).Because the PMMA iris claw IOL (Artisan/ Verisyse) is not foldable, it requires an incision that approximately equals the optic diameter (5.0 or 6.0 mm), which may induce SIA. According to **Kohnen et al.**<sup>(34)</sup> SIA after the 5.0 to 6.0 mm incisions is less than one might expect. **Menezo et al.**<sup>(9)</sup> reported no significant increase in postoperative astigmatism.

Regarding **Pigment Dispersion/Lens Deposits** : two cases of inflammatory cell deposits on the IOL surface had been reported in the present study. This might be due to the fact that the optic of the Artisan has an anterior vault to prevent iris chaffing. Pigment cells are occasionally visible on the pIOL optic in the early postoperative period from surgical trauma. iris pigment defects at the site of enclavation as a possible source of pigment dispersion <sup>(34)</sup>.Similar results were described by **Menezo et al.**<sup>(36)</sup> and **Stulting et al.**<sup>(16)</sup> reported a long-term incidence of 6.6 – 6.9% pigment dispersion after Artisan implantation.

**Chronic postoperative subclinical AC inflammation** in the present study has been a major concern in 30% of eyes .This is because this pIOL is fixated directly to the iris tissue and causes pressure or shear forces when the eye is moving or patients rub their eyes. This may lead to injury or

increased permeability of the iris vessels with breakdown of the blood–aqueous barrier and chronic release of inflammatory mediators. **Perez-Santonja *et al.***<sup>(37)</sup> reported elevated flare levels in 30 eyes compared with the levels in a normal population at 12, 18, and 24 months after surgery. **Senthil *et al.***<sup>(28)</sup> reported postoperative iritis in 3% of the eyes after Artisan implantation that resolved completely. **Moshirfa *et al.***<sup>(14)</sup> reported an incidence of 1.2% of cells and flare for 1 month after Artisan/Verisyse surgery.

Regarding **Pupil Ovalization /Iris Retraction**: Pupil ovalization or irregularity can occur if fixation of the PIOL haptics is performed asymmetrically. Slight pupil ovalization is reported in the present study in two eyes (20%) which were visually insignificant and not accompanied by any other problem. **Maloney *et al.***<sup>(25)</sup> reported pupil irregularities in 14.0% of eyes on the first day after surgery and 1.2% after 6 months. **Moshirfar *et al.***<sup>(14)</sup> reported a pupil ovalization incidence of 2.4% after Artisan/Verisyse implantation. **Stulting *et al.***<sup>(16)</sup> reported an incidence of 13.0% of asymptomatic oval pupil 1 day after Artisan/Verisyse pIOL implantation, which decreased to 0.4% at 3 years.

No cases of **RD** occurred in the present study. Mostly this was due to thorough preoperative and postoperative fundoscopic investigation. On the contrary., **Stulting *et al.***<sup>(16)</sup> reported a RD rate of 0.3% per year after Artisan/Verisyse implantation. However., this was similar to RD rates that had been reported in the highly myopic population that did not have refractive surgery (**Tielsch *et al.***<sup>(38)</sup>, (**Beijing Rhegmatogenous Retinal Detachment Study Group**<sup>(39)</sup>, **Güell *et al.***<sup>(40)</sup>).

Other complications of iris-fixated pIOL implantation early postoperative hyphema, and ischemic optic neuropathy, Crystalline lens opacities, and pupillary block were not observed.

## CONCLUSION

The present study revealed that Artisan phakic IOL had excellent results including., their suitability for high myopes, reversibility, high optical quality, predictability, safety, efficacy, potential gain in visual acuity in myopic patients due to retinal magnification, preservation of corneal architecture, a sphericity and accommodation. Moreover, correction is not limited by corneal thickness or topography. **Preoperative corneal endothelial cell density measurement**, using specular microscopy, is also obligatory. Patients with endothelial damage or corneal endothelial cell density below 2000

cell/mm<sup>2</sup> should not receive the Artisan phakic IOL. We also concluded that **surgery** is mostly the cause of the early corneal endothelial cell loss, this is also affected by the learning curve of the surgeon. **A sufficient anterior chamber depth (ACD)** is necessary, ACD less than 2.8mm measured from the endothelium is considered a limitation for Artisan phakic IOL. In addition., a thorough preoperative and postoperative **fundoscopic examination** is required to rule out retinal changes or vitreoretinal pathologies and to perform prophylactic laser photocoagulation, if required.

## REFERENCES

- (1) **Guerra MG, Silva AMM, Marques SHM *et al.* (2017)** :Phakic Intraocular Lens Implantation: Refractive Outcome and Safety in Patients with Anterior Chamber + between 2.8 and 3.0 versus  $\geq 3.0$  mm. Ophthalmic Res. ,57(4):239-246.
- (2) **Morral M, Güell JL, El Hussein MA *et al.* (2016)**: paired eye comparison of corneal endothelial cell counts after unilateral iris claw phakic intraocular lens implantation. J Cataract Refract Surg., 42(1):117-26.
- (3) **Worst (1977)**: quoted from ( **Alio´ JL, Perez-Santonja JJ (2012)**: Phakic intraocular lenses and their role in modern refractive surgery. In Refractive Surgery With Phakic IOL Fundamentals and Clinical Practice. 2nd ed New Delhi: Jaypee Brothers. Pp 5–11.)
- (4) **Fechner PU, Worst JGF (1989)**: A new concave intraocular lens for the correction of myopia. Eur J Implant Refract Surg., 1:41–43
- (5) **Alio´ JL, Perez-Santonja JJ (2012)**: Phakic intraocular lenses and their role in modern refractive surgery. In Refractive Surgery With Phakic IOL Fundamentals and Clinical Practice. 2nd ed New Delhi: Jaypee Brothers. Pp 5–11.
- (6) **Bouheraoua N, Bonnet C, Labbé A, *et al.* (2015)**: Irisfixated phakic intraocular lens implantation to correct myopia and a predictive model of endothelial cell loss. J Cataract Refract Surg., 41(11):2450-7.
- (7) **Bourne WM, Nelson LR, Hodge DO (2004)**. Central corneal endothelial cell changes over a ten-year period. Invest Ophthalmol Vis Sci., 38:779–782.
- (8) **Fechner PU, Strobel J, Wichmann W (1991)** : Correction of myopia by implantation of a concave Worst-iris claw lens into phakic eyes. Refract Corneal Surg., 7:286–898.
- (9) **Menezo JL, Cisneros AL, Rodriguez-Salvador V (1998)** : Endothelial study of iris-claw phakic lens: four year follow-up. J Cataract Refract Surg., 24:1039–1049.
- (10) **Krumeich JH, Daniel J, Gast R (1996)**: Closed-system technique for implantation of iris-supported negative-power intraocular lens. J Refract Surg., 12:334–340.
- (11) **Landesz M, Worst JGF, van Rij G (2000)**: Long-term results of correction of high myopia with an iris claw phakic intraocular lens. J Refract Surg., 16:310–316.

- (12) **Groß S, Knorz MC, Liermann A, et al.(2001):** Results of implantation of a Worst Iris Claw lens for correction of high myopia. *Ophthalmology* ,98:635–638.
- (13) **Alio´ JL, Mulet ME, Shalaby AM(2002):.** Artisan phakic iris claw intraocular lens for high primary and secondary hyperopia. *J Refract Surg.*, 18:697–707.
- (14) **Moshirfar M, Holz HA, Davis DK(2007):** Two-year follow-up of the Artisan /Verisyse iris supported phakic intraocular lens for the correction of high myopia. *J Cataract Refract Surg.*,33:1392–1397.
- (15) **Benedetti S, Casamenti V, Marcaccio L, et al. (2005):** Correction of myopia of 7 to 24 diopters with the Artisan phakic intraocular lens: two-year follow-up. *J Refract Surg.*, 21:116–126.
- (16) **Stulting RD, John ME, Maloney RK et al. (2008):** Three-year results of Artisan/Verisyse phakic intraocular lens implantation., results of the United States Food and Drug Administration Clinical Trial., the U.S. Verisyse Study Group. *Ophthalmology*, 115:464–472.
- (17) **Doors M, Berendschot TTJM, Webers CAB, et al.(2010):**Model to predict endothelial cell loss after iris-fixated phakic intraocular lens implantation. *Invest Ophthalmol Vis Sci.*, 51:811–815.
- (18) **Yuan X, PingHZ, HongWC, Yin D, et al.(2012):** Five-year follow-up after anterior iris-fixated intraocular lens implantation in phakic eyes to correct high myopia. *Eye*, 26:321–326.
- (19) **Shajari M , Scheffel M , Koss MJ, Kohnen T(2016) :** Dependency of endothelial cell loss on anterior chamber depth within first 4 years after implantation of iris-supported phakic intraocular lenses to treat high myopia. *J Cataract Refract Surg.*, 42(11):1562-1569.
- (20) **Yaşa D , Ağca A, Alkın Z et al.(2016):** Two Year Follow Up of Artisan Iris Supported Phakic Anterior Chamber Intraocularlens for Correction of High Myopia. *Semin Ophthalmol* , 31(3):280-4.
- (21) **Dejaco-Ruhswurm I, Scholz U, Pieh S et al.(2002).** Long-term endothelial changes in phakic eyes with posterior chamber intraocular lenses. *J Cataract Refract Surg.*, 28:1589-1593.
- (22) **Perez-Santonja JJ, Alio´ JL, Jime´nez-Alfaro I et al.(2000).** Surgical correction of severe myopia with an angle-supported phakic intraocular lens. *J Cataract Refract Surg.*,26:1288–1302.
- (23) **Coullet J, Guëll JL, Fournié P et al.(2006):** Iris supported phakic lenses (rigid vs foldable version) for treating moderately high myopia: Randomized paired eye comparison. *Am J Ophthalmol.*,142:909-916.
- (24) **Titiyal JS, Sharma N, Mannan R et al.(2012):** Iris fixated intraocular lens implantation to correct moderate to high myopia in Asian-Indian eyes: Five-year results. *J Cataract Refract Surg.*, 38:1446–1452.
- (25) **Karimian F, Baradaran-Rafii A, Hashemian SJ et al.(2014):** Comparison of three phakic intraocular lenses for correction of myopia. *J Ophthalmic Vis Res.*, 9:427–433.
- (26) **Maloney RK, Nguyen LH, John ME(2002):** Artisan phakic intraocular lens for myopia., short-term results of a prospective, multicenter study., the Artisan Lens Study Group. *Ophthalmology*, 109:1631–1641.
- (27) **Budo C, Hessloehl JC, Izak M et al.(2000):** Multicenter study of the Artisan phakic intraocular lens. *J Cataract Refract Surg.*, 26:1163–1171.
- (28) **Pop M, Payette Y(2004):** Initial results of endothelial cell counts after Artisan lens for phakic eyes., an evaluation of the United States Food and Drug Administration Ophtec Study. *Ophthalmology*, 111:309–317.
- (29) **Senthil S, Reddy KP, Ravisankar, Srilakshmi(2006):**A retrospective analysis of the first Indian experience on Artisan phakic intraocular lens. *Indian J Ophthalmol.*, 54:251–255.
- (30) **Venter JA, Pelouskova M, Schallhorn SC, Collins BM et al.(2015):** Visual acuity improvement in adult amblyopic eyes with an iris-fixated phakic intraocular lens: long-term results. *J Cataract Refract Surg.*, 41:541–547.
- (31) **Na K-S, Jeon S, Joo C-K(2013):** Effect of intraoperative manipulation during iris-claw phakic IOL implantation on endothelium. *Can J Ophthalmol.*, 48:259–264.
- (32) **Tahzib NG, Nuijts RM, Wu WY(2007):** Long-term study of Artisan phakic intraocular lens implantation for the correction of moderate to high myopia., ten-year follow-up results. *Ophthalmology*, 114: 1133–1142.
- (33) **Saxena R, Boekhoorn SS, Mulder PGH, Noordzij B, van Rij G, Luyten GPM. et al.(2008):** Long-term follow-up of endothelial cell change after Artisan phakic intraocular lens implantation. *Ophthalmology*, 115:608–613.
- (34) **Kohnen T, Kook D, Morral M et al.(2010):** Phakic intraocular lenses: part 2: results and complications. *J Cataract Refract Surg.*, 36: 2168–2194. Review.
- (35) **Maroccos R, Vaz F, Marinho A et al.(2001):** Glare and halos after "phakic IOL" surgery for the correction of high myopia. *Ophthalmology*, 98:1055 –1059.
- (36) **Menezo JL, Peris-Martinez C, Cisneros-Lanuza AL et al.(2004):** Rate of cataract formation in 343 highly myopic eyes after implantation of three types of phakic intraocular lenses. *J Refract Surg.*,20:317–324.
- (37) **Perez-Santonja JJ, Iradier MT, Benitez del Castillo JM et al.(1996) :** Chronic subclinical inflammation in phakic eyes with intraocular lenses to correct myopia. *J Cataract Refract Surg.*, 22:183–187.
- (38) **Tielsch JM, Legro MW, Cassard SD et al.(1996):** Risk factors for retinal detachment after cataract surgery., a population-based case-control study. *Ophthalmology*, 103:1537–1545.
- (39) **Beijing Rhegmatogenous Retinal Detachment Study Group (2003):** Incidence and epidemiological characteristics of rhegmatogenous retinal detachment in Beijing, China. *Ophthalmology*, 110:2413–2417.
- (40) **Guell JL, Morral M, Gris O et al.( 2008):.** Five-year follow-up of 399 phakic Artisan-Verisyse implantation for myopia, hyperopia, and/or astigmatism. *Ophthalmology*, 115:1002–1012.